



veterinary/ focus #28.1

The worldwide journal for the companion animal veterinarian 2018 - \$10 / 10€

CANINE AND FELINE DERMATOLOGY

Feline miliary dermatitis - Catherine D. Milley - P02

**How I approach... Canine
pododermatitis** - Rosanna Marsella - P08

Pemphigus foliaceus in feline patients
- Christoph J. Klinger and Ralf S. Mueller - P15

**Anti-inflammatory and anti-pruritic
therapy in canine atopy**
- Debbie Gow and Tim Nuttall - P20

Dermatological features of canine leishmaniasis
- Laura Ordeix and Xavier Roura - P22

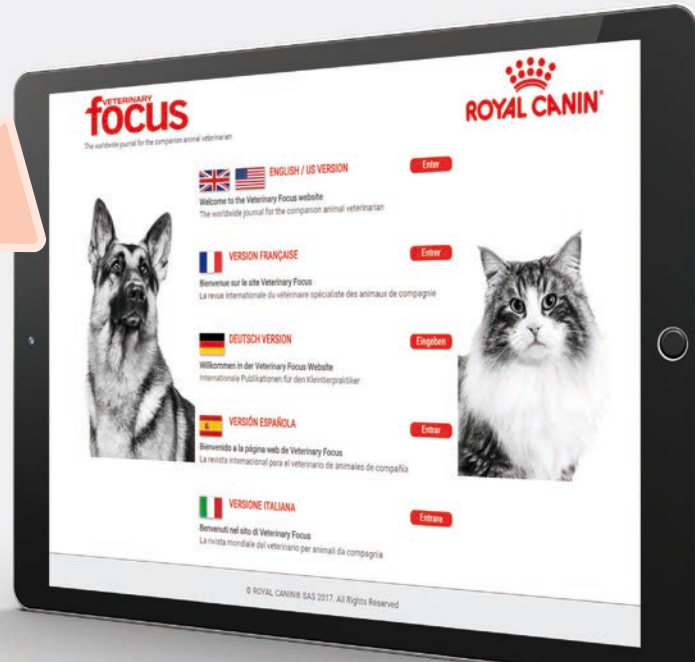**Cutaneous manifestations of
systemic disease** - Patricia D. White - P30

**Elimination diet trials: setting up for
success** - Vandre Clear - P38

Quality control for hydrolyzed diets
- Isabelle Lesponne and Jérôme Naar - P40

Vascular skin disease - Elizabeth Goodale - P42

FIND YOUR MAGAZINE ONLINE



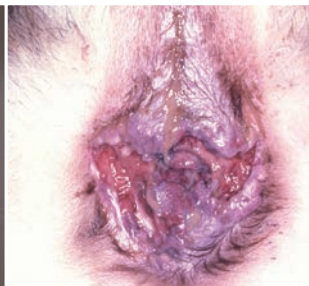<http://vetfocus.royalcanin.com/>

veterinary/ focus #28.2

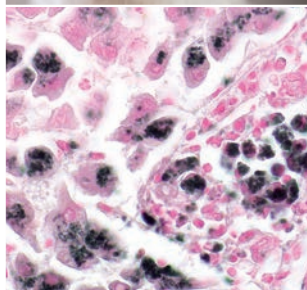
The worldwide journal for the companion animal veterinarian



Shutterstock



David Scarff



Hille Fieten



Shutterstock

COMING UP...

In our next issue of *Veterinary Focus*, we will look at different aspects of genetics:

- **Clinical applications of genetic testing**
Angela Hughes and Jamie Freyer, USA
- **Copper-associated hepatitis in dogs**
Hille Fieten, Netherlands
- **Perianal fistula disease in dogs**
Lindsay McKay, USA
- **MDR1 – new clinical implications for an old mutation**
Cindy Cole, USA
- **Genetic canine blood disorders**
Urs Giger, USA
- **Audiogenic reflex seizures in cats**
Mark Lowrie and Laurent Garosi, UK
- **Maintaining genetic diversity in dog and cat breeds: Why it matters**
Katie Lytle and Casey Knox, USA
- **Urolith prevalence in dogs and cats**
Doreen Houston and Anne-Marie Germain, Canada
- **Liquid biopsy – the future of cancer diagnostics for veterinarians?**
Matthew Breen and Claire Wiley, USA



We welcome offers to write ideas for papers and suggestions for topics and authors, which should be directed to the editor. *Veterinary Focus* is fully covered by copyright. No part of this publication may be reproduced, copied or transmitted in any form or by any means (including graphic, electronic or mechanical), without the written consent of the publishers © Royal Canin SAS 2018. Proprietary names (trademarks) have not been specially identified. It cannot, however, be conducted from the omission of such information that they are non-proprietary names and as such can be used by everyone. The publishers cannot take any responsibility for information provided on dosages and methods of application. Details of this kind must be checked for correctness by the individual user in the appropriate literature. While every effort has been made by the translators to ensure the accuracy of their translations, no responsibility for the correctness of the original articles and thus no resulting claims against professional negligence can be accepted in this connection. Views expressed by authors or contributors do not necessarily reflect the views of the publishers, editors or editorial advisors.

THOU ART A BOIL, A PLAGUE SORE, AN EMBOSSED CARBUNCLE! *Shakespeare*

“Look and you will find it – what is unsought will go undetected” *Sophocles*

It was King Lear, in the play of the same name, who voiced the above words – cursing his eldest daughter for her scheming and treachery in a way that may sound strange to modern ears, but his choice of words would strike a chord with any listener in the Elizabethan era. Such dermatological imagery was carefully chosen; in the early 17th century people recognized that many unpleasant skin lesions could preface severe systemic illness and even death – so to compare someone with such dreadful disorders was indeed a curse. And Shakespeare was not alone in using such defects as disparaging metaphors; countless authors and playwrights over the years have given their villains hideous scars and disfiguring lesions to mirror the evil that lies within.



In a more prosaic 21st century we may find more suitable quotes to describe our enemies, but we cannot deny that skin disease is still unpleasant and, in many cases, potentially serious. However beneath the cover of this issue lies much to help the clinician, and although nobody will claim that diagnosis in dermatology is always easy, this journal may help point the way; as the playwright Sophocles put it, “Look and you will find it – what is unsought will go undetected.”

Ewan McNEILL
Editor-in-chief



• Focus on *Veterinary Focus*

Pemphigus foliaceus is an uncommon autoimmune, blistering skin disease that occurs in many different species. While the clinical appearance and the underlying etiology can vary, in most feline patients the typical lesions are pustules and crusts on the face, inner pinnae and footpads, as well as paronychia.



p15

Although unusual, cutaneous manifestations of systemic disease can resemble many commonly seen skin problems, so obtaining a thorough history and interpreting clinical findings in light of this information is vital.

p30

p42

Vasculitis is inflammation that specifically targets blood vessels and is generally regarded as a reaction pattern, rather than a definitive diagnosis; it is essential to investigate possible triggers wherever possible.

veterinary focus #28.1



Origine du papier : VIRTON (Belgique)
Taux de fibres recyclés : 0%
Certification : 100% PEFC
Impact sur l'eau : 0.012 P tot kg/tonne

Editorial committee

- Craig Datz, DVM, Dipl. ACVN, Senior Scientific Affairs Manager, Royal Canin, USA
- Pauline Devlin, BSc, PhD, Scientific Communications and External Affairs, Royal Canin, UK
- María Elena Fernández, DVM, Chile
- Philippe Marniquet, DVM, Dipl. ESSEC, Veterinarian Prescribers Marketing Manager, Royal Canin, France
- Brunella Marra, DVM, Scientific Communication and Scientific Affairs Manager, Royal Canin, Italy
- Sally Perea, DVM, Dipl. ACVN, Nutritionist, Royal Canin, USA
- Claudia Rade, DVM, Scientific Affairs Manager, Royal Canin, Germany
- Anne van den Wildenberg, DVM Scientific and Regulatory Affairs Manager, Royal Canin, Netherlands

Translation control

- Elisabeth Landes, DVM (German)
- Noemí Del Castillo, PhD (Spanish)
- Matthias Ma, DVM (Chinese)
- Minoru Fukuyama, DVM (Japanese)
- Boris Shulyak, PhD (Russian)

Deputy publisher: Buena Media Plus
Bernardo Gallitelli and Didier Olivereau
90, rue de Paris 92100 Boulogne-Billancourt, France
Phone: +33 (0) 1 72 44 62 00

Editor-in-chief: Ewan McNeill, BVMS, Cert VR, MRCVS

Editorial secretary

- Laurent Cathalan (lcathalan@buena-media.fr)

Artwork

- Pierre Ménard
- Printed in the European Union**
ISSN 2430-7874

Legal deposit: March 2018
Cover: Shutterstock

Veterinary Focus is published in Brazilian Portuguese, Chinese, English, French, German, Italian, Japanese, Polish, Russian & Spanish.

Find the most recent issues on: <http://vetfocus.royalcanin.com> and www.ivos.org.

The licensing arrangements for therapeutic agents intended for use in small animal species vary greatly worldwide. In the absence of a specific license, consideration should be given to issuing an appropriate cautionary warning prior to administration of any such drug.

Veterinary Focus is fully covered by copyright. No part of this publication may be reproduced, copied or transmitted in any form or by any means (including graphic, electronic or mechanical), without the written consent of the publishers © Royal Canin SAS 2018. Proprietary names (trademarks) have

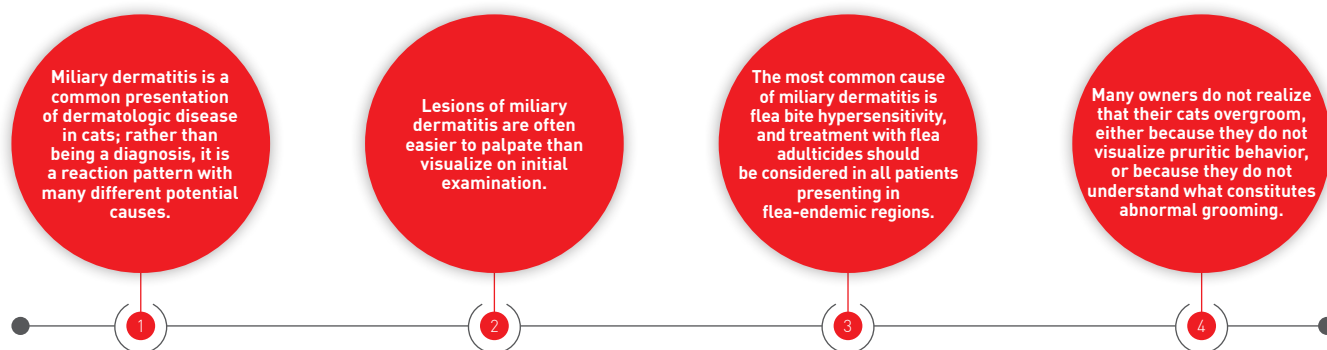
not been specially identified. It cannot, however, be conducted from the omission of such information that they are non-proprietary names and as such can be used by everyone. The publishers cannot take any responsibility for information provided on dosages and methods of application. Details of this kind must be checked for correctness by the individual user in the appropriate literature. While every effort has been made by the translators to ensure the accuracy of their translations, no responsibility for the correctness of the original articles and thus no resulting claims against professional negligence can be accepted in this connection. Views expressed by authors or contributors do not necessarily reflect the views of the publishers, editors or editorial advisors.



FELINE MILIARY DERMATITIS

The cat with miliary dermatitis is often frustrating for both owner and clinician, in that failure to identify the underlying cause and implement appropriate treatment can lead to frequent recurrence. Here Catherine Milley takes us through the logical process of working-up these cases.

KEY POINTS



Introduction

Miliary dermatitis is a common presentation of dermatologic disease in cats. Historically this condition was called “miliary eczema”; the word “miliary” is defined as “resembling or suggesting a small seed or many small seeds” (1), and the term found usage as it describes the feeling encountered when examining the coat of an affected cat. Lesions are often felt easier than they are seen, due to their small size and distribution within an often otherwise normal-appearing coat. In more specific dermatologic terms, miliary dermatitis can be described as clusters of small, typically crusted, papules. Miliary dermatitis is not a diagnosis, but rather a reaction pattern with many different potential causes; the differential diagnoses are numerous and include hypersensitivity to flea bites; cutaneous adverse food reactions; atopic dermatitis; ectoparasites; bacterial, viral, yeast or dermatophyte infections; cutaneous adverse drug reactions; pemphigus foliaceus; dietary imbalances; feline hypereosinophilic syndrome; and urticaria pigmentosa (2). This article will review the clinical signs, typical presentation and etiologies of feline miliary dermatitis, as well as focusing on the diagnostic approach and treatment options for this common skin condition.

Clinical presentation

Miliary dermatitis can be localized or generalized, and it may be the sole presenting sign or it can occur with other primary or secondary dermatologic lesions. Most commonly, groups of small papules are found on the head and neck, limbs, trunk or dorsal lumbar region (**Figure 1**). Lesions that may be concurrently detected in patients with miliary dermatitis include alopecia, excoriations, erosions and ulcers. Miliary dermatitis may also be found in cats with lesions consistent with the feline eosinophilic granuloma complex (EGC) such as indolent ulcers, eosinophilic plaques and eosinophilic granulomas. Although pruritus is common in affected patients, it is not a consistent finding. This may in part be due to the discrete grooming practices of cats; owners may not visualize pruritic behavior, or may not understand what constitutes abnormal grooming behavior.

In an attempt to concisely evaluate outcome measures of therapeutics in cats affected by miliary dermatitis and various other skin lesions, a novel scale, known as SCORFAD, has been developed (3). Using this scale, 10 body regions are identified, namely the head; neck; dorsal and lateral thorax; rump and tail; flanks; sternum and axilla; abdomen; perineum; forelimbs and paws; and the hindlimbs and paws. Using this scoring system, miliary dermatitis may be classified as *very mild* in patients with 10 or fewer papules in one body region; *mild* in patients with more than 10 papules in

Catherine D. Milley,

BSc, DVM, Dipl. ACVD

Animal Dermatology Clinic, Portland, Oregon, USA

Dr. Milley graduated from the Western College of Veterinary Medicine in Canada in 2006 and worked in both mixed and small animal practice. She then completed a residency in veterinary dermatology at the Animal Dermatology Clinic in Kentucky and currently works in a private dermatology practice. Her primary interests include the treatment and diagnosis of allergic dermatitis and infectious diseases.



one body region; *moderate* in patients with 10 or fewer papules in more than one body region; and *severe* in patients with more than 10 papules in more than one body region (3).

●●● Etiology

The potential causes of miliary dermatitis are many, so for the purposes of this discussion they will be subdivided into larger categories.

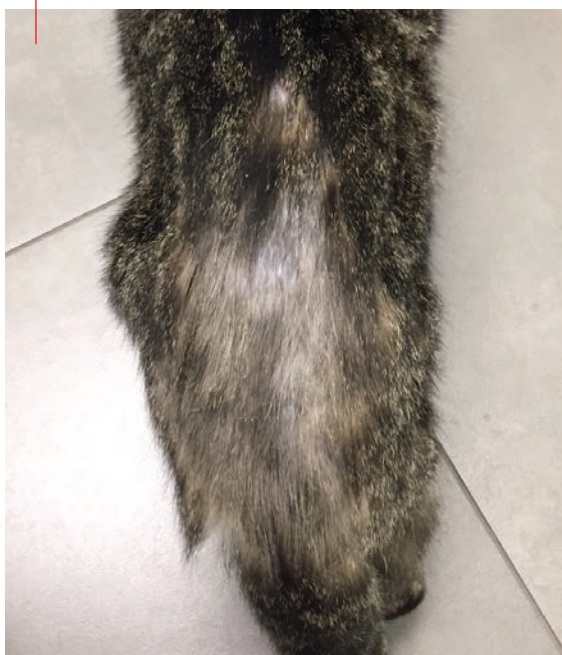Hypersensitivity

Hypersensitivity responses to insects (especially fleas), environmental allergens, food allergens and drugs have all been known to cause miliary dermatitis. Flea bite hypersensitivity is the most common cause of feline miliary dermatitis and should be considered in every case occurring in flea-endemic regions (2,4,5) as flea saliva contains many irritating substances that can lead to a hypersensitivity reaction. In contrast to dogs, where

intermittent exposure to fleas seems to cause more hypersensitivity reactions than continuous exposure, cats who are exposed to fleas regularly are at the same or greater risk to develop flea bite hypersensitivity than cats exposed intermittently (2). Cats with flea bite hypersensitivity are pruritic and frequently have lesions on the head, the dorsal lumbar region, the tail and the ventral abdomen (**Figure 2**) (5). In one multicenter study it was found that 35% of cats with flea bite hypersensitivity had miliary dermatitis as at least one of their presenting signs (5).

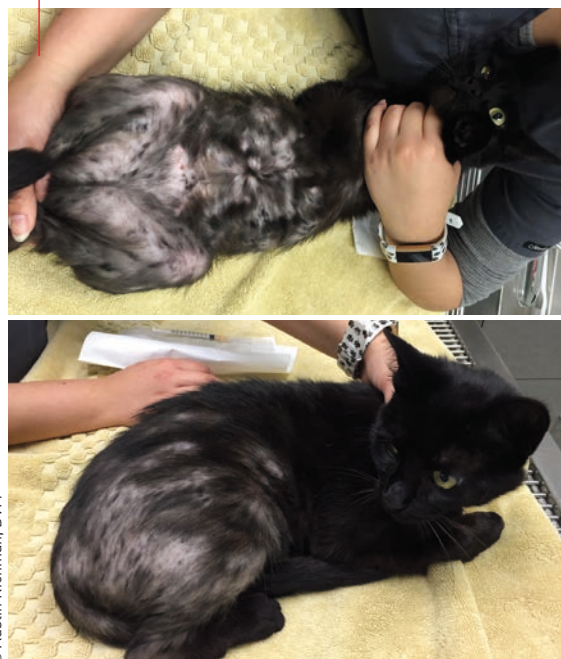Hypersensitivity to environmental allergens (non-flea, non-food induced hypersensitivity dermatitis or feline atopic syndrome) is another common cause of miliary dermatitis. Along with head and neck excoriations, self-induced alopecia and EGC lesions, miliary dermatitis is a common clinical reaction pattern (6). The literature shows that 18-34% of cats with feline atopic syndrome will present with miliary dermatitis (5,7,8), with the head and ventral abdomen most commonly exhibiting lesions and pruritus (5).

Figure 1. A cat with barbered hair, patchy alopecia and miliary dermatitis along the dorsal lumbar region.



© Austin Richman, DVM

Figure 2. A patient with flea bite hypersensitivity exhibiting barbered hair, alopecia and miliary dermatitis of the dorsal lumbar region, tail, ventral abdomen and proximal hind limbs.



© Austin Richman, DVM

Cutaneous adverse food reactions (food hypersensitivities) are reported as the primary cause of pruritus in 12-17% of non-seasonally pruritic cats (2,5). 42% of cats with pruritus and concurrent abnormal gastrointestinal symptoms of chronic vomiting or diarrhea had confirmed food hypersensitivities (9). One study found that 20% of cats with food-induced hypersensitivity presented with miliary dermatitis (5). Cats with adverse food reactions commonly have lesions and pruritus around the head and neck as well as the ventral abdomen (5).

Other hypersensitivities can also create lesions of miliary dermatitis. For example, mosquito bite hypersensitivity may cause miliary dermatitis on the bridge of the nose and pinnae, and cutaneous adverse drug reactions may cause pruritus and subsequent miliary dermatitis in some patients (10).

Infection

In addition to fleas, other ectoparasites such as *Trombiculae* spp. (Chigger mites), *Cheyletiella* spp., *Otodectes cynotis*, *Sarcoptes scabiei*, *Felicola subrostratus*, *Notoedres cati* and *Demodex* spp. can occasionally cause miliary dermatitis (Figure 3) (11-14). Location of lesions is dependent on the preferred habitats for the parasite in question, e.g., miliary dermatitis would be more likely to occur on the trunk in a patient infested with *Cheyletiella* spp. but more commonly on the head and around the ears in a cat with *Otodectes cynotis*.

One study found that 29% of cats diagnosed with pyoderma had evidence of miliary dermatitis on examination (15). The majority of cats in the study were pruritic and lesions were often multifocal (face, neck, limbs, ventral abdomen and dorsal trunk).

Cats with marked pruritus due to dermatophytosis may present with miliary dermatitis. Most often these cases are caused by *Microsporum canis*. Dermatophytosis is usually a minimally pruritic condition in cats, so when evidence of miliary dermatitis and pruritus is found in affected individuals it is suggested to investigate for concurrent bacterial infection, ectoparasitism or allergy



“Flea bite hypersensitivity is the most common cause of feline miliary dermatitis and should be considered as a differential in any cat presenting with symptoms”

Catherine D. Milley



© Catherine Milley, DVM, Dipl. ACVD

Figure 3. Preauricular and periocular miliary dermatitis and erythema in a cat with *Demodex cati* otitis and flea allergy dermatitis. The cat was positive for feline immunodeficiency virus.

(16). *Malassezia* yeast overgrowth or hypersensitivity may also cause miliary dermatitis. Rarely, cats affected by feline immunodeficiency virus (FIV) (Figure 3) can present with generalized miliary dermatitis (17).

Other

Feline pemphigus foliaceus (see page 15) presents as a focal or generalized crusting dermatosis, and could be considered as a differential diagnosis for miliary dermatitis, particularly if there are crusted papules on the head, face and ears (10). Urticaria pigmentosa is a manifestation of mastocytosis and may present as a crusted papular rash in some cats; Sphinx cats may be more severely affected (18).

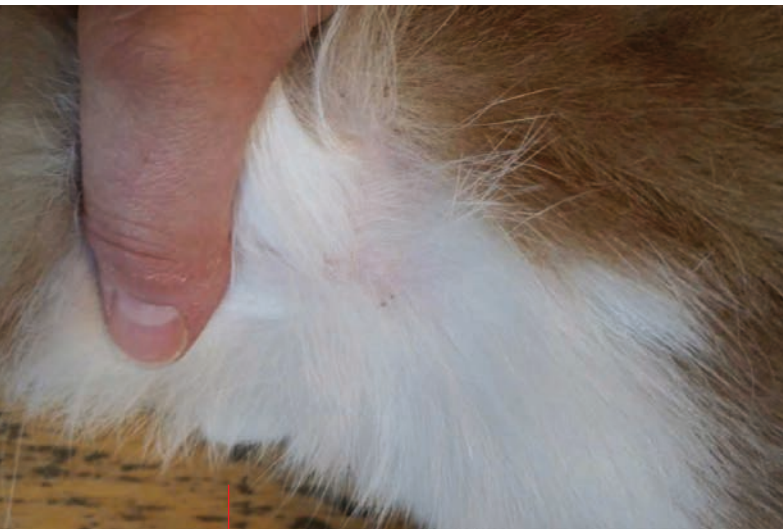

Diagnostic approach

Signalment and history

When a patient presents with signs of miliary dermatitis it is important to consider all differentials, take a detailed history and have a methodical approach in order to properly diagnose and treat the individual. Signalment and history are often some of the most important details when attempting to differentiate between etiologic causes of miliary dermatitis. One of the most valuable pieces of information is to ascertain whether or not the cat goes outdoors, or if there are any other pets in the household who go outdoors. This will help to determine the likelihood of exposure to fleas, parasites, mosquitos, and other sources of irritation. Finding out if there have been any new pets introduced to the household or if there are any other pets or humans in the household that are affected may help in differentiating contagious etiologies.

The presence or absence of pruritus, distribution of pruritus and any history of seasonal pruritus is helpful in determining hypersensitivities such as flea bite allergy, adverse food reactions and feline atopic syndrome. As noted above, owners may not perceive



© Catherine Milley, DVM, Dipl. ACVD

Figure 4. Small crusted papules of miliary dermatitis. These lesions were found upon palpation under a relatively normal hair coat.

certain feline behaviors as pruritus, and it may help to ask if the cat is licking, biting, rubbing, rolling or grooming more, or if there are any patches of hair loss, or tufts of hair around the house. Owners may not identify overgrooming but they may report their pet has more trichobezoars due to increased hair ingestion from excessive grooming.

It can be helpful to know how long the miliary dermatitis has been present, and if this is a recurring issue or a new problem. If the cat has recently been exposed to new medications or treatments an adverse drug reaction should be considered. Concurrent symptoms of gastrointestinal abnormalities may increase the suspicion of an adverse food reaction.

The breed and age of the patient can be helpful clues when determining an etiology. As noted above, Sphinx cats may be more severely affected by urticaria pigmentosa, whilst Siamese cats are reported to have a higher incidence of adverse food reactions than other breeds [2]. Most cats with feline atopic syndrome will present with initial symptoms between 6 months and 2 years of age [2].

Clinical examination

A general physical exam should be followed by a thorough dermatologic exam. The crusted miliary dermatitis lesions are often very small, so it can be helpful to feel the skin by massaging the patient's hair coat to detect the papules (**Figure 4**). An otoscopic exam may detect the presence of concurrent abnormalities that may give clues to the underlying etiologic cause, and the paws and claws should be examined for any evidence of disease.

Examine the skin for evidence of other types of lesions as well. Miliary dermatitis is one of four common clinical reaction patterns found in cats with hypersensitivity disorders (**Figure 5**), the others being head and neck excoriation, self-induced alopecia, and EGC lesions [6]. One study found that 30% of feline atopic syndrome cases presenting with miliary

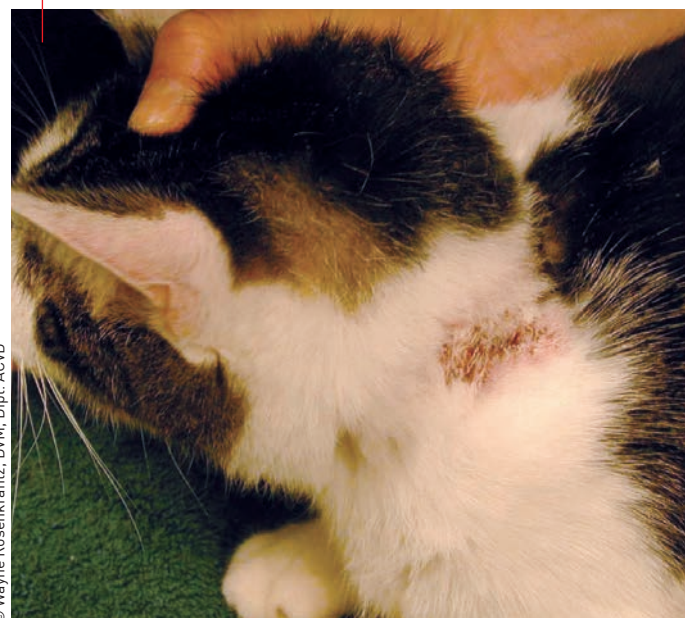dermatitis had concurrent EGC lesions, whereas only 4% had miliary dermatitis lesions alone [8]. Cats who develop pemphigus foliaceus will often have purulent debris around the claw folds in addition to crusting on the rest of the body, particularly the face. Fractured hair shafts, erythema and alopecia can occur with dermatophytosis. Large white scales or dander can accompany *Cheyletiella*. Otitis externa may occur in cats with hypersensitivities or *Otodectes cynotis* infestations.

Diagnostic tests

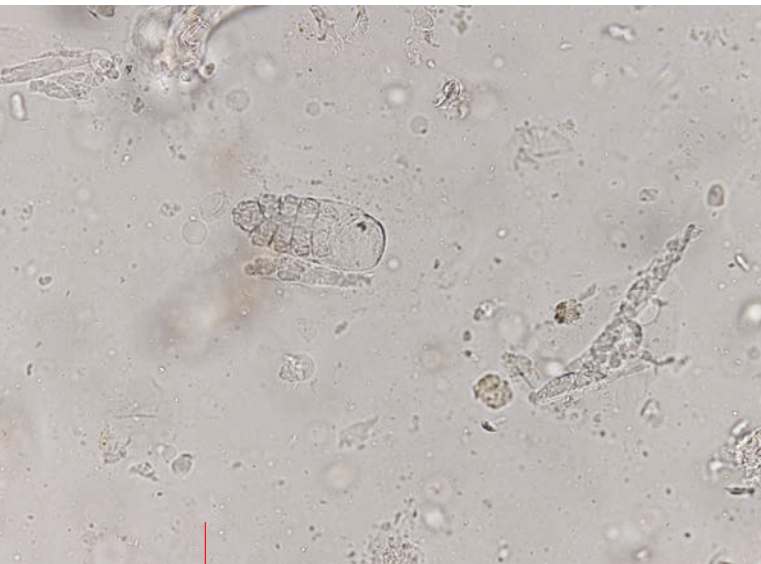Hairs and debris collected by combing should be examined for evidence of fleas or flea dirt. This can also identify parasites such as *Cheyletiella* spp. or *Felicola subrostratus*. Skin scraping is advised to look for evidence of parasites such as *Demodex* spp., *Notoedres cati*, and *Sarcoptes scabiei*. A treatment trial may be necessary to rule out parasitic infestations; in particular, flea bite hypersensitivity should be excluded by using appropriate fast-acting and effective flea adulticides such as spinosad, nitenpyram or fluralaner. It is essential to understand the flea life cycle (and explain this to owners) as flea eggs will not be affected by most adulticidal products, and cats will need to be protected against fleas that will hatch over a period of weeks to months in the environment. It is equally important to treat all in-contact animals when attempting to rule out flea bite hypersensitivity.

Fecal flotation can be a helpful adjunctive test when ruling out parasites. *Otodectes*, *Notoedres*, *Cheyletiella* mites, *Demodex gatoi* (**Figure 6**), *Lynxacarus radovskyi* and Chigger mites can all be found on fecal flotation [19]. The presence of *Dipylidium caninum* tapeworms on fecal analysis may increase the suspicion for the presence of fleas, which serve as an intermediate host [20].

Figure 5. Miliary dermatitis on the dorsal cervical region of a cat with flea allergy dermatitis and feline atopic syndrome.



© Wayne Rosenkrantz, DVM, Dipl. ACVD



© Catherine Milley, DVM, Dipl. ACVD

Figure 6. *Demodex gatoi* found on fecal flotation.

out differential diagnoses (such as cutaneous adverse food reaction, flea allergy dermatitis, pediculosis, etc.) in cats with supportive signalment, history and clinical symptoms. Allergy testing should not be used to diagnose feline atopic syndrome.

Treatment

Effective resolution of miliary dermatitis requires treatment of any infection as well as identification and treatment of all underlying causes.

If found on cytological examination, bacterial infection is most effectively treated with a combination of systemic and topical antimicrobials. Good options for empirical systemic antibiotic include amoxicillin with clavulanic acid and cefovecin, and treatment should continue for one week beyond clinical resolution of the infection [21]. Topical therapy, including chlorhexidine, benzoyl peroxide, silver sulfadiazine and fusidic acid [22], may be used alone in cases of localized infected lesions or to speed resolution of more widespread lesions. It is important to restrict patient grooming after topical products are applied; this may require an Elizabethan collar or distraction with play until the product has dried or been absorbed.

All cases of generalized dermatophytosis should receive topical therapy. Effective options include twice weekly 2% lime sulfur dips, 2% miconazole plus 2% chlorhexidine rinses or 0.2% enilconazole [23]. If systemic therapy is used, itraconazole and terbinafine are good options for cats. Therapy should be continued until 2-3 negative fungal cultures taken at weekly intervals are obtained. It is important to remember the contagious nature of dermatophytosis and affected animals should be separated or all in-contact individuals should be treated topically for the duration of treatment of the affected individual. Environmental control is important when attempting to clear dermatophyte infections, as infective spores can remain viable for up to 18 months [16]. Clients should be instructed on how to reduce environmental contamination by vacuuming and using electrostatic cleaning cloths to pick up hairs, followed by disinfection with 0.5% sodium hypochlorite or accelerated oxygen products [16].

Parasitosis should be treated with appropriate anti-parasiticides depending on which parasite is suspected or identified. Repeated dosing with a broad-spectrum parasiticide such as selamectin or 10% imidacloprid with 1% moxidectin may be used to rule out most parasites in cats. Infestations with *D. gatoi* may be particularly difficult to resolve, however, and will often require six weekly dips with lime sulphur for the affected individual and all in-contact cats [12]. There is also evidence that weekly application of 10% imidacloprid with 1% moxidectin may be effective to treat *D. gatoi* [24].

Flea bite hypersensitivity is the most common cause for chronic miliary dermatitis in cats worldwide and should be considered in every case presenting in flea endemic regions. A treatment trial with flea adulticides

All cases of miliary dermatitis should have a cytological examination. Cytology is invaluable for diagnosing and monitoring the progress of bacterial and yeast infections as well as aiding in the diagnosis and monitoring of conditions like pemphigus foliaceus and dermatophytosis. If bacterial infection is found, bacterial culture and sensitivity may be indicated in order to guide the use of systemic antimicrobials.

Dermatophyte fungal culture, Wood's lamp examination, direct microscopic hair shaft examination, dermoscopy and dermatophyte PCR testing can all be helpful for diagnosing dermatophytosis. Of course, none of these tests are 100% sensitive or specific, and any results must be interpreted in light of clinical lesions, physical exam and history.

Once infectious causes have been ruled out or treated, additional diagnostic tests may be warranted. Tissue biopsies and dermatohistopathology can be helpful to rule out pemphigus foliaceus, cutaneous adverse drug reactions, urticaria pigmentosa and neoplasia. They can also be useful to support a diagnosis of hypersensitivity. Blood work and urinalysis can help to exclude systemic diseases such as hyperthyroidism or retroviral infections that may predispose to infection or poor wound healing.

If the patient has a history of non-seasonal pruritus contributing to the miliary dermatitis, once flea bite hypersensitivity has been ruled out, an elimination diet trial with a limited ingredient novel protein or hydrolyzed protein diet is advised to rule out a cutaneous adverse food reaction. In most cases, at least some improvement in symptoms will be noted within 6 weeks of starting an elimination diet trial in affected cats, but it may take up to 12 weeks to see full resolution of symptoms [2]. Elimination diet trials should be followed by provocative re-challenge in order to confirm a diagnosis of adverse food reaction.

Intradermal skin testing and serum allergy testing may be helpful to direct treatment once a diagnosis of feline atopic syndrome has been made by ruling

should be considered as described in the section on diagnostic testing, and affected individuals may need to be treated for 2-3 months to see full resolution of signs. When ruling out flea bite hypersensitivity it is important to remember to treat all in-contact animals and the environment in order to reduce exposure of the affected individual to flea bites.

If a cutaneous adverse reaction to food was diagnosed with improvement on an elimination diet trial and worsening upon provocative re-challenge it is recommended that patients undergo individual ingredient challenges to determine the specific food allergens so that avoidance can be practiced for treatment. Alternatively, a well-balanced limited ingredient novel protein diet or hydrolyzed protein diet can be fed long term.

Cats with feline atopic dermatitis may benefit from a variety of treatment options. These can include allergy testing and allergen-specific desensitization; symptomatic control with medications such as cyclosporine, corticosteroids and antihistamines; and supportive care with diets that contain products to help the skin barrier, and long-chain polyunsaturated essential fatty acids, predominantly the omega-3-family. Topical therapy with antimicrobial products, corticosteroids and local anesthetics like pramoxine may benefit patients with feline atopic dermatitis.



CONCLUSION

The causes for feline miliary dermatitis are many, and effective treatment of miliary dermatitis depends on determining and treating all infectious and underlying etiologies. Flea bite hypersensitivity is the most common cause of feline miliary dermatitis and should be considered as a differential in any cat presenting with symptoms.



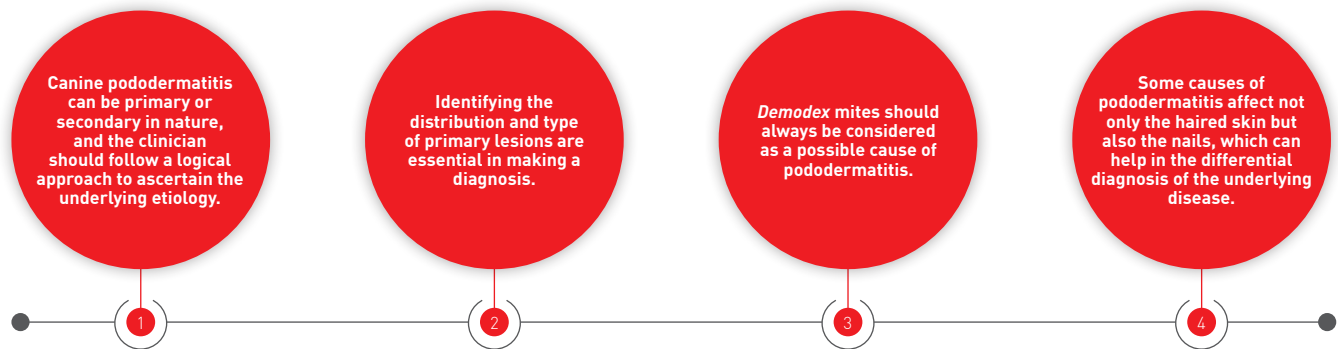
REFERENCES

1. "Miliary." Available at: www.merriam-webster.com. Accessed June 10, 2017.
2. Miller W, Griffin C, Campbell K. Hypersensitivity disorders. In: Miller W, Griffin C, Campbell K (eds). *Muller & Kirk's Small Animal Dermatology* 7th ed. St. Louis: Elsevier, 2013; 363-431.
3. Steffan J, Olivry T, Forster S, et al. Responsiveness and validity of the SCORFAD, an extent and severity scale for feline hypersensitivity dermatitis. *Vet Dermatol* 2012;23:410-e77.
4. Gross T, Ihrke P, Walder E, et al. Ulcerative and crusting diseases of the epidermis. In: Gross T, et al (eds). *Skin Diseases of the Dog and Cat: Clinical and Histopathologic Diagnosis* 2nd ed. Ames: Blackwell Science, 2005;118-121.
5. Hobi S, Linek M, Marignac G, et al. Clinical characteristics and causes of pruritus in cats: a multicentre study on feline hypersensitivity-associated dermatoses. *Vet Dermatol* 2011;22:406-413.
6. Favrot C, Steffan J, Seewald W, et al. Establishment of diagnostic criteria for feline non-flea-induced hypersensitivity dermatitis. *Vet Dermatol* 2011;23:45-e11.
7. Favrot C, Steffan J, Seewald W. Allergy – pathogenesis, diagnostics, and clinical signs: Clinical signs in cats with hypersensitivity dermatitis. *Vet Dermatol* FC-15 Free Communication Abstracts Session 3: 2008;19 (Suppl. 1):33-34.
8. Ravens P, Xu B, Vogelnest L. Feline atopic dermatitis: a retrospective study of 45 cases (2001-2012). *Vet Dermatol* 2014;25:95-e28.
9. Markwell P. Prevalence of food sensitivity in cats with chronic pruritus, vomiting or diarrhea. In: Kwochka K, et al. (eds). *Advances in Veterinary Dermatology III*, Boston: Butterworth Heinemann 1998:493.
10. Miller W, Griffin C, Campbell K. Autoimmune and immune-mediated dermatoses. In: Miller W, et al (eds.) *Muller & Kirk's Small Animal Dermatology*, 7th ed. St. Louis: Elsevier, 2013;432-500.
11. Murai T, Nogami S, Hasegawa A. Protozoal and parasitic diseases: Chigger infestation in three domestic cats with miliary dermatitis. *Vet Dermatol* Free Communication Abstracts Session 5:2008;19 (Suppl. 1):65.
12. Miller W, Griffin C, Campbell K. Parasitic skin disease. In: Miller W, et al (eds.) *Muller & Kirk's Small Animal Dermatology*, 7th ed. St. Louis: Elsevier 2013;284-342.
13. Beale K. Feline dermodicosis; a consideration in the itchy or overgrooming cat. *J Feline Med Surg* 2012;14:209-213.
14. Favrot C. Clinical presentations and specificity of feline manifestations of cutaneous allergies. In: Noli C, et al (eds) *Veterinary Allergy*. Hoboken: John Wiley & Sons, 2014;211-216.
15. Yu H, Vogelnest L. Feline superficial pyoderma: a retrospective study of 52 cases (2001-2011). *Vet Dermatol* 2012;23:448-e86.
16. Miller W, Griffin C, Campbell K. Fungal and algal skin diseases. In: Miller W, et al (eds.) *Muller & Kirk's Small Animal Dermatology*, 7th ed. St. Louis: Elsevier, 2013; 223-283.
17. Miller W, Griffin C, Campbell K. Viral, rickettsial, and protozoal skin diseases. In: Miller W, et al (eds.) *Muller & Kirk's Small Animal Dermatology*, 7th ed. St. Louis: Elsevier, 2013;343-362.
18. Miller W, Griffin C, Campbell K. Congenital and hereditary defects. In: Miller W, et al (eds.) *Muller & Kirk's Small Animal Dermatology*, 7th ed. St. Louis: Elsevier, 2013;573-617.
19. Milley C, Dryden M, Rosenkrantz W, et al. Comparison of parasitic mite retrieval methods in a population of community cats. *J Feline Med Surg* 2017;19:657-664.
20. Bowman D. Helminths. In: Bowman D, et al (eds.) *Georgis' Parasitology for Veterinarians* 8th ed. St. Louis: Elsevier, 2003:115-243.
21. Beco L, Guaguere E, Mendex C, et al. Suggested guidelines for using systemic antimicrobials in bacterial skin infections (2): antimicrobial choice, treatment regimens and compliance. *Vet Rec* 2013;172:156-160.
22. Hillier A, Lloyd D, Weese J, et al. Guidelines for the diagnosis and antimicrobial therapy of canine superficial bacterial folliculitis (Antimicrobial Guidelines Working Group of the International Society for Companion Animal Infectious Diseases). *Vet Dermatol* 2014;25:163-175.
23. Moriello K. Treatment of dermatophytosis in dogs and cats: review of published studies. *Vet Dermatol* 2004;15:99-107.
24. Short J, Gram D. Successful treatment of *Demodex gato* with 10% imidacloprid /1% moxidectin. *J Am Anim Hosp Assoc* 2016;52:68-72.

HOW I APPROACH... CANINE PODODERMATITIS

Dogs with sore feet may at first sight be mundane and easy to treat, but pitfalls await the unwary; Rosanna Marsella takes a personal look at what can be a remarkably complex clinical disorder and gives some useful tips for diagnosis and treatment.

KEY POINTS



Canine pododermatitis is a very common presentation in veterinary dermatology, but since it can result from many different causes it is important to have a logical and sequential diagnostic approach in order to successfully identify the primary disease responsible. With the correct diagnosis, clinical management becomes easier and more targeted. However, as with many dermatological cases, secondary infections and chronic skin changes frequently complicate the clinical picture, whatever the underlying disease, so it is always important to consider the primary, secondary and perpetuating factors for pododermatitis (**Table 1**).

Whilst primary causes of pododermatitis may be pruritic or non-pruritic, secondary infection is frequent and will often cause pruritus, so it is not uncommon for many dogs with pododermatitis to present with pruritus as one of the main complaints. It is therefore important to treat any infection and then re-evaluate for pruritus to effectively identify the triggering disease.

●○○○ How are the lesions distributed?

Primary causes of pododermatitis are diseases that can directly target the feet, although many of them may also affect other body regions. It is therefore important to identify the distribution of lesions on clinical examination. This allows the clinician to

appropriately rank the various differential diagnoses in order of likelihood.

Some diseases affect all four feet, while others only the front feet, at least initially. An example of the former is contact allergy, an example of the latter is atopic

Table 1. Causes of pododermatitis.

Primary factors	
Pruritic <ul style="list-style-type: none"> • Atopic dermatitis • Food allergy • Contact allergy • Flea allergy • Demodicosis • Hookworm dermatitis¹ 	Non-pruritic <ul style="list-style-type: none"> • Hypothyroidism • Demodicosis • Dermatophytosis^{1,2} • Leishmaniasis² • Immune-mediated (e.g., vasculitis², symmetric lupoid onychodystrophy²) • Autoimmune (e.g., pemphigus foliaceus) • Metabolic (e.g., necrolytic migratory erythema¹) • Neoplastic (e.g., mycosis fungoides¹)
Secondary factors	
<ul style="list-style-type: none"> • Bacterial infection • <i>Malassezia</i> infection 	
Perpetuating factors	
<ul style="list-style-type: none"> • Fibrosis/scarring • Interdigital cysts 	

¹ Diseases that can also manifest with hyperkeratosis of the footpads

² Diseases that can affect the nails

Rosanna Marsella,

DVM, Dipl. ACVD

College of Veterinary Medicine, University of Florida, USA

Dr. Marsella is a Diplomate of the American College of Veterinary Dermatology and full Professor at the University of Florida. She has served as co-editor for *Veterinary Dermatology* and is a member of the Task Force on Canine Atopic Dermatitis. She also co-edited the current *BSAVA Dermatology Manual*.



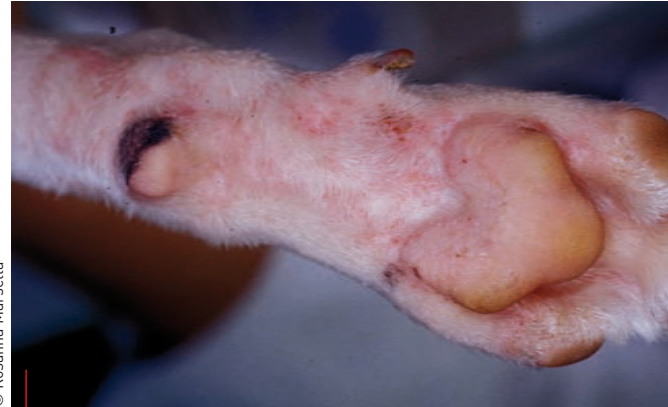dermatitis, which typically starts on the forepaws and then progresses to all four feet. Flea allergy, on the other hand, tends to primarily affect the back feet.

●●○○ What do the primary lesions look like?

It is important to know what type of primary lesions are associated with each disease (e.g., papules, pustules, bullae). For example, contact dermatitis is associated with a primary papular eruption, so if the contact allergy is to either a carpet or a grass, pruritic papules on the palmar-plantar aspect of all four feet would be the expected clinical presentation (1). Other contact areas that are also frequently affected are the muzzle, perineal area and ventral abdomen (Figures 1 and 2).

An example in which the primary lesion is a pustule is pemphigus foliaceus. As pustules are fragile, many patients have crusts as remnants of dried-up pustules (Figure 3). Pemphigus foliaceus in dogs typically affects the face (as a “butterfly” pattern affecting the periocular region, the bridge of the nose and nose itself) and the inner surface of the pinnae (2). Layers of dry pustules may be noticeable on the footpads (Figure 4), especially on the edges of the pads.

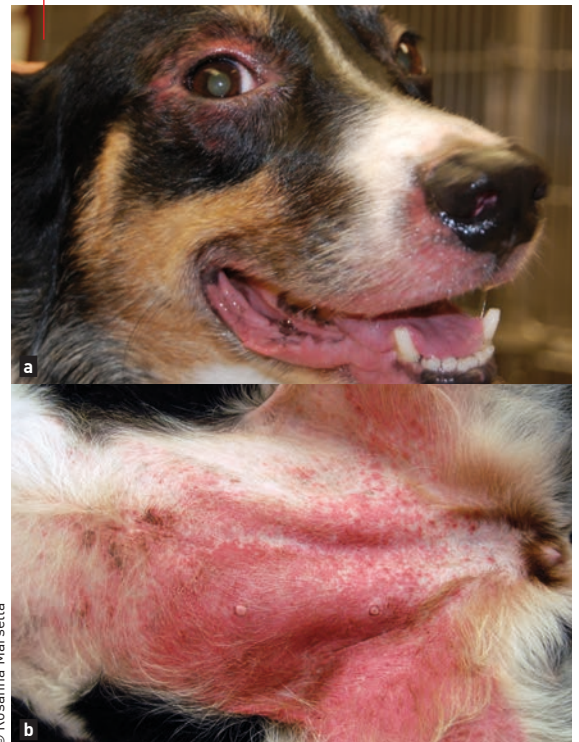Another extremely important primary cause of pododermatitis is *Demodex* mites. In fact, demodicosis should always be included on the list of differential diagnosis for canine pododermatitis (3), as this disease can manifest in a variety of ways. It can present with erythema and pruritus, and may look very similar to an allergic foot; many affected dogs also have a pruritic face and can easily be mistaken as being allergic (Figure 5). Because of this, any pruritic foot should be scraped for *Demodex* spp. before assuming that it is allergy and therapy such as glucocorticoids or oclacitinib is initiated. Comedones are another manifestation of demodicosis (Figure 6); they have a characteristic gray discoloration and are due to plugging of the hair follicles by large number of mites. Their presence should always alert clinicians to perform a skin scrape, although if the foot is too swollen and painful (Figure 7), hair plucks may be considered, with the understanding that the sensitivity of hair plucks is inferior to a deep skin scrape. As the result of folliculitis, most (but not all) affected dogs present with hair loss. Interestingly, long-haired breeds such as Yorkshire and Maltese Terriers do not appear to develop alopecia as often as short-haired breeds.



© Rosanna Marsella

Figure 1. Pruritic papules on the palmar-plantar aspect of all four feet is a typical clinical presentation if a carpet or a grass causes a contact allergy.

Figure 2. Other contact areas that are also frequently affected are the muzzle (a) and ventral abdomen (b).



© Rosanna Marsella

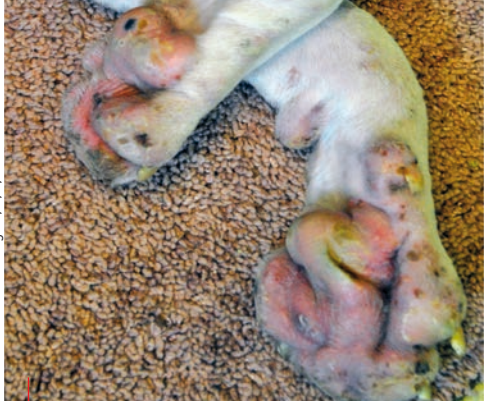

Figure 3. A dog with pemphigus foliaceus. As the pustules are fragile, crusts (remnants of dried up pustules) may be seen.

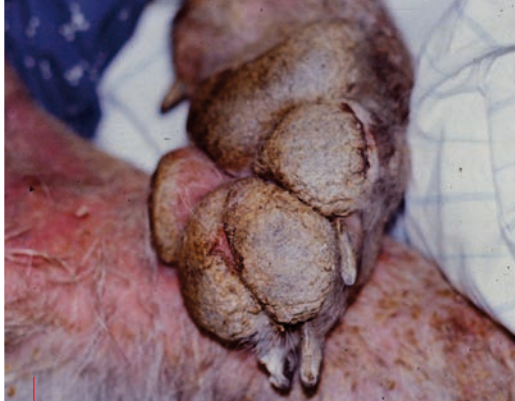

Figure 4. Layers of dry pustules may be noticeable on the footpads if a dog has pemphigus foliaceus.

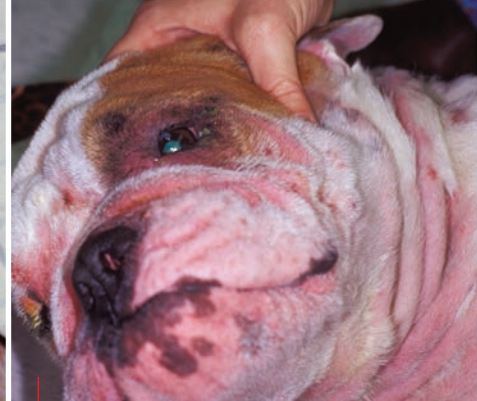

Figure 5. A dog with *Demodex* mange. Many affected dogs have a pruritic face and can easily be mistaken as being allergic.

●●● What else helps with diagnosis?

When considering other causes of pododermatitis, it is important to remember that some diseases involve both haired skin and footpads, while others do not. For example, atopic dermatitis affects only the haired skin, but autoimmune diseases like pemphigus foliaceus may also affect the footpads and present with crusting and hyperkeratosis. There are many differential diagnoses for pododermatitis and hyperkeratosis. One of the most important is superficial necrolytic dermatitis (SND), which targets both the footpads and other areas of the body such as the genitalia and the commissures of the mouth (**Figure 8 and 9**) (4). This is a disease of geriatric animals and is linked to metabolic dysfunction and amino acid deficiency. The footpads in this disease show cracking and fissures, rather than the dry layers of pustules seen with pemphigus. The appearance of the lesions, the different distribution of lesions and the age of the patient are all clues which help the clinician to rank the diseases and prioritize between the likelihood of pemphigus foliaceus and SND.

For both diseases skin biopsy is diagnostic, and it is important to stress the importance of a definitive diagnosis by biopsy rather than simply relying on



“The distribution and appearance of the lesions, along with the presence or absence of pruritus, are real pointers as to the possible underlying etiology.”

Rosanna Marsella

clinical impression, as the treatments are completely different. In pemphigus foliaceus acantholytic cells and superficial pustules are hallmarks of the disease, while parakeratosis, spongiosis and epidermal hyperplasia of the basal cell layer (“red-white-blue” layers) are considered characteristic for SND. In pemphigus, treatment with glucocorticoids and other immunosuppressive agent are the standard of care, whereas in SND glucocorticoids are usually contraindicated, as many affected dogs are either diabetic or borderline diabetic. In these cases it is crucial to investigate the underlying metabolic disease and to institute appropriate nutritional therapy with amino acids, zinc and essential fatty acids.

It is important to stress that acantholytic cells, traditionally considered a hallmark of pemphigus, can also be caused by other diseases such as contact allergy and dermatophytosis. In any disease where a severe neutrophilic inflammatory infiltrate develops, acantholysis may ensue as a consequence of the proteolytic effect of degenerating neutrophils. Since some cases of *Trichophyton* may resemble pemphigus foliaceus clinically (**Figure 10**) it is important to consider this as a differential diagnosis; misdiagnosis of dermatophytosis as pemphigus could be problematic, as glucocorticoids are inappropriate for ringworm cases. In these patients systemic antifungal therapy is necessary for many months, and itraconazole (5 mg/kg PO q24H) is commonly used as it concentrates in keratin and has residual activity after discontinuation of therapy. Terbinafine (20 mg/kg PO q12H) is also an excellent choice, due to its keratinophilic properties and its ability to persist in the keratin for extended periods of time.

●●● What else can affect the feet?

Other diseases that can affect the feet are syndromes such as vasculitis and erythema multiforme. Vasculitis is a type III hypersensitivity that can be due to many causes and is triggered by a variety of antigenic stimuli (5). The immune complex deposition may occur on the feet and ears, as well as other areas of the body. It may be initiated by drugs, vaccines, or infectious causes such as tick-borne diseases. The typical presentation on the feet is the presence of ulcers in the center of the footpads (**Figure 11**), the ulcer size varying depending on the severity and the size of the blood vessels affected. Diagnosis is based

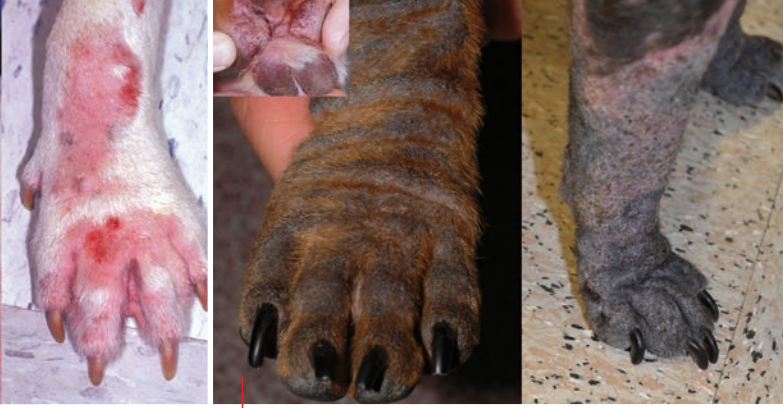

Figure 6. Many dogs with demodicosis develop comedones, with a characteristic gray discoloration.

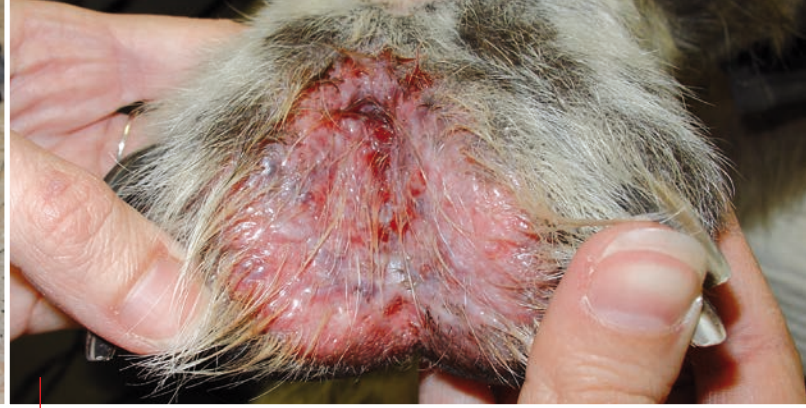
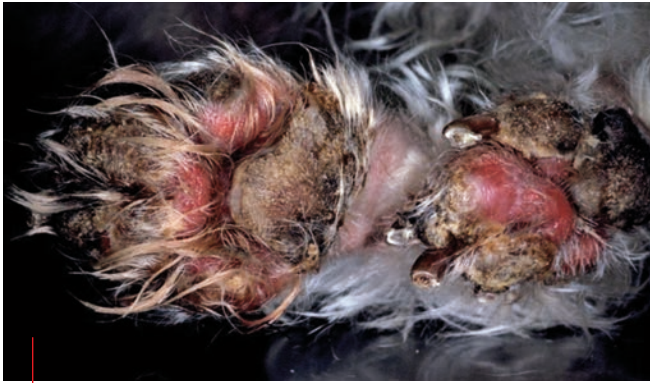
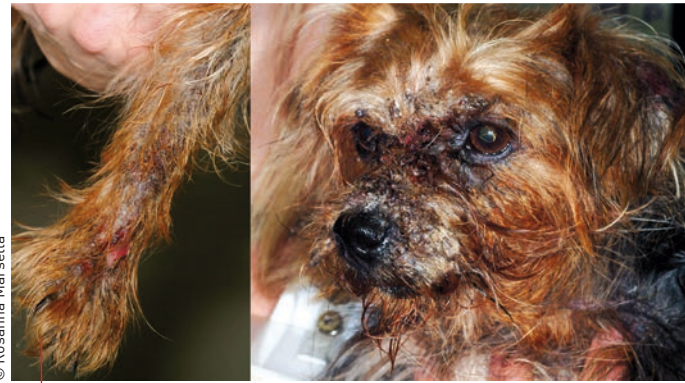Figure 7. Some dogs with demodicosis develop extremely painful interdigital lesions.



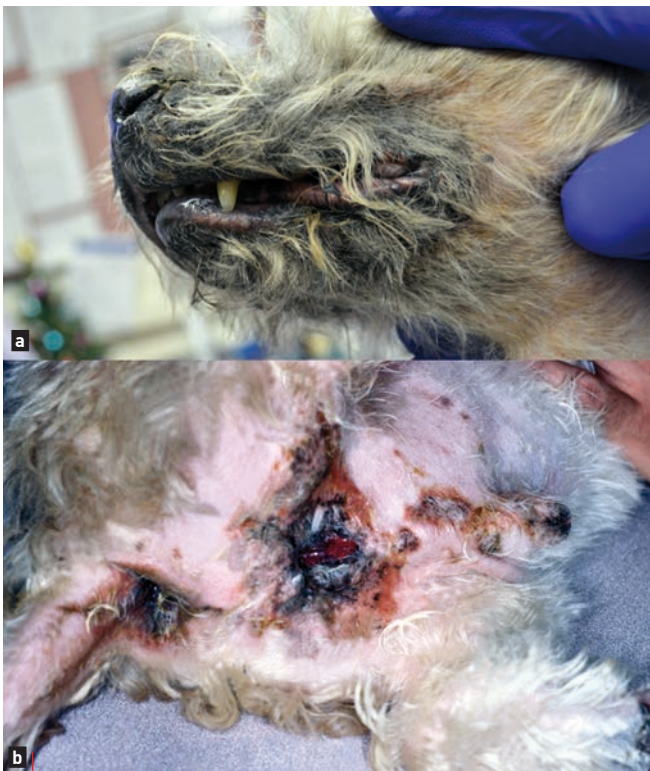© Rosanna Marsella

Figure 8. A dog with superficial necrolytic dermatitis. The footpads in this disease show cracking and fissures rather than dry layers of pustules as in the case of pemphigus.



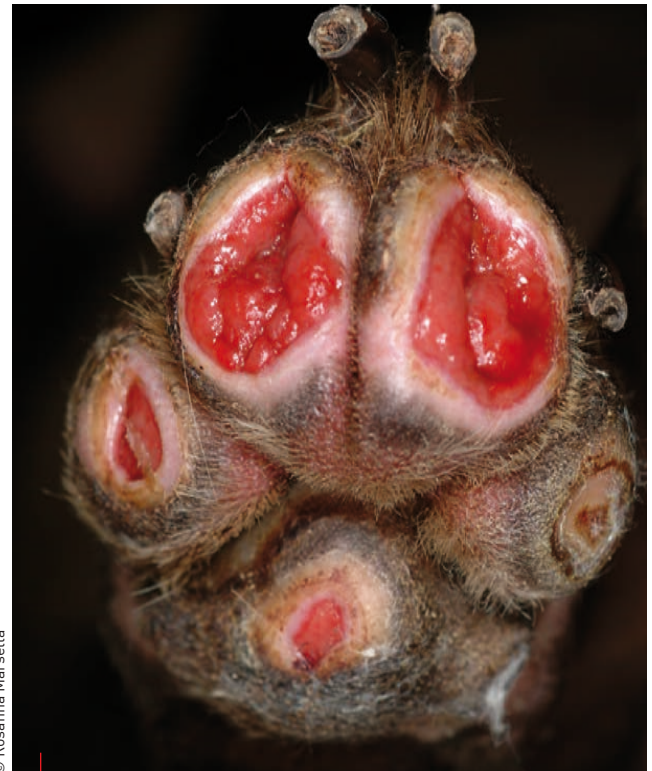© Rosanna Marsella

Figure 10. Some cases of *Trychophyton* infection can develop dramatic lesions which may look very similar to pemphigus foliaceus clinically.



© Rosanna Marsella

Figure 9. Superficial necrolytic dermatitis can also target the commissures of the mouth (a) and the genitalia (b).



© Rosanna Marsella

Figure 11. Vasculitis typically presents on the feet with ulcers in the center of the pads.

on clinical presentation and biopsy of an early lesion. It is important for the clinician to identify and treat (where possible) the underlying cause. Many of these cases require glucocorticoids at immunosuppressive doses in combination with pentoxifylline, and some patients necessitate prolonged treatment to completely extinguish the immunologic response.

Erythema multiforme should also be included in the category of immune-mediated diseases that can cause pododermatitis. This is a clinical syndrome rather than a specific diagnosis, and again the clinician needs to identify the triggering disease in order to be successful with therapy. The classic lesions are erythematous macules with a paler central area (**Figure 12**); they may be found on many areas of the body, including the feet. It is important to take a thorough history of medications and vaccines, keeping in mind that drugs can trigger this type of cutaneous reaction, even if well tolerated previously. Definitive diagnosis is by biopsy, in which individual apoptotic cells are evident. Immunosuppressive treatments are typically prescribed while addressing the triggering cause.



Don't ignore the nails!

Some causes of pododermatitis not only affect the haired skin but also the nails (6). Various changes to the normal nail structure may be noted (**Table 2**). Two classic examples are symmetric lupoid onychodystrophy and dermatophytosis (**Figure 13**). In parts of the world where *Leishmania* is present, this disease should be considered if onychogriphosis (hypertrophy and abnormal claw curvature) is noted. **Table 3** offers a more complete list of diseases that can present with pododermatitis and affected nails.

Symmetric lupoid onychodystrophy has been reported in Labradors, German Shepherds, Rottweilers and Boxers (7) and has some features of lupus, although affected dogs do not have systemic disease. Cases are usually young animals, with sudden-onset nail loss (**Figure 14**) which is associated with variable degrees of pain and

Table 2. Terminology for common abnormalities of the nail.

Onychoclasia	Breaking of the claw
Onychocryptosis	Ingrown claw
Onychodystrophy	Abnormal claw formation
Onychogriphosis	Hypertrophy and abnormal claw curvature
Onychomadesis	Sloughing of the claw
Onychomalacia	Softening of the claw
Onychorrhhexis	Longitudinal striations associated with brittleness and breakage of the claw
Onychoschizia	Splitting and/or lamination of the claw, usually beginning distally
Paronychia	Inflammation of the nail fold

pruritus. Paronychia may be seen. Secondary bacterial infections are common and contribute to the pain and pruritus. The natural course of the disease involves partial re-growth of friable, abnormal nails that continue to be sloughed. Blood work (*i.e.*, complete blood cell count (CBC), chemistry panel and antinuclear antibody (ANA)) is unremarkable, and diagnosis is obtained by amputation of P3 and histopathology. Therapy includes the use of high doses of essential fatty acids or glucocorticoids. Tetracycline and niacinamide have been used as they have immunomodulatory properties, but improvement may not be seen for a couple of months. Pentoxifylline (15-20 mg/kg PO q8H, given with food to minimize GI problems) has been found to help in some cases; the improvement may be due to the multiple immune-modulatory properties of the drug. Secondary infections need to be addressed at the same time. In some cases this disease has been linked to a food reaction, and some dermatologists recommend an elimination trial to rule out the possibility of food as a precipitating factor. Removal of P3 and the claw on affected digits may be necessary in some cases.

Figure 12. The classic lesions of erythema multiforme are erythematous macules with a paler central area; they can affect many areas of the body, including the feet.

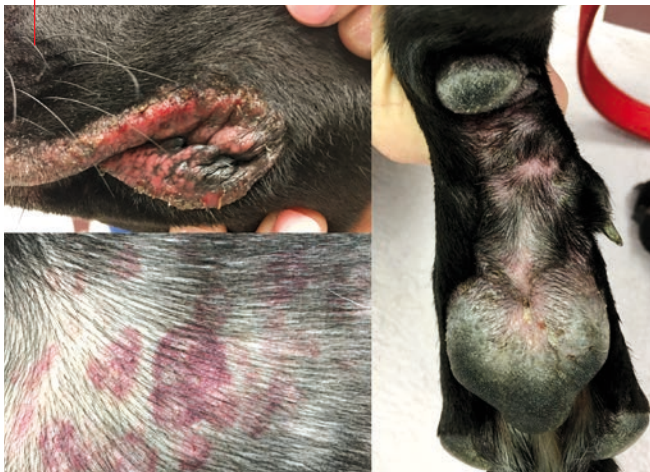

Figure 13. *Microsporium gypseum* infection in two dogs; some cases of dermatophytosis can involve the nails, with secondary pododermatitis.

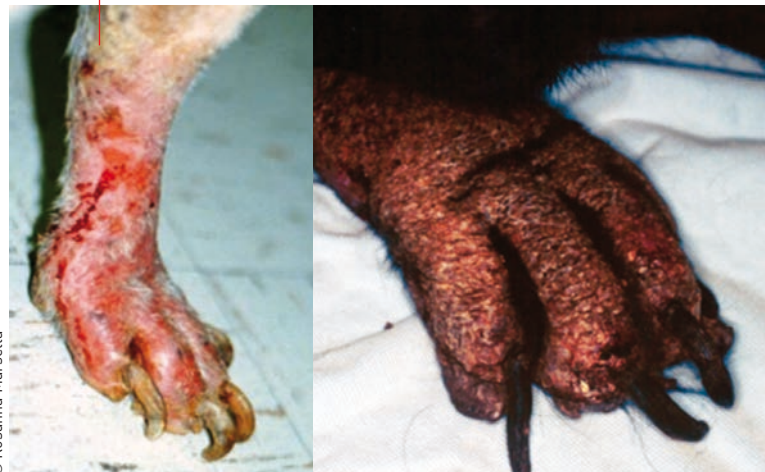
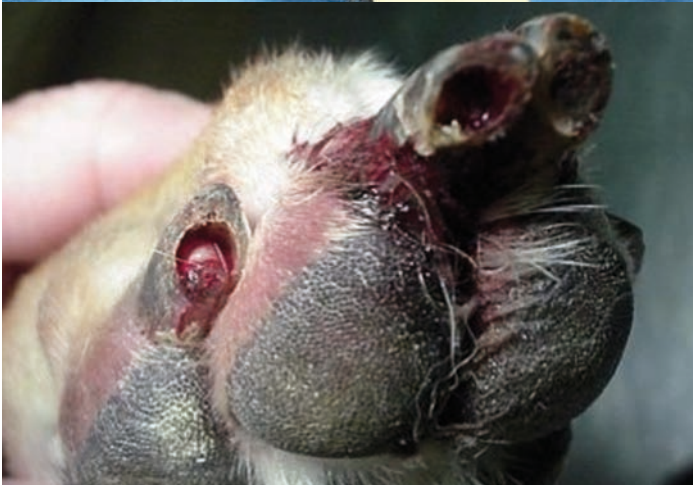
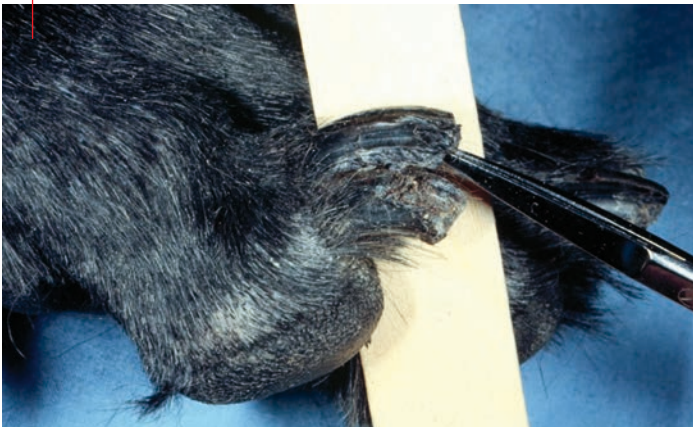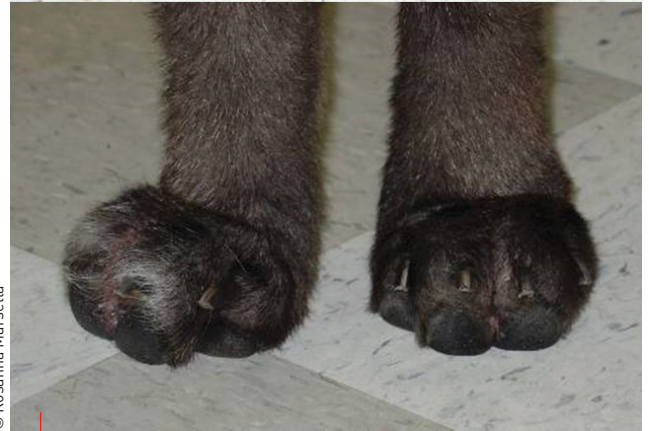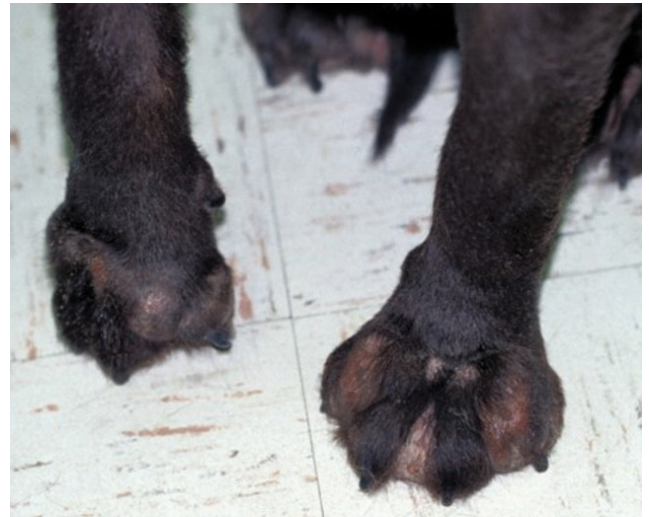Table 3. Differential diagnoses for diseases of the claws.

Symmetrical lesions
<ul style="list-style-type: none"> • Dermatophytosis • Symmetric lupoid onychodystrophy • Inflammation extending to the nail bed <ul style="list-style-type: none"> - bacterial - demodicosis - autoimmune (e.g., pemphigus) - drug eruptions - metabolic diseases (e.g., necrolytic migratory erythema) • Keratinization defects (e.g., primary seborrhea of the Cocker Spaniel) • Congenital and hereditary defects <ul style="list-style-type: none"> - dermatomyositis of Shetland Sheepdogs and Collies - acrodermatitis of Bull Terriers • Nutritional deficiency (e.g., zinc) • Vasculitis • Idiopathic onychomadesis (German Shepherd dogs, Whippets, English Springer Spaniels) • Idiopathic symmetric onychodystrophy (Siberian Husky, Rhodesian Ridgeback, Dachshund) • Leishmaniasis • <i>Malassezia</i>
Asymmetrical lesions
<ul style="list-style-type: none"> • Bacterial – most common; always a secondary issue • Trauma • Neoplasia (e.g., squamous cell carcinoma, melanoma, mast cell tumor, keratoacanthoma, inverted papilloma)

Figure 14. Symmetric lupoid onychodystrophy in young dogs. The abnormal nails are painful and friable, and slough easily.



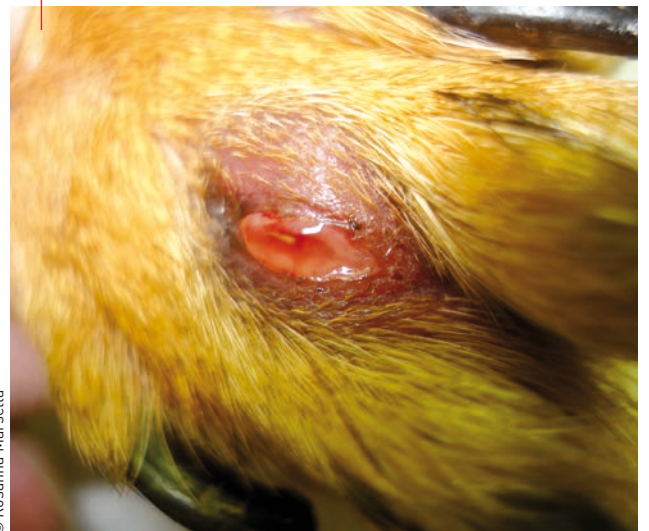© Rosanna Marsella



© Rosanna Marsella

Figure 15. Secondary changes in pododermatitis can involve a severe inflammatory response against bacteria and fragments of hairs, leading to swelling, pain and fibrosis.

Figure 16. Some dogs tend to develop cystic lesions secondary to pododermatitis as the body attempts to wall off foreign material.



© Rosanna Marsella

What about chronic changes and perpetuating causes?

As noted earlier, whatever the primary cause of pododermatitis, scarring and foreign body reaction to free keratin in the dermis can develop due to infection and the destruction of hair follicles (furunculosis). The inflammatory response built against bacteria and fragments of hairs leads to swelling, pain and fibrosis over time (Figure 15). Some dogs tend to develop cystic lesions as the body attempts to wall off foreign material (Figure 16) (8). These nodules are frequently a source of recurrence as they can act as a starting point for new bouts of infection. Short-coated dogs are more prone to this type of reaction; it is believed that the short prickly hair in the interdigital spaces tend to mechanically drive the bacteria into the skin on the opposite side. These cases can be frustrating to treat and often require long courses of oral antibiotics and topical whirlpool therapy with antimicrobial agents like chlorhexidine or benzoyl peroxide. Culture and sensitivity is strongly encouraged in these cases to identify the most effective antibiotic, although clindamycin or fluoroquinolones are usually a good choice, as they achieve excellent penetration into the deep layers of the dermis. Additionally, many cases benefit from glucocorticoids and topical antibiotics such as mupirocin. Glucocorticoids can help decrease the fibrosis and excessive inflammatory response, which sometimes hinders the resolution of the pododermatitis. Soaking with agents that may facilitate the opening and draining of these nodules (e.g., magnesium sulfate) is also beneficial. In severe cases laser surgery (9) or podoplasty may be necessary.

So what's the diagnostic approach?

When considering the numerous causes of pododermatitis, an initial clinical approach should minimally include cytology, deep skin scraping and a fungal culture (Table 4). Cytology can be done with a tape or a swab depending on the condition of the skin. Dry skin is better evaluated with tape impressions, while areas of exudate are suitable for direct impressions or swabs. Samples are easily stained and analyzed for the presence and type of inflammatory infiltrate, the presence of bacteria and yeasts and possibly acantholytic cells. Diagnosis of fungal

infections is made by Dermatophyte Test Medium (DTM) culture of the nails (shavings or clipping taken from the most proximal portions of the nail).

Blood sampling (CBC and biochemistry panel) may be indicated in older dogs, and in particular if SND is a consideration, whilst the decision to biopsy or not will depend on the signalment, clinical signs and history. Bear in mind that some conditions (e.g., autoimmune or immune-mediated disease) will necessitate biopsy for diagnosis, whereas other conditions (e.g., allergic skin disease) cannot be diagnosed by biopsy. Based on the distribution and presence of pruritus, the clinician should then the rank differential diagnoses and formulate a diagnostic plan.

Table 4. The essential aspects to consider when presented with any dog with pododermatitis can be summarized as follows;

Clinical approach to pododermatitis case – First visit

- Treat any secondary infection based on cytology. Bacterial culture may be needed, based on clinical history and prior response to antibiotic.
- Perform deep skin scrapings; if positive, start therapy for *Demodex*; note that negative hair plucks may not completely rule out demodicosis.
- Consider biopsy if necessary.
- Perform fungal culture (DTM of hair, skin and possibly nails, depending on clinical presentation).
- Do blood work (CBC and chemistry panel) if indicated, especially in older dogs and in particular if SND is a consideration.

Clinical approach to pododermatitis case – Recheck visit

- If infection is still present, repeat culture and sensitivity tests.
- If infection is resolved, consider primary lesions and rank differential diagnoses and formulate a diagnostic plan based on distribution and presence of pruritus.
- Remember that some conditions will necessitate biopsy (e.g., autoimmune, immune-mediated) but that allergic skin diseases are not diagnosed by biopsy.
- Consider conducting an elimination diet trial



REFERENCES

1. Marsella R. Contact allergy. In: *Veterinary Allergy* Noli C, Foster A, and Rosenkrantz W (eds), Chichester, Wiley Blackwell 2014;185-190.
2. Vaughan DF, Clay Hodgkin E, Hosgood GL, et al. Clinical and histopathological features of pemphigus foliaceus with and without eosinophilic infiltrates: a retrospective evaluation of 40 dogs. *Vet Dermatol* 2010;21(2):166-174.
3. Duclos D. Canine pododermatitis. *Vet Clin North Am Small Anim Pract* 2013;43(1):57-87.
4. Outerbridge CA. Cutaneous manifestations of internal diseases. *Vet Clin North Am Small Anim Pract* 2013;43(1):135-152.
5. Innerå M. Cutaneous vasculitis in small animals. *Vet Clin North Am Small Anim Pract* 2013;43(1):113-134.
6. Santoro D. An approach to disease of the claws and claw folds. In: *BSAVA Manual of canine and feline dermatology*, 3rd ed. Jackson H, Marsella R (eds); Gloucester, BSAVA 2012;121-125.
7. Mueller RS. Diagnosis and management of canine claw diseases. *Vet Clin North Am Small Anim Pract* 1999;29(6):1357-1371.
8. Duclos DD, Hargis AM, Hanley PW. Pathogenesis of canine interdigital palmar and plantar comedones and follicular cysts, and their response to laser surgery. *Vet Dermatol* 2008;19(3):134-141.
9. Perego R, Proverbio D, Zuccaro A, et al. Low-level laser therapy: case-control study in dogs with sterile pyogranulomatous pododermatitis. *Vet World* 2016;9(8):882-887.



CONCLUSION

The clinical approach to pododermatitis requires good subject knowledge and accurate identification of primary, secondary and perpetuating factors. Omitting basic tests at the initial evaluation can mean common problems are overlooked, and appropriate treatment for secondary infections is essential. Ultimately, since many diseases can look similar, it is crucial to obtain a diagnosis rather than simply attempting to treat the clinical signs.

PEMPHIGUS FOLIACEUS IN FELINE PATIENTS

Most of us do not see pemphigus foliaceus on a daily basis in our feline patients, but we need to know about it; this disease is a challenge in terms of its diagnosis and treatment, and relapse is not uncommon, as the authors explain.

Christoph J. Klinger,

Dr. med. vet. – Small Animal Medicine Clinic, Ludwig Maximilian University, Munich, Germany

Dr. Klinger graduated from Munich in 2011 and worked in small animal practice before undertaking a year-long internship at Ludwig Maximilian University. He then completed an ECVD- and ACVD-approved residency in Munich and was awarded his doctoral thesis in 2016.



Ralf S. Mueller,

Dr. med. vet., MANZCVSc (Canine Medicine), Dipl. ACVD, FANZCVSDc (Dermatology), Dipl. ECVD – Fachtierarzt für Kleintierdermatologie. Small Animal Medicine Clinic, Ludwig Maximilian University, Munich, Germany

After graduating in 1986 Dr. Mueller spent time in both large and small animal practices before undertaking a residency at the University of California, Davis. He was appointed director of the Animal Skin & Allergy Clinic in Melbourne, Australia and then assistant professor at Colorado State University. He is currently Professor and chief of veterinary dermatology at the University of Munich.

KEY POINTS

Pemphigus foliaceus is a rare autoimmune skin disease that can affect many species.

Although clinical symptoms can vary, affected cats typically develop pustules and crusts on the face, inner pinnae and paw pads, along with paronychia.

Definitive diagnosis is based on a combination of clinical history, characteristic lesions and correlating histopathology.

Long-term treatment with immunosuppressive drugs is often required; this can be frustrating due to cost, recurrence of the illness, and possible adverse effects of the medication.

Introduction

Pemphigus foliaceus (PF) is an autoimmune, vesicobullous to pustular skin disease recognized in many species, most notably dogs, cats, horses and humans. Clinical lesions in small animals typically include pustules and crusts, erosions and ulcers, as well as alopecia (Figures 1 and 2) (1). The disease is characterized histologically by acantholysis (the breakdown of desmosomes) and loss of adhesion between keratinocytes (2).

The first report of seven cases of feline PF was published in 1982 (3) and to the best of the authors' knowledge only two papers of a larger case series (>10 cats) have been published since then (4,5). Five forms of pemphigus are recognized in dogs and cats: pemphigus foliaceus, pemphigus erythematous, panepidermal pustular pemphigus, pemphigus vulgaris and paraneoplastic pemphigus (1,6,7). In contrast to humans, who are frequently affected with pemphigus vulgaris (a deep form of pemphigus), PF is the most common form in dogs and cats (1).

Many cases of PF need long-term medical treatment with immunosuppressive drugs. While glucocorticoids are often used in feline patients, only limited and contradictory data for the need for, and choice and efficacy of, alternative medications are available (1,8,9).

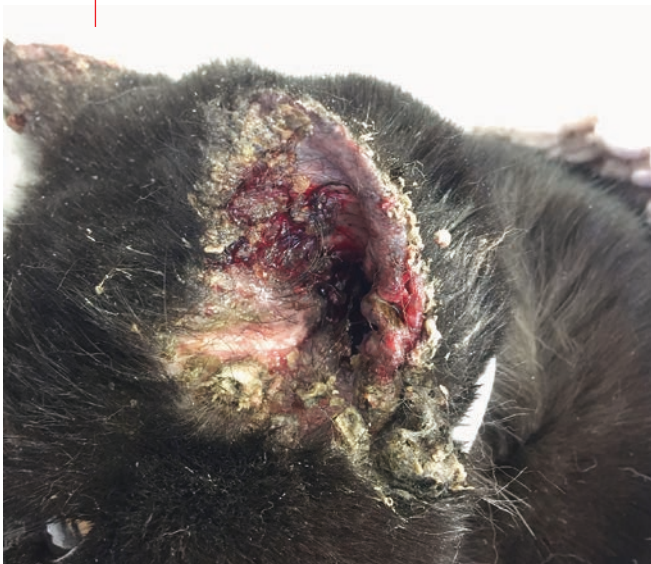●●○ Incidence, prevalence and predispositions

In most cases, the underlying cause for PF cannot be identified (1). The production of autoantibodies against adhesion molecules may result from an abnormal antigen stimulation or an exaggerated immune response (1). While genetic predispositions in humans and dogs exist, no such data has been published in cats. Breed and sex predispositions for feline PF have not been reported but domestic short-haired cats are said to be most commonly affected, and the age at disease onset, although reported to have a median of 5 years, can be highly variable (4,5). One study calculated a prevalence of 0.5% for feline PF over a 10-year period, so the disease seems to be rare in cats (4).

●●● Pathology and possible triggers

Keratinocytes develop structural molecules for either cell-to-cell (desmosomes) or cell-to-matrix adhesion (hemidesmosomes or anchoring fibril complexes). Autoantibodies against these proteins lead to intra- or sub-epidermal splitting with individual acantholytic keratinocytes or rafts of cells (**Figure 3**) and subsequently clinical signs of blistering. Depending on the autoantibody, blisters develop in the superficial or deeper layers of the epidermis. Deep lesions are seen with pemphigus vulgaris (with antibodies directed against desmoglein 1 and desmoglein 3)

Figure 1. A severe form of pemphigus foliaceus on a cat's pinnae.



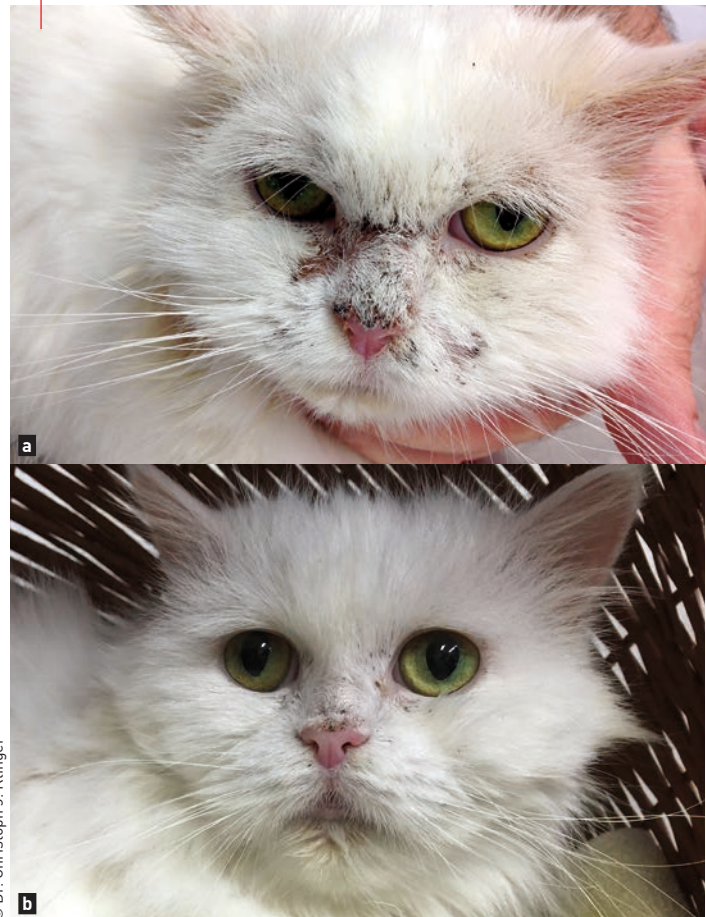© Dr. Christoph J. Klinger

and with paraneoplastic pemphigus (with antibodies against desmoglein 3 and plakins). Superficial variants include pemphigus foliaceus (targeting desmoglein 1 in humans, and desmocollin 1 in dogs) and Ig-A pemphigus (targeting desmocollin 1 and 3) (10).

The exact pathomechanism of acantholysis in feline patients is still unclear (1). Autoantibodies bind one of two members of the cadherin group (responsible for cell-to-cell adhesion), and calcium seems to be a crucial element. This binding leads to an activation of intracellular mechanisms; it is thought that the protease urokinase plasminogen activator converts plasminogen to plasmin, resulting in the destruction of intercellular bridges and acantholysis (1,11,12). Complement has been suggested as a possible co-factor, although symptoms may occur without complement involvement.

Adverse drug reactions and other skin diseases have been reported to be trigger factors for some pemphigus variants in both human and animals (3,11,13). In some regional outbreaks, infectious triggers have been presumed (1). Black flies (in combination with viral diseases and environmental factors) were reported as an insect vector for human PF [*Fogo selvagem*] in South America (14). Another study noted that dogs which later developed PF frequently had a previous history of flea bite

Figure 2. A feline patient with pemphigus foliaceus pre- (a) and 7 days after starting treatment (b).



© Dr. Christoph J. Klinger

hypersensitivity [15], although this should be taken with caution due to the high incidence of flea bite hypersensitivity in dogs within the study area [2]. Case reports of leishmaniasis as a possible trigger for canine PF have also been published [16].

Adverse drug reactions have been suspected as a trigger factor for PF in dogs and cats for a long time [5,17-19] but definitive identification of a medication as a trigger for a specific disease is very hard to achieve, and many authors will use an “adverse drug reaction probability scale” [20]. One review retrospectively applied this scale to published case reports and studies and concluded only a “possible” drug relation in almost all cases [2].

●●●○ Clinical appearance

The primary lesion of PF in domestic animals is a pustule [2]. The pustules are multifocal and rupture shortly after developing, leading to crusty erosions. Pruritus is variable, but (if present) may lead to secondary ulceration [4,21]. Yellowish crusts and erosions on the face, ears, and feet are the main feature of PF in cats (**Figures 1 and 2**) [3,5,22]. These pustules can be large and follicular or non-follicular, and may extend over several hair follicles (which is uncommon for bacterial folliculitis). While lesions in some feline patients are restricted to the head, face (**Figure 2**) and inner pinnae (**Figure 1**), other cats show generalized disease [2]. However severe generalized disease in cats is less commonly seen [2,5]. In some cases PF mainly or exclusively targets the pads or unguis folds [2-5,22]. Affected pads may be scaly or may develop crusts and erosions. Paronychia with a creamy to cheesy exudate is a PF feature unique to cats. Complete alopecia and generalized exfoliative erythroderma have been described with feline PF [9]. Lethargy, anorexia, limb edema or fever are restricted to patients with severe, widespread erosions or ulcers [4].

●●●○ Diagnostic findings

With appropriate history and clinical changes, impression smears should be obtained from intact pustules or areas underneath freshly removed crusts [4,21]. Acantholytic keratinocytes, *i.e.*, clustered, rounded keratinocytes with a dark blue “fried egg” appearance, in combination with intact neutrophils or sometimes eosinophils, are suggestive for PF (**Figure 3**) [4,21] but are not pathognomonic. Acantholytic keratinocytes with neutrophils have also been reported with severe pustular *Trichophyton* dermatophytosis in dogs and horses and severe bacterial pyoderma and leishmaniasis in dogs [16,23,24].

Histopathology in combination with the clinical appearance and history is currently the gold standard to diagnose feline PF. Histopathologically, intraepidermal pustules with active acantholysis and without evidence of infection are consistent with PF (**Figure 4**) [1]. In contrast to bacterial folliculitis, the pustules may be large and extend over multiple hair follicles [2,23]. More chronic lesions show a mild dermatitis reaction with erosive epidermitis and serocellular crusting. Classically, acantholytic keratinocytes are observed as large eosinophilic cells in the serocellular crusting (**Figure 4**).



“The majority of cats with pemphigus foliaceus require immunosuppressive drugs, so a definite diagnosis is necessary prior to commencing treatment.”

Ralf S. Mueller

Direct immunofluorescence of skin biopsies may show a “chicken-wire” pattern of intercellular immunofluorescence (in cats predominantly due to intercellular IgG) [4]. Indirect immunofluorescence for circulating serum IgG autoantibodies has been attempted unsuccessfully in feline PF patients [4]. Affected cats may present with moderate to marked leukocytosis and neutrophilia, mild (non-regenerative) anemia, mild hypoalbuminemia and elevated globulins [1].

●●●○ Treatment and outcome

Initial approach

The majority of cats with PF require immunosuppressive drugs, so a definite diagnosis is necessary prior to commencing treatment [1].

Glucocorticoid monotherapy which downregulates inflammatory cytokines and autoantibodies is often effective [8]; prednisolone (2-5 mg/kg q24H) or triamcinolone (0.6-2 mg/kg q24H) is typically recommended [5,8]. In one large study triamcinolone showed a higher remission rate (15/15 cats) than prednisone (8/13 cats) and less adverse effects [5]. Since oral prednisone is not well-absorbed or metabolized (into prednisolone) in cats, prednisolone should be used in preference. A daily prednisolone dosage of 2 mg/kg q24H led to clinical remission in 37 cats with PF in one study, but other authors reported a lower (35-50%) success rate [1,8,9]. Some cases may respond better to methylprednisolone or dexamethasone [1]. Common glucocorticoid adverse effects in dogs (polyphagia, polyuria, polydipsia, weight gain and behavioral changes) are interestingly less frequent and less prominent in cats [8], although transitional or persistent diabetes mellitus and bacterial skin and bladder infections may be observed [1].

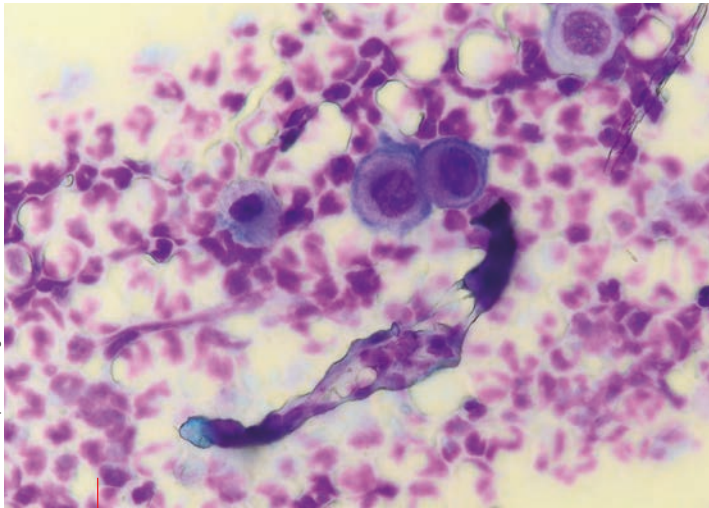


Figure 3. Cytology in feline pemphigus foliaceus; note the rounded (acantholytic) keratinocytes in small clusters (like "fried eggs") surrounded by neutrophils.

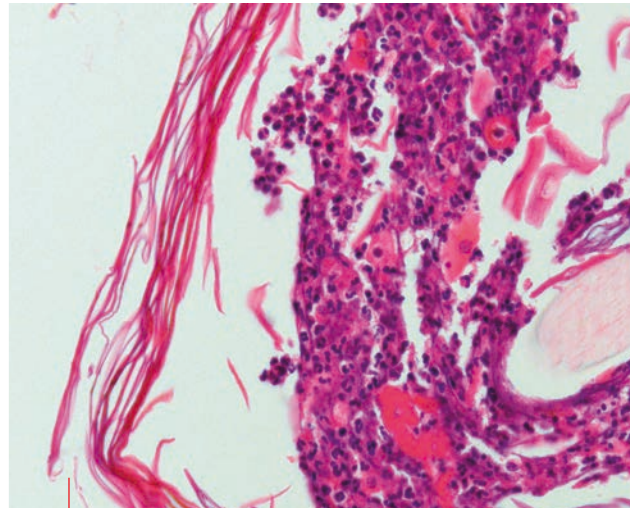


Figure 4. A histopathology section from a cat with pemphigus foliaceus demonstrating multiple acantholytic keratinocytes in an intracorneal neutrophilic pustule.

One study reported 9/11 cats (82%) with PF were treated successfully with a combination of prednisone and chlorambucil (5). Chlorambucil is an alkylating agent which affects cross-linking of DNA, resulting in a down-regulation of T- and B-lymphocytes (1) and is given at 0.1-0.2 mg/kg PO q24-48H. There can be a lag phase (2-4 weeks) before improvement is noted, so it is often combined with systemic glucocorticoids in the early treatment phase (5). Breaking the chlorambucil tablets should be avoided due to the exposure risk for staff and clients (1). Besides gastrointestinal (GI) adverse effects, patients should be monitored for signs of myelosuppression; such monitoring should occur more frequently in the early stages of therapy.

Calcineurin inhibitors, such as ciclosporin, bind to the intracellular immunophilins and thus inhibit cytokines such as interleukin-2 and T-helper and cytotoxic T-cells. Oral ciclosporin is usually administered at 7-8 mg/kg q24H and often initially combined with oral glucocorticoids. In one retrospective study 12 cats were treated with a combination of glucocorticoids and chlorambucil (n=6) or ciclosporin (n=6) (9). All six patients maintained with ciclosporin for PF management were weaned off systemic glucocorticoids and remained in remission, while glucocorticoid therapy could only be discontinued in one of six cats receiving chlorambucil. The most common adverse effects are GI signs. Prior to systemic ciclosporin therapy, a serum antibody titer for *Toxoplasma* should be obtained in free ranging cats or animals fed raw meat, as fatal outcomes have been reported in recently infected cats on ciclosporin therapy (25). A positive toxoplasmosis titer prior to ciclosporin therapy is currently regarded as protective against such events.

Azathioprine, an immunosuppressive agent frequently recommended in canine PF, is often associated with fatalities in cats, even at low doses, and therefore should not be used for feline PF.

Vitamin E at 250 mg q24H or essential fatty acid supplementation are frequently recommended as adjunctive therapy based on anecdotal evidence, although there are no studies published supporting such use.

Relapsing or refractory cases

While most patients respond to at least one of the above-mentioned therapeutic options, conventional therapy is unsuccessful in some patients. Switching the type of glucocorticoid or using an aggressive (three day) intravenous pulse therapy protocol may be beneficial (1). Alternatively, a combination of different immunosuppressive drugs at lower dosage may be attempted (1).

Chrysotherapy (administration of gold salts such as aurothioglucose) has been used in dogs and cats with PF. It is recommended that a small test dose (1 mg IM) of the chosen drug is first tried, before commencing



“Whilst the histological changes for pemphigus foliaceus are well documented, identifying the underlying etiology can be difficult, or impossible in many cases.”

Christoph J. Klinger

weekly injections at 1 mg/kg until remission is achieved. This dose is then administered every 4-6 weeks as a maintenance therapy. A successful response to aurothioglucose in four out of ten cases of feline PF has been reported (the other six cats responded well to prednisolone [4]). Skin eruptions, erythema multiforme and proteinuria are the main adverse effects for patients on gold therapy, and regular monitoring and urinalysis is recommended.

Topical tacrolimus (0.1% ointment) has improved focal lesions of PF in both canine and feline patients. Local erythema and stinging are described as possible adverse reactions of topical calcineurin inhibitors, particularly when applied on ulcerated skin.

Mycophenolate mofetil blocks the *de novo* purine synthesis (especially guanine) and thus selectively inhibits the proliferation of the guanine-dependent B and T lymphocytes, as well as consequently the production of antibodies, with comparably low adverse effects. Studies on its usage in human and veterinary autoimmune diseases show promising results. The current recommended dose for cats is 10 mg/kg q12H. The most frequently reported adverse reactions are GI signs, but there are rare cases of bone marrow suppression with a concurrent increased risk of infection. The potential for renal or hepatic toxicity seems to be relatively low.

In some patients euthanasia may be considered due to limited response to or adverse effects of treatment, or an owner's financial or psychological limitations. In one study, four of 30 cats (13%) were euthanized due to the severity of the disease, treatment failure or adverse effects [5]. An early referral to a veterinary dermatologist after a first treatment failure may result in a better outcome.



CONCLUSION

PF is an uncommon autoimmune, blistering skin disease that occurs in many different species. While the clinical appearance and the underlying etiology can vary, in most feline patients the typical lesions are pustules and crusts on the face, inner pinnae and footpads, as well as paronychia. Diagnosis is based on clinical history, appearance and histopathology. Immunosuppressive treatment is needed in most cases and can be long-term, expensive and frustrating due to relapses, adverse effects, treatment duration and costs.



REFERENCES

1. Rosenkrantz WS. Pemphigus: current therapy. *Vet Dermatol* 2004;15:90-98.
2. Olivry T. A review of autoimmune skin diseases in domestic animals: I - superficial pemphigus. *Vet Dermatol* 2006;17:291-305.
3. Manning T, Scott D, Smith C, et al. Pemphigus diseases in the feline: seven case reports and discussion. *J Am Anim Hosp Assoc* 1982;18:433-443.
4. Scott D, Walton D, Slater M, et al. Immune-mediated dermatoses in domestic animals - 10 years after. *Comp Cont Educ Pract Vet* 1987;9:539-554.
5. Preziosi DE, Goldschmidt MH, Greek JS, et al. Feline pemphigus foliaceus: a retrospective analysis of 57 cases. *Vet Dermatol* 2003;14:313-321.
6. Suter M, Bruin Ad, Wyder M, et al. Autoimmune diseases of domestic animals: an update. In: Kwochka, KK (ed). *Advances in Veterinary Dermatology III*. Boston: Butterworth-Heinemann, 1998:321-337.
7. Robinson ND, Hashimoto T, Amagai M, et al. The new pemphigus variants. *J Am Acad Dermatol* 1999;40:649-671.
8. Simpson DL, Burton GG. Use of prednisolone as monotherapy in the treatment of feline pemphigus foliaceus: a retrospective study of 37 cats. *Vet Dermatol* 2013;24:598-601.
9. Irwin KE, Beale KM, Fadok VA. Use of modified ciclosporin in the management of feline pemphigus foliaceus: a retrospective analysis. *Vet Dermatol* 2012;23:403-409.
10. Bizikova P, Dean GA, Hashimoto T, et al. Cloning and establishment of canine desmocollin-1 as a major autoantigen in canine pemphigus foliaceus. *Vet Immunol Immunopathol* 2012;149:197-207.
11. Stanley JR. Pemphigus. In: Wolff K, Goldsmith LA, et al. (eds) *Fitzpatrick's Dermatology in General Medicine*. New York: McGraw-Hill; 1999:654-665.
12. Suter M, Ziegler C, Cayatte S, et al. Identification of canine pemphigus antigens. In: Ihrke PJ, Mason IS, White SD (eds). *Advances in Veterinary Dermatology* 1993;367-380.
13. Iwasaki T, Maeda Y. The effect of ultraviolet (UV) on the severity of canine pemphigus erythematosus. In *Proceedings*. 13th Annual Members Meeting AAVD & ACVD 1997;86.
14. Aoki V, Millikan RC, Rivitti EA, et al. Environmental risk factors in endemic pemphigus foliaceus (*Fogo selvagem*). *J Invest Dermatol Symp Proc* 2004;9:34-40.
15. Pascal A, Shiebert J, Ihrke P. Seasonality and environmental risk factors for pemphigus foliaceus in animals: a retrospective study of 83 cases presented to the Veterinary Medical Teaching Hospital, University of California Davis from 1976 to 1994. In *Proceedings*. 11th Annual Members Meeting AAVD & ACVD 1995:24-25.
16. Ginel P, Mozos E, Fernandez A, et al. Canine pemphigus foliaceus associated with leishmaniasis. *Vet Rec* 1993;133(21):526-527.
17. Mason K, Day M. A pemphigus foliaceus-like eruption associated with the use of ampicillin in a cat. *Aust Vet J* 1987;64:223-224.
18. McEwan N, McNeil P, Kirkham D, et al. Drug eruption in a cat resembling pemphigus foliaceus. *J Small Anim Pract* 1987;28:713-720.
19. Noli C, Koeman J, Willemse T. A retrospective evaluation of adverse reactions to trimethoprim-sulphonamide combinations in dogs and cats. *Vet Quart* 1995;17:123-128.
20. Naranjo CA, Busto U, Sellers EM, et al. A method for estimating the probability of adverse drug reactions. *Clin Pharm Therapeut* 1981;30:239-245.
21. Mueller RS, Krebs I, Power HT, et al. Pemphigus foliaceus in 91 dogs. *J Am Anim Hosp Assoc* 2006;42:189-196.
22. Caciolo P, Nesbitt G, Hurvitz A. Pemphigus foliaceus in 8 cats and results of induction therapy using azathioprine. *J Am Anim Hosp Assoc* 1984;20:571-577.
23. Kuhl K, Shofer F, Goldschmidt M. Comparative histopathology of pemphigus foliaceus and superficial folliculitis in the dog. *Vet Pathol* 1994;31:19-27.
24. Scott DW. Marked acantholysis associated with dermatophytosis due to *Trichophyton equinum* in two horses. *Vet Dermatol* 1994;5:105-110.
25. Barrs V, Martin P, Beatty J. Antemortem diagnosis and treatment of toxoplasmosis in two cats on cyclosporin therapy. *Aust Vet J* 2006;84:30-35.

ANTI-INFLAMMATORY AND ANTI-PRURITIC THERAPY IN CANINE ATOPY

Successful management of atopic dermatitis often requires sustained therapy to prevent recurrence of the clinical signs and to minimize long-term changes to the skin; this paper offers a brief overview of the current options available.

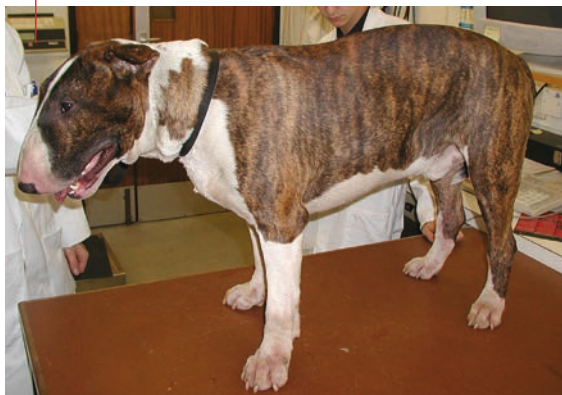●○○ Introduction

Treatment of canine atopic dermatitis (AD) involves two phases. The initial control of the inflammation and pruritus must be followed by ongoing proactive management to maintain remission and prevent chronic changes. Anti-inflammatory and anti-pruritic options with good evidence of high efficacy include topical and systemic glucocorticoids, ciclosporin, oclacitinib and lokivetmab, and clinical judgement is required to select the optimal treatment for each dog (**Figure 1**).

Topical and systemic glucocorticoids have potent, broad-spectrum and rapid activity against most cells, tissues and mediators involved in inflammation, and are ideal for initial control of inflammation and pruritus. It is generally safe to use short- and long-term topical steroids, particularly with the more reliable and well-tolerated products (e.g., hydrocortisone aceponate) and/or local treatment of the eyes, ears and feet. There is a greater risk of adverse effects with long-term systemic treatment.

Ciclosporin mainly targets lymphocytes; it therefore has potent and broad-spectrum anti-inflammatory activity, but resolution of lesions and pruritus will be

Figure 1. Early atopic dermatitis in an English Bull Terrier. This dog is pruritic but has few skin lesions apart from erythema. It should respond very well to glucocorticoids, oclacitinib or lokivetmab.

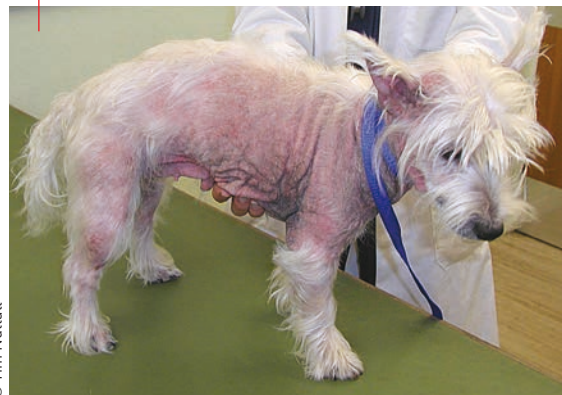

© Tim Nuttall

slower than with other agents. More rapid remission can be achieved by initially combining ciclosporin with glucocorticoids, oclacitinib or lokivetmab. However, long-term combination treatment with broad-spectrum anti-inflammatory drugs should be avoided because of the risk of immunosuppression.

Oclacitinib is a Janus Kinase (JAK) 1 inhibitor that particularly blocks activity of IL-31, a key cytokine involved in pruritus and acute inflammation. Treatment every 12 hours results in very rapid control of pruritus, although this may recur when dogs are switched to once-daily therapy. Dogs should be carefully monitored for bacterial, fungal or parasitic infections and any non-selective effects (anemia, neutropenia, raised liver enzymes, elevated bile acids and weight gain). There are also reports of viral papillomas with neoplastic

Figure 2. Severe chronic atopic dermatitis in a West Highland White Terrier with extensive inflammation, secondary infections, otitis and pododermatitis. Broad-spectrum agents such as glucocorticoids and ciclosporin would be more appropriate in managing the range of this dog's problems, as oclacitinib and lokivetmab may reduce the pruritus but mask ongoing inflammation and infection. These drugs would be more appropriate once the initial inflammation and infection are controlled.



© Tim Nuttall

Debbie Gow,

BVM&S, VN, PhD, MRCVS – Royal (Dick) School of Veterinary Studies, University of Edinburgh, UK

Dr. Gow graduated in 2007 from The Royal (Dick) School of Veterinary Studies in Edinburgh and completed a year's rotating small animal internship at Glasgow Vet School. She received her PhD in immunology in 2013 and is currently working towards her European Diploma in Veterinary Dermatology.



Tim Nuttall,

BSc, BVSc, CertVD, PhD, CBiol, MSB, MRCVS – Royal (Dick) School of Veterinary Studies, University of Edinburgh, UK

Dr. Nuttall qualified in 1992 and is an RCVS Specialist in Veterinary Dermatology. He is currently Head of Dermatology at the Royal (Dick) School of Veterinary Studies where he runs a busy referral dermatology clinic with particular interests in atopic dermatitis, otitis, antibiotic resistance and laser surgery.

transformation to squamous cell carcinoma *in situ* (Bowen's disease) and/or invasive squamous cell carcinoma.

Lokivetmab is a caninized monoclonal anti IL-31 antibody that specifically binds to and neutralizes circulating IL-31. It is fast acting and well tolerated, with little to no interaction with other medications or vaccines. Long-term safety is unknown but it is likely to be very good. Lokivetmab is administered by injection and is ideal for dogs that are hard to medicate orally and/or have concurrent conditions and treatments that preclude other medication. It offers rapid relief from pruritus and can also be combined with broad-spectrum agents.

●●○ Broad and narrow spectrum therapy

Since AD is a lifelong disease that needs proactive treatment to maintain remission and prevent flares,

most cases will require appropriate combination therapy. Regular and careful monitoring is always required. **Table 1** summarizes the main points for each class of drug.

Glucocorticoids and ciclosporin are true broad-spectrum agents effective in chronic and acute inflammation (**Figure 2**). This also balances the skin microenvironment, preventing staphylococcal and *Malassezia* overgrowth and infection. However, the broad-spectrum activity may cause other problems.

Oclacitinib is best regarded as semi-broad spectrum; it is most effective against pruritus and acute inflammation, and less useful with chronic inflammation (especially of the feet and ears). It has less impact on the skin microenvironment and the reduction in pruritus may mask ongoing inflammation and infection (especially otitis and pododermatitis). The same is true of the narrow-spectrum agent lokivetmab. These drugs may be more specific, effective and safer, but often need to be combined with local therapy to manage ongoing inflammation and prevent infection.

Table 1. A comparison of effective anti-inflammatory agents for atopic dermatitis.

	Topical glucocorticoids	Systemic glucocorticoids	Ciclosporin	Oclacitinib	Lokivetmab
Spectrum	Broad	Broad	Broad	Semi-broad	Narrow
Cost	Cheap	Very cheap	Moderate to expensive	Moderate	Moderate
Onset	Rapid	Very rapid	Slow (2-3 weeks)	Very rapid	Very rapid
Acute inflammation	Effective	Effective	Less effective	Effective	Effective
Chronic inflammation	Effective	Effective	Effective	Less effective	Less effective
Otitis & pododermatitis	Effective	Effective	Effective	Less effective	Less effective
Acute adverse effects	Rare	Common ¹	Common ²	Common to uncommon ³	Rare
Long-term safety	Moderate to good ⁴	Poor	Good	Unknown	Unknown
Monitoring	Clinical checks	Clinical checks, urinalysis & blood pressure	Clinical checks & urinalysis	Clinical checks, CBC, biochemistry & urinalysis ⁵	Clinical checks
Combine with broad-spectrum agents?	Yes ⁶	Short term	Short term	Short term	Yes ⁷

¹Polyuria, polydipsia & polyphagia; panting and altered behaviour may be seen, but gastrointestinal (GI) ulceration is rare at 0.5-1.0 mg/kg/day.

²Mild and transient anorexia, vomiting and diarrhoea; persistent GI upsets are uncommon.

³Mild GI upsets are most frequent; uncommon reported adverse effects include aggression, weight gain, altered red and white blood cells counts, and increased liver enzymes & bile acids.

⁴Long-term adverse effects are uncommon with hydrocortisone aceponate but are more frequent with other topical glucocorticoids.

⁵The authors have noted an increased incidence of UTIs in dogs on oclacitinib and recommend performing urinalysis.

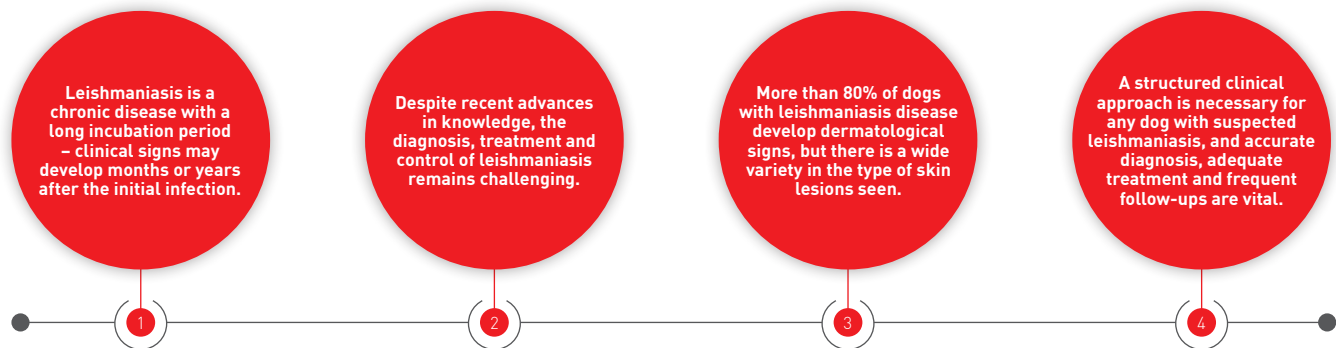
⁶Topical glucocorticoids are used with a wide variety of other anti-inflammatory agents, but formal data are lacking.

⁷Formal data are lacking but there are not likely to be any problems with concurrent drug administration.

DERMATOLOGICAL FEATURES OF CANINE LEISHMANIASIS

Both cutaneous and visceral forms of leishmaniasis can occur in regions of the world where the insect vector is endemic; this paper reviews the dermatological forms of the disease, with a focus on clinical signs and potential treatment options.

KEY POINTS



● ○ ○ ○ Introduction

Leishmaniasis is a frequent and important infectious disease of dogs living in or coming from endemic areas. The causative agent is a single-celled parasite of the *Leishmania* genus, *L. infantum*, which is transmitted by phlebotomine sand flies in the Mediterranean area, although vertical transmissions of the parasite from pregnant bitches to their offspring and directly through blood transfusions have also been documented [1,3]. Within endemic areas transmission of *Leishmania* occurs focally, so broad variations in the prevalence of infection may be seen in contiguous territories, depending mainly on the relative vector densities [1-3]. This paper provides essential general information for a clinician faced with a case of canine leishmaniasis, with specific focus on managing the different dermatological pictures seen with the disease.

● ● ○ ○ Infection and disease

Canine leishmaniasis is a classic example of an illness where the clinical signs can vary widely, from asymptomatic to severe clinical disease; this variation is intrinsically related to the interaction between the

parasite, the arthropod vector and the canine immune system [1,3].

In canine leishmaniasis the immune response from T-helper CD4+ lymphocytes plays a pivotal role in tipping the balance from infection to disease. If the response is dominated by an exaggerated humoral (Th2) reaction, together with no or minimal cell-mediated (Th1) response, dogs generally develop a chronic, progressive disease, although it usually takes several weeks or months before signs become apparent following infection. By contrast, if the immune response is characterized by little or no Th2 reaction and a robust Th1-specific response against *Leishmania*, affected dogs are usually clinically healthy or have a mild, self-limiting form of the disease.

The spectrum of clinical presentation can vary widely, from infection with no obvious clinical findings but detectable laboratory abnormalities, to overt infection characterized by moderate or severe clinical signs (and laboratory abnormalities) that may require hospitalization. Additionally, both clinical and laboratory findings can be identical to many other infectious, immune-mediated, endocrine or neoplastic diseases. The most common clinical signs of canine

Laura Ordeix,

DVM, MSc, Dipl. ECVD – Hospital Clínic Veterinari, Universitat Autònoma de Barcelona (UAB), Spain

Dr. Ordeix is associate professor and head of the dermatology division at the Universitat Autònoma de Barcelona. Board-certified since 2002, she has authored many articles and book chapters on various aspects of dermatology. Her current research focuses on canine leishmaniasis.



Xavier Roura,

DVM, PhD, Dipl. ECVIM-CA – Hospital Clínic Veterinari, Universitat Autònoma de Barcelona (UAB), Spain

Dr. Roura received his DVM from UAB in 1989 then pursued an internship at the same establishment. He has worked as a clinical instructor at UAB since 1992 but has also been visiting veterinarian at various US establishments over the years. He has a major interest in vector-borne diseases in dogs and cats, and was awarded his PhD for work on canine leishmaniasis.

leishmaniasis are enlargement of the lymph nodes and skin lesions. However, a broad and heterogeneous spectrum of signs may be detected on physical examination, including pale mucous membranes, weight loss or cachexia, polyuria/polydipsia, epistaxis, onychogryphosis, ocular lesions, lameness, lethargy, and fever. Significant laboratory findings can include thrombocytopenia, mild to moderate non-regenerative anemia, hyperproteinemia with hyperglobulinemia and hypoalbuminemia, and proteinuria.

Atypical forms of the disease have also been described, with gastrointestinal, neurological, musculoskeletal, cardiopulmonary, lower urinary tract or genital tract signs (1,3).

●●● Dermatological disease



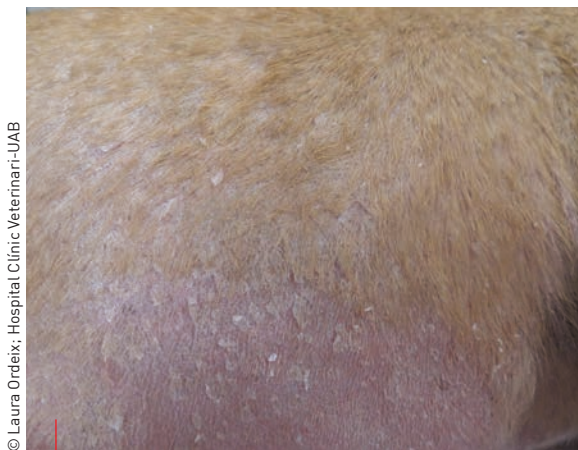Dermatological signs are the most common clinical presentation of canine leishmaniasis; around 81-89 % of affected dogs will present with skin lesions (4) and in some cases they are the only clinical manifestation of the disease. Such lesions may be divided into typical (common and/or characteristic of the disease) or atypical (less common and/or more similar to lesions caused by other diseases) (5).

Typical lesions

Exfoliative dermatitis is considered to be the most common dermatological presentation. Typical lesions are whitish, rather sticky scales initially localized on the face and ears. Facial scales often distribute symmetrically around eyes (“butterfly sign”) and on the dorsum of the nose. As the disease progresses, lesions affect the trunk and extremities. Exfoliative dermatitis is usually non-pruritic and the skin may be partially ulcerated under the scales (**Figure 1**) (5,6).

Ulcerative dermatitis on bony prominences is the second most common dermatological presentation, with the carpal and tarsal regions most usually affected. Lesions are typically indolent, persistent ulcers, usually with elevated borders (**Figure 2**). It is hypothesized that persistent pressure causes secondary inflammation leading to the formation of an ulcer in an infected dog (5).

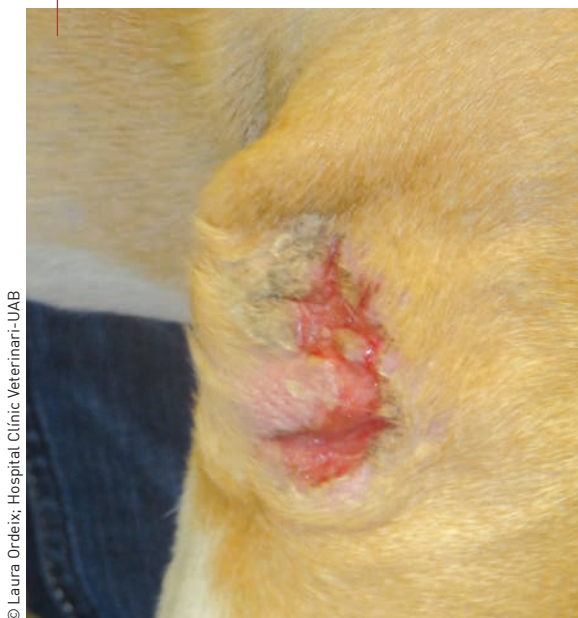Onychogryphosis is classically characterized by excessive growth and abnormal curvature of the nails



© Laura Ordeix, Hospital Clínic Veterinari-UAB

Figure 1. Exfoliative dermatitis, with white, relatively adherent scales, is considered to be the most common dermatological presentation of leishmaniasis.

Figure 2. Ulcerative dermatitis is usually found on bony prominences; lesions are typically persistent indolent ulcers with elevated borders.



© Laura Ordeix, Hospital Clínic Veterinari-UAB

THREE CLINICAL CASES ILLUSTRATING FREQUENT ASPECTS OF CUTANEOUS LEISHMANIASIS

The main objectives when treating dogs with leishmaniasis are to reduce the parasite load, treat any organ damage, and restore an effective immune response. Once stabilized, it is important to keep the dog healthy and treat any clinical relapse. The therapeutic options should be considered in light of the different clinical forms and stages of the disease; the case studies demonstrate typical treatment regimes for the main dermatological clinical presentations seen with canine leishmaniasis.

Case 1

Signalment

Boxer, spayed female, 1.5 years of age

Clinical signs

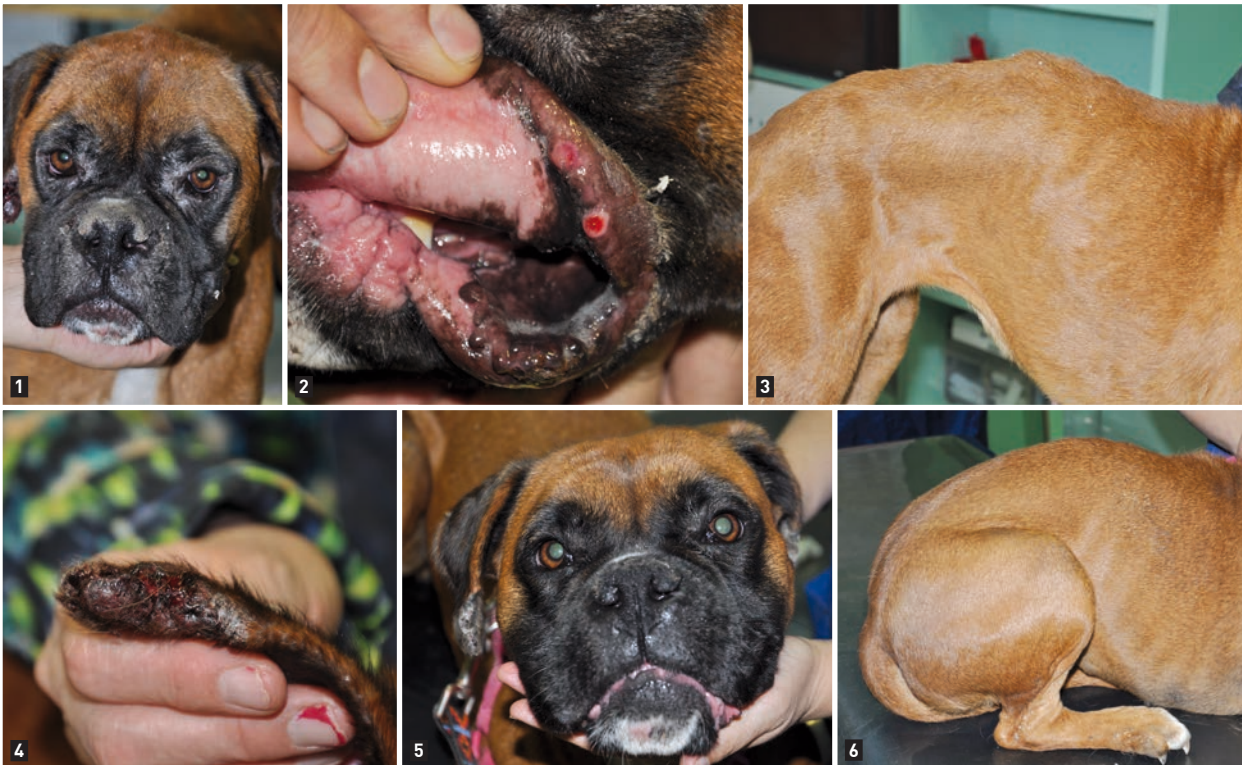General physical examination: weight loss with moderate but generalized lymphadenopathy. Skin lesions included exfoliative dermatitis with underlying ulceration on the face and the extremities (**Figure 1**); papular dermatitis on the inner pinnae and lips (**Figure 2**); nodular dermatitis on the trunk (**Figure 3**) and ulcerative dermatitis on the ear margins (**Figure 4**).

Diagnosis

Cytology on the papules, nodules and ulcers was positive for amastigotes. Moderate non-regenerative anemia, hypoalbuminemia, hypergammaglobulinemia. UPC ratio = 0.51; high positive ELISA

Treatment

Meglumine antimoniate for 4 weeks and allopurinol for one year (at the recommended dose) with follow-up at 30, 180 and 365 days after diagnosis. At Day 30 the lesions were in partial remission (**Figures 5 and 6**), no new signs were noted, and serology was medium positive. At one year follow-up the dog was clinically healthy and serology was still medium positive.



© Laura Ordex; Hospital Clínic Veterinari-UAB

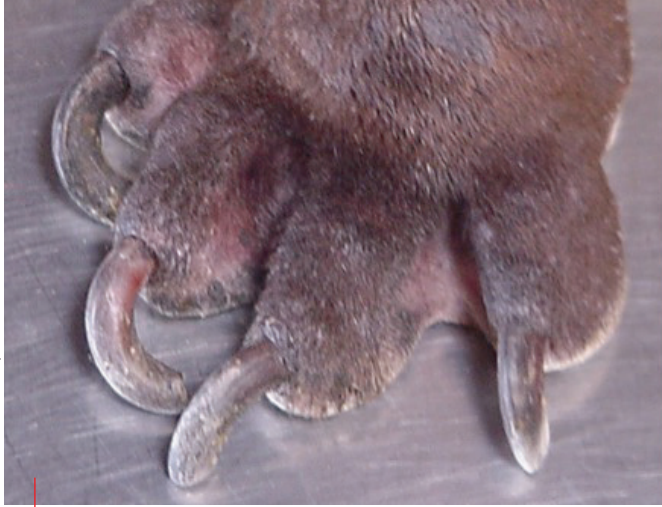

Figure 3. Onychogryphosis may (rarely) be the only clinical sign of leishmaniasis.

(**Figure 3**) (7). The prevalence of this sign varies widely (24-90% of cases) and may rarely be the only clinical sign; however, most dogs with leishmaniasis also have other skin lesions.

Persistent papular dermatitis may be a very common finding in endemic regions, but the exact prevalence is unknown (5). It has been suggested to be indicative of a protective immune response (8,9). Lesions start as a raised papule, probably at the site of inoculation in a less haired area such as inner pinnae, eyelids, dorsum of the nose, lips and caudal abdomen. The papules enlarge and can coalesce to form small plaques. A crust develops centrally, covering an ulcer with a raised edge and variable surrounding induration (**Figure 4**).

Atypical lesions

Ulcerative dermatitis can have various presentations. One possibility is ulceration of the nasal planum (**Figure 5**) which, when diffuse or located on the dorsum of the nose, can be indistinguishable from discoid lupus erythematosus (which is the main differential diagnosis, both clinically and histologically (10)). Erosive, ulcerative lesions at mucocutaneous junctions can also be seen; all junctions may be affected. Signs have also been described at sites of previous cutaneous injury (11,12). Finally, ulcerative dermatitis can also develop due to cutaneous vasculitis



“Dermatological signs are the most common presentation of canine leishmaniasis. In some cases they are the only clinical manifestation of the disease.”

Laura Ordeix

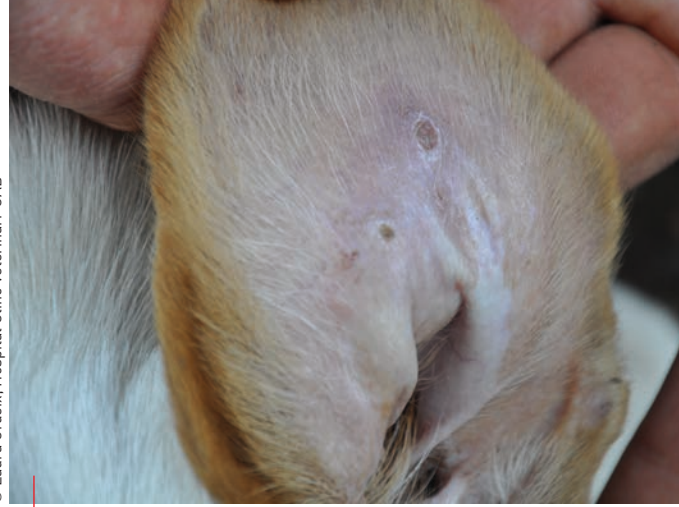

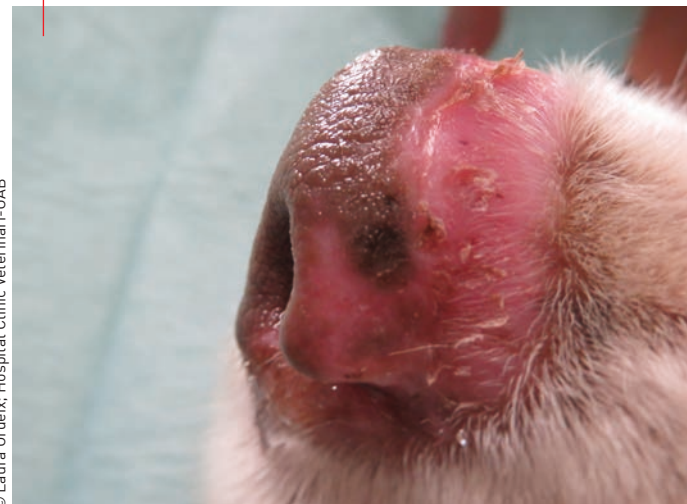Figure 4. Papular dermatitis may be a very common finding in leishmaniasis-endemic regions, but the exact prevalence is unknown. Lesions are often found on less haired areas such as the inner pinna.

from deposition of immunocomplexes; in this case, ulcers are located at distal extremities, such as tips of the pinnae, tail, digits and pads (5).

Muco-cutaneous nodular dermatitis is a relatively uncommon clinical presentation (2-17% of cases) described more frequently in Boxers. Clinically, these are single or multiple nodules of variable size (1-10 cm), usually located on the head, thorax and extremities. They are covered by hair and sometimes ulcerate. Lesions have been reported at mucocutaneous and mucosal junctions such as the mouth or genitalia (**Figure 6**) (5).

Pustular dermatitis is a clinical form described uncommonly in affected dogs, but if present is frequently generalized. Pustules are related to erythematous papules and epidermal collarettes, and are distributed symmetrically over the entire body surface. Pruritus is variable, but is often present and intense (5). It has been suggested that leishmaniasis is a risk factor for the development of an immune-mediated neutrophilic pustular dermatitis in dogs which is unresponsive to antibiotics (13,14).

Figure 5. Ulcerative dermatitis of the nasal planum can be diffuse and may mimic discoid lupus erythematosus.



Case 2

Signalment

Cross-bred, male, 5 months of age

Clinical signs

Papular dermatitis (lesions < 1 cm and with a central ulcer and/or crust) on the inner pinnae, eyelids, bridge of the nose and lips (**Figures 1-3**).

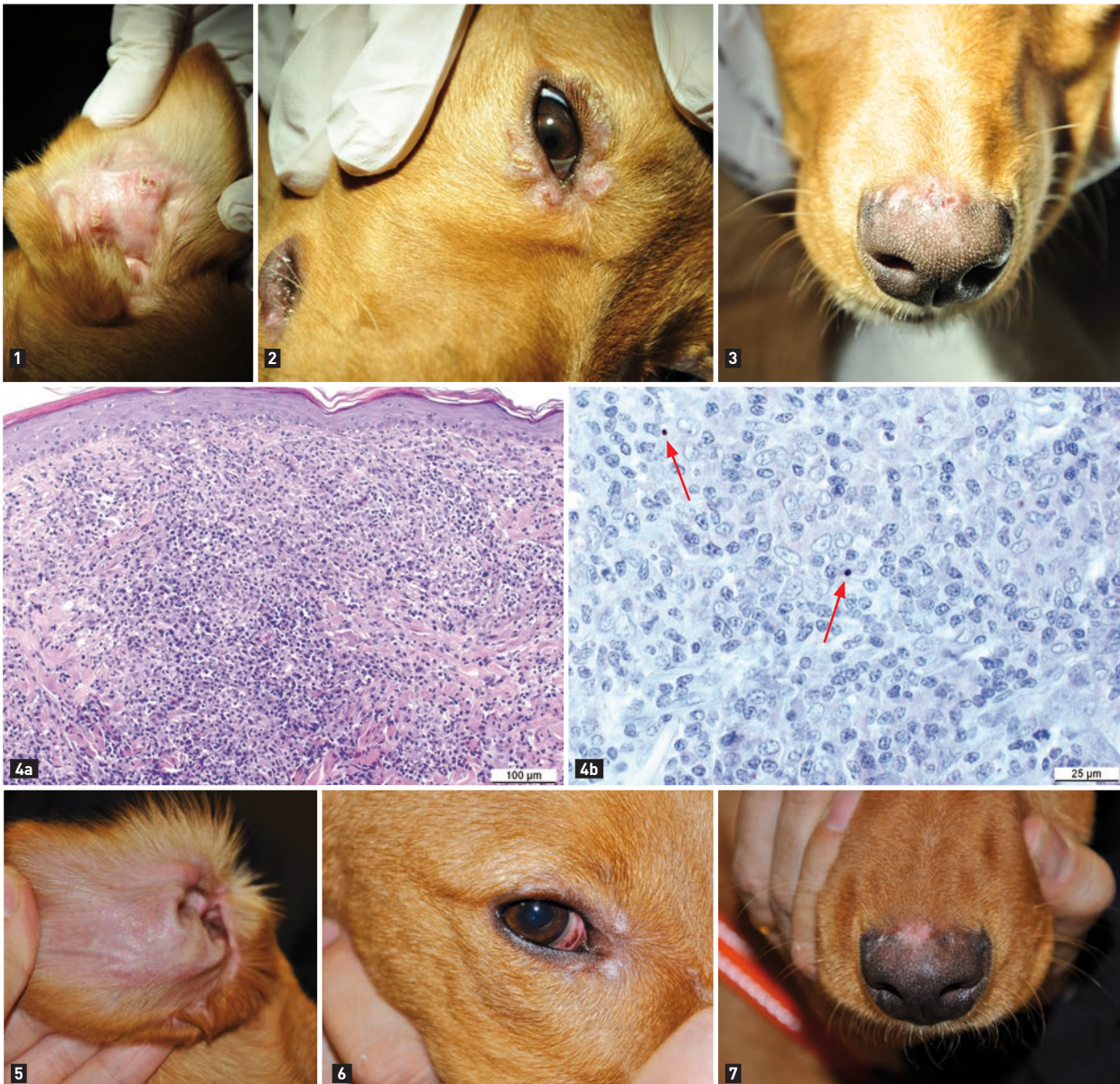
Diagnosis

Cytology revealed macrophagic inflammation with some neutrophils and extracellular cocci. Nodular to diffuse pyogranulomatous inflammation on skin biopsies with positive *Leishmania*-specific immunohistochemistry

(**Figures 4a and b**). Mild hypergammaglobulinemia; UPC ratio = 0.2; low positive ELISA.

Treatment

The prognosis for this clinical picture is good, although the optimal treatment regime is debatable; some cases recover without any treatment. Monotherapy with meglumine antimoniate for 4 weeks was chosen, with follow-up as for case 1. It is important to emphasize that a dog should return for specific anti-*Leishmania* treatment if there is a poor response to therapy. At Day 30, lesions were in remission (**Figures 5-7**), no new signs were noted, and serology was negative. The findings were the same at one-year follow-up.



© Laura Ordeix; Hospital Clínic Veterinari-UAB

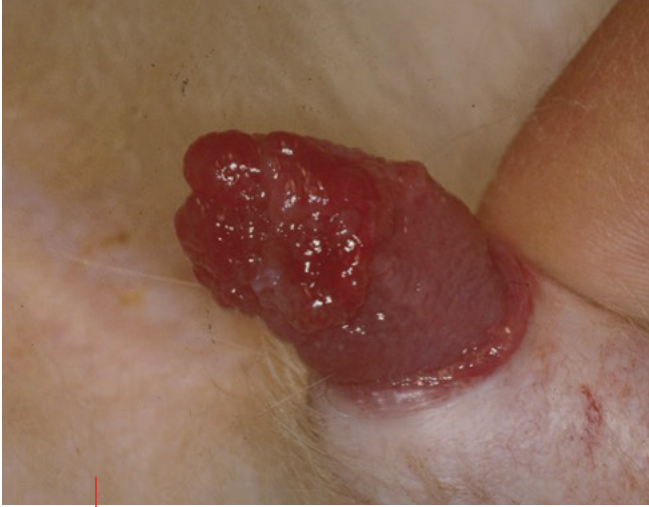

Figure 6. Mucocutaneous nodular lesions at the tip of the penis.

Multifocal alopecia is rarely seen in canine leishmaniasis and is a consequence of an ischemic dermatopathy. As with ulcerative dermatitis due to vasculitis, it has been suggested that the cutaneous vascular damage is due to secondary deposition of immune complexes (5).

Naso-digital hyperkeratosis is atypical and often associated with other clinical manifestations of leishmaniasis, both typical and atypical. Greyish, thick and dry scales characterize the lesions. These are strongly adhered to the underlying skin and are sometimes accompanied by deep fissures, which can be painful, especially on the pads (5).



Diagnosis and staging

Since diagnosis of canine leishmaniasis is complex, an integrated approach is required, and should consider signalment, history, clinical findings, and laboratory tests to detect the parasite (via cytology, histopathology or PCR) or to evaluate the immune response of the host via qualitative or quantitative serology (15,16).

In most cases, and especially with typical lesions, demonstration of intralesional parasites can be sufficient to confirm the causal role of *Leishmania*. Skin cytology (**Figure 7**) or determination of parasitic DNA by PCR are the most practical ways to identify the parasite (5,17). However, demonstration of intralesional parasites in atypical lesions may be insufficient to confirm the causal role of *Leishmania*, especially in an endemic region, since infected dogs may have another concomitant disease (18) and it may be necessary to determine a favorable response to anti-*Leishmania* treatment in order to confirm that the parasite is responsible for the clinical signs.

It is essential to determine if clinical signs are due to *Leishmania* infection, or if illness is due to another disease. Dogs in the first category require specific leishmaniasis treatment irrespective of the disease severity (1,15), and must be staged for the disease, as this will determine the duration of treatment, the use of ancillary therapies, and the prognosis (1,3,15,16). Differentiation can be aided by the clinical classification developed by the Canine Leishmaniasis Working Group (CLWG) or Leishvet group*. Dogs in the second category do not require specific leishmaniasis treatment.

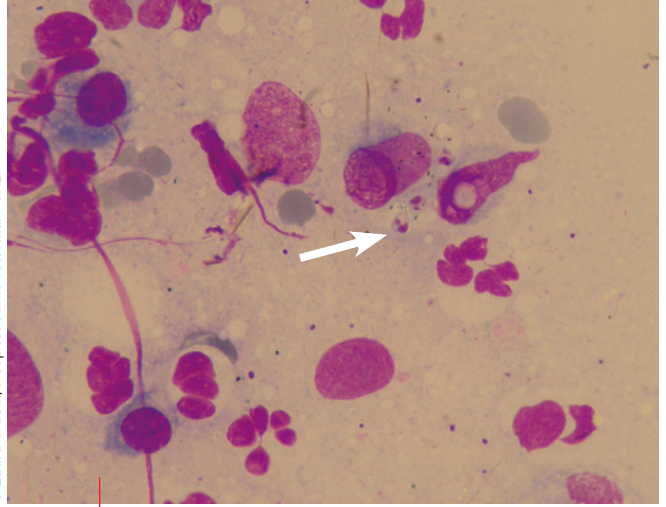


Figure 7. Intralesional *Leishmania* parasites (arrowed) can be demonstrated by cytology.



Treatment

All known drugs against *Leishmania* for dogs can lead to temporary or permanent remission of clinical signs, but complete elimination of the parasite is rare. Because of this, the aims of treatment are to induce a general reduction in the parasite load, to treat organ damage caused by the parasite, to restore an efficient immune response, to maintain clinical improvement once achieved, and to treat any relapse (19,20).

Therapeutic options and choice of drug regimens for sick dogs should be considered in light of the different clinical forms and stages of the disease, as exemplified by the case studies within this paper. The most widely used protocol is a combination of meglumine antimoniate (50 mg/kg SC q12H or 100 mg/kg q24H for at least 4 weeks) and allopurinol (10 mg/kg PO q12-24H for at least 12 months); this is suitable for all dogs with clinical patent leishmaniasis. An alternative is miltefosine (2 mg/kg PO q24H for 28 days) administered in combination with allopurinol (at the above dose) (19-21).

If treatment with meglumine or miltefosine is not possible, allopurinol can be administered alone at the above dosage for at least 12 months (19,20,22). Recent

* www.gruppoleishmania.org or www.leishvet.org.



“The diagnosis of canine leishmaniasis is complex and an integrated approach, which considers signalment, history, clinical findings and laboratory test results, is required.”

Case 3

Signalment

Boxer, neutered male, 4 years of age

Clinical signs

Generalized papulo-pustular dermatitis on the inner pinnae, head, trunk and extremities (**Figures 1-4**) and naso-digital hyperkeratosis (**Figure 5**).

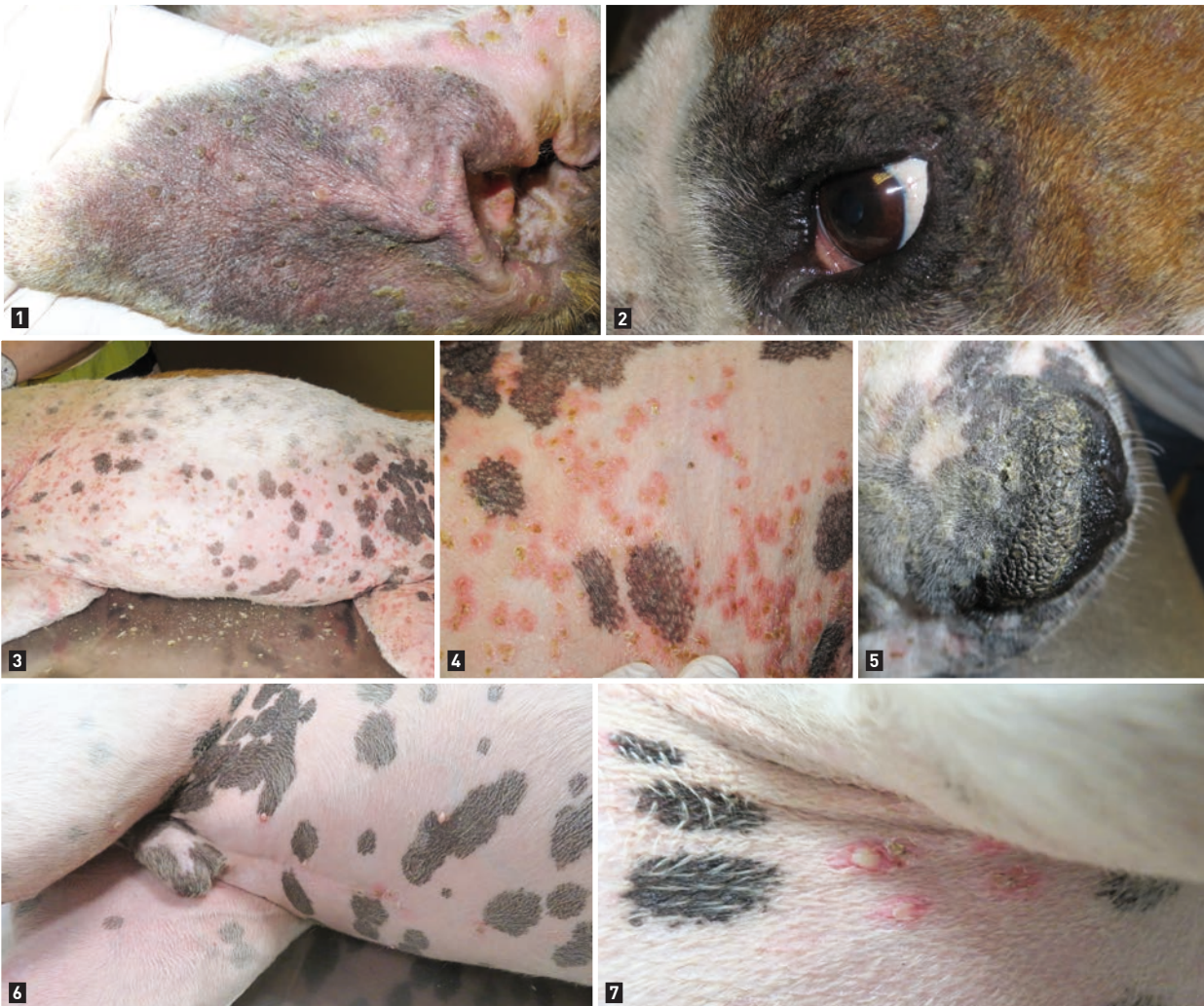Diagnosis

Cytology revealed neutrophilic inflammation with few extracellular cocci and acantholytic cells. Bacteriological culture and sensitivity tests yielded coagulase negative *Staphylococcus* spp. sensitive to various antibiotics. Moderate non-regenerative anemia, neutrophilic leukocytosis, hypoalbuminemia, marked hypergammaglobulinemia. UPC ratio = 1.3. High positive ELISA.

Treatment

The recommended treatment was as for case 1, along with doxycycline (10 mg/kg PO q24h) based on the results of the antibacterial sensitivity test. A week later the dog presented with apathy, anorexia, painful joints, fever and reluctance to walk, and the skin lesions had not improved despite

treatment. Blood and urine tests were repeated but were unchanged. Skin biopsies revealed a subcorneal neutrophilic dermatitis with acantholysis; specific immunohistochemistry was positive for *Leishmania*. The diagnosis was generalized and pruritic non-antibiotic responsive pustular dermatitis. Prednisone (1 mg/kg PO q12H) was prescribed for the presumed concomitant immune-mediated diseases (*i.e.*, dermatitis, glomerulonephritis and polyarthritis) and clinical improvement was noted a week later, and although intact pustules were still visible, pruritus had improved. At day 30, skin lesions were in partial remission and pruritus was absent; the UPC ratio had dropped to 0.9 with mild hypergammaglobulinemia. Antibiotic was then stopped and meglumine antimoniate, allopurinol and prednisone were continued. At day 60, papulo-pustular dermatitis had improved by 80% and pruritus was absent. Meglumine was then withdrawn, allopurinol maintained and the dose of prednisone was progressively reduced (25% reduction every 21 days). By day 90 there was only a mild pustular dermatitis with epidermal collarettes on the ventral abdomen (attributable to superficial pyoderma based on cytology) (**Figures 6 and 7**). There were no clinico-pathological abnormalities and the UPC ratio was 0.4. At 180 days post-diagnosis there was a total resolution of clinical signs.



research has centered around using immunotherapy methodologies alongside conventional treatment for canine leishmaniasis, but more work is required [20].

but as yet it is uncertain that this approach increases the degree of protection compared to a single strategy [20,24,25].

Prognosis

In the majority of dogs with mild or moderate clinical stages, correct application of a therapeutic protocol should result in a clinical cure. In addition, treatment should produce a considerable decrease in parasite load for a prolonged period of time, which is necessary for reducing transmission of the parasite to sand flies. For dogs with a severe form of the disease, the above protocols offer a good chance of improvement, but may not result in a clinical cure. In this situation, particular if severe chronic renal disease is present, any ancillary treatment and the prognosis will be determined by the clinical signs [3,23].

Prevention

Preventive measures against *Leishmania* infection are essential in all dogs living in or visiting areas where the parasite is endemic. To date, two strategies have been shown to be effective and are becoming more commonly used [20,24,25]:

1. prevention of infection by avoiding sand fly bites by regular use of a topical pyrethroid insecticide repellent; this is thought to be an effective tool in protecting dogs and also reduces the risk of human infection.
2. prevention of disease development after infection by vaccination and/or oral treatment with domperidone; this appears to be a good option to protect dogs when challenged by *Leishmania*.

However there is no guarantee that disease can be avoided totally. The preventive efficacy of pyrethroids is between 84–98% in individual dogs and close to 100% at population-level, whilst the preventive efficacy of vaccination is ~ 70% in individual dogs, and 80% using domperidone. Prevention strategies may be combined,

CONCLUSION

Leishmaniasis can cause a wide variety of clinical signs in dogs, and active infection can be debilitating in many patients. Identifying the disease can be problematic, and the clinician should adopt a structured approach to potential cases to ensure accurate diagnosis and staging of the disease. Treatment is usually long-term and requires frequent follow-up; recurrence of clinical signs is not uncommon as it is rare for the parasite to be eliminated completely. Because the dermatological signs can vary widely, the veterinarian should invariably consider leishmaniasis a possible diagnosis if a dog from an endemic area is presented with skin lesions.



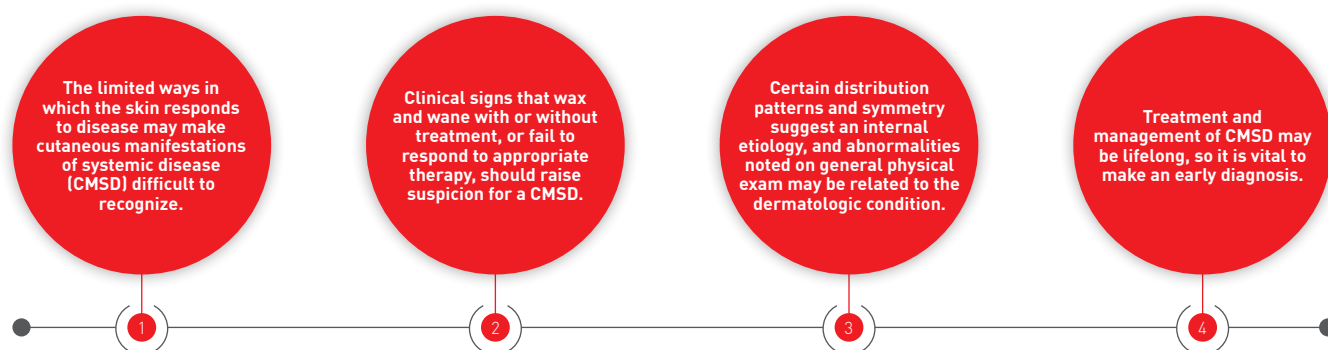
REFERENCES

1. Paltrinieri S, Solano-Gallego L, Fondati A, et al. Canine Leishmaniasis Working Group, Italian Society of Veterinarians of Companion Animals. Guidelines for diagnosis and clinical classification of leishmaniasis in dogs. *J Am Vet Med Assoc* 2010;236:1184-1191.
2. Silvestrini P, Batchelor D, Allenspach K, et al. Clinical leishmaniasis in dogs living in the UK. *J Small Anim Pract* 2016;57:453-458.
3. Solano-Gallego L, Miró G, Koutinas A, et al. LeishVet guidelines for the practical management of canine leishmaniasis. *Parasit Vectors* 2011;4:86.
4. Solano-Gallego L, Koutinas A, Miro G, et al. Directions for the diagnosis, clinical staging, treatment and prevention of canine leishmaniasis. *Vet Parasitol* 2009;165:1-18.
5. Ordeix L, Fondati A. Manifestaciones clínicas cutáneas. In: Solano-Gallego L (ed). *Leishmaniasis canina. Una revisión actualizada*. Zaragoza: Servet; 2013;69-95.
6. Saridomichelakis MN, Koutinas AF. Cutaneous involvement in canine leishmaniasis due to *Leishmania infantum* (syn. *L. chagasi*). *Vet Dermatol* 2014;25:61-71.
7. Koutinas AF, Carlotti DN, Koutinas C, et al. Claw histopathology and parasitic load in natural cases of canine leishmaniasis associated with *Leishmania infantum*. *Vet Dermatol* 2010;21:572-577.
8. Ordeix L, Solano-Gallego L, Fondevila D, et al. Papular dermatitis due to *Leishmania* spp. infection in dogs with parasite-specific cellular immune responses. *Vet Dermatol* 2005;16, 187-191.
9. Bottero E, Poggi M, Viglione M. Lesioni papulari indotte da *Leishmania* spp. in 8 cani giovani. *Veterinaria* 2006;20;33-36.
10. De Lucia M, Mezzalana G, Bardagi M, et al. A retrospective study comparing histopathological and immunopathological features of nasal planum dermatitis in 20 dogs with discoid lupus erythematosus or leishmaniasis. *Vet Dermatol* 2017;28:200-e46.
11. Wortmann GW, Aronson NE, Miller RS, et al. Cutaneous leishmaniasis following local trauma: a clinical pearl. *Clin Infect Dis* 2000;31;199-201.
12. Prats N, Ferrer L. A possible mechanism in the pathogenesis of cutaneous lesions in canine leishmaniasis. *Vet Rec* 1995;137;103-104.
13. Bardagi M. Canine leishmaniasis: the challenge of histopathological diagnosis. In: *Proceedings, ISVD pre-congress day, 7th World Congress of Veterinary Dermatology*. Vancouver 2012;22-30.
14. Colombo S, Abramo F, Borio S, et al. Pustular dermatitis in dogs affected by leishmaniasis: 22 cases. *Vet Dermatol* 2016;27:9-e4.
15. Paltrinieri S, Gradoni L, Roura X, et al. Laboratory tests for diagnosing and monitoring canine leishmaniasis. *Vet Clin Pathol* 2016;45:552-578.
16. Solano-Gallego L, Cardoso L, Pennisi MG, et al. Diagnostic challenges in the era of canine *Leishmania infantum* vaccines. *Trends Parasitol* 2017;33:706-717.
17. Lima T, Montserrat-Sangrà S, Martínez L, et al. Leishmania quantitative polymerase chain reaction from stained cytologies – a new method for diagnosis of canine cutaneous lesions. In: *Proceedings, 29th ESVD-ECVD Annual Congress, Lausanne 2017; in press*.
18. Solano-Gallego L, Fernández-Bellón H, Morell P, et al. Histological and immunohistochemical study of clinically normal skin of *Leishmania infantum*-infected dogs. *J Comp Pathol* 2004;130:7-12.
19. Oliva G, Roura X, Crotti A, et al. Guidelines for treatment of leishmaniasis in dogs. *J Am Vet Med Assoc* 2010;236:1192-1198.
20. Reguera RM, Morán M, Pérez-Pertejo Y, et al. Current status on prevention and treatment of canine leishmaniasis. *Vet Parasitol* 2016;227: 98-114.
21. Pierantozzi M, Roura X, Paltrinieri S, et al. Variation of proteinuria in dogs with leishmaniasis treated with meglumine antimoniate and allopurinol: a retrospective study. *J Am Anim Hosp Assoc* 2013;49:231-236.
22. Maroli M, Torres M, Pastor J, et al. Adverse urinary effects of allopurinol in dogs with leishmaniasis. *J Small Anim Pract* 2016;57:299-304.
23. Roura X, Fondati A, Lubas G, et al. Prognosis and monitoring of leishmaniasis in dogs: a working group report. *Vet J* 2013;198:43-47.
24. Gradoni L, Oliva G, Castagnaro M, et al. Guidelines for prevention of leishmaniasis in dogs. *J Am Vet Med Assoc* 2010;236:1200-1206.
25. Miró G, Petersen C, Cardoso L, et al. Novel areas for prevention and control of canine leishmaniasis. *Trends Parasitol* 2017;33:718-730.

CUTANEOUS MANIFESTATIONS OF SYSTEMIC DISEASE

Common diseases are seen commonly – but we must not forget that rare diseases can occur too. Here Patricia White describes some of the systemic diseases that can present with dermatologic signs, and offers some pointers for a diagnostic approach.

KEY POINTS



Introduction

It is common to treat dermatologic signs in veterinary practice without identifying a clear cause. Typically a clinician may take a brief history, perform a physical exam, treat any secondary infection, and make a tentative diagnosis. Because the skin has a limited number of ways of responding to injury, this approach may miss the opportunity to diagnose the rare cutaneous manifestations of systemic disease (CMSD).

Although unusual, CMSD can resemble many commonly seen skin problems, so obtaining a thorough history and interpreting clinical findings in light of this information is vital. A complete history includes: age of onset and duration; all medications, topical therapies and nutritional supplements (for both pet and owner); diet quality and composition (to check for potential deficiencies, homeopathic supplements); concurrent diseases/conditions and their treatment; exposure to pets in the household and other animals (daycare/boarding/travel); presence of pruritus; response to specific therapy and any evidence of other organ systems involved.

Routine bench diagnostic tests (skin scraping, fur pluck, tape prep, impression smear, dermatophyte culture) should be done in every patient to identify microbial overgrowth or demodicosis, and to get a handle on basic supportive care needs. Recognizing dermatologic changes that are markers for specific internal conditions allows the clinician to choose specific tests to obtain a definitive diagnosis, and it is at this point that successful treatment for these rare conditions begins. This article presents a brief overview of just a few systemic diseases that announce their presence with dermatologic clues.

Paraneoplastic disorders

Paraneoplastic skin disorders occur as a result of a neoplasm elsewhere in the body; the cancer itself is not in the skin (1). The cause of the associated skin lesion(s) is generally unknown but may be the result of immune-mediated activity, the impact of a tumor protein on the skin, or the development of enzymes that interfere with normal skin function. These patients may have vague signs of illness (lethargy, weight loss, inappetence, vomiting, diarrhea) but the skin changes announce the systemic abnormality.

Patricia D. White,

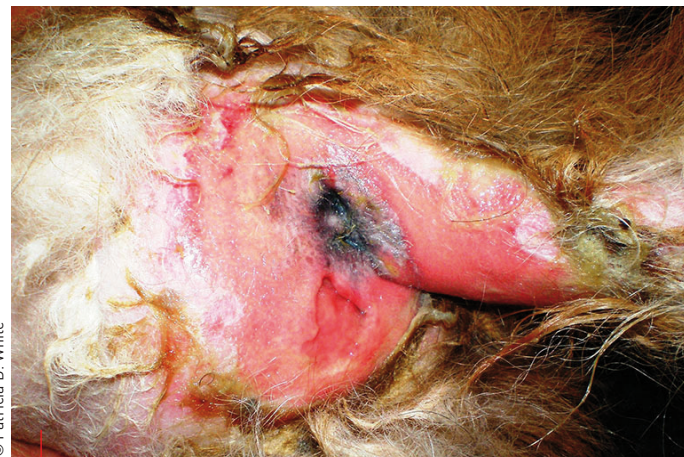DVM, MS, Dipl. ACVD – Atlanta Veterinary Skin & Allergy Clinic, Georgia, USA

Dr. White earned her DVM degree from Tuskegee University's Veterinary School. After completing a dermatology residency, Master's degree and post-doctorate fellowship at The Ohio State University, she opened a specialist dermatology clinic in her hometown of Atlanta. Her clinical areas of interest include ear disease and creative management of atopic dermatitis.



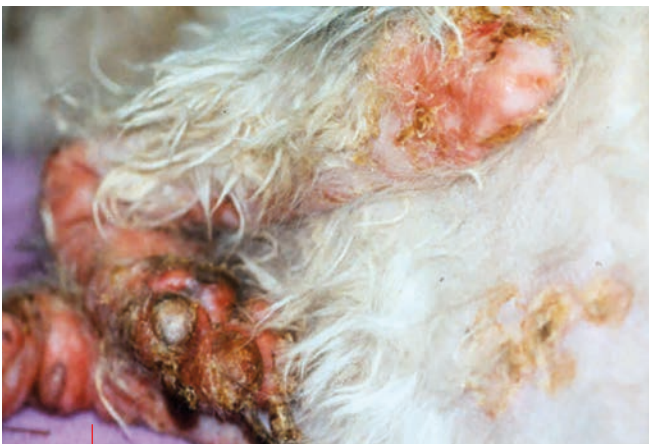Superficial necrolytic dermatitis (SND, or Hepatocutaneous Syndrome, Necrolytic Migratory Erythema (NME), Metabolic Epidermal Necrosis), is a rare and often fatal condition in older (> 10 years) dogs of either sex and smaller breeds (2-5) and very rarely in cats (6,7). A common presentation is of constant paw licking or difficulty walking. The clinical history includes acute onset of lethargy and lameness, inappetence, polyuria/polydipsia (PUPD), cutaneous pain and pruritus, and weight loss. Skin lesions are often dramatic; ulceration and depigmentation at the mucocutaneous junctions, and erythemic, exudative crusting over points of wear including elbows and hocks, axillae and groin, and footpads showing marked hyperkeratosis) (**Figures 1-3**). Secondary bacterial and yeast infections are common. The cutaneous lesions are markers for advanced hepatic disease or pancreatic neoplasia, and may precede clinical signs of the primary disease by weeks or months. In humans, SND is most often associated with a glucagonoma, but this is rare in dogs. A history of potentially hepatotoxic drug therapy (ketoconazole, rifampin, phenobarbital, etc.) may indicate a possible cause, but more often the etiology remains unknown (2-5). Differential diagnoses in dogs include pemphigus foliaceus (PF), systemic lupus erythematosus (SLE),

drug eruption, zinc responsive dermatitis, cutaneous lymphosarcoma / mycosis fungoides (CLSA/ MF), and leishmaniasis. In cats the rule outs include PF, SLE, exfoliative dermatitis, feline paraneoplastic alopecia, and Cushing's/acquired skin fragility syndrome.



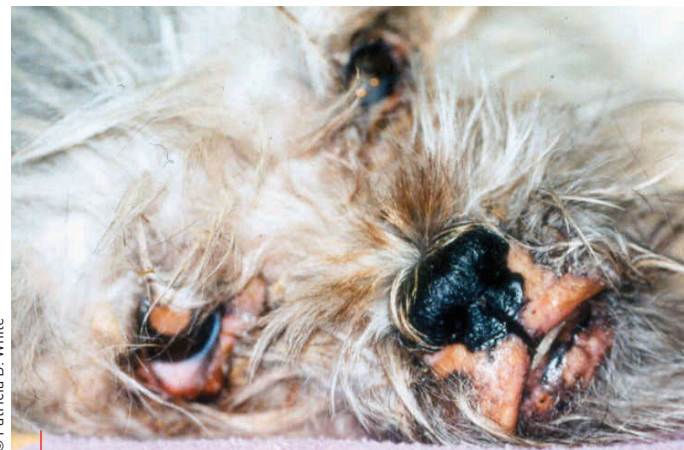
© Patricia D. White

Figure 2. SND with marked perianal erosion and ulceration of the skin.



© Patricia D. White

Figure 1. Superficial necrolytic dermatitis (SND) in a dog. Note the marked erythroderma, crusting and painful ulceration of the elbows and footpads.



© Patricia D. White

Figure 3. Depigmentation, crusting and erosion at the oral, nasal and ocular mucocutaneous junctions due to SND.

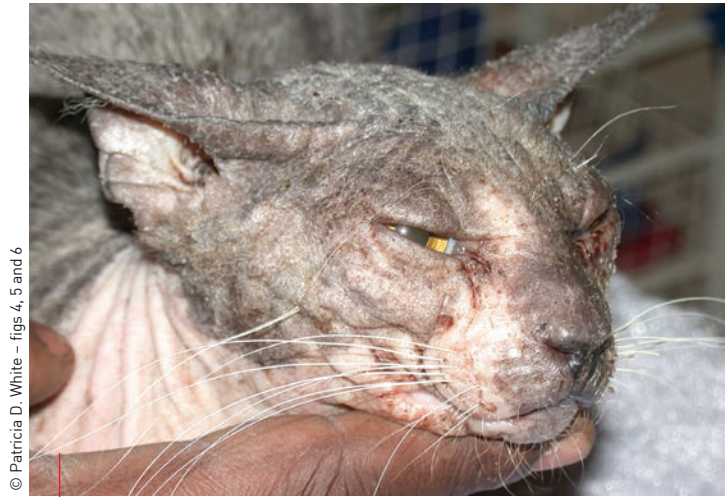Routine blood tests will often demonstrate hypoalbuminemia, normocytic normochromic non-regenerative anemia, hyperglycemia, glycosuria, elevated alkaline phosphatase and ALT, and increased total bilirubin and bile acids. Hypoaminoacidemia is a consistent finding, regardless of the primary diagnosis, and is thought to be responsible for the dermatological signs (2-7). Hepatic abdominal ultrasound may show a "honeycomb" hyper- and hypoechoic pattern (idiopathic vacuolar hepatopathy) but identification of a pancreatic tumor on ultrasound is rare. Skin biopsies (which should include newly crusting areas with the crust intact) are diagnostic, with a classic diffuse parakeratotic hyperkeratosis, intra- and intercellular epidermal edema, and a superficial dermal perivascular to lichenoid infiltrate (red, white and blue pattern) on H&E (2-7). Chronic lesions may lack the epidermal edema. Secondary bacterial and yeast infections may be identified in the superficial crusts.

SND is a severe, challenging condition with a grave prognosis because the causative disease is often advanced and irreversible. Therapy is directed at correcting the underlying disease if possible and providing supportive care. Animals with pancreatic neoplasia or drug-induced hepatopathy have the best chance of survival if the tumor can be removed or the drug withdrawn in time for the liver to recover. Treatment for idiopathic vacuolar hepatopathy is limited to supportive care, which includes treating secondary skin infections and nutritional support to correct the amino acid deficiency. Intravenous hyperalimentation with a hypertonic amino acid supplement over a 6-8 hour period 1-2 times a week until lesions improve is beneficial in some patients, but if there is no response in the first two weeks, this is unlikely to be of help. Dietary support includes adding omega-3 fatty acids, zinc and high quality protein to the diet. Glucocorticoid therapy may produce temporary improvement of skin signs, but the state of glucose intolerance and risk of inducing diabetes mellitus may preclude their use.



“Veterinarians often treat dermatologic signs in their patients without identifying a clear cause, but this approach may mean that cutaneous manifestations of systemic disease are missed.”

Patricia D. White



© Patricia D. White – figs 4, 5 and 6

Figure 4. Feline paraneoplastic alopecia with diffuse alopecia, mild crusting and a shiny nose.

Feline paraneoplastic alopecia (FPA) presents with a history of acute onset, rapidly progressive non-pruritic alopecia affecting the ventral chest, axillae, abdomen, and medial and caudal thigh regions extending onto the perineum, paws and nasal planum (**Figure 4**). A classic glistening or shiny appearance to the skin sets it apart from other causes of alopecia, but may not be present in every case. There may be a mild to moderate crusting at the margin of the haired skin and the fur epilates easily in these areas. Pruritus may be attributed to a *Malassezia* infection in the crusted margins. Other vague clinical signs include weight loss and inappetence. Histopathologic results demonstrate telogenization of hair follicles without tricholemal keratinization, a hyperplastic epidermis, and a mild mononuclear cell infiltrate in the superficial dermis (8-10). This is a rare condition in older cats (>10 years) associated with pancreatic carcinoma, cholangiocarcinoma, hepatocellular carcinoma, metastatic intestinal carcinoma, neuroendocrine pancreatic neoplasia and hepatosplenic plasma cell tumor (8-10). By the time the dermatologic signs are evident the cancer has already metastasized. Primary differential diagnoses include dermatophytosis, demodicosis, allergic dermatoses, hyperadrenocorticism, thyroid disease (hyper- and hypothyroidism), and exfoliative dermatitis. Removal of the tumor may be possible, but FPA generally carries a grave prognosis.

Exfoliative dermatitis and thymoma in cats can present with marked diffuse exfoliative dermatitis, where large, flat, dry flakes come off the skin in sheets, a hallmark presenting sign for this condition (11,12) (**Figure 5**). As the disease progresses generalized erythroderma develops and the fur may epilate easily, but the condition is non-pruritic, unless accompanied by *Malassezia* overgrowth. These cats are clinically sick (anorectic, depressed, thin). Identification of a mediastinal mass [via thoracic radiograph/ultrasound] supports the diagnosis, but the dermatitis may precede detection of a mediastinal mass. CBC and biochemical profile findings are variable and unremarkable. Histologic findings on skin biopsy include marked

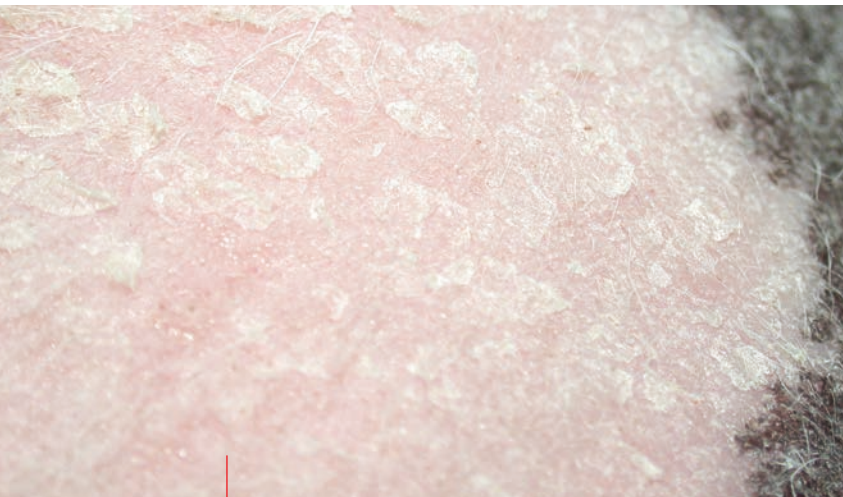


Figure 5. Feline exfoliative dermatitis with large sheets of scale on the skin and mild generalized erythroderma.

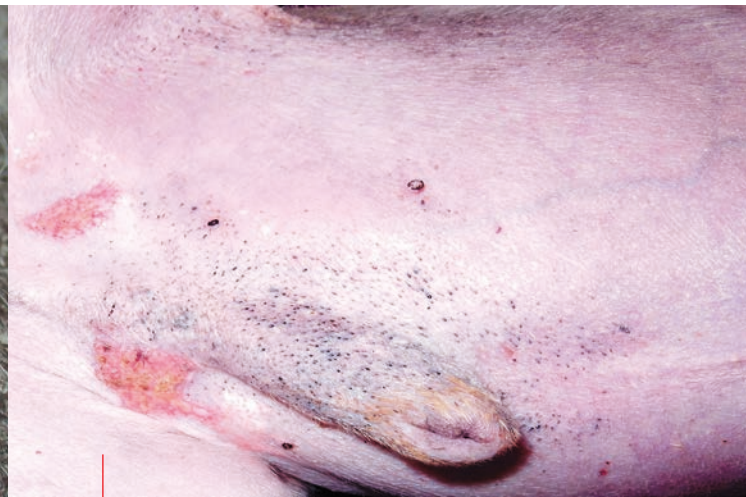

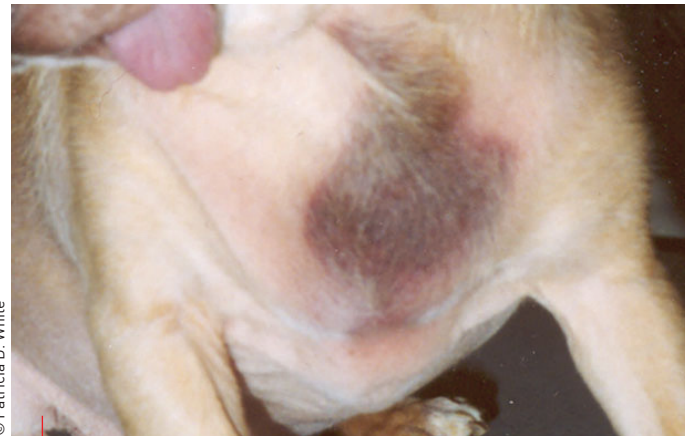Figure 6. Spontaneous hyperadrenocorticism in a dog. Note the thin skin, comedones and prominent dermal blood vessels on the ventral abdomen. The erythemic plaques are typical of calcinosis cutis.

diffuse orthokeratotic hyperkeratosis, a cell-poor interface dermatitis with hydropic degeneration of basal cells, and apoptosis of keratinocytes (11,12). The pathomechanism of the dermatosis is unknown but is thought to be a graft vs. host-like reaction, where immunoreactive T-cells target the skin. Primary rule-outs include FPA, dermatophytosis, Erythema Multiforme, SLE, CLSA/MF, and Exfoliative Dermatitis not related to thymoma. Removal of the thymic tumor is the treatment of choice.

Exfoliative dermatitis without thymoma (12) is an important differential diagnosis for this condition because it carries a better prognosis and a different therapeutic approach. The diagnostic evaluation is the same but a search for a mediastinal tumor is negative and the condition responds well to immunosuppressive therapy (ciclosporin and glucocorticoids).

●●● Endocrine dermatoses

Endocrine disorders are caused by an imbalance (usually excess) in hormones. The classic dermatological presentation is bilaterally symmetrical hypotrichosis to alopecia without pruritus (13), although secondary bacterial or yeast infection, as a result of altered barrier function and immune response, can cause pruritus. Common endocrinopathies include gonadal, adrenal and thyroid disorders. Skin changes are often noted before constitutional signs develop and are similar among the different hormonal abnormalities. Signalment, a thorough history and complete dermatologic examination will inform the differential diagnosis list. Endocrine dermatoses may present with dry, brittle fur; non-pruritic symmetrical trunk alopecia (the head and extremities are often spared); loss of primary pelage (puppy coat); symmetrical cutaneous hyperpigmentation in the areas of fur loss that can become generalized; lichenification, especially over areas of friction; failure of the fur to regrow after being clipped; and a scaly seborrheic dermatosis that may be dry or oily (1). These diseases may also be classified as paraneoplastic, as they are

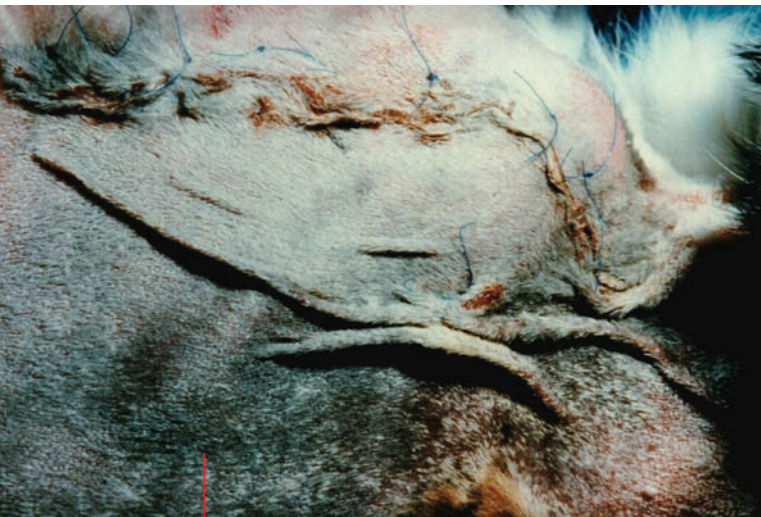


© Patricia D. White

Figure 7. Marked bruising on the neck as a result of venipuncture in a 7-year-old Chihuahua with HAC. The only other dermatologic sign of HAC was mild symmetrical hypotrichosis on the head, ventral neck, chest and abdomen.

often caused by excess hormone from a glandular tumor. Common skin disorders that can resemble endocrine disease include any chronic pruritic condition that leads to alopecia, hyperpigmentation and lichenification; *Malassezia* dermatitis (chronic); or the effects of iatrogenic hormonal excess.

Hyperadrenocorticism (HAC) or spontaneous Cushing's disease results in excess cortisol from either a pituitary or adrenal tumor. It occurs in middle aged to older dogs; Boxers, Poodles, Boston terriers, Scottish terriers and Dachshunds are over-represented (13). Excess cortisol has a significant effect on epidermal, follicular, collagen and elastin production. Naturally occurring HAC may cause PUPD, panting,



© Patricia D. White

Figure 8. HAC caused by a pituitary tumor in a cat. The fur epilated easily and the skin tore with even mild handling (note the sutured skin). This cat presented with marked bruising, open wounds, paper-thin atonic skin, PU/PD and uncontrolled diabetes mellitus.

thinning of the fur, bruising of the skin, cutaneous hyperpigmentation, bilaterally symmetrical alopecia, seborrheic dermatitis, thin hypotonic skin, comedones, muscle atrophy, prominent dermal blood vessels, and a pot-bellied appearance (**Figures 6-7**). Calcinosis cutis may occur in about 10 % of patients. Chronic, recurrent superficial pyoderma, generalized demodicosis, *Malassezia* dermatitis, or dermatophytosis may occur concurrently, reflecting a suppressed immune function. Other effects of excessive cortisol include diabetes mellitus, recurrent urinary tract infections, acute pancreatitis, and glomerulonephritis. The disease is very rare in older cats; skin lesions may include symmetrical loss of fur, thin, fragile skin that tears and bruises easily, curling of the ear tips, comedones

and prominent blood vessels (**Figure 8**). Iatrogenic HAC may occur in both dogs and cats with therapeutic glucocorticoid excess.

Various abnormalities are often noted on blood sampling [13], and an ACTH stimulation test or a low dose dexamethasone suppression test (LDDST) confirms diagnosis. Abdominal ultrasound may reveal a unilateral adrenal tumor with contralateral adrenal atrophy, or bilaterally plump adrenal glands with pituitary dependent HAC.

Some patients have normal cortisol values on testing despite classic HAC dermatologic changes (13-18). Various terms have been used for this (adrenal hyperplasia-like syndrome, adrenal sex hormone imbalance, alopecia X, pseudo-Cushing's disease), but **hair cycle arrest** is currently the preferred term [16,17]. Adult (2-10 year old) male or female neutered or intact dogs develop a gradual and progressive symmetrical loss of primary but retention of secondary hairs that affects the collar region, trunk and caudal thighs, with the head, face and paws spared (**Figure 9**). Over time, the skin becomes alopecic, hyperpigmented, scaly, dry and hypotonic. Pruritus is rare. Breeds over-represented include the Pomeranian, Chow Chow, Keeshond, Samoyed, and Poodle, although mixed breeds may be affected as well. A clear pathogenesis has yet to be defined [14,15] but primary differential diagnoses include most endocrine dermatopathies. A variety of treatment options have been proposed (melatonin, mitotane, trilostane, phytoestrogens, microneedling) but response to therapy is unpredictable [13,16-19], and both mitotane and trilostane may cause adrenal suppression, which warrants caution with either of these therapies.



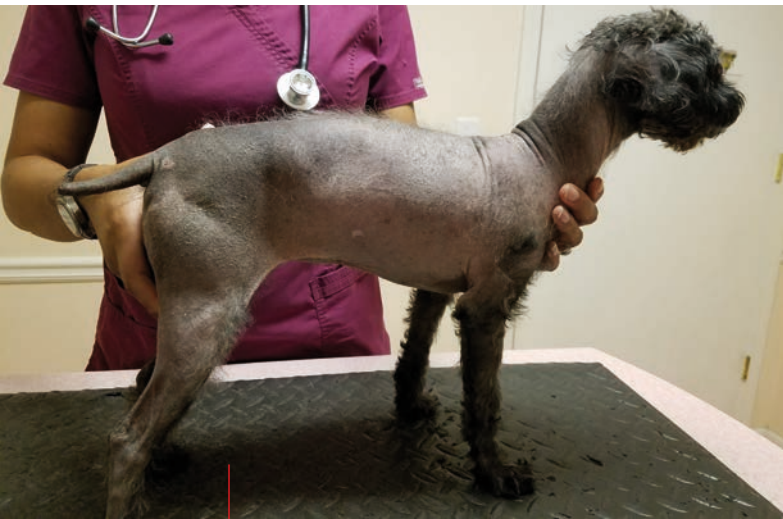“Although unusual, cutaneous manifestations of systemic disease can resemble many common primary dermatological problems... if a patient fails to respond to logical, problem-based therapy, a CMSSD should be considered.”

Patricia D. White

Figure 9. Hair cycle arrest in a Chow Chow.



© Patricia D. White



© Patricia D. White

Figure 10. Generalized trunkal alopecia with dorsal hyperpigmentation and waxy seborrheic dermatitis caused by hyperestrogenism in a recently adopted adult female Poodle whose spay history was unknown.

Hyperestrogenism (feminization syndrome) is the most common and most serious of the gonadal hormone imbalances and can occur with cystic ovaries, a retained testicle or testicular tumor, from contact with an owner's estrogen supplement, or treatment with an estrogen drug for urinary incontinence. History is key for diagnosis. Dermatologic signs may be the only clues and include symmetrical alopecia, cutaneous hyperpigmentation of the neck and trunk, seborrheic dermatitis, and pruritus from yeast or bacterial overgrowth (**Figure 10**). Female dogs may show signs of estrus and vulvar enlargement.

Sertoli cell tumors are the most common testicular neoplasm causing estrogen excess in the dog. Male dogs may show gynecomastia, pendulous prepuce,

macular melanosis (**Figure 11**) in the groin, linear preputial pigmentary change, preputial dermatosis, and attraction to other male dogs. Estrogen excess may cause a life-threatening non-regenerative anemia and thrombocytopenia via bone marrow suppression, so a CBC is mandatory in suspected patients. Surgical removal of the source of the estrogen excess is curative if metastasis has not occurred.



Immune-mediated disease

Immune-mediated skin conditions can present in a variety of ways and mimic a whole spectrum of common conditions. Again a thorough history, including recent and concurrent medications, supplements, diet and topical therapies, is key in obtaining the correct diagnosis.

Cutaneous adverse drug reactions (CADR) occurs when a negative, harmful and unintended reaction occurs as a result of administering or applying a medication, or as a result of the interaction between two chemicals or medications [20]. The pathomechanism is broadly divided into non-immunologic (overdose, irritant reaction, drug interaction) and immunologic (either an autoimmune or foreign antigen response) but the actual pathogenesis is unknown. Lesions can develop with medication used only once or multiple times over months or years. CADR can mimic almost any dermatologic condition and is always a consideration for CMSD. An animal with a history of an allergic condition might be dismissed as simply having a severe flare-up of allergies if this possibility is not considered. If what usually works for an allergic pet suddenly stops working, the diagnosis should be reassessed.

Figure 11. Macular melanosis in the groin of a male dog with a testicular tumor.

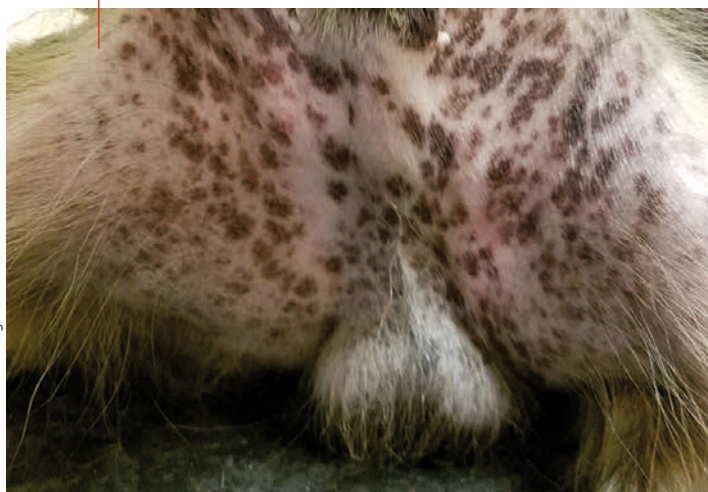
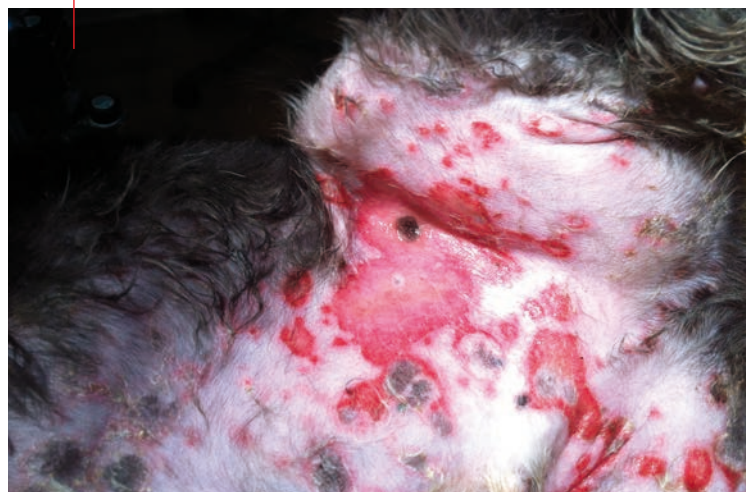
Figure 12. A CADR which presented as erythema multiforme in a dog. Note the targeted, slightly raised ulcers with a pigmented center, and flat annular erythemic and ulcerated macules that coalesce and spread peripherally in the groin. An anti-seizure medication was implicated.



© Patricia D. White — figs 11 and 12

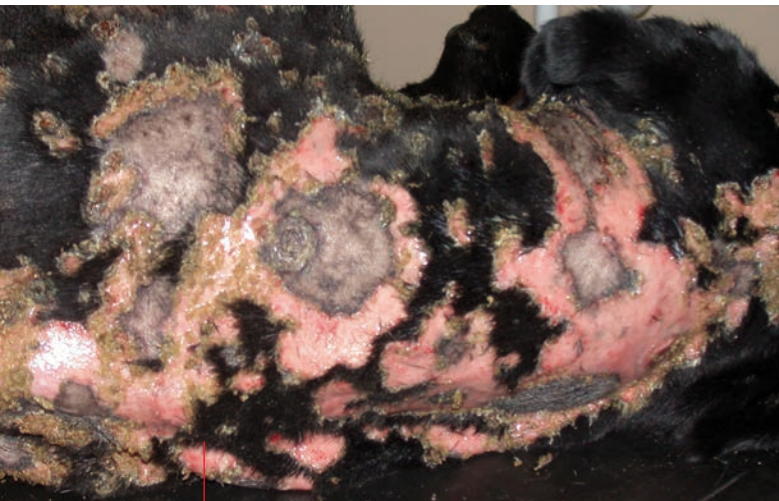

Figure 13. The dorsal neck and shoulders of a 10-year-old Labrador Retriever with TEN. Note the geographic pattern of dermatitis. Initial histologic diagnosis was masked by a severe suppurative pyoderma that made the classic changes of toxic epidermal necrolysis difficult to identify. Biopsy following control of pyoderma was diagnostic.

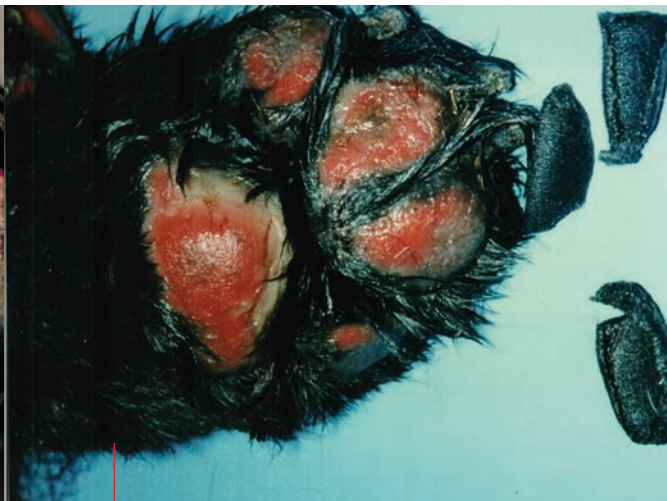

Figure 14. Sloughed footpads from a Chow Chow with TEN subsequent to a potentiated sulfonamide antibiotic.

© Patricia D. White - figs 13 and 14

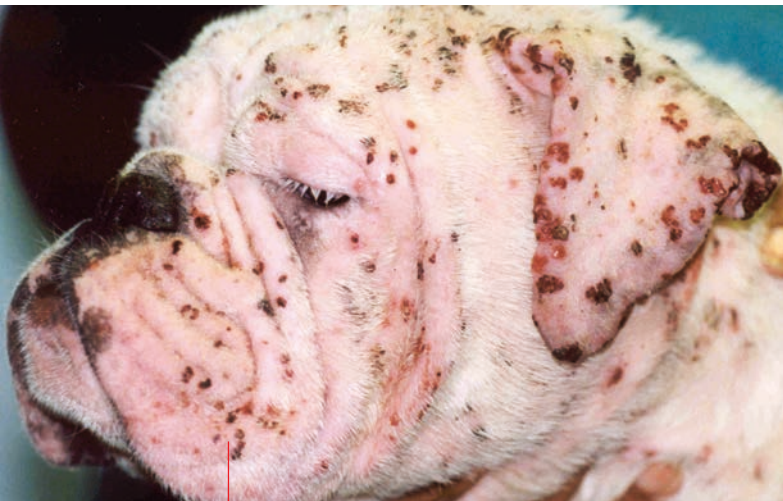There is no age, breed or sex predilection. Any medication used recently or currently is suspect, but commonly implicated drugs include vaccines, sulfonamides, cephalosporins, penicillins, carprofen, and topically applied insecticides and shampoos [20]. Certain dietary ingredients have also been implicated. Dermatological findings include macular-papular-pustular eruptions; exfoliative erythroderma; depigmentation; superficial pustular dermatitis with crusting; erythema, erosions and ulceration of mucous membranes and mucocutaneous junctions; urticaria and angioedema; and full thickness necrosis. Lesions tend to occur ventrally (axilla, groin, genitalia) (**Figure 12**), over pressure points, at mucocutaneous junctions and mucous membranes, and on extremities (pinna, footpads, nail beds). A history of an acute onset and rapid progression of dermatitis should prompt careful evaluation and immediate discontinuation of any medications. The reaction may be limited to the skin or may affect multiple organs.

Erythema multiforme (EM) and **toxic epidermal necrolysis (TEN)** are the two most severe presentations for a drug eruption. In dogs, EM is thought to be a host-specific cell-mediated hypersensitivity reaction directed toward an antigenic stimulus [20]. Clinically, EM demonstrates erythematous flat or raised macules with central clearing that spread peripherally and coalesce to produce annular to serpiginous patterns with or without adherent surface crusts (**Figure 12**). Lesions may occur in the axillae, groin, oral cavity, mucocutaneous junctions, pinnae and footpads. Oral and mucocutaneous lesions are erythemic to vesiculobullous to ulcerative. Some patients are febrile, moribund and anorexic. A skin biopsy taken from a non-ulcerated lesion with an intact epidermis is required to make the diagnosis. Histologic findings for EM include a cell-rich interface dermatitis and keratinocyte apoptosis.

TEN is a rare life-threatening ulcerative and vesiculobullous disease of the skin, mucous membranes and oral cavity most commonly caused by an adverse drug reaction [20]. There is an acute onset of fever, inappetence and lethargy that accompanies the skin eruptions, which may involve a large area of the body. Routine handling of skin may result in sloughing (**Figures 13 and 14**). Histologic findings include full thickness epidermal necrosis, minimal dermal inflammatory cell infiltrate, and dermal epidermal separation with the formation of subepidermal vesicles.

Treatment of drug eruptions includes identifying and eliminating the cause, treating with immunosuppressive (glucocorticoids, ciclosporin) and immunomodulatory (niacinamide, pentoxifylline) medications, and providing appropriate supportive care. Milder forms may resolve without further therapy within a couple of weeks, but more severe forms require aggressive treatment.

Pemphigus foliaceus (PF) is the most common autoimmune disease in dogs and cats. Although typically considered idiopathic, it has occurred as a result of topical pesticides and drugs as well as a paraneoplastic condition [20-24]. Differentiating idiopathic PF from drug-induced or paraneoplastic disease requires a complete and thorough history, but the distinction will dictate the course and duration of therapy. PF is a pustular and crusting disease involving the head, face, ears and paws. The primary differential diagnoses include pyoderma, demodicosis and dermatophytosis and allergies with secondary infection (**Figure 15**). Nasal and mucocutaneous ulceration and depigmentation may also occur, adding other forms of pemphigus, discoid lupus erythematosus, drug eruption, CLSA, SLE, NME, and leishmaniasis to the rule outs. Diagnosis is confirmed with the hallmark histopathological findings of subcorneal and intracorneal pustules containing acantholytic cells.



© Patricia D. White

Figure 15. Pemphigus foliaceus in a 5-year-old bulldog with generalized pustular dermatitis and a history of atopic dermatitis, flea allergy, and recent topical monthly flea treatment.

Paraneoplastic pemphigus (PNP) has the unique histologic findings of intra-epidermal pustules with acantholytic cells similar to PF, along with suprabasilar clefting as seen with pemphigus vulgaris, and intraepidermal apoptosis seen with erythema multiforme. This triad on histopathologic findings warrants investigation for a hidden neoplasm. PNP has been reported in 3 dogs associated with a thymoma, a thymic lymphoma and a splenic sarcoma and one cat with lymphocytic thymoma (25). Establishing an etiology is relevant to therapy because removing the cause can result in permanent resolution of clinical signs.



CONCLUSION

Nowhere in veterinary dermatology is a thorough history more important than with CMSD. Bench diagnostic tests eliminate the obvious (parasites, dermatophyte infection, pyoderma, *Malassezia*) and allows the clinician to treat specific lesions whilst developing an initial list of differential diagnoses, but recognizing the skin markers may identify the cause. If a patient fails to respond to logical, problem-based therapy, a CMSD should be considered; it is certainly time to stop and reassess the diagnosis. Revisiting the history and scrutinizing diagnostics to identify the piece of the puzzle that is missing is essential; once the diagnosis is in hand, the therapeutic part is relatively straightforward.



REFERENCES

1. Miller WH, Griffin CE and Campbell KL. Neoplastic and non-neoplastic tumors. *Muller and Kirk's Small Animal Dermatology*. 7th ed. St Louis: Elsevier, 2013;774-843.
2. Gross TL, Song MD, Havel PJ, et al. Superficial necrolytic dermatitis (necrolytic migratory erythema) in dogs. *Vet Pathol* 1993;30:75-81.
3. McNeil PE. The underlying pathology of the hepatocutaneous syndrome; a report of 18 cases. In Ihrke PJ, Mason IS, White SD (eds): *Advances in Veterinary Dermatology* Vol 2. New York, Pergamon Press, 1993;113-129.
4. Outerbridge, CA, Marks, SL, Rogers QR. Plasma amino acid concentrations in 36 dogs with histologically confirmed superficial necrolytic dermatitis. *Vet Dermatol* 2002;13:177-186.
5. Cave A, Evans T, Hargreaves H, et al. Metabolic epidermal necrosis in a dog associated with pancreatic adenocarcinoma, hyperglucagonaemia, hyperinsulinaemia and hypoaminoacidaemia. *J Small Anim Pract* 2007; 48:522-526.
6. Godfrey DR, Rest, RJ. Suspected necrolytic migratory erythema associated with chronic hepatopathy in a cat. *J Small Anim Pract* 2000;41:324-328.
7. Kimmel SE, Christiansen W, Byrne KP. Clinicopathological, ultrasonographic, and histopathological findings of superficial necrolytic dermatitis with hepatopathy in a cat. *J Am Anim Hosp Assoc* 2003;39:23-27.
8. Brooks DG, Campbell KL, Dennis JS. Pancreatic paraneoplastic alopecia in three cats. *J Am Anim Hosp Assoc* 1994;30:557-563.
9. Turek MM. Cutaneous paraneoplastic syndromes in dogs and cats: a review of the literature. *Vet Dermatol* 2003;14:279-296.
10. Chiara C, Albanese F, Binanti D, et al. Two cases of feline paraneoplastic alopecia associated with a neuroendocrine pancreatic neoplasia and a hepatosplenic plasma cell tumor. *Vet Dermatol* 2016;27:508-512.
11. Rottenberg S, von Tscherner C, Roosje PJ. Thymoma-associated exfoliative dermatitis in cats. *Vet Pathol* 2004;41:429-433.
12. Linek M, Rüfenacht S, Brachelente C, et al. Non-thymoma-associated exfoliative dermatitis in 18 cats. *Vet Dermatol* 2015;26:40-e13.
13. Frank LA. Endocrine and metabolic diseases. In: Miller WH, Griffin CE and Campbell KL (eds). *Muller and Kirk's Small Animal Dermatology*. 7th ed. St Louis: Elsevier, 2013;512-553.
14. Behrend EN, Kennis R. Atypical Cushing's Syndrome in dogs: arguments for and against. *Vet Clin Small Anim* 2010;40:285-296.
15. Greco DS. Hyperadrenocorticism associated with sex steroid excess. *Clin Tech Small Anim Pract* 2007;2:12-17.
16. Frank LA, Hnilica KA, Oliver JW. Adrenal steroid hormone concentrations in dogs with hair cycle arrest (Alopecia X) before and during treatment with melatonin and mitotane. *Vet Dermatol* 2004.15:278-284.
17. Frank LA. Oestrogen receptor antagonist and hair regrowth in dogs with hair cycle arrest (Alopecia X). *Vet Dermatol* 2007;18:63-66.
18. Leone F, Cerundolo R, Vercelli A, et al. The use of trilostane for the treatment of alopecia X in Alaskan malamutes. *J Am Anim Hosp Assoc* 2005;41:336-342.
19. Stoll S, Dietlin C, Nett-Mettler CS. Microneedling as a successful treatment for alopecia X in Pomeranian siblings. *Vet Dermatol* 2015;26:387-390.
20. Halliwell, REW. Autoimmune and Immune-mediated dermatoses. In: Miller WH, Griffin CE and Campbell KL (eds). *Muller and Kirk's Small Animal Dermatology* 7th ed. St Louis MO: Elsevier, 2013;466-500.
21. Bizikova P, Linder KE, Olivry T. Fipronil-amitraz-S-methoprene triggered pemphigus foliaceus in 21 dogs: clinical, histological and immunologic characteristics. *Vet Dermatol* 2014;25:103-111.
22. Bizikova P, Moriello KA, Linder KE, et al. Dinotefuran/pyriproxyfen/permethrin pemphigus-like drug reaction in three dogs. *Vet Dermatol* 2015;26:206-208.
23. Oberkirchner U, Linder KE, Dunston S, et al. Metaflumizone/amitraz (Promeris)-associated pustular acantholytic dermatitis in 22 dogs: evidence suggests contact drug-triggered pemphigus foliaceus. *Vet Dermatol* 2011;22:436-448.
24. Foster AP, Sturgess CP, Gould DJ. Pemphigus foliaceus in association with systemic lupus erythematosus, and subsequent lymphoma in a cocker spaniel. *J Small Anim Pract* 2000;41:266-270.
25. Hill PB, Brain P, Collins D, et al. Putative paraneoplastic pemphigus and myasthenia gravis in a cat with a lymphocytic thymoma. *Vet Dermatol* 2013;24:646-e164.

ELIMINATION DIET TRIALS: SETTING UP FOR SUCCESS

For many vets, common challenges when conducting elimination diet trials include client compliance, practicality and interpretive value, but Vandré Clear offers some pointers to help make the trial meaningful, user-friendly and successful.



Client communication

Explain that animals can develop an allergy to any proteins they have ever eaten, whether animal-based or plant-based. Many pet owners believe that their pet cannot be allergic to their food "because they have eaten it their whole life". When conducting an elimination diet trial, you must eliminate everything the pet has previously been exposed to. Exposure to even small amounts of an antigenic substance can cause a flare or persistence of symptoms.

Address the misconceptions that grains cause allergies.

They have no increased likelihood of causing symptoms over any animal-based protein.

Explain that grains and other plant-based proteins are in pet food to provide highly digestible sources of protein, not as fillers.

While many pet food manufacturers now use peas or potatoes as plant-based proteins, animals can develop adverse reactions to these proteins as well.

Prepare your clients for the rigors, expense, pitfalls and benefits of a proper elimination diet trial.



© Shutterstock



Avoiding pitfalls

Whenever possible, have all pets of the same species in the household on the food chosen for the elimination trial. This will reduce cross contamination and accidental or unseen exposure via shared food and water bowls. Additionally, access to other animals' foods, licking dishes left out on tables or counters, etc. can all confound a diet trial.

Most pet owners are disheartened by the need to eliminate all treats and flavored chew toys. **Make sure that you provide treats and/or canned food that**

are appropriate to the diet you choose. Provide options of chew toys that are not flavored and that do not contain animal or plant proteins.

Ensure you have a strong base knowledge about pet nutrition and ingredients. The more you can explain to your client about pet nutrition, the more success with compliance you will have. **It is imperative to success that owners understand why you are conducting the elimination diet trial and why you are setting certain specific rules and guidelines.**



© Shutterstock

Vandre Clear,

DVM – Animal Skin Ear and Allergy Clinic, St. Louis, MO, USA

Dr. Clear received her DVM from The Ohio State University in 2009. She completed a specialized private practice internship in Internal Medicine and Critical Care, then practiced as an emergency clinician and general practitioner for the next three years. However, with a developing interest in dermatology she left general practice and completed her residency in dermatology at Michigan State University in 2015.



Duration of a diet trial

The duration of a diet trial is 8 weeks and ideally up to 12 weeks (1). In most cases, improvement (*i.e.*, a reduction in pruritus and the ability to decrease or eliminate adjunct medications) occurs within 6-8 weeks, while maximum improvement and resolution of clinical signs may take 10-12 weeks.

Adjunctive symptomatic medications are often needed at the start of the diet trial. Throughout the trial, try to periodically reduce or eliminate these medications

and assess results with the diet alone. If there is no or minimal improvement with diet alone, and/or additional symptomatic medications are still needed after 8 weeks, pursue other causes of pruritus. If there is more than one allergic disease present that has not been diagnosed or controlled, symptoms can persist, making it appear the diet trial has been unsuccessful.

In pets with a concurrent true food allergy as well, there may be resolution of GI signs as early as 4-6 weeks.



© Shutterstock



Do's and Don'ts

DO switch to topical or non-flavored preventives during the diet trial. The proteins in flavorings are enough to cause some dogs to flare up.

DON'T use over-the-counter diets for an elimination diet trial! (see page 40)

If you know or suspect the pet also has environmental allergies, DON'T start a diet trial during the

season(s) in which their symptoms are exacerbated.

DO make sure that prior to the diet trial, the owner has fully disclosed the pet's dietary history; include treats, medications, preventives and any table food their pet eats/has eaten. If it is a multiple-species household, inquire about the pet's access to the other animals' foods. Not all pets will respond to the same type of prescription diet. In today's world of specialty pet foods, it is

becoming increasingly difficult to find a "novel" protein, *i.e.*, one that the pet has never been exposed to.

While hydrolyzed, novel protein and home cooked diets with novel proteins are, in most cases, successful, an allergic animal can still flare/react to even these diets on occasion. If one type of diet does not seem to be successful, try a different type and also question the client again about previous exposures and any possible transgressions.



© Shutterstock



REFERENCES

1. Olivry T, Mueller R, Prélaud P. Critically appraised topic on adverse food reactions of companion animals (1): duration of elimination diets. *BMC Vet Res* 2015;11:225.

QUALITY CONTROL FOR HYDROLYZED DIETS

Identifying a suitable diet for pets with adverse food reaction can be less than straightforward and pitfalls await the unwary; here Jérôme Naar and Isabelle Lespoune outline how Royal Canin ensure their Anallergenic diets are free from unwanted proteins.

KEY POINTS

Recent studies have highlighted that the contents of many diets claiming to be suitable for adverse food reactions are potentially not fit for purpose.

1

Royal Canin Anallergenic diets are manufactured to exacting standards which ensure they are appropriate for animals that suffer from adverse food reactions.

2

Adverse Food Reactions (AFR) in dogs and cats are a not-uncommon cause of dermatological signs presented in clinical practice. Commercial AFR diets are often used in both the diagnosis (via an elimination trial, as detailed on **page 38**) and treatment of the condition, and two broad categories of diets are available:

1. "Selected" or "novel" protein diets, with limited protein sources and – ideally – a single carbohydrate source.
2. "Hydrolyzed diets", consisting of partially or extensively hydrolyzed protein.

Elimination diet trials can be subject to various potential failures. Two major concerns are that the AFR diet must be free of ancillary proteins (as potential cross-contamination in petfood factories is a major concern) and (for hydrolyzed diets) have a guaranteed level of hydrolysis, with no remaining allergenic fragments present. Recent studies have highlighted that some commercial (mostly "over-the-counter") diets marketed for AFR contain undeclared ingredients and/or large molecular weight proteins; for instance, discrepancies were found between protein analyses and labeling in around 75% of diets tested in recent studies (1-3). Consequently, to ensure the absence of

cross-contaminated products, three key elements are required: fully characterized raw materials, fit-for-purpose industrial equipment and cleaning processes, and optimal analytical controls.

A recent study sought to confirm the specific protein composition of Royal Canin's Anallergenic canine and feline diets (Ultamino in North America) – which are based on extensively hydrolyzed poultry feather and cornstarch – and the efficacy of the cross-contamination risk management process.

- Protein composition was assessed via high-sensitivity chromatographic, electrophoretic and proteomic techniques by an external independent laboratory. The results obtained confirmed the extensive level of protein hydrolysis (**Figure 1**), the absence of protein in the palatability enhancers (included in the kibble coating), and the absence of cross-contamination (4). The ubiquitous corn starch glycoprotein GBSS (granule-bound starch synthase) was detected, which to date has no known adverse effects in pets, but lipo-transfer proteins (LTPs) – which are well-recognized to be allergenic – were not detected. The same results were obtained for both canine and feline diets (4).

- Cross-contamination risks are assessed by testing each production batch using a specific 3-step DNA-based analysis (**Figure 2**). This involves measurement of the total DNA content of the diet and comparing the results with a conformity threshold established during a multicentre pre-clinical trial (5). If DNA is detected above this threshold, PCR analyses are conducted to identify the contamination source. To correlate the DNA to the unwanted proteins, "calibration curves" are then employed to assess the actual concentrations of protein present.

Since launching in 2011, this method has been employed to test more than 2,500 production batches of Anallergenic, with all found to conform to the required standards. This has allowed the batches to be released from the factory for sale.

Acknowledgements to Mars Petcare Central Laboratory, Aimargues (France) and the Luxembourg Institute of Science and Technology.

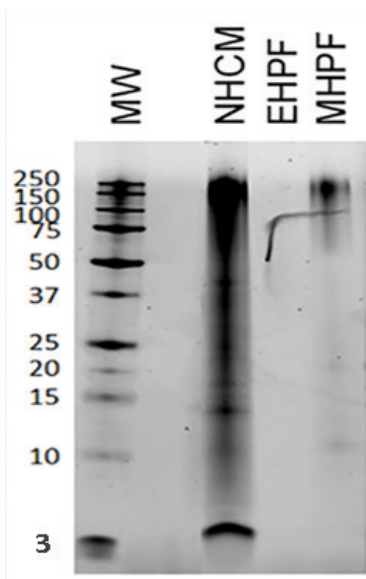


Figure 1. Protein electrophoresis on three different poultry-based raw materials, including the extensively hydrolyzed feather protein of Anallergenic diets.

Key:

- **NHCM** (non-hydrolyzed chicken meal): many proteins of varying molecular weight can be seen
- **EHPF** (Anallergenic extensively hydrolyzed poultry feather): no band seen
- **MHPF** (mildly hydrolyzed poultry feather): residual large proteins are seen
- **MW**: molecular weight in kilodaltons (kDa)

Note: Free amino acids are not visualized by this technique. The artefact on the gel was a deposit before migration.

Isabelle Lesponne,

DVM – Royal Canin R&D, Aimargues, France

Dr. Lesponne graduated from the National Veterinary School of Toulouse in 2001 and worked in small animal practice for several years before moving to an animal pharmaceutical company in 2007. She has served as scientific support manager at Royal Canin R&D since 2011.



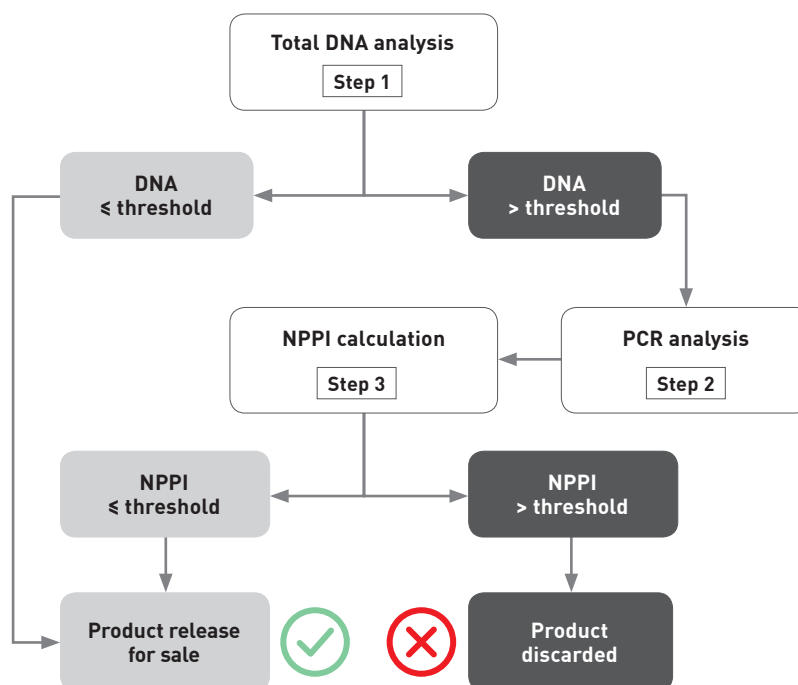
Jérôme Naar,

PhD – Royal Canin R&D, Aimargues, France

Dr. Naar has a background in biochemistry, environmental science and toxicology and joined Royal Canin in 2012 as an expert within the Quality & Food Safety team in R&D. Prior to this, he worked with the Pasteur Institute in French Polynesia before relocating to the USA to manage a research laboratory specializing in environmental toxicology.

Figure 2. Each production batch is tested to determine if there has been unwanted protein cross-contamination using a specific 3-step DNA-based analysis.

- **Step 1:** The total DNA content is measured and compared to a threshold established during a multicentre pre-clinical trial on dogs suffering from complex or refractory AFR (5).
- **Step 2:** If DNA levels exceed the threshold, PCR analysis is conducted to identify the type of protein contamination.
- **Step 3:** The concentration of the unwanted proteins is calculated from the total DNA measurement using the appropriate calibration curve. This is known as the “no protein pollution index” or NPPI. If the NPPI is at or below the acceptable threshold, the batch is released for sale; if the NPPI is above the acceptable limit the batch is discarded.



REFERENCES

1. Horvath-Ungerboeck C, Widmann K, Handl S. Detection of DNA from undeclared animal species in commercial elimination diets for dogs using PCR. *Vet Dermatol* 2017;28(4):373-e86.
2. Ricci R, Granato A, Vascellari M, et al. Identification of undeclared sources of animal origin in canine dry foods used in dietary elimination trials. *J Anim Physiol Anim Nutr (Berl)* 2013;97 Suppl 1:32-38.
3. Roitel O, Maurice D, Douchin G, et al. High molecular weight proteins in hydrolysed dog foods. *Vet Dermatol* 2015;26:304.
4. Lesponne I, Naar J, Montano M, et al. DNA and protein analyses support the clinical reliability of an extensively hydrolysed diet. *Vet Dermatol* 2017;28:11.
5. Mougeot I, Weese H, Sauve S, et al. Clinical efficacy of a highly hydrolyzed poultry feather protein-based diet for canine AFR diagnosis and dietary management: a 12 case pilot study. In *Proceedings*, Waltham International Nutrition Sciences Symposium 2013.
6. Bizikova P, Olivry T. A randomized, double-blinded crossover trial testing the benefit of two hydrolysed poultry-based commercial diets for dogs with spontaneous pruritic chicken allergy. *Vet Dermatol* 2016;27(4):289-e70.
7. Boutigny L, Lesponne I, Feugier A, et al. Evaluation of a new extensively hydrolyzed poultry feather protein-based diet for the dietary management of feline adverse food reaction (AFR): a 15 cases pilot study. Poster, SEVC congress, Barcelona, 2017.
8. Cadiegues MC, Muller A, Bensignor E, et al. Diagnostic value of home-cooked and an extensively hydrolysed diet (*Anallergenic*, Royal Canin, France) in the diagnosis of canine adverse food reaction: a randomized prospective multicenter study in 72 dogs. In: *Proceedings*, World Veterinary Dermatology Congress 2016.

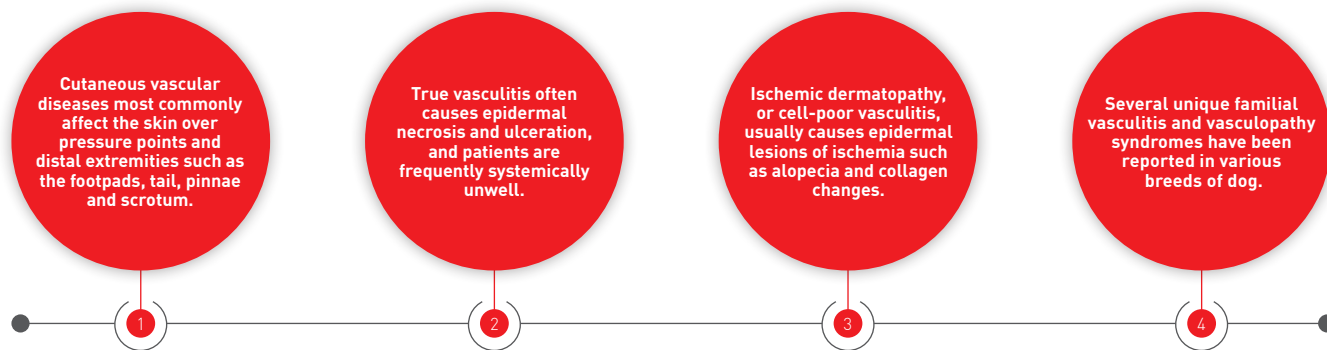
CONCLUSION

Because of the strict quality control features (careful selection of raw materials, scrupulous factory protocols and cleaning methods, and rigorous DNA tests), no cross-contamination is present in these diets which, along with proven extensive protein hydrolysis, ensures optimal clinical reliability and efficacy for using Anallergenic in AFR diagnosis and management (6-8).

VASCULAR SKIN DISEASE

The vasculature of the skin plays a vital role in ensuring various homeostatic mechanisms function as normal, but when disease strikes, the effects can be dramatic. Elizabeth Goodale takes an analytical look at what can go wrong.

KEY POINTS



●○○○ Introduction

As the largest organ in the body, the skin has a variety of anatomical and physiological functions. The vasculature of the skin is important for thermoregulation, immune function, endocrine function and wound healing, and the hair follicle cycle and normal epidermal turnover are dependent on adequate blood supply. The skin receives about 4% of the total cardiac output, and the cutaneous vasculature is a complex network of plexuses of arteries and veins. The deep plexus contains the major arteries and supplies the subcutaneous tissues, the dermis, the lower portion of the hair follicles and the sebaceous glands. The middle plexus is at the level of the sebaceous glands and supplies the *arrector pili* muscles, the mid portions of the hair follicles, and the sebaceous glands. The superficial plexus supplies the upper portion of the hair follicles and the epidermis (1). The external ears, footpads, nipples and mucocutaneous junctions (eyelid, lip, nostril, prepuce, anus and vulva) are exceptions to this, which may explain why some vascular diseases affect these locations more commonly.

Without an adequate blood supply, skin lesions can range from alopecia to complete ulceration and necrosis, depending on the size of vessel affected and the severity. Most vascular diseases affecting companion animals primarily affect the smaller vessels.

●●○○ Vasculitis

Vasculitis is inflammation that specifically targets blood vessels and it is generally regarded as a reaction pattern, rather than a definitive diagnosis. Any diagnosis of vasculitis should therefore prompt a thorough investigation into possible triggers (2,3).

Patients with true vasculitis are often systemically unwell; pyrexia, anorexia and lethargy are common. Pain is also frequently reported, but can be variable. The cutaneous lesions of vasculitis vary depending on the severity of vascular compromise and subsequent tissue hypoxia. Mild cases may show alopecia, erythema, edema and urticaria (2,3). More severe acute vasculitis can cause sharply demarcated ulcerations (**Figure 1**) or eschars (devitalized skin that is hard and cold to the touch). The pinnae, footpads, tail tip, scrotum, oral cavity and pressure points are most commonly affected, but lesions can also be generalized (**Figures 2 and 3**) (2,3).

There are many reported triggers of vasculitis and it is important to try to identify the etiology for every case (**Table 1**). It is especially important to identify patients with septic vasculitis (including vasculitis caused by deep pyoderma, endocarditis or cellulitis), because immunosuppressive treatments are contraindicated (3). A thorough history – including details of diet, supplements, topical therapies, vaccination history and any medications given – is critical. Patients should

Elizabeth Goodale,

DVM, Dipl. ACVD – University of California, Davis (UCD) Veterinary Medical Teaching Hospital, USA

Dr. Goodale qualified from the Ontario Veterinary College and followed a small animal rotating internship at the Western College of Veterinary Medicine in Saskatoon. She then spent a year working in private small animal emergency practice before doing a residency in dermatology at UCD, which she completed in 2015. She currently works as a staff dermatologist at UCD.



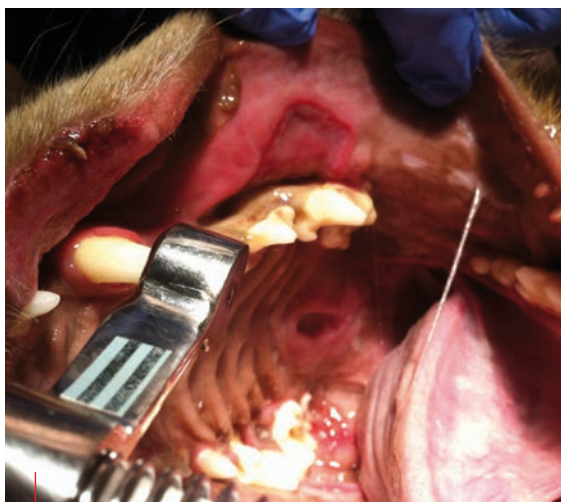
undergo a general physical exam in addition to a dermatological exam. A complete blood count (CBC), serum biochemistry profile, urinalysis and titers for tick-borne diseases should be evaluated in every case.

The diagnosis of vasculitis is made on skin biopsy, which should be collected from acute lesions (erythema and petechiae) rather than completely ulcerated or necrotic skin. Biopsies must be down to the subcutaneous tissue, because the lesions are often very deep. Histopathological lesions essentially show damage to the vascular walls associated with inflammation; there is often microhemorrhage, leukocytoclasia (fragmented granulocyte nuclei) and necrosis. The most common inflammatory cell type is neutrophils, and small vessels are most frequently affected [2].



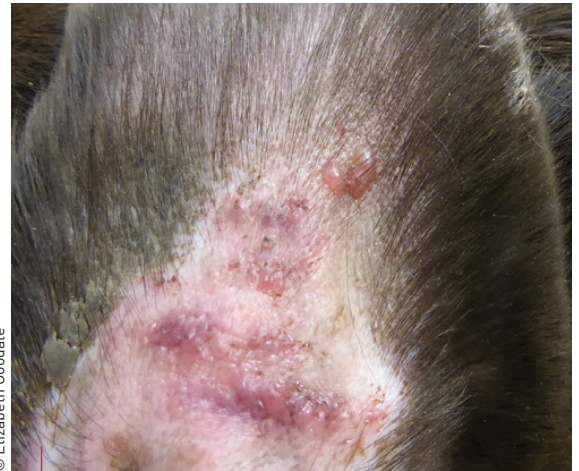Treatment options

Given the wide range of severity and clinical signs, treatment protocols should be tailored to the individual patient (Table 2). If a drug reaction is suspected the offending medication should be discontinued. Infectious diseases and neoplasia should be treated where possible. Food hypersensitivity can also be a trigger (especially if a generalized urticarial vasculitis is present) and an elimination diet trial may be considered appropriate [2].



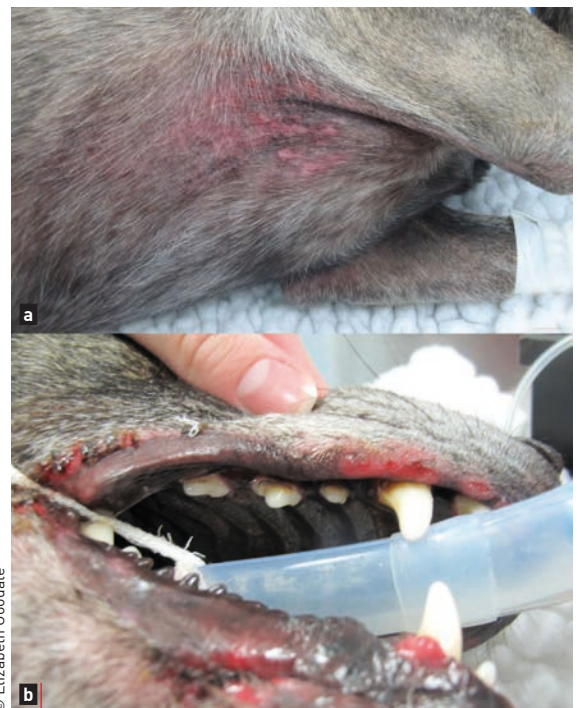© Elizabeth Goodale

Figure 1. Severe, sharply demarcated oral ulceration due to vasculitis triggered by a drug reaction to cephalexin.



© Elizabeth Goodale

Figure 2. The pinnae are often affected in vasculitis cases. This dog with neutrophilic vasculitis presented with vesicles on the concave aspect of its ears.



© Elizabeth Goodale

Figure 3. A case of neutrophilic vasculitis showing ulcerations and erythema in the axilla (a) and ulceration of the lip margins and oral cavity (b).

Table 1. Potential triggers of vasculitis.

Drugs (e.g., cephalosporins, sulfonamides, itraconazole)
Bacterial, viral, protozoal and vector-borne infections
Neoplasia
Vaccinations
Insect bites
Food hypersensitivity
Immune mediated diseases (e.g., systemic lupus erythematosus)

Very mild idiopathic cases are often managed with pentoxifylline or a combination of doxycycline and niacinamide [2]. Pentoxifylline is a methylxanthine derivative that increases red blood cell flexibility, decreases blood viscosity and has anti-inflammatory effects. It is generally well tolerated, but clinical response can take 1-3 months. Doxycycline (a tetracycline antibiotic) and niacinamide (a B-vitamin) used in conjunction have immunomodulatory effects, although the exact mechanisms are not fully understood. Hepatotoxicity with doxycycline has been reported, but is rare. This drug combination also has a very slow onset of action; if a rapid response is necessary, both pentoxifylline and doxycycline/niacinamide can be combined with corticosteroids. Vitamin E has also been used alongside doxycycline/niacinamide.

More severe cases will need more aggressive therapy with a faster onset of action. Glucocorticoids can provide very rapid improvement in clinical signs, but must be used cautiously in patients with extensive ulcerations because they delay wound healing. Anti-inflammatory doses (0.5-1 mg/kg/day) are often sufficient [3].

Secondary immunosuppressive agents (i.e., steroid-sparing drugs, such as ciclosporin or azathioprine) can also be used. Ciclosporin has been used to treat atopic dermatitis and a variety of immune-mediated conditions including vasculitis [2-4], although the cost can be prohibitive. Branded microemulsified products

Table 2. Commonly used medications and oral dosage for vasculitis and ischemic dermatopathies.

Pentoxifylline	15-30 mg/kg q8-12H
Doxycycline	5 mg/kg q12H
Niacinamide	250 mg q8H <10 kg, 500 mg q8H >10 kg
Prednisone/prednisolone	0.5-1 mg/kg q24H
Ciclosporin	5-10 mg/kg q24H
Azathioprine	2.2 mg/kg q24H for 14 days, then q48H
Mycophenolate mofetil	10-20 mg/kg q12H
Sulfasalazine	20-40 mg/kg q8H
Dapsone	1 mg/kg q8H
Vitamin E	200IU q12H small breeds, 400IU q12H medium breeds, 600IU q12H large breeds

have better absorption than generic formulations and are to be preferred [4]. Maximal effect is generally seen after 4 weeks, with transient gastrointestinal upset (vomiting and diarrhea) the most common side effect. Freezing the capsules and administering while frozen has been anecdotally reported to decrease the incidence of vomiting [4] and does not appear to impact the bioavailability [5]. There are many drugs that interact with ciclosporin, so its use should be evaluated carefully when multiple medications are being administered.

A less expensive option as a secondary immunosuppressive agent would be a purine antagonist such as azathioprine or mycophenolate mofetil [3,6]. Azathioprine can cause hepatotoxicity and bone marrow suppression, as well as an increased risk of pancreatitis, so frequent bloodwork is required [3]. A serum biochemistry profile and CBC is generally recommended prior to initiating therapy and should be repeated after 2, 4, 8 and 12 weeks of treatment; if the drug is well tolerated at this point, the tests are then typically repeated every 4 months. A clinical response can take 3-6 weeks. Hepatotoxicity is most likely to occur within the first 2-4 weeks, while bone marrow suppression may occur with chronic usage [7].

Mycophenolate mofetil has not been as extensively employed as azathioprine until recently because of its cost, but generic products are now available and its use is increasing [6]. It has fewer side effects when compared to azathioprine, although diarrhea can occur; bone marrow suppression is uncommon. Again baseline CBC and biochemistry are recommended, but intensive monitoring is not generally required. Clinical response can take 3-8 weeks.

Sulfonamides (e.g., sulfasalazine and dapsone) have been recommended for cases of neutrophilic vasculitis that have not responded to other therapies [2,3]. They interfere with the neutrophil myeloperoxidase system, but their exact mechanism of action is not fully understood. Sulfasalazine is generally better tolerated but can cause reversible keratoconjunctivitis sicca (KCS). Dapsone has been associated with bone marrow suppression, hemolytic anemia, hepatotoxicity, neurotoxicity and hypersensitivity reactions. Baseline CBC and biochemistry is recommended and testing should be repeated every 2-3 weeks for the first 4 months, then every 3-4 months.

As with other immune-mediated skin diseases, the secondary agents are used at the full dose with or without corticosteroids until remission is achieved. The corticosteroid is then generally tapered, aiming to reduce the dose by 25% every 2-4 weeks. Ideally, the goal is to discontinue the corticosteroid before tapering the secondary agent, again by 25% every 4 weeks until the lowest effective dose is achieved or the drug is discontinued. In some cases low doses of both corticosteroid and the secondary agent may need to be maintained.

●●● Ischemic dermatopathies

These are a group of clinical conditions whereby ischemic tissue damage results in lesions without significant visible vasculitis [8]. Often termed "cell-poor vasculitis", common clinical signs include

alopecia, hyper- or hypopigmentation, skin thinning, scale and erosions or ulcers that are slow to heal. These lesions are typically seen at pressure points and the distal extremities. The most common histological lesions are follicular atrophy, pale-staining mucinous collagen and clefting at the basement membrane zone.

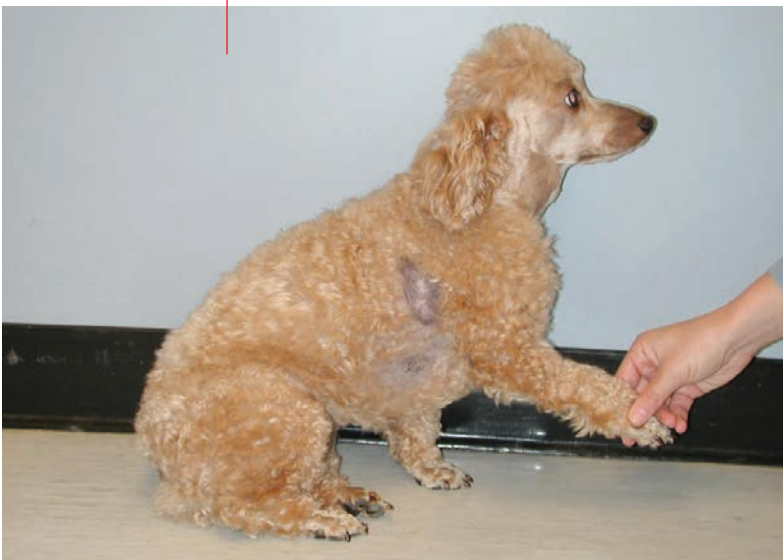Post rabies vaccination panniculitis

This ischemic dermatopathy presents as a focal area of alopecia with hyperpigmentation and occasionally a swelling or plaque at the site of a rabies vaccination (**Figure 4**) (9). It is most commonly seen in Miniature Poodles and other small breed dogs (8,9). The signs typically occur 2-6 months after vaccination and the lesions are non-painful. The diagnosis is often made simply on clinical signs, but biopsy shows a cell-poor vasculitis with follicular atrophy and dermal pallor; inflammation in the subcutaneous tissues (panniculitis) may be present (9). Amorphous blue material, thought to be vaccine components, can sometimes be seen, and rabies-specific immunofluorescence has been identified within the walls of blood vessels. These lesions are mainly cosmetic and rarely necessitate therapy, but pentoxifylline may be used if the lesions are expanding. Repeat vaccination should be done with caution as progressive disease is possible.

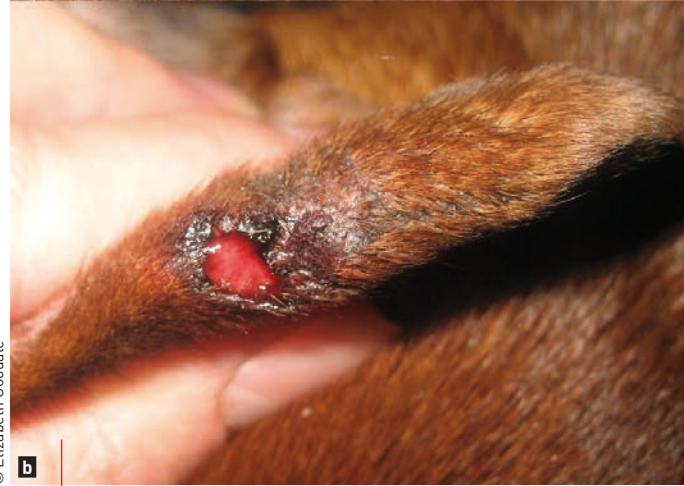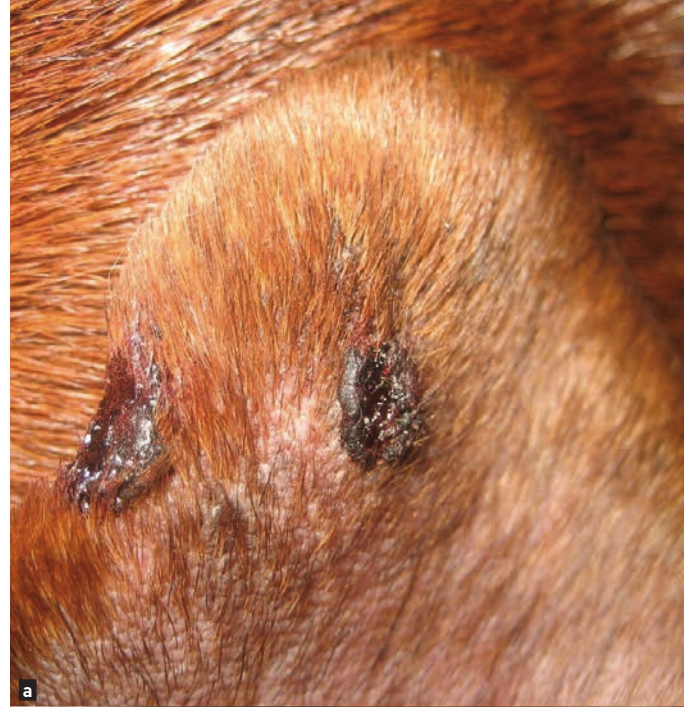Pinnal margin vasculopathy

Sometimes referred to as proliferative thrombovascular necrosis of the pinnae, this is a fairly common ischemic dermatopathy that targets the ear margins. Lesions begin as an area of thickening and scale, often wedge-shaped, on the concave surface of the pinnae, and can progress to ulceration and necrosis of the tips (**Figure 5**) (8). Lesions are generally bilateral and can deform the ear margin. Many cases are idiopathic but there may be an association with recent vaccination or with cutaneous adverse food reactions (8). Since the lesions have a very striking appearance, and because the location is difficult to biopsy, diagnosis is often on clinical

Figure 4. An area of alopecia that developed after rabies vaccination. Notice the drip pattern ventrally.



© Dr. Stephen White



© Elisabeth Goodale

Figure 5. Pinnal margin vasculopathy causing ulcerations and a defect in the pinnal margin (a) and thickening of the pinna (b).



“Vasculitis often causes a severe clinical syndrome with systemic signs, with ulcerations and necrosis of the skin, while ischemic dermatopathy is typically much milder with lesions resulting from epidermal hypoxia”

signs alone. Biopsy shows ischemic tissue damage with or without a cell-poor vasculitis that can have severe thickening of the arteriole walls. Pentoxifylline, doxycycline/niacinamide and/or vitamin E are the most commonly used treatments. For cases that are ulcerated or bleeding, anti-inflammatory doses of corticosteroids are often required, but must be used cautiously because they can delay healing (8). Tacrolimus 0.1% ointment has a similar mechanism of action to ciclosporin and can be applied topically in these cases, although irritation and pruritus at the site of application has been reported in dogs (and humans). If a cutaneous adverse food reaction is suspected then an elimination diet trial should be performed (see **page 38**). For cases that have not responded to medical management surgical removal of the pinnae can be curative, but this should be done cautiously.

Generalized ischemic dermatopathy

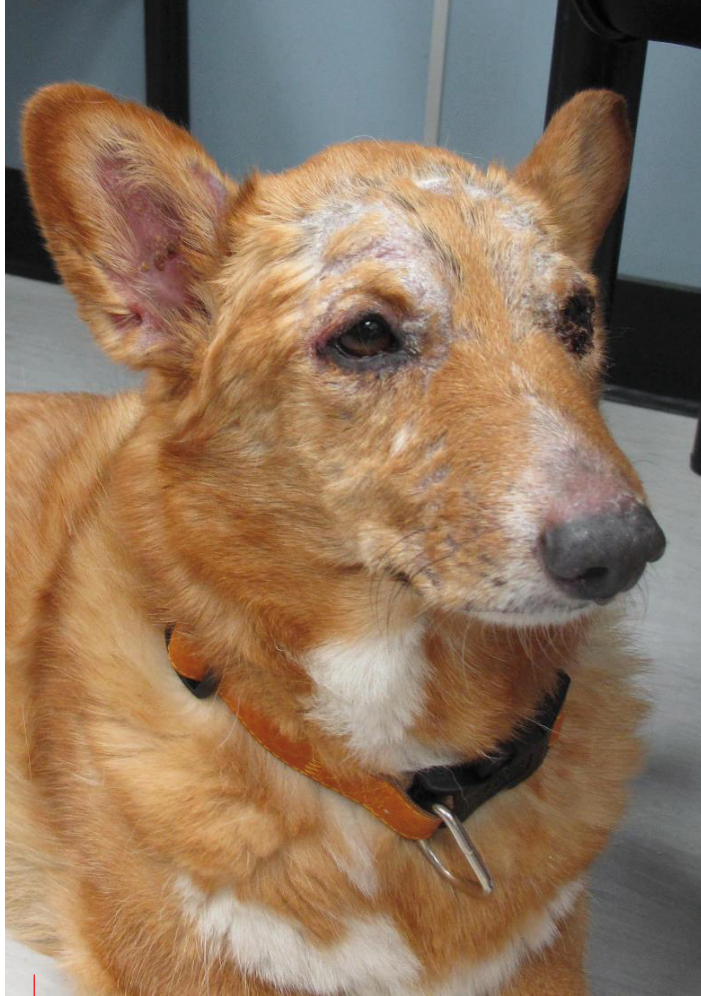These cases present with widespread lesions of ischemic tissue damage, especially over bony prominences of the face and extremities (*i.e.*, distal limbs, ears, pinnal folds, and tail) (8,10). Lesions often begin as alopecia, scale and crusting, and progress to erosions and ulcers with eventual scarring. The nailbeds can be involved and sloughing of the claws may be seen. There can also be a prominent myopathy causing severe muscle atrophy (**Figure 6**) (10). Clinically these cases are often indistinguishable from familial canine dermatomyositis (see below). Skin biopsies are consistent with a cell-poor vasculitis and show the typical ischemic epidermal and dermal changes. This condition can occur in juvenile or adult animals and has been associated with vaccination, although it is often idiopathic (8,10). Secondary bacterial infections can cause pruritus which can result in these cases being mistaken for allergic animals. Treatment options include pentoxifylline, vitamin E, doxycycline/niacinamide or ciclosporin, depending on the severity, but corticosteroids are often avoided because they can exacerbate the epidermal and muscle atrophy. If triggered by a vaccine, repeat vaccinations should be avoided as they can cause a relapse.

●●●○ Familial vasculitis and vasculopathy

Several unique familial vasculitis and vasculopathy syndromes have been reported, and they are briefly discussed below.

Familial canine dermatomyositis

This is a familial generalized ischemic dermatopathy that has been reported in the Border Collie, Shetland Sheepdog, Beauceron Shepherd, Australian Kelpie, Portuguese Water Dog and Belgian Tervueren Shepherd (11-16). Signs typically occur in dogs under 6 months of age, although adult onset has been reported, and signs can vary in severity from mild to severe (8,11-16). These



© Elizabeth Goodale

Figure 6. Adult onset generalized ischemic dermatopathy with significant muscle atrophy of the temporalis muscles in a Welsh Pembroke Corgi.

cases are clinically and histologically indistinguishable from generalized ischemic dermatopathy, and the treatment is the same for both conditions.

Cutaneous vasculopathy of German Shepherd Dogs

Affected dogs usually develop signs between 4-7 weeks of age and often within 7-10 days of their initial vaccination (17). The signs typically include swelling, depigmentation and ulceration of the footpads, ulcers on the pinnae, tail tip and nasal planum, swelling on the bridge of the nose, and nasal depigmentation. Repeat vaccination causes a recurrence or worsening of signs. Affected dogs are usually lethargic, febrile and can be lame with swollen joints. There are no consistent laboratory abnormalities in these cases, and patients generally recover by 5-6 months of age; no treatment has been shown to be effective. Biopsies show subtle vasculopathy and panniculitis with inflammation centered around degenerate collagen bundles (17).

Leukocytoclastic vasculitis of the nasal planum in Scottish Terriers

Clinical signs start at 3-4 weeks of age with a clear nasal discharge and ulceration of the nasal planum, and progressively worsen with destruction of the planum and nasal mucosa [18]. Biopsies show pyogranulomatous inflammation, neutrophilic leukocytoclastic vasculitis and epidermal necrosis. No effective treatment has been reported and all affected dogs have been euthanized.

Cutaneous vasculitis of the Parson Jack Russell Terrier

The most common clinical signs are alopecia, crusting and ulcerations over bony prominences, wedge-shaped necrosis of the pinnae tips, and ulceration of the footpads [19]. Reports note that vaccinations were given 2-3 weeks prior to the onset of lesions in 60% of cases. Histopathology shows leukocytoclastic vasculitis, apoptotic keratinocytes and ischemic degeneration of hair follicles. The clinical and histological appearance is similar to dermatomyositis. Cases have been managed successfully with prednisone, dapsone and/or vitamin E [19].

Dermal arteritis of the nasal philtrum

A proliferative vasculitis affecting the dermal arteries and arterioles underlying the nasal philtrum has been described primarily in Saint Bernards, but also in Giant Schnauzers and Basset Hounds [20,21]. The primary lesions consist of an ulceration affecting only the nasal philtrum that hemorrhages (**Figure 7**). The bleeding can be severe enough to cause anemia and require hospitalization. This condition has been successfully medically managed with prednisone acutely and doxycycline/niacinamide, fish oils and/or topical fluocinolone in dimethyl sulfoxide [20]. Surgery to resect the affected tissue, ligate the vessels and reconstruct a new "philtrum" has also been successful [21].

Cutaneous and renal vasculopathy of Greyhounds

This condition most commonly affects Greyhounds between the ages of 1 and 4 years [22]. Lesions occur most commonly on the tarsus, stifle or thigh and begin as bruising that progresses into sharply demarcated ulcers; these extend into the subcutaneous tissue and heal slowly. Azotemia, polyuria, polydipsia, vomiting, dark or tarry stools, salivation, pyrexia and distal limb edema develops in some cases. Skin biopsies show thrombosis and necrosis of arteries, arterioles, venules and capillaries which cause large areas of tissue necrosis. Renal biopsies show peracute glomerular necrosis involving afferent arterioles, with thrombi in glomerular capillaries. When signs of renal failure are present, aggressive fluid therapy and supportive care is required, but these cases often die. There is some suggestion that this may be similar to hemolytic uremic syndrome in humans, which is caused by a Shiga-like toxin produced by *Escherichia coli* [22].



“Whilst treatment for both vasculitis and ischemic dermatopathies employ similar medications, the therapy should always be tailored to the severity of disease.”

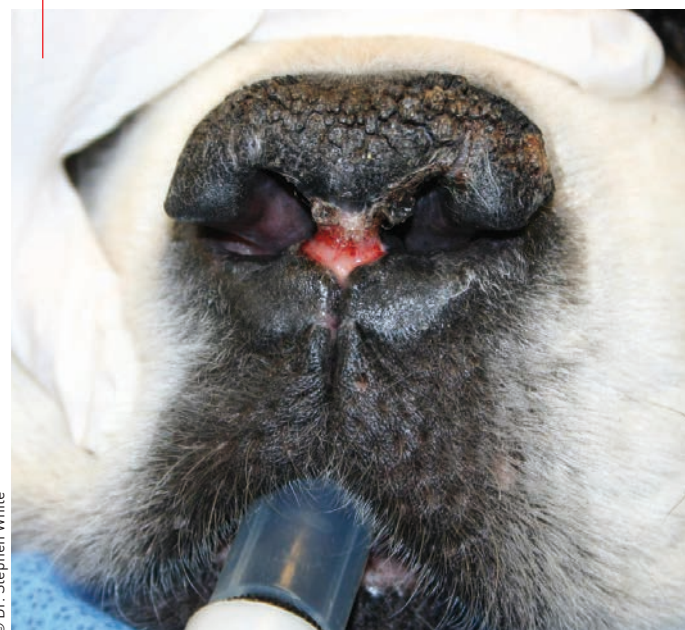Elisabeth Goodale

Environmental vascular diseases

Solar vasculopathy

Chronic sun exposure can cause damage to the vessels in the superficial dermis. This most commonly affects non-pigmented and lightly haired skin on the dorsal muzzle and nasal planum. Acute clinical signs are erythema, swelling, erosions or ulceration, and

Figure 7. Nasal arteritis in a Saint Bernard.



© Dr. Stephen White

with chronic sun exposure this can lead to scarring and further depigmentation. Treatment is mainly through sun avoidance.

Cryofibrinogenemia and cryoglobulinemia

This is a very rare disease whereby cold temperatures cause either fibrinogen or globulins in the blood to form thrombi or immune complexes which precipitate and induce vasculitis. The end result is disruption of blood flow to the extremities, resulting in pain, erythema, purpura, acrocyanosis and necrosis. The cryoglobulins can also target erythrocytes and cause a hemolytic anemia, renal disease or peripheral polyneuropathy. These conditions may be primary in nature or can be secondary to infection or lead poisoning. Diagnosis is by demonstrating agglutination of blood at cold temperatures, a Coombs test, or measuring cryoprecipitate levels. Management involves avoiding a cold environment, correcting the underlying cause, and occasionally medical management with corticosteroids or pentoxifylline.



CONCLUSION

Vascular diseases of the skin most commonly affect the skin over pressure points and distal extremities, such as the footpads, tail, pinnae and scrotum. Vasculitis often causes a severe clinical syndrome with systemic signs, with ulcerations and necrosis of the skin, while ischemic dermatopathy is typically much milder with lesions resulting from epidermal hypoxia. In all instances the underlying triggers should be identified whenever possible, and whilst treatment for both vasculitis and ischemic dermatopathies employ similar medications, the therapy should always be tailored to the severity of disease.



REFERENCES

1. Hughes HV, Dransfield JW. Blood supply to the skin of the dog. *Br Vet J* 1959; 115: 299-310.
2. Nichols PR, Morris DO, Beale KM. A retrospective study of canine and feline cutaneous vasculitis. *Vet Dermatol* 2001;12:255-264.
3. Innera M. Cutaneous vasculitis in small animals. *Vet Clin Small Anim* 2013;43: 113-134.
4. Forsythe P, Paterson S. Ciclosporin 10 years on: indications and efficacy. *Vet Rec* 2014;174:13-21.
5. Bachtel JC, Pendergraft JS, Rosychuk RA, et al. Comparison of the stability and pharmacokinetics in dogs of modified ciclosporin capsules stored at -20°C and room temperature. *Vet Dermatol* 2015;26:228-e50.
6. Ackermann AL, May ER, Frank LA. Use of mycophenolate mofetil to treat immune-mediated skin disease in 14 dogs – a retrospective evaluation. *Vet Dermatol* 2017; 28:195-e44.
7. Wallisch K, Trepanier LA. Incidence, timing and risk factors of azathioprine hepatotoxicosis in dogs. *J Vet Intern Med* 2015;29:513-518.
8. Morris DO. Ischemic dermatopathies. *Vet Clin Small Anim* 2013;43: 99-111.
9. Wilcock BP, Yager JA. Focal cutaneous vasculitis and alopecia at sites of rabies vaccination in dogs. *J Am Vet Med Assoc* 1986;188:1174-1177.
10. Vitale CB, Gross TL, Magro CM. Vaccine-induced ischemic dermatopathy in the dog. *Vet Dermatol* 1999;10:131-142.
11. Hargis AM, Haupt KH, Hegreberg GA, et al. Familial canine dermatomyositis – initial characterization of cutaneous and muscular lesions. *Am J Pathol* 1984;116: 234-244.
12. Hargis AM, Prieur DJ, Haupt KH, et al. Postmortem findings in a Shetland sheepdog with dermatomyositis. *Vet Pathol* 1986;23:509-511.
13. Guaguere E, Magnol JP, Cauzinille L, et al. Familial canine dermatomyositis in eight Beauceron shepherds. In: Kwochka KW, Willemse T, Von Tscharner C, (eds). *Advances in Veterinary Dermatology*. New York: Pergamon Press 1996;527-528.
14. Rothig A, Rufenacht S, Welle MM, et al. Dermatomyositis in a family of working kelpies. *Tierärztl Prax Ausg K Kleintiere Heimtiere* 2015;43: 331-336.
15. Campbell KL, Lowe AD, Lichtensteiger CA. Dermatomyositis in three Portuguese water dog littermates [abstract]. *Vet Dermatol* 2008;19:69.
16. Guaguere E, Degorce-Rubiales F, Muller A. Familial canine dermatomyositis in six Belgian shepherds (Tervueren) [abstract]. *Vet Dermatol* 2008;19:70.
17. Weir JA, Yager JA, Caswell JL, et al. Familial cutaneous vasculopathy of German Shepherds: clinical, genetic and preliminary pathological and immunological studies. *Can Vet J* 1994;35:763-769.
18. Pedersen K, Scott DW. Idiopathic pyogranulomatous inflammation and leukocytoclastic vasculitis of the nasal planum, nostrils and nasal mucosa in Scottish Terriers in Denmark. *Vet Dermatol* 1991;2:85-89.
19. Parker WM, Foster RA. Cutaneous vasculitis in five Jack Russell Terriers. *Vet Dermatol* 1996;7:109-115.
20. Torres SM, Brien TO, Scott DW. Dermal arteritis of the nasal philtrum in a Giant Schnauzer and three Saint Bernard dogs. *Vet Dermatol* 2002;13:275-281.
21. Pratschke KM, Hill PB. Dermal arteritis of the nasal philtrum: surgery as an alternative to long-term medical therapy in two dogs. *J Small Anim Pract* 2009;50: 99-103.
22. Carpenter JL, Andelman NC, Moore FM, et al. Idiopathic cutaneous and renal glomerular vasculopathy of Greyhounds. *Vet Pathol* 1988; 25:401-407.

FURTHER READING

- *Muller & Kirk's Small Animal Dermatology* 7th ed. Miller WH, Griffin CE, Campbell KL (eds). St. Louis: Elsevier Mosby, 2013
- *Skin diseases of the dog and cat* 2nd ed. Gross TL, Ihrke PJ, Walder EJ, et al (eds). Oxford: Blackwell Science Ltd, 2005
- *Plumb's veterinary drug handbook* 8th ed. Plumb DC. Wisconsin: PharmaVet Inc 2015



**SAVE
THE DATE
2018
CONGRESS**



30th

**EUROPEAN VETERINARY
DERMATOLOGY CONGRESS**
ORGANIZED BY ESVD-ECVD



27-29 SEPTEMBER 2018
DUBROVNIK CROATIA

WWW.ESVD-ECVDCONGRESS.COM





TAKE A COMPLETE NUTRITIONAL APPROACH TO ALLERGIC DERMATITIS

Only the ROYAL CANIN® Dermatological range offers the choice of extensively-hydrolysed and partially-hydrolysed protein-based diets for cats and dogs, allowing you to choose the level of hypoallergenicity. From diagnosis to long-term management, now there is a diet for every stage of your clinical approach.

Our ANALLERGENIC product is your first choice for elimination diet trials for Adverse Food Reaction (AFR) or diagnosing Atopy by exclusion.



INCREDIBLE IN EVERY DETAIL

