

VETERINARY focus

#25.1
2015 - \$10/10€

25TH ANNIVERSARY

The worldwide journal for the companion animal veterinarian



Senior and Aging Issues

Chronic valvular disease in dogs • Osteoarthritis in cats • How I approach...The dog with failing eyesight • Age at diagnosis of select chronic diseases • Blood testing in the geriatric dog • Weight loss in the older cat • Canine hyperadrenocorticism • Cut-out and keep guide...
The three most common oral pathologies in adult cats

**ROYAL CANIN**

25

years of *Veterinary Focus*



In the picture above: Editorial committee members. From left to right: Giulio Giannotti (Royal Canin, Italy), Joanna Gale (WALTHAM Centre for Pet Nutrition, UK), Ewan McNeill (Editor in chief, UK), Franziska Conrad (Royal Canin, Germany), Yann Quéau (Royal Canin, HQ), Cláudia Palmeiro (Royal Canin, Portugal) and Philippe Marniquet (Royal Canin, HQ). Missing members: Craig Datz (Royal Canin, USA), Pauline Devlin (Crown Pet Foods, UK) and María Elena Fernández (External member, Costa Rica)

Long live *Veterinary Focus*! It's noteworthy when a private company is willing to use its resources to publish a magazine for a sustained period of time. 25 years have elapsed since the first edition of *Veterinary Focus* appeared, and it continues to develop and grow. Initially created by Waltham, the journal is now edited by Royal Canin with the help of Banfield and the Waltham Centre for Pet Nutrition, and is underwritten by the expertise and principles of Mars, the parent company. The longevity of *Veterinary Focus* underlines our commitment to produce a truly worthwhile journal dedicated to accuracy, excellence and value – qualities that can be said to reflect the ethos behind the publication.

Veterinary Focus underlines our commitment to the "Five Principles" of Mars, the special values of Quality, Responsibility, Mutuality, Efficiency and Freedom. Of these, it is perhaps the concept of mutuality – sharing – that stands out in particular, because the journal requires input and support from a number of dedicated people who have a vision; to share and improve global veterinary

knowledge. The editorial board strives to produce a truly worthwhile journal that offers significant support to the professional community; in some countries, it is the main – or sometimes the only – clinical magazine available to colleagues. As part of our commitment to companion animal clinicians worldwide, the journal is translated into 11 languages, including Russian, Brazilian Portuguese, Japanese and Polish, and we ensure that the papers in each issue are written by passionate authors who want to share not only their enthusiasm and know-how, but also their questions – and even their uncertainties – with veterinarians everywhere.

A recent on-line survey among European practitioners revealed that 75% of them know *Veterinary Focus*, with half of them reading it regularly, and 73% considering it to be "good" or "very good" when compared to other veterinary journals. Our mission for the next 25 years is to improve the distribution, recognition, relevance and appreciation of the journal even more!

Long live *Veterinary Focus*!
The Editorial Committee





WHAT DO OUR AUTHORS THINK OF THE JOURNAL?



"It was a matter of personal satisfaction and pride to be invited to write for *Veterinary Focus* on dermatology, a discipline which is a passion for me. Congratulations on the first 25 years of hard work and professional teaching which results in a clinical journal that offers quality education for many veterinarians, especially those based in Latin America. This reminds me of the words of the Mexican philosopher, Paul Latapí, who said 'Time and experience are valuable, but without professional training and professional wisdom they are practically worthless.'"

Porfirio Trápala Arias, MV, Mexico



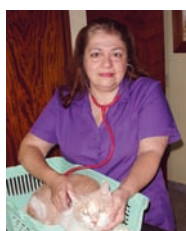
"*Veterinary Focus* could be seen simply as a method by which vets can deepen and update their clinical knowledge in different fields, but I think that in Italy it is much more than this – the journal represents a real bridge between veterinary surgeons in the field and veterinary experts in specialist establishments."

Serena Adamelli, DVM, PhD, Italy



"Written by outstanding professionals and therefore offering excellent reading!"

Javier Collados, DVM, Spain



"It has been a pleasure and an honor to share my area of interest with so many colleagues! *Veterinary Focus* is a prime example of how to extend knowledge; the journal makes it possible to disseminate news and

expertise, and thus contributes towards the bettering of our veterinary abilities. It helps us to advance our diagnostic and treatment skills, and so improve not just the quality of life for our patients, but also for their owners and even ourselves. *Veterinary Focus* allows us to enjoy each day a little more, because we can be a little bit better than yesterday. Congratulations!"

Gabriela Pérez Tort, MV, Argentina

"I personally regard *Veterinary Focus* as a high level professional journal. It is very interesting, with excellent scientific content and good authors."



Isabelle Goy-Thollot, MSc, PhD, France



"*Veterinary Focus* provides timely information for continuing veterinary education. The articles are concise, have good quality illustrations, charts and tables, and are well referenced."

William Widmer, DVM, MS, Dipl. ACVR, USA

"*Veterinary Focus* has been a great reference source used daily over the past 25 years by many French veterinarians. It covers diverse fundamental themes via didactic, well illustrated clinical papers, which together establish a real spirit and enthusiasm for learning. We all anticipate further excellent editions that will enrich the next 25 years!"



Valérie Freiche, DMV, Dipl. ESV, France

**VETERINARY
focus**

**Published in
11 languages**

**Available in
60 countries**

**3 issues
per year**

**30 authors
per year**

**175,000
copies printed
in 2014**

**240,000
downloads on
ivis.org**

**~ 700 articles
published in
25 years**

**25 YEARS OF
SHARED KNOWLEDGE**

03 **Chronic valvular disease in dogs**
Rebecca Stepien

13 **Osteoarthritis in cats**
Elizabeth LaFond

21 **How I approach...The dog with failing eyesight**
Gareth Jones

28 **Age at diagnosis of select chronic diseases**
Emi Kate Saito and Catherine Rhoads

31 **Blood testing in the geriatric dog**
Theresa Rizzi

38 **Weight loss in the older cat**
Diego Esteban Saltiveri and Albert Lloret

46 **Canine hyperadrenocorticism**
Bradley Bishop and Patty Lathan

55 **Cut-out and keep guide... The three most common oral pathologies in adult cats**
Javier Collados



Aging is a peculiar concept. Day by day, hour by hour, we all grow older whether we like it or not; the passing of time is inescapable, and every one of us reading this is older today than we were yesterday. The old Chinese proverb – “Man fools himself; he prays for a long life and he fears old age” neatly encapsulates our varying and sometimes contradictory

attitudes to aging. Certainly it seems that today’s society is obsessed with getting old – or the problems it brings; at every turn we are presented with advertisements promoting products designed to keep us young, and we will use euphemistic words such as “senior” or “mature”, perhaps in the hope that this will make the negatives associated with aging less onerous. Yet old age can also be presented as a positive, and we are encouraged to look forward to retirement and make provision for when we can enjoy it – whilst at other times we may find age to be a useful excuse, claiming that we have gained weight, or are less fit, simply because we are getting older rather than through any fault of our own. And these attitudes carry over to our pets. Veterinarians are frequently presented with an animal that has lost weight, or is stiff, or has a cough, or any number of other signs, and the owner will often suggest that perhaps “it’s just old age,” despite our assurances that old age is not a disease in itself – although one cannot deny that the aging process brings unwanted problems.

Another attitude towards growing old is the oft-heard observation that age allows a person to become wiser; essentially, through the experience of life, one learns. Although this is not always guaranteed – as Oscar Wilde, the humorist and writer put it, “with age comes wisdom, but sometimes age comes alone.” We believe that this issue of *Veterinary Focus* will confound that statement – in the time taken to read the following clinical papers, we anticipate that the clinician will indeed become at least a little wiser.

Ewan McNeill – Editor-in-chief

Veterinary Focus – Vol 25 n°1 – 2015

Find the most recent issues of *Veterinary Focus* on IVIS website: www.ivis.org.

Editorial committee

- Franziska Conrad, DVM, Scientific Communications, Royal Canin, Germany
- Craig Datz, DVM, Dipl. ACVN, Senior Scientific Affairs Manager, Royal Canin, USA
- Pauline Devlin, BSc, PhD, Scientific Communications and External Affairs, Royal Canin, UK
- Maria Elena Fernández, DVM, Costa Rica
- Joanna Gale, BVetMed, CertLAS, MRCVS, Science and Technical Communications Manager, WALTHAM Centre for Pet Nutrition, UK
- Giulio Giannotti, BSc, Product Manager, Royal Canin, Italy
- Hervé Marc, Global Corporate Affairs Manager, Royal Canin, France
- Philippe Marniquet, DVM, Dipl. ESSEC, Veterinary Communication Manager, Royal Canin, France

- Cláudia Palmeiro, DVM, Communication Manager, Royal Canin, Portugal
- Yann Quéau, DVM, Dipl. ACVN, Research Nutritionist, Royal Canin, France

Translation control

- Elisabeth Landes, DVM (German)
- Noemi Del Castillo, PhD (Spanish)
- Giulio Giannotti, BSc (Italian)
- Matthias Ma, DVM (Chinese)
- Chie Saito, DVM (Japanese)
- Boris Shulyak, PhD (Russian)

Deputy publisher: Buena Media Plus
Bernardo Gallitelli and Didier Olivreau
Address: 85, avenue Pierre Grenier
92100 Boulogne-France
Phone: +33 (0) 1 72 44 62 00

Editor-in-chief

- Ewan McNeill, BVMS, Cert VR, MRCVS

Editorial secretary

- Laurent Cathalan
lcathalan@buena-media.fr
- Jérémy Davis

Artwork

- Pierre Ménard

Printed in the European Union

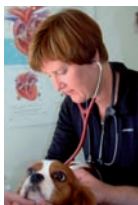ISSN 1354-0157
Circulation: 70,000 copies
Legal deposit: March 2015
Cover: Dr. Mike Davidson

Veterinary Focus is also published in French, German, Chinese, Italian, Polish, Spanish, Japanese & Russian.

The licensing arrangements for therapeutic agents intended for use in small animal species vary greatly worldwide. In the absence of a specific license, consideration should be given to issuing an appropriate cautionary warning prior to administration of any such drug.



Chronic valvular disease in dogs



■ **Rebecca L. Stepien, DVM, MS, Dipl. ACVIM (Cardiology)**

University of Wisconsin School of Veterinary Medicine, Madison, Wisconsin, USA

Dr. Stepien graduated from the University of Wisconsin School of Veterinary Medicine and received her Master's degree at The Ohio State University. She has been a Clinical Professor at the University of Wisconsin since 1994 and is past president of the ACVIM Specialty of Cardiology. Dr. Stepien's research interests include myxomatous valve disease in whippets, systemic hypertension and therapy of congestive heart failure.

■ **Introduction**

Chronic valvular disease (CVD) is a common acquired heart disease in dogs, and may account for up to 75% of congestive heart failure (CHF) cases in this species. CVD, which may also be described as “degenerative valve disease”, “myxomatous valve disease” or “endocardiosis”, causes progressive thickening and malformation of the heart valve leaflets, with the mitral valve most commonly affected. In many cases, similar changes are present on the tricuspid valve.

■ **Epidemiology**

CVD is a disease of middle-aged to older dogs, although earlier onset has been noted in some breeds (e.g., Cavalier

King Charles spaniels). Although the etiology has not been ascertained in most dogs, a genetic tendency toward development of CVD has been proven in Cavalier King Charles Spaniels and Dachshunds (1,2), and a genetic basis for at least some of the changes noted is suspected in other breeds. All breeds can be affected, but the disease most commonly results in clinical signs in small and medium breeds.

■ **Pathology**

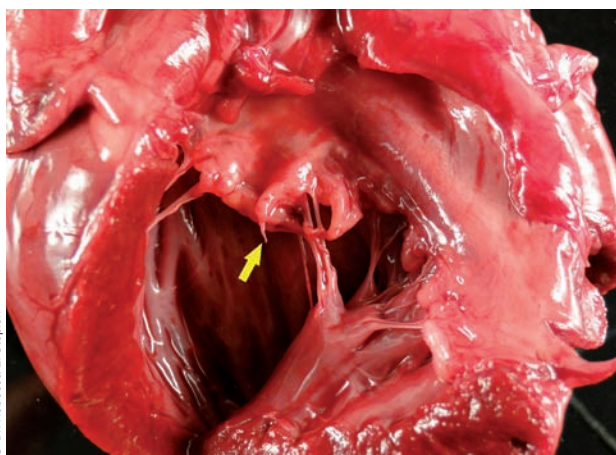
The histologic changes to the valve consist of degenerative changes in collagen (“myxomatous degeneration”) and development of valvular fibrosis. Grossly, the affected valve leaflets in patients with CVD are thickened, white to yellow in color, with nodular edges that may be curled (3). In contrast to valvular changes associated with valve leaflet infection (*i.e.*, bacterial endocarditis), the endocardial surface of the irregular valve leaflets is typically intact with a smooth surface. The degenerative changes often affect the chordae tendineae as well as the leaflet itself, and the stretching and thickening may result in chordal rupture (**Figure 1**). In the atrioventricular valves, the distortion of the leaflets caused by this remodeling results in incomplete closure of the valves, and regurgitation of blood during systole. Chronically, mitral and tricuspid regurgitation cause atrial and ventricular dilation on the affected sides of the heart. Secondary damage within the atrium may include jet lesions (roughened areas of endocardium at the point of contact with the regurgitant jet) and in some cases, partial rupture of the atrial endocardium (**Figure 2**) or complete left atrial rupture.

■ **Echocardiographic findings**

The echocardiographic appearance of CVD in dogs can be divided into anatomic and functional changes to the valve

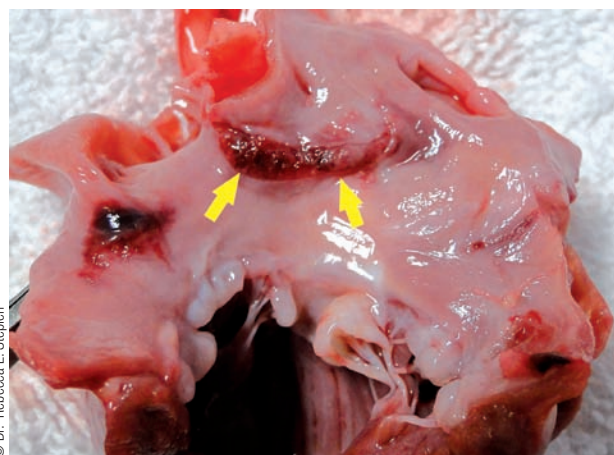
KEY POINTS

- “Endocardiosis”, “myxomatous valve disease” and “degenerative valve disease” are all terms used to describe chronic valvular disease in dogs, which is the commonest acquired canine heart disease.
- Use of the ACVIM classification system allows staging of the degree of heart disease and development of a treatment plan.
- Taking resting respiratory rates at home is an important method for monitoring chronic valve disease patients.
- Treatment of first-time congestive heart failure due to chronic valvular disease usually consists of “triple therapy”: furosemide, pimobendan and an angiotensin-converting enzyme inhibitor.



© Dr. Rebecca L. Stepien

Figure 1. View of the mitral valve leaflet from an elderly Dachshund with chronic valvular disease. Note the nodular thickening of the valve leaflets, with preserved, smooth endocardial surface. The arrow marks the previous attachment site of a ruptured chorda tendinea.



© Dr. Rebecca L. Stepien

Figure 2. Left-sided view of the heart from a Maltese Terrier showing an enlarged left atrium and thickened, nodular valve leaflets. Arrows designate a linear endocardial rupture.

leaflets/valve apparatus, and changes to the size, shape and function of the cardiac chambers that occur secondary to the volume loading due to valvular regurgitation.

Valvular changes

Changes to the anatomy include thickening of the valve leaflets with variable increases in echogenicity. The anterior mitral valve leaflet often seems to be more distorted than the posterior leaflet, and may appear to be curved or “hockey-stick” shaped when open. When closed, mitral valve prolapse may be noted, with portions of the valve leaflet ballooning backward into the atrium in systole. Mitral valve prolapse may occur as chordal structures elongate or rupture. Rupture of a more major chord may result in a “flail” mitral valve leaflet, in which an untethered edge of the leaflet flips backward into the atrium in systole, causing acute worsening of valvular regurgitation (**Figures 3 a-d**). Mitral regurgitation (MR) secondary to these anatomic changes may be documented using color-flow Doppler mapping (**Figure 4 a,b**).

Grading of the severity of the valve changes may take into account the degree of anatomic change to the valve, the presence/absence of mitral valve prolapse and flail, the size of the color-mapped mitral jet (especially at its source at the valve leaflet) and the presence of left atrial enlargement (4). With CVD of the tricuspid valve, the septal leaflet often appears to be more affected than the mural leaflet, with changes similar to the mitral valve (thickening, increased echogenicity, prolapse, **Figure 3b**). As with the mitral valve, evidence of right

atrial dilation usually indicates more severe tricuspid regurgitation.

Other echocardiographic findings

Cardiac remodeling secondary to chronic atrioventricular valvular regurgitation is common and the degree of remodeling is affected by the severity of the regurgitation. If moderate to severe MR is present, the left atrium becomes progressively dilated. The left ventricle dilates and becomes more spherical in appearance (*i.e.*, eccentric hypertrophy, **Figure 3a**). Initially, the left ventricular free wall may be mildly thickened, but later in the disease, when ventricular dilation occurs, both free wall and interventricular septum may become thinned. Moderate to severe tricuspid regurgitation results in similar changes in the right heart (**Figure 3b**).

Systolic function, as measured by fractional shortening, may appear to be increased in the moderate stages of MR; it remains unclear if these apparent beneficial functional changes are an artifact of decreased afterload or represent actual increases in systolic function (**Figure 5**). As CVD progresses and the ventricle dilates further, the fractional shortening may become normal once again; this may indicate the early stages of myocardial systolic failure. Severe MR may lead to secondary pulmonary hypertension due to chronically elevated left atrial pressure. If pulmonary hypertension is present, the right atrium and right ventricle become dilated and eventually develop systolic failure (“right heart failure secondary to left heart failure”).

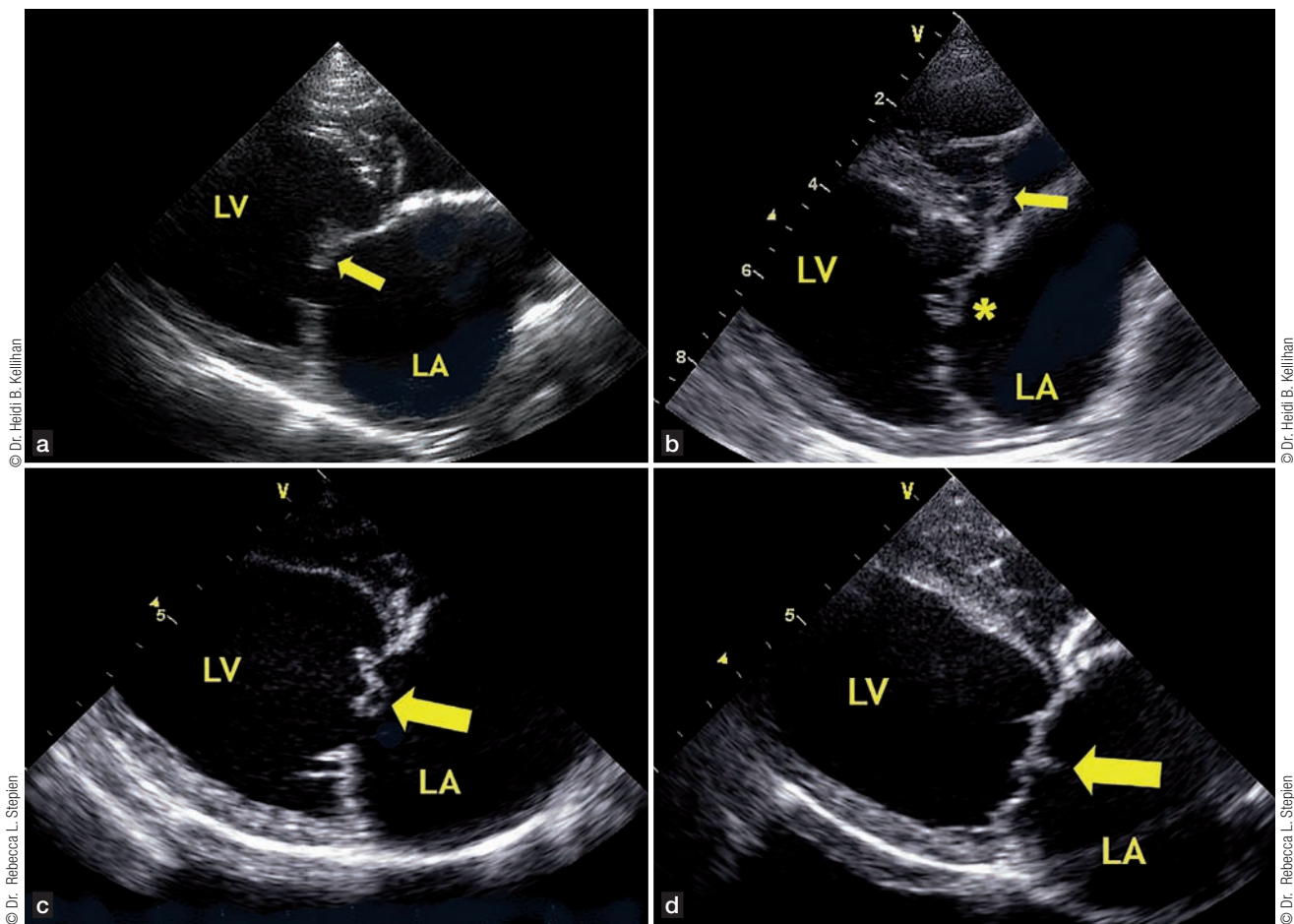


Figure 3. Echocardiographic images from dogs with chronic valvular disease, illustrating various echocardiographic features of the disease. In all figures, LA: left atrium, LV: left ventricle.

(a) Right parasternal long axis view (diastolic frame). The arrow indicates the thickened anterior mitral valve leaflet. Note globoid appearance of left atrium and ventricle, reflecting eccentric hypertrophy due to chronic volume loading.

(b) Right parasternal long axis view of the mitral and tricuspid valves (systolic frame). The arrow indicates the thickened and prolapsing septal tricuspid valve leaflet. The asterisk identifies a segment of mitral valve prolapse on the anterior mitral valve leaflet.

(c) Right parasternal long axis view of the mitral valve (end-diastolic frame). The arrow indicates a prolapsed segment of the anterior mitral valve leaflet.

(d) Right parasternal long axis view of the mitral valve (systolic frame). The arrow indicates a flailed portion of the anterior mitral valve leaflet.

■ Clinical evaluation

The American College of Veterinary Internal Medicine (ACVIM) guidelines for staging of heart disease in dogs (**Figure 6**) are a helpful guide when discussing CVD in clinical patients (5) and are a useful reference for both diagnosis and therapy of CVD, as clinical findings allow classification and thus can guide therapy.

Approach to patients at risk for development of CVD (ACVIM Stage A)

Patients at risk for development of CVD are commonly recognized to be small to medium breed, older dogs, with males more frequently affected than females. “At

risk” breeds may be presented at screening events for routine or pre-breeding evaluations. The Stage A population, *i.e.*, patients identified as “at risk” based on breed/breed type but with no cardiac abnormalities identified on physical examination, require no therapy, but the owners or breeders should be informed about the future risk of the disease, and alerted to clinical signs that may indicate development of heart disease or congestive heart failure (*e.g.*, cough, increased respiratory rate or effort, signs of fatigue). Annual physical examination and careful auscultation of breeds at risk are especially recommended for early detection of heart murmurs that may indicate the onset of CVD.

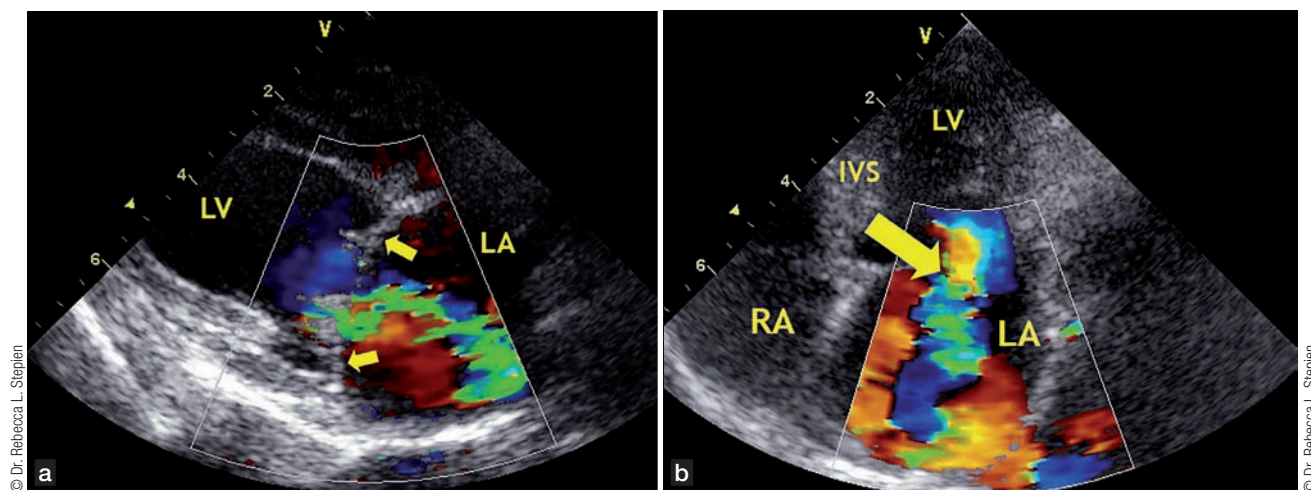


Figure 4. (a) Right parasternal long axis view optimized for the left ventricular inflow tract (systolic frame). The small arrows identify the mitral valve leaflets. The color jet in the left atrium during systole indicates the presence of mitral regurgitation. LA: left atrium, LV: left ventricle. **(b)** Left apical parasternal long axis view optimized for the left ventricular inflow tract (systolic frame). The arrow indicates the point at which the width of the mitral regurgitation jet can be assessed as an indicator of severity. LA: left atrium, LV: left ventricle, IVS: interventricular septum, RA: right atrium.

Approach to the patient with a heart murmur and no clinical signs (ACVIM Stage B1 or B2)

History

Dogs with CVD may have detectable changes on auscultation (typically, systolic murmurs) evident for 3-5 years prior to the onset of clinical signs. During these preclinical years, the patient usually has no cough, difficulty breathing, syncope or fatigue, and the murmurs are detected during routine physical examination. Some dogs in the later stages of preclinical CVD will have gallop sounds or arrhythmias (irregular heart rhythm with associated pulse deficits) detected. Pulse strength is usually normal. As cardiomegaly progresses in dogs with large airway compromise (e.g., inflammatory airway disease or bronchomalacia), a hacking, non-productive cough may develop due to impingement of the enlarged left atrium on the left mainstem bronchus. A paroxysmal, hacking, non-productive cough without changes in respiratory rate or effort in a dog suspected of having MR is usually indicative of cardiomegaly rather than CHF.

Physical examination

The most common method of detecting CVD for the first time is by identifying a heart murmur on routine physical examination. In the early stages of CVD (Stage B1 or B2), the heart rate is normal and a regular rhythm or a sinus arrhythmia may be present. The murmur of MR is usually heard best at the left apex of the heart

(where the apex beat may be palpated) and occurs during systole – confirmed when the murmur is heard simultaneously with the palpated femoral pulse. Murmurs are graded on a scale from 1-6 in dogs, with grades 1 and 2 representing soft murmurs, grades 3 and 4 representing moderate intensity murmurs and grades 5 and 6 representing the loudest murmurs. Grade 5 or 6 murmurs are accompanied by a palpable systolic “thrill” (vibration) over the area of maximal murmur intensity. In dogs with CVD the intensity of the murmur is associated with the severity of regurgitation, with murmurs of grades 4 to 6 representing more severe disease. In the case of tricuspid regurgitation (TR), a systolic murmur may be identified with the point of maximal intensity at the right cardiac apex (approximately at intercostal space 4 on the right thorax). When mitral and tricuspid regurgitation co-exist in a patient, it may be difficult to differentiate a TR murmur from the referred sound of the MR murmur. A jugular pulse with every heartbeat supports a diagnosis of hemodynamically significant tricuspid regurgitation.

Diagnostic testing in the early stages of CVD may be offered to the client with the aim of confirming the diagnosis, staging the disease severity and establishing other baseline information (e.g., serum biochemical analysis) that may become useful for comparison in the future or for establishing normal organ function if therapy is contemplated.

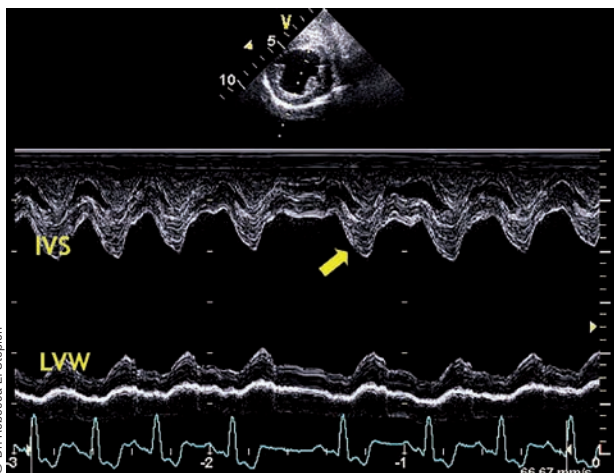
Radiography

Thoracic radiography is an essential part of evaluating the patient, allowing determination of heart size via the Vertebral Heart Score [VHS] assessment ((6), **Figure 7**) and scrutiny of pulmonary vasculature and parenchyma for evidence of pulmonary infiltrates and vascular engorgement typical of CHF. In the patient without clinical signs, the size of the heart, assessed over time, can be used to estimate the likelihood of CHF development in the near future; a VHS > 12 or an increase in VHS between visits of approximately > 0.7 VHS units/month indicates impending CHF (7,8). In patients without clinical signs, baseline radiographs may reveal a normalized heart (Stage B1 disease) or cardiac enlargement (Stage B2) that may be mild to severe. Knowledge of a patient's degree of cardiomegaly allows the clinician to educate the client as to monitoring their pet for development of signs of CHF. Patients diagnosed at Stage B1 may have no clinical signs for 2-4 years, while those with some degree of cardiac enlargement may develop signs of CHF sooner. The prognosis for CVD patients without clinical signs is fairly optimistic; 70% of preclinical dogs in one study were alive 6 years later (9).

Echocardiography

Echocardiography is not required for tentative diagnosis of CVD in its early stages if the signalment and physical examination findings in a patient without clinical signs present a picture consistent with MR and/or TR. Nevertheless, obtaining an echocardiogram at first detection of a murmur allows confirmation of the tentative diagnosis

Figure 5. M-mode echocardiographic image from a dog with mitral regurgitation. Note the exaggerated excursion (arrow) of the interventricular septum (IVS) versus that of the left ventricular wall (LVW).



of CVD. In addition, in dogs also at risk for occult dilated cardiomyopathy (e.g., large-breed dogs), echocardiography is the diagnostic test of choice to differentiate these conditions. Lastly, if unexpected clinical findings are noted (e.g., irregular heart rhythm in a dog without other clinical signs), echocardiography can provide important additional information.

Other diagnostic testing

Measurement of biomarkers, specifically NT-proBNP concentration, has been assessed in this type of patient and may be useful for identifying dogs at increased risk of development of CHF within one year (8); currently the test is not considered diagnostic in a non-clinical CVD patient but it may add information (10). Other methods can be recommended for individuals based on clinical findings (e.g., an ECG if an irregular heart rhythm is detected) or concurrent known illnesses (e.g., blood pressure measurement if renal disease is present).

Monitoring

When a patient is diagnosed with Stage B2 disease, introduction of the concept of home “resting respiratory rate” (RRR) monitoring is helpful (**Table 1**); owners can be counseled to monitor the RRR of their pet, and contact their veterinarian if the rate exceeds the normal (or the reference) range (< 25 breaths per minute) (11).

Approach to the patient with CVD and clinical signs of CHF (ACVIM Stage C or D)

History

Dogs with CVD and CHF may have had a heart murmur recognized previously but have not had any clinical signs until the CHF presentation. Alternatively, some dogs with MR will have had a dry hacking cough previously with little effect on quality of life. A recent history that should cause the clinician to suspect CHF may include varying degrees and combinations of respiratory abnormalities (increased rate and effort), fatigue or easy tiring with exercise, or (rarely) syncope. General signs of systemic illness, including weight loss and changes in behavior (*i.e.*, less playful or quieter), may be present. Note that CVD dogs with previous CHF are still considered to be Stage C since medications are required to maintain a compensated state.

Physical examination

If CHF is present (Stage C or D), heart murmurs are detected as in the early stages of disease, but other physical findings reflecting low cardiac output or fluid retention are present. For dogs with left-sided CHF,

Heart disease class	Description of affected patient	Therapeutic considerations	
A →	<ul style="list-style-type: none"> At risk for development of CVD* No current heart disease 	<ul style="list-style-type: none"> No medical therapy Screening exams Client education 	
B →	B1 →	<ul style="list-style-type: none"> CVD* is suspected based on exam No clinical signs are present No cardiac enlargement is present 	<ul style="list-style-type: none"> No medical therapy Yearly auscultation Client education
	B2 →	<ul style="list-style-type: none"> CVD* is suspected based on exam No clinical signs are present Cardiac enlargement is present 	<ul style="list-style-type: none"> Typically no medical therapy Severe enlargement: consider ACEI* If cough: cough suppressants Begin home RRR* monitoring
C →	<ul style="list-style-type: none"> CVD* is present Past or current signs of CHF* are detected 	<ul style="list-style-type: none"> Triple therapy: furosemide, pimobendan, ACEI* Consider adding spironolactone Treat arrhythmias if present 	
D →	<ul style="list-style-type: none"> CVD* is present Past or current signs of CHF* are detected 	<ul style="list-style-type: none"> Triple therapy: furosemide, pimobendan, ACEI* Spironolactone Screen for pulmonary hypertension Consider additional vasodilators (e.g., amlodipine) Treat arrhythmias if present Referral consultation 	

Figure 6. ACVIM classification system for heart disease and heart failure as applied to chronic valve disease.

*CVD: chronic valvular disease; ACEI: angiotensin-converting enzyme inhibitor; CHF: congestive heart failure; RRR: resting respiratory rate

increased respiratory effort and coughing may be noted due to pulmonary edema. In severe CHF, the patient may be cyanotic and coughing up blood-tinged white foam. Lung sounds are usually abnormal, and range from increased large airway sounds to easily detected pulmonary crackles, suggesting the presence of alveolar fluid accumulation. Ascites and jugular distention usually indicate right-sided CHF, which may be due to tricuspid CVD, development of pulmonary hypertension secondary to left-sided disease, or a combination of both. Irregular heart rhythms may accompany severe CVD with or without CHF. Common arrhythmias usually ascribed to severe atrial dilation include atrial premature complexes, atrial tachycardia or atrial fibrillation. Less commonly, CVD patients may develop ventricular ectopy.

Once CHF is suspected in a patient with a heart murmur consistent with CVD, further evaluation is required to estimate the severity of the heart failure and establish the best course of therapy. In general, thoracic radiography provides information about the presence/absence/severity of CHF, while echocardiography provides information regarding the underlying disease and the development of complications such as pulmonary hypertension.

Radiography

The initial evaluation of heart size in conjunction with findings of left-sided heart failure (*i.e.*, interstitial or alveolar pulmonary infiltrates in the presence of left atrial enlargement and pulmonary venous engorgement) in a patient with new clinical signs establishes a diagnosis of CHF and serves as a baseline for comparison once therapy is initiated (**Figure 8**). In patients with clinical signs of right-sided CHF (particularly ascites), radiography allows for screening for pleural effusion as well as assessment of right-sided cardiac structures (including pulmonary arteries) for evidence of pulmonary hypertension. Where left-sided heart disease has resulted in the development of pulmonary hypertension and subsequent right-sided heart failure, enlargement of both left and right heart structures may be present. Serial radiographs are invaluable to assess the success of therapy as well as to monitor the status of a CHF patient over time.

Echocardiography

Echocardiography at the time of diagnosis of CHF (obtained once the patient is stable) adds valuable information to the patient's record. If not previously performed, it can establish the exact anatomic/functional diagnosis

of CVD and be used to estimate the severity of disease as well as screen for complications such as pulmonary hypertension, chordae tendineae rupture or left atrial rupture. Echocardiography in CVD patients is often most helpful as a diagnostic tool at specific time points rather than a monitoring tool for the presence of heart failure over time.

Biomarkers

Serum NT-proBNP concentration may be useful to establish a diagnosis of CHF in dogs with known CVD and respiratory distress when it is not clear if the respiratory compromise is due to CHF or respiratory disease. Although there is some variability between studies in exact values, an elevated NT-proBNP concentration (e.g., > ~1000 pmol/L) is supportive of CHF as a cause of dyspnea, whereas a normal level suggests a respiratory cause for dyspnea (12). In all cases, NT-proBNP assessment should be considered supportive rather than diagnostic of cardiac disease (10).

■ Therapy for dogs with CVD

ACVIM Stage A heart disease

As noted above, patients at risk for CVD without clinical findings require no specific treatment, and no therapy has been proven to prevent or delay the onset of CVD in these patients. Screening for physical evidence of CVD (e.g., a systolic heart murmur) should be performed at each physical examination, accompanied by discussion of the risks.

ACVIM Stage B1 heart disease

As with Stage A CVD, Stage B1 patients require no specific therapy, but more owner education is essential since the disease is already present, and it is a good time to optimize the patient's weight and body condition if not already ideal. Discussion with owners about diet and exercise, as well as likely clinical signs of CVD, provides inducement for closer management and observation of their pet.

ACVIM Stage B2 heart disease

As CVD progresses, cardiac enlargement occurs and will progress at a variable rate, individual to the dog. In early Stage B2, cardiomegaly is identified via radiography or echocardiography, but may not be severe. Most cardiologists do not recommend any specific therapy at this point.

When cardiomegaly worsens, recommendations for therapy become less uniform. Important factors to consider are the degree of cardiomegaly and concurrent findings

on radiography, and the presence or absence of a cough due to mainstem bronchial compression with or without underlying large airway abnormalities. When cardiomegaly is severe and CHF seems likely in the near future, the author typically recommends initiation of angiotensin-converting enzyme inhibitor (ACEI) therapy (13). In patients with cough due to cardiomegaly, ACEI therapy, antitussive therapy (e.g., butorphanol) or a combination of the two may be used. Currently there is no proven benefit to routine initiation of pimobendan therapy at this stage.

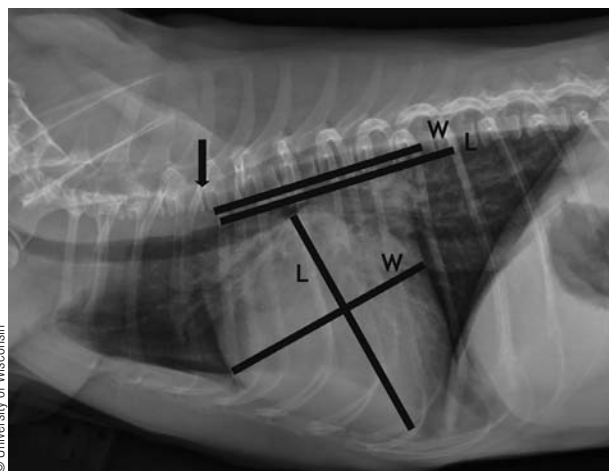
ACVIM Stage C heart disease (CHF)

The diagnosis of CHF in a dog with CVD is usually the moment when direct therapy for CHF begins. Acute therapy of the emergency patient with respiratory distress differs slightly from chronic CHF therapy (see below). Most therapy for CHF is lifelong, although the number and choice of medications, as well as dosing regimens, may change over time.

Acute CHF

Dogs with acute CHF due to CVD are usually presented in respiratory distress. Immediate oxygen therapy (e.g., oxygen cage or "blow by" oxygen supplementation) should be provided while developing a tentative diagnosis. If CHF is suspected based on history and physical examination, thoracic radiography can confirm the presence of fluid suggestive of pulmonary edema but may not be obtainable if the patient's condition is unstable.

Figure 7. Assessment of VHS (6). The length of the long axis (L) plus short axis (W) of the heart is compared to the vertebral column beginning at the cranial end of the 4th thoracic vertebral body (arrowed). Normal VHS (L + W) for dogs is < 10.5 vertebral bodies; this dog has a VHS of 11.75, reflecting moderate cardiomegaly. Elevation of the trachea is present, reflecting LV enlargement, and moderate to severe LA enlargement is present.



© University of Wisconsin

Table 1. Monitoring a dog's RRR at home can provide early warning of developing problems and allow the caretaker to assess the efficacy of medications. The following pointers may be useful.

<ul style="list-style-type: none"> • Normal RRR (with the dog at rest, not panting and not in an exceptionally warm environment) is usually ~16-24 breaths per minute. • Animals with a history of CHF that are well controlled on their medications should have a RRR < 30-32 breaths per minute.
<ul style="list-style-type: none"> • One “count” in a respiratory rate includes one inhale/exhale cycle. • Count the number of inhale/exhale cycles in 10 seconds and multiply by 6 to obtain a “breaths per minute” rate.
<ul style="list-style-type: none"> • Count the RRR daily for at least the first week to get an idea of what is normal for the dog, and log it to establish a baseline value; once established, it can be monitored at intervals set by the caretaker and recorded. • The RRR log should be taken with the dog to the next appointment to provide information regarding trends over time.
<ul style="list-style-type: none"> • Knowing their pet’s “normal” rate can help caretakers determine if the dog has a problem, e.g., if the dog looks like it is breathing rapidly or abnormally, the caretaker can count the rate immediately and compare it to the dog’s normal rate. • If the new rate is more than 10 breaths per minute higher than the dog’s usual RRR, it may indicate that there is a problem. • If the dog seems comfortable, the RRR can be rechecked in an hour, and if the increase is persistent, the veterinarian can be contacted to discuss the findings. • If the dog’s RRR is > 32 breaths per minute, if there is increased respiratory effort, or the dog appears uncomfortable, this may represent an emergency situation; the attending veterinarian or an emergency clinic should be contacted immediately.

In these cases, immediate parenteral administration of furosemide can be life-saving. Dogs that can tolerate oral medication may receive pimobendan as soon as feasible. An injectable form of pimobendan, to be administered intravenously, is available in some countries and may provide an alternative for dogs unable to be given oral medication. After initial furosemide has been administered,

the patient should be observed with minimal handling until respiratory rate and effort improve. A second parenteral dose of furosemide can be administered if no urination is observed within 30-60 minutes of injection. In very anxious patients, low doses of butorphanol can be administered SC or IM to provide very mild sedation. Dogs with significant ascites causing discomfort can have abdominocentesis performed to relieve pressure on the diaphragm that may be limiting ventilation. Some dogs will become hypotensive if the full amount of ascites is removed; removal of approximately 75% of the ascitic fluid acutely is usually tolerated. Cage rest with minimal exercise and oxygen supplementation is recommended until acute pulmonary edema has resolved.

Chronic management of CHF

Once a CHF patient has improved to the point where oxygen therapy is no longer needed, home-administered oral treatments are possible, and several medications have proven survival benefits (14-17). Left-sided congestive heart failure is initially treated with “triple therapy” (furosemide, pimobendan and ACEI), with the addition of spironolactone chronically in many patients. Of these medications, furosemide and pimobendan should be administered first and are essential for early treatment of pulmonary edema due to left-sided CHF. Once a patient is rehydrated (reliably signaled by the return of appetite), an ACEI may be administered safely. Dehydrated patients may develop pre-renal azotemia if given ACEI; in this case the drug should be stopped while the patient is rehydrated, restarting the drug once the dog is stabilized. Like ACEI, spironolactone is considered a chronic, rather than acute, therapy for CHF. Administering spironolactone as a neurohormonal blocker early in the course of chronic CHF decreases sodium and water retention and may increase survival (17). Once the patient is stable at home, a gradual return to normal exercise can be initiated, although strenuous exercise (e.g., prolonged ball-chasing, competitive sports) may not be tolerated.

ACVIM Stage D heart disease (refractory CHF)

A CVD patient that has been stable on chronic therapy may appear to become refractory to therapy over time. This presentation may include a recurrence of heart failure despite stable medications, or incomplete resolution of heart failure on triple therapy. The owners should be questioned carefully with regard to exact medication dosing, with special attention to any inadvertent lapses in administration that may have occurred. In addition, careful patient evaluation may reveal evidence of other findings suggestive of systemic disease, arrhythmia or

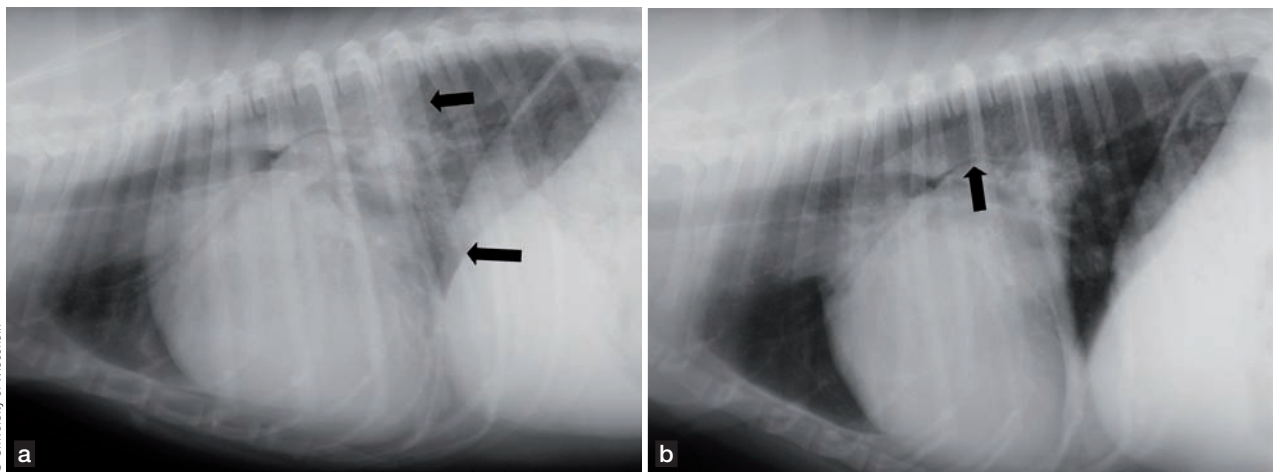


Figure 8. Left lateral thoracic radiographs obtained from a dog with Stage C chronic valvular disease. **(a)** Film obtained on emergency presentation; note significant cardiomegaly and severe, patchy alveolar infiltrates representing acute pulmonary edema (arrows). **(b)** The same patient after 48 hours's therapy with furosemide and oxygen. The pulmonary infiltrates have resolved. Note the impingement of the severely enlarged left atrium on the left mainstem bronchus (arrow).

development of complications such as pulmonary hypertension. Metabolic changes such as dehydration or hypokalemia may interfere with CHF therapy. Complications such as arrhythmias or pulmonary hypertension require diagnostic testing for full evaluation and direct therapy as necessary. If recurrence of CHF is due to progression of CVD (*i.e.*, other causes have been ruled out), additional oral arterial vasodilators such as amlodipine for further “offloading” of the left side of the heart

may be required. Animals with severe recurrent CHF may require short-term hospitalization with oxygen support and temporary use of parenteral inotropic drugs like dobutamine. Consultation with, or referral to, a specialist for management of these cases may be beneficial. A consensus paper regarding diagnosis and therapy of canine CVD has been published (5); **Table 2** sets out common drugs, usage and dosage, and a useful formulary may be found online*.

Table 2. Dosage of medications used in acute and chronic therapy of CVD in dogs.

Medication	Indications (ACVIM classification)	Actions in CVD patients	Dosage
Furosemide	Stage C/D	Diuresis in acute or chronic CHF, relief of pulmonary edema, thoracic or abdominal effusions	Parenteral: 2-4 mg/kg, q1h-6h IV/IM/SC PO: 1-6 mg/kg, q8-12h to a maximal total daily dosage of 12 mg/kg, daily
Pimobendan	Stage C/D	Positive inotrope, balanced vasodilator in acute or chronic CHF	PO: 0.25-0.3 mg/kg, q12h
Benazepril	Stage B2 Stage C/D	Preload and afterload reduction, reduction of sodium/water retention in acute or chronic CHF	PO: 0.25-0.5 mg/kg, q12-24h
Enalapril	Stage B2 Stage C/D	Preload and afterload reduction, reduction of sodium/water retention in acute or chronic CHF	PO: 0.25-0.5 mg/kg, q12h
Spironolactone	Stage C/D	Reduction of sodium/water retention in chronic CHF	PO: 1-2 mg/kg, q12h or 2 mg/kg, q24h
Amlodipine	Stage C/D	Afterload reduction in Stage D CHF	PO: 0.1-0.2 mg/kg, q12h or 0.2-0.4 mg/kg, q24h
Butorphanol	Stage B2 for cough Stage C/D	Cough suppressant, anxiolysis in acute CHF	Parenteral: 0.1-0.5 mg/kg, IV/IM/SC PO: 0.5-1.0 mg/kg, q4-6h

■ Dietary considerations for valvular disease patients

Dietary recommendations for canine patients with chronic valvular heart disease continue to evolve. Previously, diets with severe sodium and protein restrictions were commonly discussed for these patients, but more recent considerations suggest that diets with high quality protein and moderate sodium restriction, along with supplementation of omega-3 fatty acids, are likely to be helpful to manage chronic disease. Omega-3 fatty acid supplementation, delivered separately or as part of a commercial diet, is thought to have beneficial effects in dogs both before heart failure occurs (18) and during clinical heart failure (19), likely due to the anti-inflammatory and anti-cachexia effects of these essential fatty acids (20). Feeding a diet with moderate sodium restriction and enhanced with omega-3 fatty acids and amino acids like taurine and carnitine may be beneficial even in early valvular disease (Stage B) before congestive heart failure occurs (18).

■ Prognosis for CVD

The clinical course of canine CVD is unpredictable, especially in the early stages. Although clients should be

informed about the disease and possible clinical signs at the time a diagnosis of heart disease is made (e.g., at the time a murmur is detected), they should also be informed that many dogs with CVD will never develop CHF. The disease tends to be progressive over time, but the rate of progression is individual to the dog. The amount of time to onset of CHF, if it occurs, is also related to how early the disease is detected; animals with very soft (\leq grade 2/6) murmurs of MR and no cardiomegaly usually remain free of clinical signs longer than those with loud (\geq grade 4/6) murmurs or cardiomegaly at diagnosis. Overall, preclinical CVD dogs may remain without clinical signs of CHF for 2-4 years (9,21,22).

Once CHF occurs, survival depends on choice of therapy (14,15), but other factors have an impact. Dogs whose owners monitor them closely and notice problems early, and dogs that tolerate the medications easily tend to survive longer and have better quality of life. In general, dogs treated optimally with triple therapy can be expected to live approximately 6-18 months post-CHF.

* <http://cardiaceducationgroup.org/resources/ceg-formulary>.

References

- Swenson L, Häggström J, Kvarn C, *et al.* Relationship between parental cardiac status in Cavalier King Charles spaniels and prevalence and severity of chronic valvular disease in offspring. *J Am Vet Med Assoc* 1996;208:2009-2012.
- Olsen LH, Fredholm M, Pedersen HD. Epidemiology and inheritance of mitral valve prolapse in Dachshunds. *J Vet Int Med* 1999;13(5):448-456.
- Fox PR. Pathology of myxomatous mitral valve disease in the dog. *J Vet Cardiol* 2012;14(1):103-126.
- Chetboul V, Tissier R. Echocardiographic assessment of canine degenerative mitral valve disease. *J Vet Cardiol* 2012;14(1):127-148.
- Atkins C, Bonagura J, Ettinger S, *et al.* Guidelines for the diagnosis and treatment of canine chronic valvular heart disease. *J Vet Int Med* 2009;23(6):1142-1150.
- Buchanan JW, Bücheler J. Vertebral scale system to measure canine heart size in radiographs. *J Am Vet Med Assoc* 1995;20(2):194-199.
- Lord P, Hansson K, Kvarn C, *et al.* Rate of change of heart size before congestive heart failure in dogs with mitral regurgitation. *J Small Anim Pract* 2010;51(4):210-218.
- Reynolds CA, Brown DC, Rush JE, *et al.* Prediction of first onset of congestive heart failure in dogs with degenerative mitral valve disease: The PREDICT cohort study. *J Vet Cardiol* 2012;14:193-202.
- Borgarelli M, Savarino P, Crosara S. Survival characteristics and prognostic variables of dogs with mitral regurgitation attributable to myxomatous valve disease. *J Vet Cardiol* 2008;22:120-128.
- Oyama MA. Using cardiac biomarkers in veterinary practice. *Vet Clin North Am: Small Anim Pract* 2013;43:1261-1272.
- Rishniw M, Ljungvall I, Porciello F, *et al.* Sleeping respiratory rates in apparently healthy adult dogs. *Res Vet Sci* 2012;93:965-969.
- Oyama MA, Rush JE, Rozanski EA, *et al.* Assessment of serum N-terminal pro-B-type natriuretic peptide concentration for differentiation of congestive heart failure from primary respiratory tract disease as the cause of respiratory signs in dogs. *J Am Vet Med Assoc* 2009;235(11):1319-1325.
- Atkins CE, Brown WA, Coats JR, *et al.* Effects of long-term administration of enalapril on clinical indicators of renal function in dogs with compensated mitral regurgitation. *J Am Vet Med Assoc* 2002;221(5):654-658.
- Häggström J, Boswood A, O'Grady M, *et al.* Effect of pimobendan or benazepril hydrochloride on survival times in dogs with congestive heart failure caused by naturally occurring myxomatous mitral valve disease: The QUEST study. *J Vet Int Med* 2008;22(5):1124-1135.
- Ettinger SJ, Benitz AM, Ericsson GF. Effects of enalapril maleate on survival of dogs with naturally acquired heart failure. The Long-term Investigation of Veterinary Enalapril (LIVE) Study Group. *J Am Vet Med Assoc* 1998;213:1573-1577.
- BENCH Study Group. The effect of benazepril on survival times and clinical signs of dogs with congestive heart failure: Results of a multicenter, prospective, randomized, double-blinded, placebo-controlled, long-term clinical trial. *J Vet Cardiol* 1999;1(1):7-18.
- Bernay F, Bland JM, Häggström J, *et al.* Efficacy of spironolactone on survival in dogs with naturally occurring mitral regurgitation caused by myxomatous mitral valve disease. *J Vet Int Med* 2010;24(2):331-341.
- Freeman LM, Rush JE, Markwell PJ. Effects of dietary modification in dogs with early chronic valvular disease. *J Vet Intern Med* 2006;20(5):1116-1126.
- Freeman LM, Rush JE, Kehayias JJ, *et al.* Nutritional alterations and the effect of fish oil supplementation in dogs with heart failure. *J Vet Intern Med* 1998;12(6):440-448.
- Freeman LM. Beneficial effects of omega-3 fatty acids in cardiovascular disease. *J Small Anim Pract* 2010;51(9):462-470.
- Atkins CE, Keene BW, Brown WA, *et al.* Results of the veterinary enalapril trial to prove reduction in onset of heart failure in dogs chronically treated with enalapril alone for compensated, naturally occurring mitral valve insufficiency. *J Am Vet Med Assoc* 2007;231(7):1061-1069.
- Kvarn C, Häggström J, Pedersen HD, *et al.* Efficacy of enalapril for prevention of congestive heart failure in dogs with myxomatous valve disease and asymptomatic mitral regurgitation. *J Vet Int Med* 2002;16(1):80-88.

Osteoarthritis in cats



■ **Elizabeth LaFond, DVM, Dipl. ACVS, Dipl. ACVSMR, CCRP**
University of Minnesota College of Veterinary Medicine, St Paul, Minnesota, USA

Dr. LaFond is associate professor of small animal surgery and director of small animal rehabilitation services at the University of Minnesota College of Veterinary Medicine. A Diplomate of the American College of Veterinary Surgeons and the American College of Veterinary Sports Medicine and Rehabilitation, she has a special interest in rehabilitation medicine and is past president of the International Association for Veterinary Rehabilitation and Physical Therapy. She received her veterinary degree from the University of Minnesota and her specialty surgery training at Purdue University.

■ Introduction

Arthritis is a general term used to refer to inflammation of the joints from any cause. Osteoarthritis (OA) is a form of chronic joint inflammation specifically caused by progressive and permanent deterioration of joint cartilage, and is a term often used interchangeably with degenerative joint disease (DJD). The reference to OA as a “non-inflammatory” arthritis stems from the rationale that inflammation is not a key feature of OA. However, the inflammatory component of OA is present and should not be ignored, since many of the components of a management program for treating the disease focus on modulating the associated inflammation. Because the propagation of the inflammatory vs. non-inflammatory terminology can be confusing it is best avoided; **Figure 1** sets out a classification.

Primary OA is an idiopathic disease that occurs without an identifiable initiating factor and currently represents most of the feline cases (1). With secondary OA, an underlying cause such as a joint malformation or evidence of trauma involving the joint is apparent; one example that has been described in cats is hip dysplasia (2). This paper will focus on osteoarthritis of both primary and secondary etiologies, as the clinical features and approach to management are similar.

■ General considerations

Osteoarthritis is one of the most prevalent diseases in companion animals. Cats over six years of age have a reported radiographic prevalence of OA of up to 61% using a random screening method and up to 90% of cats over 12 years of age have degenerative changes in one or more joints. The most consistent predictor of OA is increasing age (1,3).

Osteoarthritis develops secondary to trauma or malformations because of the abnormal forces that occur in the joint. Cartilage and other periarticular tissues undergo damage and stress, and lead to further disruption in joint continuity. The body responds to these abnormal forces by laying down new tissue in an attempt to stabilize the joint, leading to the bony proliferation seen radiographically.

■ Clinical presentation/diagnosis

A complete history and whole-body physical examination with appropriate work-up are important to establish a diagnosis of OA, to rule out other conditions that can cause similar signs, and to establish a baseline database prior to treatment. Cats are well known for their propensity to avoid display of signs associated with discomfort or deficiencies, therefore diagnosis of clinical disease can be challenging.

KEY POINTS

- Historical findings based on careful owner interview provide the most useful information to establish a diagnosis of clinically relevant osteoarthritis.
- Physical exam findings commonly seen in other species, such as lameness and joint crepitus, may not be key features in arthritic cats.
- There are few medications licensed for long-term use in cats with osteoarthritis, but various drugs can be used to treat the condition.
- A multimodal approach to management of osteoarthritis in cats provides best results and can consist of medication, diet and supplements, environmental enhancement, and physiotherapy.

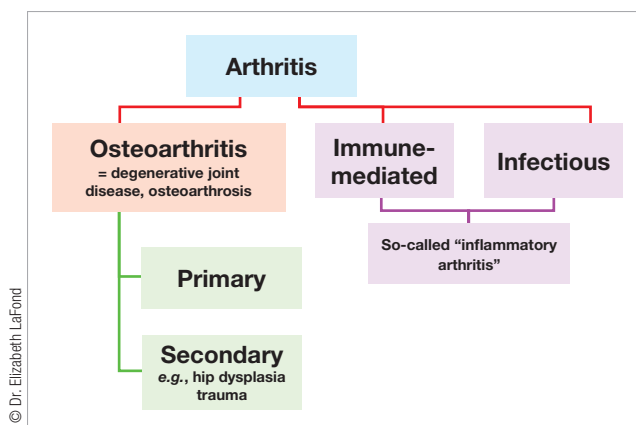


Figure 1. Flow chart depicting classifications of arthritis.

History

The importance of historical information and owner assessment of activity for establishing a diagnosis of OA has become clear in the last decade (4-6). Patients are often reported to be less active and owners may note things that suggest a change in, or difficulty with, mobility, such as the cat being less likely to jump or perch in their “favorite” elevated spot; having accidents outside the litter box; or being less playful and interactive. Other signs may include increased irritability, difficulty grooming, and a stiff-legged gait. While acute exacerbation of signs can occur and must be managed, the history is usually insidious and gradually progressive over months or years. Lists of questions for owner interview have been suggested to aid the feline practitioner (1,7).

General physical examination

Although OA is an orthopedic disease, a general physical exam plays a critical role in disease management. Many signs of OA in cats are non-specific and may be consistent with non-OA related diseases (Figure 2); for example, polyneuropathies secondary to diabetes mellitus and hyperthyroidism. Additionally, affected cats are often older and co-morbidities are not uncommon. A complete understanding of the patient’s health status will be important as therapies are considered and initiated.

Orthopedic examination

For most species, one of the first steps for orthopedic examination is gait evaluation, either with the patient directed on leash or while observing spontaneous ambulation during the history-gathering phase of examination. A thorough gait exam can be a challenge in cats, however, as most are reluctant to walk on leash and they often react to new situations by hiding in corners or crawling under anything they can find. It may be for this

reason that historical information appears to better correlate with clinical OA than physical exam findings (4-6,8). Nonetheless, thorough orthopedic examination should be performed to aid the diagnosis, localize involved joints, and rule out other causes of clinical signs. It is important to allow the cat to acclimatize to the environment and encourage it to move about freely to facilitate gait evaluation. Video capture is readily available these days, and many owners can obtain relatively high quality videos using a smart phone or camera. The advantage of this strategy is that owners can catch the cat in a relaxed state in their normal environment, and it is especially useful for animals that are not able to adapt to the exam room environment.

Following gait examination, palpation of all bones and joints is performed. A common feature of OA in cats is periarticular thickening, which may be most notable in the elbow and stifle joints. Patients are variably uncomfortable when one or more joints are manipulated and decreased range of movement may be noted. In contrast to dogs, lameness and crepitus are not major findings in cats with OA, although they can be a helpful indicator when identified (1,9).

Radiographs

Radiographic evaluation is a cornerstone for diagnosis of osteoarthritis in any species. That said, it is widely recognized that there is poor correlation between radiographic changes and clinical signs seen. Up to 61% of cats six years of age or more radiographed for any reason had signs of OA in one or more joints and the prevalence of degenerative changes increased significantly with age (6,9,10).

Typical abnormalities seen on feline radiographs that are consistent with OA include osteophytosis, subchondral sclerosis, changes in joint congruency and soft-tissue swelling (7). A distinctive feature in affected cats is the relatively common finding of ossicles and soft tissue mineralization (Figure 3). This mineralization, which can provide a dramatic appearance to radiographs, can be intra-capsular, extracapsular or synovial (1) (Figure 4).

Additional diagnostics

Supplementary diagnostic tests that can be employed when history, physical examination and radiographs do not adequately narrow down the diagnosis include joint-fluid analysis (including culture when indicated), advanced imaging such as computed tomography (CT) and magnetic resonance imaging (MRI), and nuclear

scintigraphy. For most cases these advanced techniques are not necessary.

■ Assessing the data

If radiographic evidence of OA is highly prevalent in clinically normal cats, and cats are notorious for hiding signs of pain, how can we tell whether OA is a significant enough contributor to pain that it warrants treatment? Chronic pain is a maladaptive process that is detrimental to patient well-being. Research suggests that, in addition to the direct pain of damaged tissue, chronic pain leads to development of “wind-up”, a neurological phenomenon that may need to be addressed differently than the well-recognized inflammatory aspects of OA pain (11). Given that cats are notorious for hiding their discomfort, it is likely that the degree of pain experienced by cats with OA is underestimated (12).

■ Treatment and management options

A comprehensive approach to management of OA in any species can be boiled down to five components: medication; dietary supplements and nutraceuticals; physical medicine; weight control; and monitoring. Employed together, these strategies provide a multimodal approach to therapy, providing the advantage that no one strategy needs to be depended upon entirely in order to effect change. In the case of medications, lower doses often suffice when coupled with other methods of pain control, thereby lessening detrimental side effects. Furthermore, as noted above, there are varying components to chronic pain (e.g., inflammation-induced pain and neurologic pain associated with “wind-up”) and all components must be addressed in the treatment protocol to be effective.

Figure 2. A sixteen-year-old cat with osteoarthritis of the stifles, hips and lumbar spine. Note the unkempt haircoat and plantigrade stance, but these are non-specific signs and may be also be consistent with non-OA related diseases.

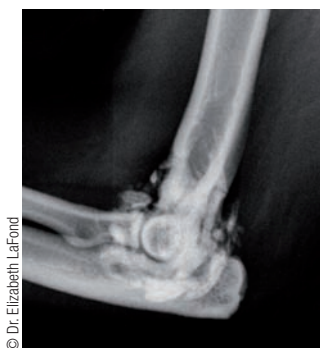

Figure 3. Lateral radiographic projection of the elbow of a cat with OA. Note the extensive mineralization within the soft tissues immediately surrounding the joint margins.

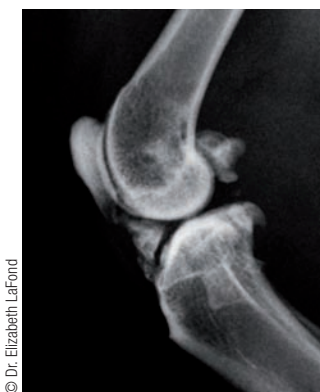

Figure 4. Lateral radiographic projection of the stifle of a cat with OA. This cat also had a history of medial patellar luxation. Note the triangular shaped mineralization within the craniomedial aspect of the joint; this may represent meniscal mineralization or mineralization of the synovium.

Because of differences in metabolism, behavior and lifestyle, this multi-faceted approach will look different in cats than it does in other species treated for OA. A balance needs to be struck between “thinking outside the cat box” and maintaining awareness of what is and is not known about the treatment options that are currently available.

Medications

Osteoarthritis is a long-term disease and the chronic pain associated with it must be managed – it cannot be cured. This means that whatever treatments are employed, they must be effective and safe for long-term use. Because there are few medications specifically approved for long-term use in the cat, it is common for clinicians to prescribe “off-label”, making it even more important that they are familiar with medication profiles (**Table 1**). It has been postulated that the lack of licensed medications may prevent clinicians from treating painful cats at all (12).

NSAIDs

Non-steroidal anti-inflammatory medications (NSAIDs) are a cornerstone of therapy for management of osteoarthritis in many species, and there is an increasing body of evidence for the effectiveness of NSAIDs for treating

Table 1. Medications that have been described for at-home chronic use in cats with OA*.

Medication	Dosage regimens	Duration	Notes
NSAIDS			
Acetylsalicylic acid	1-25 mg/kg PO q72h ¹	Off-label	All use is off-label for cats
Ketoprofen	1 mg/kg PO q24h ¹²	Up to 5 days	Chronic use is off-label for cats
Meloxicam	0.1 mg/kg PO day 1, then 0.05 mg/kg PO q24h	Indefinite (Europe and UK only)	A lower dose of 0.01-0.03 mg/kg PO q24h has been shown to be effective and may be preferred ^{13,14,15} Chronic use in cats is off-label in many countries
Piroxicam	0.3 mg/kg PO q24h ¹⁶	Off-label	Used most often for adjunctive treatment of neoplasia
Robenacoxib	1 mg/kg PO q24h ¹²	Up to 6 days	Chronic use is off-label
Tepoxalin	12 mg/kg PO q24h ¹⁵	Off-label	One study comparing tepoxalin and low dose meloxicam suggested both may be effective ¹⁵ All use is off-label for cats
Other medications			
Amantadine	3-5 mg/kg PO q24h ¹⁶	Off-label	NMDA antagonist. May be useful for chronic pain by addressing “wind-up”
Amitriptyline	2.5-12.5 mg/cat PO q24h ¹⁶	Off-label	Tricyclic antidepressant. Rationale for use with OA pain is uncertain, but may aid in addressing neuropathic pain
Buprenorphine	0.01-0.03 mg/kg q8-12h trans-buccally ¹⁶	Off-label	Limited effectiveness alone for OA-related pain. May be most useful for episodes of “break-through” pain
Fentanyl	12.5-25 mcg/h transdermal patch q4-5d ¹⁶	Off-label	Limited effectiveness alone for OA-related pain. May be most useful for episodes of “break-through” pain
Gabapentin	5-10 mg/kg PO q8-12h ¹⁶	Off-label	Anticonvulsant that is also used for chronic neuropathic pain. Rationale for use with OA pain is uncertain, but may aid in addressing neuropathic pain secondary to this chronic condition
Tramadol	2 mg/kg PO q12h ¹⁶	Off-label	Synthetic opioid-like medication. Limited effectiveness alone for OA-related pain. May be most useful for episodes of “break-through” pain. Very little data in cats.

*Note that licensing regulations differ among countries and the clinician should refer to local regulatory bodies before employing any of the regimens listed above.

OA in cats (12,13). The rationale behind using NSAIDs for treatment of pain associated with osteoarthritis is sound; the inflammatory effects of prostaglandins that contribute to OA pain are blocked by inhibiting the breakdown of arachidonic acid, which serves as the source for these inflammatory mediators. There are important, albeit perhaps subtle, species differences in the role that the cyclooxygenase (COX) isoenzymes (COX-1 and COX-2) play in inflammatory processes and normal physiological functions (12), and because of this, the optimal relative modulation of the COX-1 and COX-2 enzymes in various species is not definitively established. Deficiencies in glucuronidation pathways in the cat that aid in the metabolism of NSAIDs may be responsible for prolonging the half-life of some NSAIDs and explain why they seem to be riskier in cats than other species, although some newer NSAIDs are metabolized by oxidation (12).

There are many NSAIDs available on the market but safety and efficacy studies in cats are generally scarce. Meloxicam is the NSAID most thoroughly studied in cats and is the only one approved for long-term use in cats in some countries – many countries have no drug licensed for long-term use – and there is evidence of a positive effect of long-term, low-dose treatment (13). Reports of life-threatening renal side effects associated with the use of NSAIDs in the cat lead many clinicians to shy away from using these drugs for a prolonged period.

A recently published comprehensive consensus statement regarding use of NSAIDs in cats (12) states that they “have a major role to play in the management of chronic pain in cats...”, but cautions that limited feline-specific data is available. The bottom line recommendation is that it is advisable to use NSAIDs to help manage

OA based on their function and efficacy, but the lowest effective dose (often lower than manufacturer-published doses) should be used. Regardless of the drug chosen, appropriate systemic evaluation including CBC, serum chemistry, and urinalysis should be performed prior to initiation of treatment, and client education handouts for use with patients prescribed NSAIDs are useful*.

Other medications

Because of the concerns surrounding long-term management of cats using NSAIDs, alternate medications have become increasingly popular for chronic use in cats. It is important to note that use of these medications, especially for prolonged periods, is often off-label as well.

Opioids and similar drugs can provide safe and effective pain relief in older animals. However, they are not the most effective pain relievers for OA and their most appropriate use in patients with chronic OA is likely for “break-through” pain or for short duration when performing tests for diagnosis. Buprenorphine is probably the most extensively used opioid in cats, with the preferred method of administration being IM or IV. The subcutaneous route does not provide adequate effect, although the development of an extended-release formulation for subcutaneous injection shows promise. The trans-buccal route has been found to be inconsistently absorbed (17), limiting the drug’s utility for home use.

Tramadol is an opioid-like drug that has become increasingly popular in small animal medicine, but there appears to be considerable variation in how it affects different animals and information on its use in cats is anecdotal at best. Additional studies are necessary before it can be recommended on a regular basis. In addition the risk of abuse means that it is now a scheduled drug in many countries.

Gabapentin is a drug that may be most useful to treat neuropathic pain. Developed initially as an anticonvulsant, it has been used more and more frequently for chronic pain in small animals. Anecdotally, positive results are reported, although studies do not support these conclusions.

There is some evidence that blockage of NMDA receptors may be an effective approach to wind-up pain that has been demonstrated in cats with OA, leading to an interest in using drugs such as amantadine (11). However, clinical data are lacking. Glucocorticosteroids are not recommended for chronic treatment of OA owing to the

detrimental effect on cartilage and long-term side effects. Additionally, as with NSAIDs, the deficiency of glucuronidase pathways in cats suggests a need for caution if they are used.

Dietary supplements and nutraceuticals

A number of dietary supplements have been studied for use in dogs and other species to modulate signs associated with OA. In a recent comprehensive review of studies of nutraceuticals in dogs, cats and horses, there was only one reliable report specific to cats identified and, although a beneficial effect of omega-3 fatty acids was noted, the authors cautioned against drawing strong recommendations based on one study (18).

There are a number of commercial therapeutic diets available for management of OA. These diets contain variable amounts of omega-3 fatty acids, glucosamine and chondroitin, or green-lipped mussel extract, generally at lower doses than when these substances are supplemented individually (19). The optimal concentrations of some of these compounds have not always been defined.

Physical medicine

Physical medicine, including physiotherapy techniques and modalities, as well as environmental enhancement, is becoming recognized as a more and more important component of OA management in all species. In cats, given the paucity of reliable and practical medication options, this option is particularly attractive and should play a major role in any OA management program.

Environmental enhancement

Relatively simple changes to the environment can be very effective in helping to manage chronic pain. Recommendations that should be considered include providing multiple litter pans that allow easy (low-sided) access, padded areas that are easily reachable to a cat that may not be able to jump normally, heated beds, ramps or steps to access “perches”, and food and water in multiple locations in the house to encourage mobility (7).

Physiotherapy

There is growing evidence of the positive effect that many physiotherapy techniques have for the treatment of OA. However, there are very little feline-specific data and most recommendations are extrapolated from information in humans and dogs. We know there are significant species differences, but many of the therapies are based on modulation of physiologic tissue

* www.catvets.com/guidelines/practice-guidelines/nsaids-in-cats

CASE 1

A sixteen-year-old male neutered domestic short hair cat had a two-year progressive history culminating in a reluctance to sit, difficulty climbing onto things and intermittent defecation outside his litter box. The owner noted that he seemed to have changed his normal sleeping pattern, choosing to sleep in a space closer to the floor rather than his normal “perch”. He also avoided the stairs and other objects he used to frequent and was perhaps less interactive with humans, the other cat and the two boisterous dogs in the household.

On physical examination the cat weighed 4.3 kg and had a body condition score of six out of nine (4-5 is normal). He was well hydrated, had a normal hair coat, but had mild calculus and gingivitis. The remainder of his general exam was unremarkable. He was observed walking across the examination room with an abnormally stiff gait, best described as a rear limb shuffling with exaggerated movement of his hips and a partially plantigrade stance (**Figure 2**). Manipulation of bones and joints revealed palpable thickening of both stifle joints, and an equivocal pain response on hyperextension of the stifles, elbows and hips. There was no crepitus palpable in any joint. Recommended testing to rule out metabolic causes for the signs seen included a complete blood count, serum chemistry profile, urinalysis and T_4 analysis. The only significant finding noted on these tests was a urine specific gravity (USG) of 1.022. Radiographs of the hips and stifles revealed mild to moderate degenerative changes in all appendicular joints imaged.

Management options were discussed with the owner, including an emphasis on a multimodal approach and a commitment to follow-up monitoring. Suggestions for environmental enhancement included moving his favorite cat bed to a ground floor location and establishment of a “cat-only” accessible area of the house, low-sided litter pans and plenty of padded bedding. Following an initial two-week period of strict rest, controlled activity was encouraged by providing access to an area of the house separate from the other animals, and with sleeping and eating areas away from each other. Options for systemic medication were discussed and treatment with meloxicam (0.02 mg/kg q24H PO) was commenced, along with a weight loss program and a joint supportive diet to supplement the environmental enhancements.

At the recheck visit 3 weeks following initial evaluation, the owner reported improved mobility and more frequent positive interaction with other household members. The

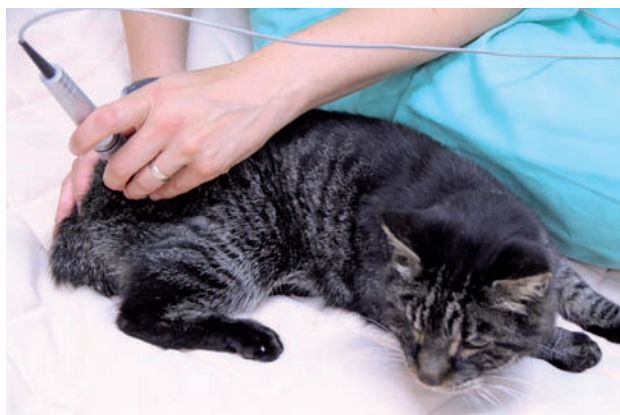renal panel and urinalysis were unchanged, and medication and environmental enhancement were continued as previously prescribed with a recommendation for follow-up every 6 months.

Three months later, the cat was evaluated because he was acutely lame on the right hind limb following a particularly active episode with one of the household dogs. A diagnosis of pain exacerbation associated with OA was made and a 5-day regimen of buprenorphine at 0.02 mg/kg q24H trans-buccally was prescribed to treat this “break-through” episode of pain.

During routine follow-up 12 months later, the clinical signs were noted to have returned on a more consistent basis. General and orthopedic physical assessments were similar to the previous examinations, with the exception of increased palpable thickening in the stifle joints, and a more marked pain response with stifle, hip and shoulder hyperextension bilaterally, and lumbar spine hyperesthesia. Body condition score was 4-5 out of 9 and the weight was 3.8 kg. Screening bloodwork (CBC, serum chemistry profile, T_4) was unremarkable and the USG was 1.019. The management regimen was continued with minimal modifications to the environmental enhancement. Gabapentin and laser therapy were instituted as adjunctive treatment, with laser therapy focusing on the hip and stifle joints (**Figure 5**).

This case illustrates the thought process required to rule out conditions that may mimic signs seen with OA, and the multimodal and dynamic approach required for life-long management of this condition.

Figure 5. Low level laser therapy may be used as adjunctive treatment for osteoarthritis.



© Dr. Elizabeth LaFond

healing processes that cross species. In general, joint motion is necessary to enhance joint health by improving movement of synovial fluid throughout the intracapsular space.

The goals of treating OA in any species using physiotherapy methodologies are to manage chronic pain, optimize function and joint range of motion (ROM), and maintain or regain normal activity (20). Cold therapy can be used during acute inflammation (“flare-ups”) or after exertional sessions of therapy. Low-impact exercises and activities help to improve muscle and joint tissue strength and health while minimizing harmful or painful stresses on the joints. Cats are often resistant to leash walking, so alternative techniques such as providing distance between food and toileting areas of the house can be used to encourage relatively controlled movement. Therapeutic exercises can be developed to achieve various levels of enhancement of joint ROM, muscle strengthening and proprioception.

Some cats can be acclimated to water therapy, which provides a number of beneficial aspects for OA treatment. The buoyancy of the water provides support for animals that are uncomfortable supporting their own weight. Swimming action and underwater treadmill walking have been shown to alter the active range of motion of joints, which can aid in maintaining joint function. Water temperature can be controlled so that tissues can be heated to increase elasticity and comfort (20).

Additional treatment options that may have a place in the management of OA in cats based on evidence in other species include acupuncture, extracorporeal shock-wave therapy, therapeutic ultrasound, low-level laser

therapy, and electrical stimulation, although again there is a paucity of cat-specific evidence (21).

Weight control

Although the relationship between DJD and weight is clear in dogs, a correlation between obesity and painful OA in cats has not been established, and in one study only 14% of older cats with painful OA were obese (6). That said, it is likely that obesity in the older cat contributes to the clinical problem by causing a mechanical overload of the diseased joints. Additionally there is increasing evidence in humans that fat may contribute to synovial inflammation and chondrocyte damage. With these points in mind, it is logical to ensure general weight management is an integral part of managing the cat with clinical OA.

Monitoring

Re-evaluation at regular intervals serves multiple purposes: to monitor for any adverse effects of therapies; to assess for response to treatment; and to modify therapies as appropriate as the disease progresses.

Because of the known potential for side effects of NSAIDs, reassessment (at minimum via phone interview) is recommended 5-7 days following the initiation of treatment with NSAIDs, and re-examination and minimum blood testing for renal and hepatic evaluation 2-4 weeks after initiation of treatment (12). Additional follow-up can vary based on perceived risks and other factors; because affected cats are often old, re-evaluation is recommended even when alternative medications are used to ensure tolerance. Response to treatment can be a valuable diagnostic tool and can help a practitioner to verify the diagnosis as well as determine whether further investigation is warranted.

CASE 2

A six-year-old female spayed domestic shorthair cat had a history of bilateral grade 2 medial patella luxation (MPL) and cranial cruciate ligament (CCL) insufficiency. Surgery to correct the MPL and CCL insufficiency on the right stifle had been performed at the age of two (tibial tuberosity transposition, trochlear sulcoplasty, lateral anti-rotation and imbrication). The left MPL was managed medically. The cat had

developed a left hindlimb lameness and progressive difficulty jumping. On physical examination, the cat weighed 4 kg and had a body condition score of 4 out of 9, and was systemically healthy. Radiographic evaluation of the left stifle revealed severe OA and grade 4 medial patella luxation (**Figure 4**). Surgical correction similar to the right was performed for the left stifle, although the CCL was intact.

Because of the young age of the animal and the need to manage the cat’s residual OA for many years, physiotherapy, weight management and dietary supplementation was emphasized over medications. This case illustrates the fact that young cats can also suffer from OA, and that an underlying cause is often involved. Identification and correction of the primary cause is important.

OA is a progressive disease and therapies that are effective on day one may not work after a few months or years. Additionally, the lowest effective dose of medications, especially NSAIDs, is ideal in order to minimize potential adverse side effects. As is the case for the initial diagnosis, one of the most useful and practical tools is the owner interview; there is evidence that owner reports of activity at home may be more sensitive than periodic veterinarian evaluation (14), although repeat orthopedic examinations are recommended.

Additional tools for monitoring the progression of OA and the effectiveness of treatment include pressure platform gait analysis and the use of collar-mounted accelerometers. These techniques have been most often employed in the research setting, but owing to advances in technology, and decreasing cost, they may be more readily available in the clinical setting than in the past.

Surgery

For some cats with OA, surgery may be indicated. If the OA is secondary to a correctable disease process the

appropriate surgery is dependent on the underlying problem and may necessitate continued medical management of OA. Salvage procedures have also been described for management of OA and are aimed at removing or rendering motionless the painful tissues within the joint. Femoral head and neck excision for OA in the hip is the most common procedure, although total joint replacement and arthrodesis are also options. These procedures are not as commonly indicated in cats as in larger species, however, owing to their smaller size.

Summary

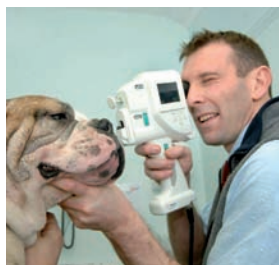Osteoarthritis is increasingly recognized as an important and treatable condition in cats. Research suggests that careful owner interview may be the most useful tool for diagnosis and monitoring. While there is only a small body of literature addressing OA in cats specifically, the list is growing and, coupled with a sound approach and understanding of benefits and limitations of extrapolating information from other species, the feline practitioner can effectively identify and monitor cats with OA.

References

- Bennett D, Ariffin SMBZ, Johnston P. Osteoarthritis in the cat: 1. How common is it and how easy to recognise? *J Fel Med Surg* 2012;14:65-75.
- Langenbach A, Green P, Giger U, *et al.* Relationship between degenerative joint disease and hip joint laxity by use of distraction index and Norberg angle measurement in a group of cats. *J Am Vet Med Assoc* 1998;213:1439-1443.
- Lascelles BD. Feline degenerative joint disease. *Vet Surg* 2010;39:2-13.
- Klinck M, Frank K. Owner-perceived signs and veterinary diagnosis in 50 cases of feline osteoarthritis. *Can Vet J* 2012;53:1181-1186.
- Gruen ME, Simpson W, Lascelles BD. Owner-assessed indices of quality of life in cats and the relationship to the presence of degenerative joint disease. *J Fel Med Surg* 2012;14:863-870.
- Clarke SP, Bennett D. Feline osteoarthritis: a prospective study of 28 cases. *J Small Anim Pract* 2006;47:439-445.
- Caney S. How I approach... Feline arthritis. *Vet Focus* 2007;17.3;11-17.
- Benito J, Hansen B, DePuy V, *et al.* Feline musculoskeletal pain index: responsiveness and testing of criterion validity. *J Vet Int Med* 2013;27:474-482.
- Slingerland LI, Hazewinkel HAW, Meij BP, *et al.* Cross-sectional study of the prevalence and clinical features of osteoarthritis in 100 cats. *Vet J* 2011;187:304-309.
- Godfrey DR. Osteoarthritis in cats: a retrospective radiological study. *J Small Anim Pract* 2005;46:425-429.
- Guillot M, Taylor PM, Rialland P, *et al.* Evoked temporal summation in cats to highlight central sensitization related to osteoarthritis-associated chronic pain: a preliminary study. Eldabe S, ed. *PLoS One* 2014;9:e97347.
- Sparkes AH, Heiene R, Lascelles BD, *et al.* ISFM and AAFFP consensus guidelines: long-term use of NSAIDs in cats. *J Fel Med Surg* 2010;12:521-538.
- Gowan RA, Lingard AE, Johnston L, *et al.* Retrospective case-control study of the effects of long-term dosing with meloxicam on renal function in aged cats with degenerative joint disease. *J Fel Med Surg* 2011;13:752-761.
- Gruen ME, Griffith E, Thomson A, *et al.* Detection of clinically relevant pain relief in cats with degenerative joint disease associated pain. *J Vet Int Med* 2014;28:346-350.
- Charlton AN, Simpson W, Freire M, *et al.* Evaluation of the clinical use of tepoxalin and meloxicam in cats. *J Fel Med Surg* 2013;15:678-690.
- Plumb DC. *Plumbs Veterinary Drug Handbook*. 7th Ed. Ames, IA: Blackwell Publishing;2011.
- Steagall PVM, Monteiro-Steagall BP, Taylor PM. A review of the studies using buprenorphine in cats. *J Vet Int Med* 2014;28:762-770.
- Vandeweerdt JM, Coisnon C, Clegg P, *et al.* Systematic review of efficacy of nutraceuticals to alleviate clinical signs of osteoarthritis. *J Vet Int Med* 2012;26:448-456.
- Lascelles BD1, DePuy V, Thomson A, *et al.* Evaluation of a therapeutic diet for feline degenerative joint disease. *J Vet Intern Med* 2010;24(3):487-495.
- Davidson JR, Kerwin SC. Common orthopaedic conditions and their physical rehabilitation. In: Millis DL, Levine D, eds. *Canine Rehabilitation and Physical Therapy* 2nd ed. Philadelphia, PA: Elsevier/Saunders; 2014; 543-581.
- Sawaya S. Physical and alternative therapies in management of arthritic patients. *Vet Focus* 2007;17.3;37-42.

HOW I APPROACH...

The dog with failing eyesight



■ **Gareth Jones, BVSc, CertVOphthal, MRCVS**
Park Veterinary Group, Leicester, UK

Dr. Jones qualified from the University of Liverpool Veterinary College in 1986. He initially worked in general practice before undertaking a residency in veterinary ophthalmology at London's Royal Veterinary College between 1992-1995, gaining his Certificate in Veterinary Ophthalmology in 1993. He is currently a director at a large mixed-animal general veterinary practice, where he sees both first opinion and referral ophthalmology cases. Dr. Jones is also a special lecturer in Veterinary Ophthalmology at the School of Veterinary Medicine and Science, University of Nottingham.

■ Introduction

When dealing with a dog that has started to lose its eyesight, it is essential – as with so many other situations in veterinary medicine – to initiate the consultation by obtaining a good history. The following points are especially pertinent.

What is the signalment?

It is an axiom that many eye conditions present themselves with a particular history in certain ages and breeds

of pedigree dogs. To understand veterinary ophthalmology the beginner should know which breeds develop certain eye conditions. For example, if presented with an 8-year-old Labrador with a history of night blindness and ophthalmic examination confirms the presence of bilateral retinal degeneration, then this is very suggestive of generalized progressive retinal atrophy (gPRA). A dog that presents with a painful, cloudy blind eye may well have glaucoma, but if it is a Jack Russell Terrier, the glaucoma is very likely secondary to primary lens luxation. Ophthalmic examination, including tonometry, would confirm the diagnosis and enable prompt treatment. Indeed misdiagnosis of this case might be considered negligent, so by learning which conditions affect each breed the aspiring ophthalmologist will be half way to understanding the subject.

Is the failing eyesight acute or chronic in onset?

Unfortunately some owners can be unobservant when it comes to noticing something wrong with their pet's eyes, and they may delay seeking help if they do observe a problem. However, this is not always the case, and many clients may seek timely help. If the problem is associated with ocular pain, namely lacrimation and blepharospasm, this may spur owners to present their animal early in the course of a disease. However if there is no overt pain then the first signs may be missed. An owner's personality and attitude to seeking medical help has a strong influence on whether or not an animal is presented in the early stages of sight loss, and as part of the history taking it is important to determine how long the disease condition may have been present, asking open questions wherever possible to allow the owner time to speak.

KEY POINTS

- **History taking is key when presented with a dog that has failing eyesight; it is especially important to note the animal's signalment and to determine when the poor eyesight was first noted by the owner.**
- **Do not rush the process of getting an animal into the consult room and onto the table; take time to observe the dog as it walks and try to judge how good or bad its eyesight is.**
- **Visual tracking, using a cotton-wool ball, is very useful when assessing an animal's sight, but other tests, including the pupillary light reflex, should also be conducted.**
- **It is not uncommon to be presented with an animal with failing eyesight that also has normal ocular features of aging, and it is essential to be able to differentiate these from an acquired pathology.**

What is the client's primary complaint, and what other ocular features might be present?

Find out if the eye is painful; ask if any redness or discharge has been noticed, and whether the eye appears abnormal (e.g., cloudy) in any other way. Determine (both from the history and from the examination) if the condition affects one or both eyes. If blindness is the primary presenting feature then one would expect both eyes to be affected with a degree of symmetry in the lesions seen. However it is also possible for a dog to have lost the sight in one eye due to a certain condition and for the other eye to then become affected at a later date from either the same or a new underlying pathology.

■ Clinical examination

Many systemic conditions can present with ophthalmic features and the alert clinician should always include the eyes during any general physical examination. Equally the ophthalmologist should be aware of the “ocular support structures” (which may be regarded as the rest of the animal) and examine the entire animal thoroughly, particularly where bilateral ocular conditions are present. A complete physical examination should always be considered appropriate and conducted where time allows. For example, a diabetic dog not uncommonly develops secondary cataracts and therefore will require a full examination, although the animal will usually already have presented with other symptoms such as polydipsia and may indeed be receiving insulin medication by the time the cataracts develop.

■ Ophthalmic examination

Ophthalmic examination is the key to making a specific diagnosis. Localizing and identifying a lesion within the eye is the essence of ophthalmology. There is a great variation in eye appearance in normal animals and an essential part of understanding this subject is learning to differentiate what is normal from an acquired or congenital abnormality. A full description of how to perform an ophthalmic examination is outwith the scope of this article, and the reader is referred to other literature for more detail (1), although it is pertinent to discuss vision testing here. It is also worth noting that some knowledge of tonometry (the measurement of intraocular pressure) could be considered essential, as glaucoma not infrequently causes vision loss, and it is very useful if a clinician has access to a tonometer device to allow intraocular pressure to be measured.

The first part of the ophthalmic examination begins with observation of the pet. In general, veterinarians are very keen to get the pet into the consultation room as quickly

as possible, and will usually immediately put the patient on the examination table. Do not become distracted at this point; observe the pet from a distance if you can. It is when I am greeting the owner that I first look at the patient from a distance. Watch the animal's movements as it comes into the room and while on the floor, undisturbed by the owner. Acutely blind dogs, especially those of a nervous temperament, will show signs of anxiety on their faces. In contrast, dogs that have become gradually blind can adapt well, and may become so skilled at spatial awareness that even in an unfamiliar area like a consult room they can move around as though apparently sighted. You need to have a feeling for whether or not the dog can really see, as preconceived ideas can influence the clinician's approach to a case.

Vision testing is generally the first part of my eye examination. It is a truism in veterinary work that a vision test is subjective; if our animal patients could talk and tell us what they can or cannot see, ophthalmology would be a very different discipline. My favorite test is visual tracking using a cotton-wool ball. This is dropped from above, within the pet's eye line, observing for reflex movement of the eyeball or head as the pet watches the object moving downwards. A cotton-wool ball is the best object to use for this test because of the speed at which it falls; the white color also assists visibility. Each eye is tested in turn, and allowance should be made for the overlapping visual fields. I ask the owner to gently cover one eye of the animal with their hand held flat while the other eye is tested for vision. It is important to make sure there isn't too much restraint to avoid encumbering movement of the head.

In larger dogs the test can be done with them standing on the floor, whilst medium sized dogs can be stood on the exam table and gently restrained and reassured by the owner. Small toy dogs may be held in the owner's arms – if the dog is nervous or excitable it is essential to ensure the dog's head is facing towards you in a comfortable manner, not tucked under the owner's arms or towards their chest. Some dogs won't co-operate, and in fact cats are notorious for this.

Other forms of visual testing include the following;

1. Obstacle course. If the waiting room is empty and I am unsure about the degree of vision present, I will set up an obstacle course. Be aware that this might not be appropriate to do immediately in a first opinion setting, as

it takes time and needs space; it may be necessary to admit the pet to the clinic for this degree of assessment. A sufficiently large and secure room, devoid of other animals and owners, must be available; all doors need to be closed so the animal cannot escape. Objects of various sizes are placed across the floor to create a maze-like course for the pet to negotiate; I use readily-available items such as chairs placed on their side, leaflet holders and waste paper bins (**Figure 1**). The owner should assume a position on the far side of the maze whilst I hold the pet on the near side. The owner is then asked to calmly call their dog towards them, allowing me to assess the dog's vision. Over-enthusiastic calling must be avoided as the dog may rush through the maze and hurt itself.

Where possible it might be appropriate to attempt to assess vision in both light (photopic) and dark (scotopic) conditions, as some conditions, such as inherited retinopathies, (specifically gPRA) initially affect night time vision because of particular effects on rod function. The history may give a clue in this situation, so it is important to ask the owner what the pet's vision is like when taken out at night, but the clinician should also judge if the response to the visual test seems worse in dim light, although of course this will be very much a subjective assessment.

2. Pupillary light reflex (PLR). A bright light is shone into the eye to assess constriction of the pupil. Beware: this is not a test of vision. PLR is subcortical and is a test of the afferent and efferent arms of the autonomic nervous system, *i.e.*, the neuroretina, the optic nerve and oculomotor nerve. I consider this test to be useful in giving clues as to the state of health of the retina, optic nerve, optic chiasma and oculomotor nerve. However, the following comments on this test are important:

- It is possible to have a good, rapid PLR even where there is complete retinal detachment or advanced retinal degeneration. Until recently the reason for this was unknown, although it was thought that perhaps the response relied only on a very small number of functioning photoreceptors. Recently it has become apparent that PLR is elicited by different colors (*i.e.*, wavelengths) of light, so the chosen light source may have a much greater influence on this test than most clinicians realize (2).
- The PLR test will be of no help without a sufficiently powerful light source; the iris muscle will not contract rapidly. This also occurs if there is age-related iris atrophy (see later) or if the dog is particularly fearful or



© Dr. Gareth Jones

Figure 1. An obstacle course set up in the waiting room can help determine how well an animal can see.

aggressive. A negative test does not necessarily mean there is a lesion; if necessary get a better light source or replace the battery in the flashlight!

- PLR will be absent and/or the pupil will be dilated if a mydriatic drug has been applied, so use open questions to verify this point when taking a thorough history. If a case has been seen previously by another center, identify what topical drugs have been used recently. Remember that if atropine has been applied topically then it can last several days, especially in a normal eye where no uveitis is present (or if an acute uveitis has been present but quickly controlled).
- The test is particularly useful if there is a unilateral ocular opacity. The presence of a consensual PLR (where the pupil in the opposite eye constricts) will give a clue that the retina is functional in the affected eye (**Figure 2**). Further tests, such as the swinging flashlight test, are recommended for clinicians with a major interest in ophthalmology (3).

3. Dazzle test. A bright light is suddenly shone onto the eye to see if there is a reflex blink; this is also a subcortical

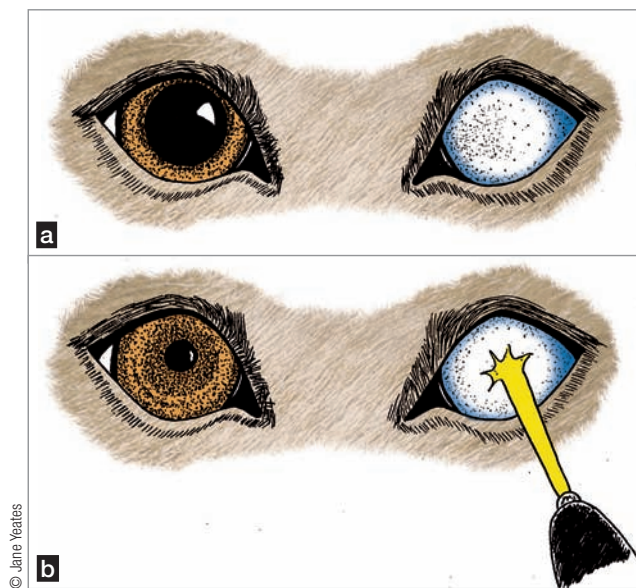


Figure 2. Positive indirect (consensual) PLR in the presence of an opaque cornea. When examining an eye with an opaque cornea, or where anterior chamber turbidity makes it impossible to see the pupil clearly in the affected eye (a), the presence of a consensual PLR, whereby the pupil in the opposite eye constricts, will give a clue that the retina is functional in the affected eye (b).

reflex and gives an indication of retinal function. Again it is a useful pointer in some cases, *e.g.*, when investigating mature cataracts; a poor PLR in an older pet with cataracts might be due to iris atrophy, whereas a positive dazzle test may indicate the retina is healthy enough to warrant consideration of cataract extraction.

4. Menace test. The hand is suddenly moved into the visual field to determine if the animal can see – strictly speaking this should be called a menace response as it is a learned behavior. The full pathway differs from that of the PLR because it has a component that involves the cerebellum. There are good and bad techniques to performing the menace response, and there is more to it than simply waving a hand close to the animal's face. Test each eye in turn, and be aware that there is a nasal and temporal field of vision in each eye due to the cross-over in central optic nerve pathways. Do not create air currents with your hands; some authors recommend using a plastic screen to shield the air currents but in my opinion this makes performing the test too complicated!

The aim of an ophthalmic examination is to determine the anatomical location of any abnormality within the eye and then to reach a conclusion as to the possible etiology.

The remainder of the examination involves detailed assessment of the adnexa (eyelids), conjunctiva, cornea, anterior chamber, iris, lens, vitreous and retina.

■ Normal features of aging

Care should be taken as it is not uncommon to be presented with an animal with failing eyesight that also has a normal ocular feature of aging, and it is essential to be able to differentiate this from an acquired pathology. A normal aging feature will have no effect on vision and there may be another lesion present which needs differentiation and definitive diagnosis.

Normal features of aging include;

1. Iris atrophy. This is an age-related atrophy of the iris muscle, particularly the constrictor muscles which lie more centrally than the dilator muscles. The pupil develops a “ragged” edge and the iris tissue becomes thinner. Transillumination with a bright light source will highlight this. Iris atrophy can be a feature of aging of any animal, particularly over the age of ten, and small breeds (*e.g.*, toy poodles) are commonly affected. It has no known effect on vision but it is relevant as it can lead to a negative or poor PLR.

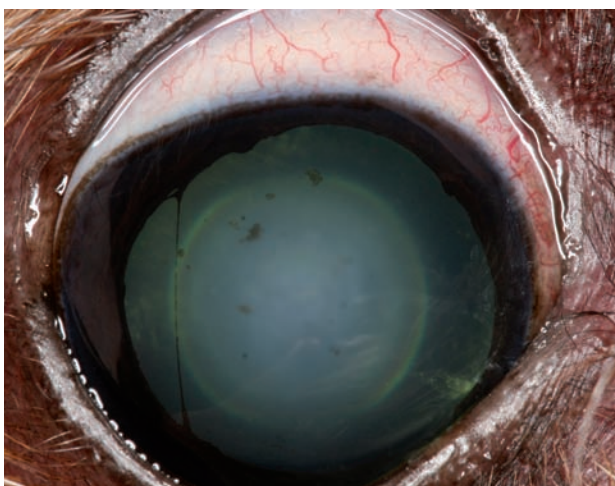
2. Nuclear sclerosis. The lens, which has a structure comparable to the layers of an onion, grows throughout life. The nucleus becomes more compressed with age and can give the illusion that the central portion of the lens is cloudy when viewed under normal background lighting (**Figure 3**). Owners will often present old dogs with eyes that appear opaque with the presumption they have cataracts. By using distant direct ophthalmoscopy, nuclear sclerosis can be readily differentiated from a true cataract by using the technique of retroillumination (**Figure 4**).

■ Diagnosis

There are many diseases and conditions of the eye which are potentially injurious to vision, and there are too many to cover in any great detail within this article. However, vision loss can result either from conditions that cause opacity of the ocular media or conditions that are injurious to specific structures of the eye (such as the retina and optic nerve), and these can result from either congenital (**Table 1**) or acquired (**Table 2**) pathologies. Two case reports offer examples as to conditions that can lead to failing eyesight in the dog.

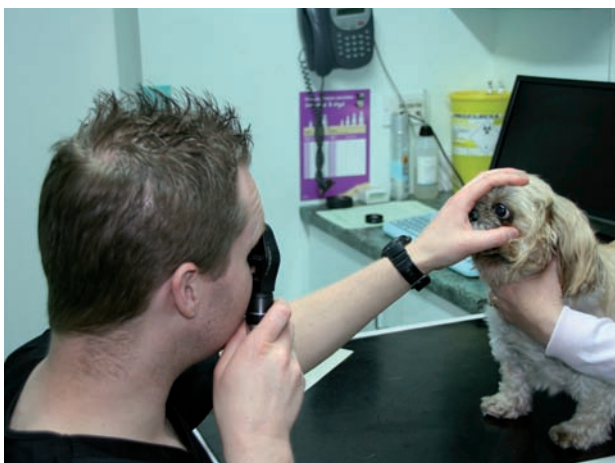
■ Conclusion

Having seen thousands of eye cases over the last 25



© Dr. Gareth Jones

Figure 3. Senile nuclear sclerosis of the lens and iris atrophy; the central lens appears as a distinct circle.



© Dr. Gareth Jones

Figure 4. Distant direct ophthalmoscopy can be used to identify nuclear sclerosis.

Table 1. Congenital/early developmental eye conditions associate with vision impairment.

- Microphthalmos/anophthalmos
- Congenital cataract +/- multiocular anomaly
- Mesodermal dysgenesis
- Persistent hyperplastic primary vitreous (PHPV)
- Retinal dysplasia
- Congenital cataract/early developmental cataract
- Collie eye anomaly (CEA)
- Optic nerve coloboma
- Optic nerve hypoplasia
- Central nervous system malformations (e.g., hydrocephalus)

Table 2. Common acquired eye conditions associated with vision impairment*.

Acute sight problems
<ul style="list-style-type: none"> • Acute “angle closure” glaucoma • Primary lens luxation • Acute severe uveitis • Intraocular hemorrhage • Certain forms of cataract (e.g., diabetic) • Sudden acquired retinal degeneration (SARD) • Retinal detachment • Certain forms of central blindness (e.g., optic nerve meningioma/granulomatous meningoencephalitis) • Optic neuritis • Toxicity • Severe trauma
Chronic sight problems
<ul style="list-style-type: none"> • Chronic “open angle” glaucoma • Pigmentary glaucoma • Secondary glaucoma (e.g., chronic uveitis/neoplasia) • Chronic severe corneal disease (e.g., dense pigmentary keratitis) • Chronic uveitis • Cataracts (mature) • Chorioretinitis (severe) • Generalized PRA or other inherited retinopathies • Nutritional deficiency (e.g., vitamin E) • Neurological disorder (e.g., hepatic encephalopathy)

* Note that this is not an exhaustive list and there is a degree of crossover between acute and chronic conditions (4).

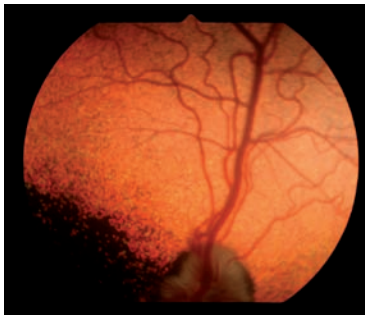
years, I take a relatively simple view when making a diagnosis: if it looks like the last case I saw with a certain condition, then it has probably got that one. This method of achieving a diagnosis is called “pattern recognition” and for a clinician who has had lots of case experience it can work well. However the beginner to ophthalmology might need to adopt what is called a “problem-oriented” approach, and even experienced veterinarians should use this method when presented with a rare or unusual case. At its most basic level, determine which part of the eye is affected, list all the salient features, consider the differential diagnoses, reach a provisional diagnosis and conduct confirmatory

CASE 1

An 8-year-old Springer Spaniel presented for assessment of blindness. Overtly, there were no other symptoms and neither eye was painful or opaque. The dog was one of eight animals that lived outside on a smallholding; the owner had noticed poor eyesight over the last few days, and was unsure whether the dog could see or not. The dog seemed well systemically and was reported to be eating and drinking normally.

Visual tests, although inconclusive, suggested that

Figure 6. An apparently normal appearance of the retina in a dog with SARD.



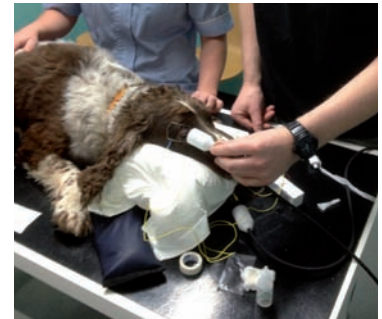© Dr. Gareth Jones

vision was poor; the dog could negotiate around a room without colliding with stationary objects but could not follow cotton-wool balls easily. Both pupils were dilated and poorly responsive to bright light. There was no other cranial nerve or neurological deficit present.

Ophthalmic examination did not reveal any ocular lesion, other than absent PLR, and each retina appeared fundoscopically normal. The referring vet was concerned about retinal bleeding but none was apparent.

A normal color variation (an orange-brown color) of the non-tapetal fundus was noted, this was perhaps mistaken for retinal hemorrhage by the referring vet.

Differential diagnoses include sudden acquired retinal degeneration (SARD), optic neuritis or a CNS lesion affecting the central pathways.



© Dr. Gareth Jones

Figure 5. Electroretinography can be a useful procedure to assess retinal function.

Electroretinography (**Figure 5**) was performed and showed a negative trace, which supported a possible diagnosis of SARD (**Figure 6**) and a more complete work-up, including MRI imaging to investigate for a central lesion, was therefore deemed unnecessary.

No treatment is possible for this condition but the owner can be counseled on their pet's welfare and how to help the animal adapt to vision loss.

CASE 2

A 10-year-old Cairn Terrier presented because of concerns about failing eyesight. The dog had started to become lost on walks and collide with certain objects around the house. On questioning the owner did not feel their pet was showing any signs of ocular pain but did report that the eyes had become cloudy some months before and were now looking even more "odd", in that they seemed to be bulging and red.

The dog failed to respond to sight tests and both pupils were dilated and non-responsive. Ophthalmic examination on this occasion revealed a number of ocular changes. Each globe was

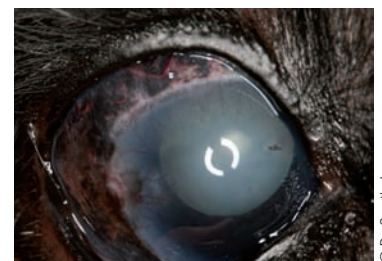
buphthalmic (enlarged) and there was episcleral congestion and dark brown pigmentation of the scleral and peripheral cornea (**Figure 7**).

Diffuse corneal edema was also present, making the intraocular examination more challenging. With indirect ophthalmoscopy, bilateral retinal degeneration was visible with cupping of the optic nerve. Tonometry revealed a high intraocular pressure reading in each eye (45 mmHg).

This case was diagnosed as pigmentary glaucoma, a condition which has been reported in the Cairn Terrier. The disease course is chronic and insidious but

medical management with anti-glaucoma medication can slow the inevitable deterioration and give the dog and the owner time to adapt to the blindness.

Figure 7. Pigmentary glaucoma in the right eye of a Cairn Terrier.



© Dr. Gareth Jones

tests. Never forget that history, signalment and full clinical examination are also key to a successful diagnosis!

Finally, it must be stressed that in some situations a quick diagnosis is essential – for example, a cloudy, painful eye with episcleral congestion and impaired vision, together with a sluggish dilated pupil, can be the

cardinal signs of glaucoma. Tonometry will generally confirm this diagnosis, and gonioscopy of the other eye might help determine if it is a primary or secondary glaucoma. If the clinician waits until the globe is grossly enlarged before confirming the diagnosis then it is too late – so if ever in doubt, consider referral to a specialist ophthalmologist!

References and further reading

1. Heinrich C. Ophthalmic examination. *In*: Gould D, McLellan G, eds. *BSAVA Manual of Canine and Feline Ophthalmology*. 3rd ed. Gloucester: BSAVA, 2014 (in press).
2. Grozdanic SD, Kecova H, Lazic T. Rapid diagnosis of retina and optic nerve abnormalities in canine patients with and without cataracts using chromatic pupil light reflex testing. *Vet Ophthalmol* 2013;16(5):329-340.
3. Turner S. *Veterinary Ophthalmology: A Manual for Nurses and Technicians* London, Butterworth-Heinemann 2006;34.
4. Smith K. Clinical examination and diseases of the fundus in dogs. *In Pract* July/August 2014;35(7):315-330.

Further reading

- Featherstone H, Holt E. *Small Animal Ophthalmology; What's Your Diagnosis?* Oxford, Wiley-Blackwell 2011
- Peiffer R, Petersen-Jones S (Eds). *Small Animal Ophthalmology, A Problem-Oriented Approach*. 4th ed. Oxford, Wiley-Blackwell 2008.

Age at diagnosis of select chronic diseases



■ **Emi Kate Saito, VMD, MSPH, MBA, Dipl. ACVPM (Epidemiology)**
Banfield Pet Hospital, Portland, Oregon USA

Dr. Saito graduated from the Veterinary School at the University of Pennsylvania in 1997. She was awarded a Masters in Public Health by Emory University in 2001 and studied for her MBA at the University of Colorado between 2010-2012. She has worked for Banfield's Applied Research and Knowledge (BARK) team since 2013, following a period when she worked for both the US Department of Agriculture and the US Department of the Interior as an epidemiologist. She has wide experience of wildlife and regulatory livestock diseases and has published several papers on these topics.



■ **Catherine Rhoads, BA**
Banfield Pet Hospital, Portland, Oregon USA

Catherine Rhoads is a senior data analyst for the BARK team, supporting Mars Petcare business units using Banfield data and insights. Catherine joined Banfield in 2007 after graduating from the University of Oregon in 2006. Within the company she has filled roles as an operations analyst and a marketing systems analyst, and in her current role she continues to enjoy using Banfield's veterinary database to find actionable insights that make the world a better place for people and pets.

■ Introduction

The increasing recognition of the importance of preventive care has led to recommendations for routine veterinary visits and laboratory diagnostics for early detection of diseases. Following these recommendations can lead to both early disease detection (which may enable interventions that stop or slow disease progression) and establishment of baseline pet health information for monitoring over time (1-4). For some commonly diagnosed problems, the onset of clinical disease can be subtle, and pets can be good at hiding signs of weakness or illness. As such, the veterinarian's job in assessing the health of the aging pet is more challenging. When pets seem healthy, it may be difficult to convince owners of the additional benefits of routine visits and laboratory screenings (2), although reports have presented evidence of such benefits in apparently healthy pets (5-7). In this article, information will be provided to support veterinarians in their discussions with clients about wellness care.

■ Methods of analysis

The health records of all canine and feline patients who had visited a Banfield Pet Hospital from 1994 through 2013 – over 10.87 million dogs and 3.29 million cats – were screened to identify those patients that had been diagnosed with the following diseases: heart disease

(cardiomyopathy, heart failure, and valvular disease), endocrinopathies (Cushing's disease, diabetes mellitus, and hyper- or hypothyroidism), hepatopathy, and kidney failure (acute and chronic). The records of affected patients were screened to identify the age at which the diagnosis was first recorded – note that since medical conditions are not mutually exclusive, a pet may have been diagnosed with more than one disease, and may therefore be represented more than once within the study. Median ages at first diagnosis were calculated and, for dogs, categorized by breed size. Prevalence of each disease diagnosis was also calculated for 2003, 2008 and 2013, using the total number of patients seen in each of those years. An analysis was conducted to evaluate observed temporal changes in disease prevalence using a z-test to compare proportions (8).

■ Results

The overall Banfield canine patient population can be classified as about 2.92 million (26.9%) toy breeds, 1.90 million (17.5%) small, 3.14 million (28.9%) medium, 2.68 million (24.7%) large, and 0.21 million (2.0%) giant. From the Banfield caseload, 131,972 (4.0%) cats and 321,843 (3.0%) dogs were found to have at least one of the diagnoses of interest; of the latter group, the affected canine patients were subdivided as follows: 93,604 (20-year prevalence = 3.2%) were toy breeds; 68,400 (3.6%)

small; 82,678 (2.6%) medium; 72,774 (2.7%) large; and 4,387 (2.1%) giant. The median age at first diagnosis by breed size for each disease is shown in **Tables 1 and 2**. With exception of thyroid disease and hepatopathy diagnoses, the median ages for the other diagnoses in dogs (overall) are typically between 9-11 years, with the median figure varying somewhat by breed size, and giant dogs having observable differences from the other sizes for each illness. The median age at first diagnosis in cats was more variable than for dogs.

Prevalence estimates of each of the disease conditions are presented in **Table 3**. Of these disorders, the most prevalent in 2013 (in decreasing order) were: thyroid disease, heart disease, kidney disease and hepatopathy in dogs; kidney disease, thyroid disease, diabetes mellitus and hepatopathy in cats. Statistically significant ($p \leq 0.05$) changes in prevalence were found in almost all diseases over the last 10 years, with the exception of valvular disease in cats. Statistically significant increases in prevalence between 2003 and 2008 for valvular disease in dogs can be seen; however, the change in prevalence

between 2008 and 2013 for this condition was not statistically significant. Although prevalence for cardiomyopathy (dogs) and Cushing's disease (cats) increased from 2003 to 2008, the prevalence for both diseases declined in 2013 to show an overall non-significant change from 2003 to 2013.

■ Discussion

A look at the data suggests that the apparent prevalence of the diseases of interest in the pet population has increased significantly since 2003 for almost all of the selected diseases. This increase may be at least partially explained by the increasing age of the Banfield pet population*. Establishing age-adjusted prevalence calculations for each of these conditions was beyond the scope of this study.

It is important to note that "diagnosis" of the selected diseases was based solely on the entry of the diagnostic code into the pet's health record – there may or may not have been supporting laboratory tests performed. In addition, a pet seen at Banfield for the first time may

Table 1. Descriptive statistics for each of the select heart diseases and the median age (in years) at first diagnosis.

Species/ dog size	Cardiomyopathy		Heart failure		Valvular disease	
	# Cases	Median age (yrs)	# Cases	Median age (yrs)	# Cases	Median age (yrs)
Dogs	6,044	10.1	32,271	11.9	6,809	10.7
Toy	1,771	10.6	14,148	11.6	2,977	10.4
Small	1,047	11.3	8,267	12.4	2,022	11.2
Medium	2,062	8.9	6,833	11.8	1,409	10.6
Large	1,018	9.7	2,849	11.2	380	9.7
Giant	146	6.4	174	8.4	21	3.2
Cats	5,125	9.2	2,349	11.6	205	7.1

Table 2. Descriptive statistics for endocrinopathies and other chronic diseases and the median age at first diagnosis.

Species/ dog size	Cushing's disease		Diabetes mellitus		Thyroid disease*		Hepatopathy		Kidney disease	
	# Cases	Median age (yrs)	# Cases	Median age (yrs)	# Cases	Median age (yrs)	# Cases	Median age (yrs)	# Cases	Median age (yrs)
Dogs	15,240	10.5	23,073	9.3	67,484	7.9	106,956	7.5	38,835	10.9
Toy	3,744	10.1	6,931	9.1	9,915	8.1	40,629	4.9	10,523	11.0
Small	4,852	10.8	6,780	9.9	10,141	8.8	24,978	8.4	8,929	12.3
Medium	4,136	10.6	4,665	9.6	20,311	7.9	22,769	8.9	10,698	10.7
Large	2,425	10.2	4,558	9.1	25,836	7.6	17,640	9.3	8,128	9.8
Giant	83	9.3	139	8.1	1,281	6.5	940	6.3	557	5.1
Cats	123	11.6	22,359	11.2	32,616	14.1	15,158	8.0	59,428	13.9

* hyperthyroidism – cats; hypothyroidism – dogs

Table 3. Prevalence of each of the selected diseases (# cases per 10,000 animals) and statistical evaluation of changes in prevalence in 2008 and 2013.

	Dogs			Cats		
	2003	2008 (p-value, compared to 2003)	2013 (p-value, compared to 2003 and 2008, respectively)	2003	2008 (p-value, compared to 2003)	2013 (p-value, compared to 2003 and 2008, respectively)
Heart diseases						
Cardiomyopathy	3.5	4.4 (0.0017)	3.6 (0.691; 0.0001)	11	17.1 (<<0.0001)	14.1 (0.0007; 0.0006)
Heart failure	17.7	17.7 (0.932)	23.8 (<<0.0001 for both)	3.5	4.6 (0.048)	7.2 (<<0.0001; <0.0001)
Valvular disease	4.2	5.0 (0.006)	5.3 (0.0002; 0.267)	0.4	0.6 (0.525)	0.6 (0.341; 0.723)
Endocrinopathies and other diseases						
Cushing's disease	7.6	10.6 (<<0.0001)	13.1 (<<0.0001 for both)	0	0.4 (0.005)	0.2 (0.152; 0.024)
Diabetes mellitus	10.3	14.8 (<<0.0001)	28.0 (<<0.0001 for both)	43.8	66.1 (<<0.0001)	91.4 (<<0.0001 for both)
Thyroid disease	38.5	58.8 (<<0.0001)	63.8 (<<0.0001 for both)	59.1	92.4 (<<0.0001)	147.1 (<<0.0001 for both)
Hepatopathy	11.8	48.6 (<<0.0001)	181.5 (<<0.0001 for both)	16.6	30.0 (<<0.0001)	75.4 (<<0.0001 for both)
Kidney disease	15.5	22.6 (<<0.0001)	34.3 (<<0.0001 for both)	102.8	150.7 (<<0.0001)	229.9 (<<0.0001 for both)

already have been diagnosed previously with one of the conditions, and so the pet's age at this visit was used as the age of first diagnosis, rather than the actual age if diagnosis was made by the original veterinary hospital. Although it is not known how this may have biased the study results, there is no reason to suspect deliberate inaccuracies in pet age. Finally, because Banfield hospitals operate as a primary/general veterinary practice, remember that some of the data for diseases that might be diagnosed by a veterinary specialist (e.g., a cardiologist) may be somewhat more subjective than data for diseases which are more common to the general

practitioner (e.g., diabetes mellitus, kidney failure) and therefore lend themselves to definitive diagnosis.

This study is not intended to provide proof that apparently healthy pets can have disease, but rather to support conversations between veterinarians and their clients about these diseases and when they appear in the pet population, thus assisting both the clinician and the pet owner in the decision-making process.

* The average ages for each year are shown right:

Year	Canine	Feline
2003	3.5	4.0
2008	3.5	4.3
2013	4.3	5.3

References

- Epstein M, Kuehn NF, Landsberg G, et al. AAHA senior care guidelines for dogs and cats. *J Am Anim Hosp Assoc* 2005;41:81-91. Available at: <https://www.aahanet.org/PublicDocuments/SeniorCareGuidelines.pdf>.
- Vogt AH, Rodan I, Brown M, et al. AAHP-AAHA feline life stage guidelines. *J Am Anim Hosp Assoc* 2010;46: 70-85. Available at: <https://www.aahanet.org/PublicDocuments/FelineLifeStageGuidelines.pdf>.
- Bartges J, Boynton B, Vogt AH, et al. AAHA canine life stages guidelines. *J Am Anim Hosp Assoc* 2012;48:1-11. Available at: https://www.aahanet.org/PublicDocuments/Canine_Life_Stage_Guidelines_.pdf.
- Metzger FL, Rebar AH. Clinical pathology interpretation in geriatric veterinary patients. *Vet Clinics North Am: Small Anim Pract* 2012;42:615-629.
- Davies M. Geriatric screening in first opinion practice – results from 45 dogs. *J Small Anim Pract* 2012;53: 507-513.
- Paepe D, Verjans G, Duchateau L, et al. Routine health screening: findings in apparently healthy middle-aged and old cats. *J Feline Med Surg* 2013;15:8-19.
- Knesl O, Lavan R, Horter D, et al. Canine Health Risk Assessment – a review of 7,827 cases. *Zoetis Technical Bulletin 2013*. Available at: https://www.zoetis.com/solutions/pages/lifelongcare/documents/pet_wellnessreport_tech_bulletin_canine_final-may17.pdf.
- Woodward M. *Epidemiology: Study Design And Data Analysis*. 2nd ed. Boca Raton, FL: Chapman and Hall/CRC, 2005.

Blood testing in the geriatric dog



■ **Theresa Rizzi, DVM, Dipl. ACVP**
Oklahoma State University, Stillwater, Oklahoma, USA

Dr. Rizzi is a Clinical Associate Professor in the department of Veterinary Pathobiology at the Center for Veterinary Health Sciences in Oklahoma State University (OSU). Originally from Brooklyn, New York, she obtained her veterinary degree from OSU in 1998 and after some years in private practice returned to the university for residency training in Veterinary Clinical Pathology, achieving board certification in 2005. Her clinical interests include diagnostic cytology, hematology, and infectious diseases (particularly *Cytauxzoon felis*) and she has authored several book chapters and journal articles on these subjects. Dr. Rizzi also enjoys teaching select pathology classes to OSU veterinary students.

■ Introduction

Older dogs often have complex, multisystem medical challenges, and blood testing is part of a thorough diagnostic work-up in the clinic; indeed early detection of disease is often paramount for successful treatment and/or a superior quality of life for our geriatric patients. However, annual or semi-annual blood testing may not only enable early identification of problems, it will also allow evaluation of trends and the monitoring of the systemic response to disease treatment. The establishment

of baseline data may be invaluable when assessing subsequent alterations of a particular blood parameter, especially when the changes are incremental over time; a small increase in magnitude may not be as significant as the long-term trend of a given parameter. It is also prudent to perform baseline blood work prior to the initiation of medications, and in particular to evaluate renal and liver function. Geriatric blood testing should include a complete blood count, a serum or plasma biochemistry profile which incorporates electrolytes, and urinalysis. Additional tests may then be indicated based on irregularities detected on laboratory data and/or physical examination findings.

KEY POINTS

- Geriatric blood testing should include a complete blood count, a serum or plasma biochemistry profile that incorporates electrolytes, and urinalysis, with additional tests performed as necessary.
- It is prudent to perform survey blood tests prior to initiating some medication in the older dog; in particular renal and liver function should be evaluated.
- Creatinine is the more reliable indicator of GFR, whereas urea nitrogen concentrations may be affected by high protein meals and gastrointestinal hemorrhage and dehydration.
- Liver enzyme elevations in older dogs should always be investigated. These elevations may not be directly related to primary liver disease but rather reflect the liver's response to other systemic or metabolic illnesses.

■ Interpreting the senior complete blood count

The complete blood count (CBC) provides information about the patient's blood, with the sample collected in a tube containing the anticoagulant EDTA. This test can identify anemia, inflammation, primary hemostatic conditions, and hematopoietic malignancies. Most of the information gathered is generated by an automated hematology analyzer, with additional information provided by a microscopic examination of the stained blood film.

Red blood cells

Anemia is defined as a reduction in red cells below the reference interval, and is measured by the hematocrit (Hct), hemoglobin (Hb) concentration, and red blood cell (RBC) count. Anemia causes decreased tissue oxygenation with ensuing clinical signs that correspond to the degree of anemia and the rapidity of red cell decline; these may include lethargy, tachycardia, tachypnea,

weakness, exercise intolerance, and tissue pallor. Anemia may be caused by blood loss, hemolysis, or decreased bone marrow production (**Table 1**). The response to blood loss or hemolysis, provided enough time has elapsed, is characterized by increased numbers of reticulocytes being released from the bone marrow; the bone marrow response typically takes 3-4 days, with a peak response generally occurring within 5-7 days. An increased absolute reticulocyte count above the reference interval indicates a regenerative anemia and this test should be requested on all anemic patients (**Table 2**). Microscopic examination of the blood film should reveal increased numbers of larger, polychromatophilic erythrocytes (**Figure 1**) which correspond to aggregate reticulocytes. An examination of a bone marrow aspirate/biopsy should be performed for any persistent, unexplained, non-regenerative anemia (**Table 1**).

Erythrocytosis (or polycythemia) is an increase in RBC count above the reference interval (**Table 3**). It is detected as an increase in Hct, Hb concentration, and RBC count. Dehydration, with a decrease in plasma volume and an apparent increase in the hematocrit, is the most common cause; this is known as a “relative erythrocytosis”. Mild elevations in red cell mass are not typically associated with adverse clinical signs, but an extreme erythrocytosis may cause increased viscosity of blood or decreased circulation, causing decreased tissue oxygenation. Secondary erythrocytosis may be classed as “appropriate” or “inappropriate”. A “secondary appropriate erythrocytosis” is a response to systemic tissue hypoxia, whereby increased production of erythropoietin (EPO) stimulates

erythropoiesis, thus improves oxygen carrying capabilities. A secondary inappropriate erythrocytosis is seen following excessive EPO production (from an EPO-producing tumor or a kidney lesion that causes renal micro-environment hypoxia, which stimulates EPO production). Clinical signs related to increased blood viscosity may include exercise intolerance, purplish or brick-red skin and mucous membranes, congested retinal blood vessels accompanied by hemorrhage, mucosal bleeding episodes, and neurologic disturbances. Excluding relative erythrocytosis, additional steps to determine the basis of an erythrocytosis could include echocardiography, abdominal ultrasound, measuring serum erythropoietin concentration, and bone marrow examination.

Particular attention to erythrocyte morphologic changes can assist the practitioner in identifying certain medical conditions. Spherocytes (**Figure 2**) are RBCs that have lost their bi-concave shape and instead are almost spherical. This is due to loss of erythrocyte membrane without loss of cell volume. Erythrocyte membrane loss may be due to intravascular shearing of the RBC or by partial phagocytosis by reticuloendothelial macrophages. Increased numbers of spherocytes detected in the blood film examination of an anemic dog is strong evidence of immune-mediated hemolytic anemia (IMHA).

Acanthocytes are red blood cells with irregular spicule projections of the erythrocyte membrane. They are presumed to be caused by changes in the lipid concentrations of the erythrocyte membrane and may be associated with conditions associated with altered lipid metabolism

Figure 1. Polychromatophils (arrows) stain bluish-red with Romanowsky-type stains. They correspond to aggregate reticulocytes and indicate a regenerative bone marrow.

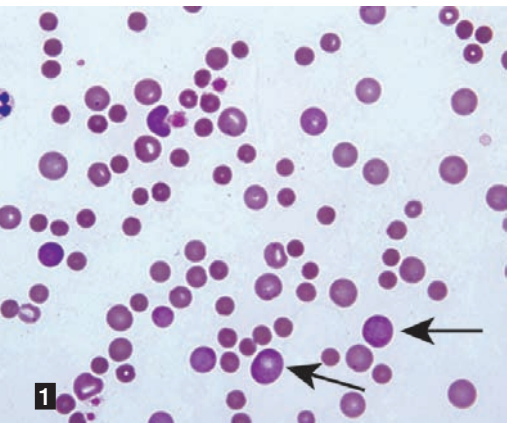


Figure 2. Spherocytes (arrows) are red blood cells that have lost their bi-concave shape due to the loss of the cell membrane without loss of cell volume.

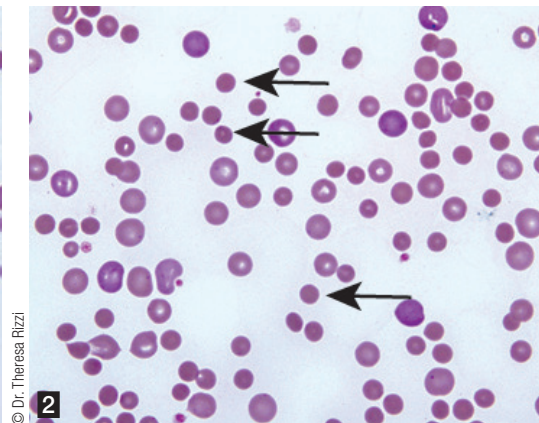
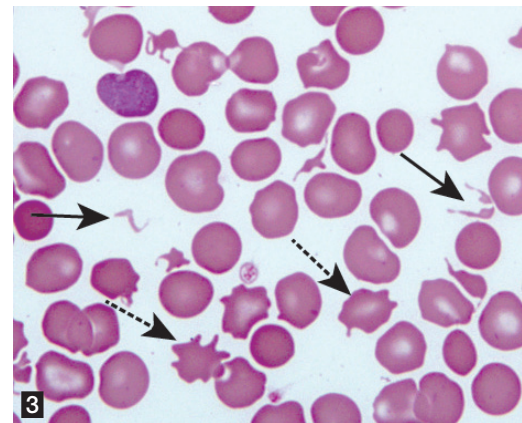


Figure 3. Schistocytes (red cell fragments – solid arrows), and acanthocytes (red blood cells with irregular spicule projections of the erythrocyte membrane – dotted arrows), have been observed in dogs with hemangiosarcoma.



(e.g., diabetes mellitus, liver disease). Schistocytes are red cell fragments which indicate intravascular trauma, and have been observed in animals with disseminated intravascular coagulation, vasculitis, vascular neoplasms, and iron deficiency. The combination of acanthocytes and schistocytes (**Figure 3**) has been noted in dogs with hemangiosarcoma; in such situations additional imaging studies of the thorax and abdomen may be warranted.

White blood cells

The total white blood cell (WBC) count is generated by an automated hematology analyzer, but the differential count is preferably done manually and reported as both a percentage of total WBCs and absolute numbers.

A neutrophilia is an increase in the total neutrophil count above the reference interval. The three most common causes of a neutrophilia are a physiologic response due to an epinephrine surge when excited, anxious, fearful or painful; a stress response caused by increased plasma concentration of either endogenous or exogenous glucocorticoid; or inflammation (**Table 4**). Neutrophilia associated with increased cortisol or epinephrine concentrations are typically less than twice the upper reference limit. Lymphopenia is often associated with increased cortisol concentrations and a lymphocytosis with an epinephrine response. Neutrophilia associated with inflammation is typically 2-3 times the upper reference limit or is accompanied by a “left shift”. This is an increase in band neutrophils above the reference limit and is considered to be the hallmark of acute inflammation; in fact a left shift indicates inflammation regardless of the neutrophil count. Neutrophil toxic change may be present with inflammation; this refers to defects that occur during accelerated maturation of neutrophils in the bone marrow as a response to inflammation.

A neutrophilia exceeding 50,000/μL is uncommon and has been termed a “leukemoid response”; this refers to the magnitude of a leukemoid response that is non-leukemic. Causes are typically focal areas of marked inflammation (e.g., pyometra, abscess, prostatitis, pleuritis, pneumonia, pyelonephritis, pericarditis, peritonitis, pancreatitis), but canine hepatozoonosis (caused by the protozoan *Hepatozoon americanum*), and paraneoplastic response to certain malignant tumors may cause a similar neutrophil elevation. Chronic myelogenous leukemia is uncommon in dogs.

Neutropenia is a decrease in total neutrophils below the reference interval (**Table 5**). The most common cause is

Table 1. Conditions causing anemia in dogs.

Conditions causing regenerative anemia	Conditions causing non-regenerative anemia
<p>Hemorrhage</p> <ul style="list-style-type: none"> • Trauma • Surgery • Parasites <ul style="list-style-type: none"> - Endoparasites - Ectoparasites • Coagulopathy • Gastrointestinal bleeding <ul style="list-style-type: none"> - Ulcers - Neoplasia - Inflammatory bowel disease 	<p>Bone marrow suppression</p> <ul style="list-style-type: none"> • Inflammation • Chronic disease <ul style="list-style-type: none"> - Hypothyroidism - Hypoadrenocorticism - Hypoandrogenism • Chronic renal disease • Infectious <ul style="list-style-type: none"> - Fungal - Bacterial - Viral - Protozoal - Rickettsial
<p>Hemolysis</p> <ul style="list-style-type: none"> • Immune-mediated <ul style="list-style-type: none"> - Idiopathic or primary - Secondary Drugs Toxins Neoplasia Infectious disease Post-transfusion • Infectious <ul style="list-style-type: none"> - <i>Mycoplasma spp.</i> - <i>Leptospira spp.</i> - <i>Clostridium spp.</i> - <i>Babesia spp.</i> • Hereditary metabolic defects <ul style="list-style-type: none"> - Pyruvate kinase deficiency - Phosphofructokinase deficiency • Oxidative damage <ul style="list-style-type: none"> - Drugs (e.g., acetaminophen, benzocaine) - Toxins (e.g., garlic toxicity) • Fragmentation <ul style="list-style-type: none"> - Disseminated intravascular coagulation - Vasculitis - Cardiac valvular disease - Caval syndrome - Hemangiosarcoma • Envenomation <ul style="list-style-type: none"> - Bees - Snakes - Spider 	<p>Toxicity</p> <ul style="list-style-type: none"> • Chemotherapies • Estrogen • Phenylbutazone • Cephalosporins • Phenobarbital • Griseofulvin • Sulfonamides • Others <p>Irradiation</p> <p>Immune-mediated</p> <ul style="list-style-type: none"> • Destruction directed against precursors • Pure red cell aplasia • Chronic erythropoietin administration <p>Myelophthisis</p> <ul style="list-style-type: none"> • Leukemia • Multiple myeloma • Other neoplasia • Myelofibrosis <p>Myelodysplastic syndromes</p> <p>Nutritional deficiencies</p> <ul style="list-style-type: none"> • Iron • Cobalamin • Folate <p>Liver disease or failure</p>

Table 2. Interpretation of reticulocyte response to anemia.

Absolute reticulocyte count	Response
< 60,000/ μ L	None
80,000-150,000/ μ L	Mild
150,000-500,000/ μ L	Moderate
> 500,000/ μ L	Marked

Table 3. Causes of erythrocytosis.

Absolute
<ul style="list-style-type: none"> • Primary <ul style="list-style-type: none"> - Polycythemia vera *
<ul style="list-style-type: none"> • Secondary appropriate <ul style="list-style-type: none"> - Cardiac disease – right to left shunt - Chronic congestive heart failure - Chronic lung disease - High-altitude disease - Severe obesity - Hyperthyroidism
<ul style="list-style-type: none"> • Secondary inappropriate <ul style="list-style-type: none"> - Renal cysts/neoplasia - Paraneoplastic
<ul style="list-style-type: none"> • Endocrine-associated excessive hormone production <ul style="list-style-type: none"> - Cortisol - Androgen - Thyroxine
Relative
<ul style="list-style-type: none"> • Dehydration** <ul style="list-style-type: none"> - Splenic contraction

*rare **most common

acute, overwhelming demand due to inflammation and is often accompanied by a left shift. The neutrophils often exhibit toxic change. An examination of a bone marrow aspirate/biopsy should be performed for any persistent, unexplained neutropenia.

A lymphocytosis is an increase in total lymphocytes above the reference interval (**Table 6**). Physiologic and reactive lymphocytosis are the most common causes; however a lymphoproliferative disorder should always be considered, particularly in older dogs. Careful attention should be paid to the morphologic appearance of the lymphocytes; large, immature lymphocytes, regardless

of the lymphocyte count, indicate an acute lymphoproliferative process. Physiologic lymphocytosis is caused by a release of catecholamines related to excitement, fear, or pain; in this situation the lymphocyte count is typically around twice the upper reference interval and transient, with all the lymphocytes small and normal in appearance. Reactive lymphocytosis is in response to antigenic stimulation and reactive lymphocytes may be observed on the blood film. Rarely, the lymphocyte count may exceed 30,000/ μ L with antigenic stimulation and significant lymphocytosis has been observed with *Ehrlichia canis* infection. Molecular testing is indicated to differentiate a lymphoproliferative disorder from a reactive lymphocytosis, particularly if there is a persistent, chronic lymphocytosis of any magnitude or lymphocytes with an atypical appearance.

■ Clinicopathologic findings in common geriatric diseases

Whilst space does not allow for an exhaustive discussion on the typical blood abnormalities that may accompany all canine diseases, it is pertinent to review the clinicopathological findings for the most common disorders of older dogs, namely renal and liver disease, diabetes mellitus and hypothyroidism. Hyperadrenocorticism is discussed fully in the paper on page 46.

Renal disease

Chronic renal disease is commonly encountered in geriatric patients. The ability of kidneys to remove metabolic waste and reabsorb necessary substances may become impaired as the dog ages, and clinical signs vary depending on the duration and scope of the renal impairment. Early clinical signs may include polyuria and polydipsia (PU/PD). As the disease progresses and uremia worsens, other signs such as anorexia, lethargy, vomiting, diarrhea, and neurological abnormalities (seizures, coma) can occur. Expected clinicopathologic abnormalities in chronic renal disease include azotemia, an increase in non-protein nitrogenous waste in the blood which is detected as increased serum urea nitrogen (BUN) and creatinine (Cr) concentration on the biochemistry profile. This is due to a considerably reduced glomerular filtration rate (GFR), which is caused by an estimated 75% (or more) loss of functional renal mass. Creatinine is the more reliable indicator of GFR because the rate of production and excretion are relatively constant, whereas urea nitrogen concentrations may be affected by high protein meals and gastrointestinal hemorrhage and dehydration. Elevations of serum BUN and Cr must be interpreted in light of the urine specific

gravity (USG); in dogs with chronic renal disease, the USG is commonly isosthenuric (1.008-1.012). When interpreting the significance of the azotemia, remember that various factors can decrease USG (**Table 7**) and thus mimic primary renal disease.

Other abnormalities that are often present in dogs with chronic renal disease are: anemia, due to decreased erythropoietin production; hyperphosphatemia; hypocalcemia; increased serum amylase and lipase concentrations; and decreased bicarbonate concentration. Mild proteinuria may be detected on the urinalysis multiple-reagent test strips – this is caused by small proteins that are normally present in the glomerular filtrate but which are not reabsorbed by the impaired tubules; the proteinuria is usually slight and often variable.

Glomerular disease (amyloidosis or glomerulonephritis) may be encountered in older dogs. Clinical presentations result from intravascular fluid shifting into tissues or body cavities consequent to diminished oncotic pressure gradients, so that body cavity effusions and tissue edema may be noted. Potential thrombi formation, due to the renal loss of antithrombin, may cause dyspnea, tachycardia, and weak pulses, and hypertension is common. Clinicopathologic findings include marked proteinuria, marked hypoalbuminemia, and hypercholesterolemia. Renal azotemia may be present if the lesion is severe, but is often not present in earlier stages of the disease. To identify actual protein loss, additional testing includes the urine protein:creatinine ratio (UPC) which compares the urine protein concentrations with the constant rate excretion of creatinine; the UPC is typically < 0.5 in healthy dogs.

Liver disease

Liver enzyme elevations in older dogs should always be investigated. These elevations may not be directly related to primary liver disease but rather reflect the liver's response to other systemic or metabolic illnesses. Since non-hepatic conditions can induce increased hepatic enzyme activity, finding the cause often involves other diagnostic tests to assess liver function, such as imaging studies, needle aspirates for cytology, and/or biopsy for histology.

Alkaline phosphatase (ALP), an inducible and cholestatic enzyme, may be elevated in older dogs without obvious clinical signs, and elevations may not be related to primary liver disease (**Table 8**). Alanine transaminase (ALT) is present pre-formed in the cytosol of hepatocytes and an increase in serum concentration typically signals

Table 4. Causes of neutrophilia.

<p>Inflammation</p> <ul style="list-style-type: none"> • Infectious (bacterial, viral, fungal, rickettsial, protozoal) • Immune-mediated hemolytic anemia • Tissue necrosis – any cause • Sterile inflammation/foreign body
<p>Steroid response</p> <ul style="list-style-type: none"> • Stress (from any cause), chronic pain • Hyperadrenocorticism • Corticosteroid therapy (oral, otic, ophthalmic, parenteral, topical)
<p>Physiologic (epinephrine) response</p> <ul style="list-style-type: none"> • Excitement, fear, pain, anxiety, exercise
<p>Neoplasia</p> <ul style="list-style-type: none"> • Paraneoplastic syndrome • Chronic granulocytic leukemia
<p>Other</p> <ul style="list-style-type: none"> • Early estrogen toxicity

Table 5. Causes of neutropenia.

<p>Inflammation</p> <ul style="list-style-type: none"> • Acute, overwhelming inflammation • Overwhelming bacterial sepsis • Endotoxemia
<p>Decreased production</p> <ul style="list-style-type: none"> • Infectious – ehrlichiosis, parvovirus, histoplasmosis • Medication – chemotherapeutic agents, estrogen, phenylbutazone, griseofulvin • Myelophthisis – leukemia, multiple myeloma, myelofibrosis, other neoplasms • Myelodysplastic syndrome • Bone marrow necrosis
<p>Immune-mediated</p>

Table 6. Causes of lymphocytosis.

<p>Epinephrine response</p> <ul style="list-style-type: none"> • Excitement, pain, fear, exercise, anxiety • Catecholamine injection (epinephrine, norepinephrine)
<p>Chronic antigenic stimulation</p> <ul style="list-style-type: none"> • Infectious, especially from <i>Ehrlichia canis</i> and fungal, viral, or protozoal agents
<p>Hypoadrenocorticism</p>
<p>Thymoma</p>
<p>Lymphoproliferative disorder</p>

Table 7. Select causes of decreased urine specific gravity.

<ul style="list-style-type: none"> • Diuretic administration • Glucocorticoid administration (including topical) • Fluid therapy • Pyometra • Hypercalcemia • Hyponatremia/hypochloremia • Hypokalemia • Liver failure • Hypoadrenocortism • Hyperadrenocortism • Psychogenic polydipsia • Diabetes mellitus • Diabetes insipidus
--

Table 8. Select causes of increased serum ALP activity in older dogs.

<p>Drugs</p> <ul style="list-style-type: none"> • Corticosteroids (from any administration route) • Anticonvulsants
<p>Cholestasis</p> <ul style="list-style-type: none"> • Hepatic bile flow obstruction — hepatocyte swelling, hepatitis, neoplasia • Post-hepatic bile flow obstruction/bile duct obstruction — pancreatitis, cholangitis, neoplasia
<p>Osteoblastic activity</p> <ul style="list-style-type: none"> • Osteosarcoma or other bone neoplasia • Healing fracture
<p>Endocrine</p> <ul style="list-style-type: none"> • Hyperadrenocorticism (steroid induction) • Diabetes mellitus • Hypothyroidism • Hyperparathyroidism
<p>Other</p> <ul style="list-style-type: none"> • Mammary gland neoplasia • Breed related (Siberian Husky, Scottish Terrier)

Table 9. Non-thyroid factors that can cause decreased tT₄ concentration.

<p>Medications</p> <ul style="list-style-type: none"> • Glucocorticoids, phenobarbital, carprofen, furosemide, phenylbutazone, and sulfa-based drugs
<p>Non-thyroid illness</p> <ul style="list-style-type: none"> • Hyperadrenocorticism, inflammatory diseases
<p>Other</p> <ul style="list-style-type: none"> • Breed related (sighthounds)

hepatocellular injury. The magnitude of the elevation may indicate the extent of hepatocellular injury, but does not differentiate reversible from irreversible damage.

To assess liver function, serum bile acid testing can be performed. Bile acids are made in the liver, stored in the gall bladder and released into the small intestine to aid in the emulsification of dietary lipids. Normally bile acids are absorbed from the intestines and efficiently retrieved from the portal circulation; reduced clearance from the portal circulation results from decreased liver function, which is characterized as increased serum bile acid concentration. Inflammatory, metabolic, acquired porto-systemic shunts and degenerative conditions may cause enough loss of hepatic function to increase serum bile acid concentration. Measuring serum bile acid concentration is particularly useful when monitoring dogs receiving medications (e.g., glucocorticoids, phenobarbital) recognized to cause hepatopathy, but such drugs also induce non-hepatic increases in liver enzyme activity.

Diabetes mellitus

Diabetes mellitus (DM) can occur at any age but is most common in elderly dogs. Certain risk factors may predispose animals to acquiring this illness, including hyperadrenocorticism and chronic pancreatitis, and long-term medication treatment with glucocorticoids or progestins.

Common clinical signs of uncomplicated DM include weight loss, polyphagia, PU/PD, dull hair coat, lethargy, hepatomegaly, and cataract formation. Additional clinical signs in complicated DM include neurologic impairment, weakness, and coma. Serum glucose concentration may be elevated as a physiologic response to excitement, pain, and fear, or due to endogenous or exogenous corticosteroids, but rarely does it exceed the renal threshold for glucose of 180 mg/dL (10 mmol/L) – the normal glycemic reference interval is 75-120 mg/dL (4.16-6.67 mmol/L). Diabetes mellitus is diagnosed on the basis of persistent hyperglycemia, glycosuria and clinical signs. Clinicopathologic abnormalities that are typically encountered with uncomplicated DM include elevated serum glucose concentration, increased liver enzyme activity (reflecting altered lipid metabolism and the subsequent development of hepatic lipidosis), hypercholesterolemia, hypertriglyceridemia, and glycosuria. Urinalysis may also reveal evidence of a urinary tract infection. Additional clinicopathologic findings in complicated DM include ketonuria, electrolyte irregularities, and decreased plasma bicarbonate concentration, indicating metabolic acidosis.

Hypothyroidism

Common clinical signs associated with hypothyroidism include obesity, skin disease (including hair loss or excessive shedding, dry hair coat, excessive scaling, hyperpigmentation, and recurrent skin/ear infections), lethargy, mental dullness, exercise intolerance, and cold intolerance. Neurologic signs are an uncommon presentation and include seizures, neuromuscular disorders, and peripheral neuropathies related to the severe hyperlipidemia that sometimes occurs.

Clinicopathologic findings may include a mild, non-regenerative anemia, mild elevations in liver enzyme activity, and elevations in serum cholesterol and triglyceride concentrations. In dogs suspected of hypothyroidism, a screening serum total T_4 (tT_4) concentration can be performed. This assay measures both free and protein-bound thyroid hormone, and concentrations may be affected by other factors including non-thyroid illness and certain medications (**Table 9**). “Euthyroid sick syndrome” refers to non-thyroidal illnesses that result in a suppression of the circulating

thyroid hormone concentration. Low-normal to below the reference interval tT_4 concentrations in a dog suspected of thyroid disease requires additional testing, which should include free T_4 (fT_4) and thyroid stimulating hormone (TSH) assays. Free T_4 is the non-protein bound hormone available to cells and, in theory, is a better indicator of thyroid function. In dogs suspected of thyroid disease, serum tT_4 and fT_4 concentrations are decreased below the reference interval and TSH is often increased above the reference interval.


Conclusion

As noted at the start of this paper, early detection of disease is often essential for successful treatment and/or a superior quality of life for geriatric canines. It is therefore imperative that the clinician has a good knowledge of the common causes that lie behind hematological and/or biochemical abnormalities, and acts accordingly to benefit the patient. However, it is also prudent to be aware that results can sometimes be affected by parameters which can lead to misinterpretation of the blood results and potentially mistreatment!

Further reading

- Thrall MA, Weiser G, Allison RW, *et al.* *Veterinary Hematology and Clinical Chemistry*. 2nd ed. Ames, IA:Wiley-Blackwell, 2012; 61-140, 401-440, 497-544.
- Stockham SL, Scott MA. *Fundamentals of Veterinary Clinical Pathology*. 2nd ed. Ames, IA: Blackwell, 2008;53-222, 675-706, 783-830.
- Latimer KS. *Duncan & Prasse's Veterinary Laboratory Medicine Clinical Pathology*. 5th ed. Ames, IA: Wiley-Blackwell, 2011;3-82, 211-230, 253-282, 295-330.

Weight loss in the older cat



■ **Diego Esteban Saltiveri, DVM**
Tot Cat Clínica Felina, Barcelona, Spain

Dr. Esteban graduated from the Veterinary School of Universitat Autònoma de Barcelona (UAB) in 1998. After a year in first opinion small animal practice he moved to an exclusively feline clinic where he is currently responsible for internal medicine cases. Dr. Esteban is a former treasurer and current member of the scientific board of GEMFE (the Feline Study Group of the Spanish Small Animal Veterinary Association), and is also a member of the International Society of Feline Medicine (ISFM). He has published several papers in clinical journals and has spoken on feline internal medicine topics at both national and international scientific events.



■ **Albert Lloret, DVM**
Fundació Hospital Clínic Veterinari, Faculty of Veterinary Medicine, Universitat Autònoma de Barcelona, Spain

Dr. Lloret graduated in Veterinary Medicine at UAB in 1990 and spent seven years in small animal private practice before being appointed clinical instructor in the Internal Medicine Service at the UAB Veterinary Teaching Hospital. A member of the ISFM Veterinary Subcommittee, he is a former chairman of GEMFE and serves on the European Advisory Board in Cat Diseases. As a recognized expert on internal medicine he is frequently invited to speak at veterinary congresses, and has authored or co-authored clinical papers which have been published in both national and international journals. Dr. Lloret's specific areas of interest are feline medicine and oncology.

■ Introduction

Weight loss is a very common, but non-specific, clinical sign in older cats. It may be accompanied by other signs (e.g., diarrhea, vomiting and polyuria/polydipsia) which may help pinpoint a definitive diagnosis, but frequently

there are no other obvious clinical findings. Weight loss may be the result of reduced calorie and nutrient intake, or increased metabolism. A reduction in calorie intake may be due to inadequate food consumption secondary to anorexia or oral lesions, or deficient absorption or digestion (despite a normal appetite) as a result of gastrointestinal, hepatic, biliary or pancreatic disease. Weight loss may also be caused by inefficient metabolism of nutrients after absorption (e.g., diabetes mellitus), whilst increased metabolism and calorie requirements are associated with certain diseases such as hyperthyroidism and some neoplastic conditions (cancer cachexia). The nature of the disease causing the weight loss determines if the appetite is affected; diabetes mellitus and hyperthyroidism are both frequently characterized by weight loss in spite of a normal or markedly increased appetite, whilst in gastrointestinal or neoplastic disorders the appetite may initially be normal or increased – although more commonly it is diminished, particularly if such diseases are inflammatory or there is systemic involvement.

Table 1 provides a summary of the diseases that are characterized by weight loss in geriatric cats. The most common conditions include chronic kidney disease (CKD), hyperthyroidism, diabetes mellitus (DM), and

KEY POINTS

- **Weight loss is a very common, but non-specific, presentation in older cats; other clinical signs may or may not be obvious.**
- **It is important to weigh animals whenever they attend the practice throughout their lifetime; even the smallest weight loss in an older cat may be significant.**
- **A good clinical history must always be obtained; this should include details of the cat's lifestyle and environment, and any possible changes in diet.**
- **If the cause of the weight loss is not obvious from the medical history and physical examination, blood and urine samples should be submitted for basic laboratory tests, with supplementary investigations performed as necessary.**

infiltrative gastrointestinal problems (inflammatory or lymphoma). Some cats may be presented in an advanced state of weight loss, particularly if there are no other clinical signs to prompt the owner to seek veterinary care. However, if the cat was previously overweight or obese it can be difficult to discern weight loss in the early stages of disease, and it is therefore important for the clinician to make a point of routinely weighing animals as they present for various consultations throughout their life. Even the smallest weight loss in an older cat may be significant and can justify at least a minimal diagnostic assessment.

■ History and physical examination

Understanding the medical history is essential, particularly if the clinician is to determine the presence of significant factors other than weight loss, such as polyuria, polydipsia, vomiting, diarrhea, and behavioral changes. A good history should include details of the lifestyle and environment of the cat and any possible changes in diet. Occasionally weight loss may result not from disease but from insufficient food or changes in the environment – competition with other cats should also be considered. A thorough, systematic physical examination is essential, and should include: examination of the oral cavity, palpation of the thyroid area, cardiac auscultation, abdominal evaluation, ophthalmic examination, palpation of the muscles and joints (including an assessment of muscle condition score) (1), and a basic neurological assessment.

A comprehensive list of the findings should then be drawn up to determine the likely differential diagnoses and identify the most appropriate diagnostic tests.

■ Basic diagnostic testing

If the cause of the weight loss is not obvious after gathering the history and conducting a clinical exam, basic laboratory tests and imaging should be considered (*Table 2*).

Biochemistry and hematology tests. The differential blood count does not usually provide a definitive diagnosis, but certain changes may help narrow down the list of possible diagnoses. These include the presence of normochromic, normocytic anemia (suggestive of renal, chronic inflammatory, or neoplastic disease), microcytosis (*e.g.*, gastrointestinal hemorrhage), polycythemia (*e.g.*, hyperthyroidism), or leukocytosis (*e.g.*, inflammatory or neoplastic disease). In many cases serum biochemistry can provide a definitive diagnosis, but other tests such as urinalysis may be essential, with a collective interpretation of all the results.

Urinalysis. This is underutilized by many veterinarians but should be performed routinely, even if it is difficult to obtain a sample; commercial kits are available with inert artificial cat litter to facilitate urine collection at home. The presence of dilute urine (where the urine specific gravity (USG) is 1.012-1.020) can be the earliest indicator of renal disease before azotemia develops. Glycosuria along with hyperglycemia may indicate diabetes mellitus, provided that stress-induced hyperglycemia has been ruled out. Proteinuria can be an indicator of glomerulopathy and should be quantified by determining the urine protein:creatinine ratio (UPC). The presence of an active sediment (as demonstrated by urinary casts or leukocytes), significant proteinuria, or reduced USG should prompt urine culture, preferably on a sample obtained by cystocentesis.

Thyroid tests. Total thyroxine (tT_4) analysis is extremely useful in confirming hyperthyroidism, but it is important to interpret the values correctly. If the level is above the upper range the diagnosis is confirmed, but some affected cats can have a tT_4 value within the upper limit of the normal range, either because the hyperthyroidism is mild or because another non-thyroid disease (*e.g.*, CKD) is present, which suppresses tT_4 levels (euthyroid sick syndrome). If there is a very high clinical suspicion of hyperthyroidism (weight loss, enlarged thyroid mass), it is acceptable to start therapy; if in doubt, a free T_4 (fT_4) analysis should be requested, but the result should always be interpreted in conjunction with the tT_4 level.

Table 1. Geriatric diseases with weight loss as a primary finding.

More common
Chronic kidney disease (CKD)**
Diabetes mellitus*
Hyperthyroidism*
Neoplasia (cancer cachexia)***
Intestinal inflammatory disease***
Chronic pancreatitis***
Less common
Acromegaly*
Hyperadrenocorticism*
Glomerulonephritis***
Heart failure (cardiac cachexia)**
Feline immunodeficiency virus**
Feline infectious peritonitis**
Periodontal disease/chronic stomatitis**
Central nervous system disease/cognitive dysfunction***
Osteoarthritis***

* typically characterized by polyphagia or normal appetite ** typically characterized by anorexia *** anorexia or normal appetite depending on the stage of the disease

Table 2. Minimal or initial diagnostic tests in the older cat with weight loss.

- Complete blood count
- Serum biochemistry (including electrolytes)
- Complete urinalysis (specific gravity by refractometer, "dipstick" urine strip, sediment, protein:creatinine ratio)
- Total serum thyroxine (tT₄) concentration
- Screening for feline leukemia virus and feline immunodeficiency virus
- Radiographs of the thorax, abdomen, and joints
- Blood pressure measurement

since fT₄ is elevated in a significant percentage of normal cats. Alternatively, assessment of canine TSH* (cTSH) levels can be useful in cases where tT₄ is in the high normal range, or – if available – scintigraphy can be confirmatory.

Virus testing. Screening for feline leukemia virus (FeLV) and feline immunodeficiency virus (FIV) should be performed in any sick cat, in particular those that roam freely and are therefore possibly exposed to infection through contact with other cats. In many cats, FIV infection can remain asymptomatic for years, with clinical signs associated with infectious, inflammatory, or neoplastic disease (secondary to immunosuppression) only appearing at an advanced age.

Radiography. Thoracic radiography is useful for ruling out the presence of a pulmonary tumor (whether primary or metastatic) and the cardiac silhouette should be assessed for evidence of cardiomegaly (which may suggest a cardiomyopathy). Abdominal radiographs can demonstrate the presence of organomegaly or some non-palpable abdominal masses. In cats with CKD it is particularly useful to check for renal or ureteral calculi, a common cause of chronic kidney disease. Animals with lameness or musculoskeletal pain should be evaluated for radiographic signs of osteoarthritis.

Blood pressure assessment. It is important to determine blood pressure in cats diagnosed with CKD or hyperthyroidism, since hypertension is very prevalent in both conditions and, if untreated, can result in severe damage to the kidneys, retina, and central nervous system.

■ Advanced diagnostic testing

If a definitive diagnosis has not been reached following the above tests, or if renal or gastrointestinal disease

* The canine TSH-assay has been shown to be suitable for assessment of feline TSH levels.

has been diagnosed without any obvious cause, further investigations are warranted (**Table 3**).

Abdominal ultrasound. This is indicated if there is no definitive diagnosis or if there are gastrointestinal, urinary or hepatic signs. Imaging may reveal the presence of occult intra-abdominal neoplasia, pancreatic abnormalities associated with chronic pancreatitis, and intestinal changes and mesenteric lymphadenopathy compatible with infiltrative intestinal disease (**Figure 1**). In cats with CKD, ultrasonography can be useful to determine the etiology (e.g., nephrolithiasis or lymphoma), whilst for cats with hypokalemia and/or hypertension imaging can reveal adrenal hyperplasia or neoplasia, which may suggest hyperaldosteronism. In diabetic cats, ultrasonography is useful to rule out associated pancreatitis and adrenal gland enlargement, which might indicate hyperadrenocorticism or acromegaly (**Figure 2**). Finally, the technique can allow guided biopsies for cytology or histology of various organs.

fPLI assay. Feline pancreatic lipase immunoreactivity testing is a useful, non-invasive method to diagnose pancreatitis, particularly when combined with pancreatic ultrasonography. Sensitivity is very high (near 100%) for moderate and severe cases of pancreatitis, and specificity is excellent for cats that do not have the disease. It is indicated if a diagnosis has not been determined, or when ultrasonography suggests the presence of pancreatic lesions.

Table 3. Advanced diagnostic tests for an older cat with weight loss.

- Urine culture (if active sediment, isosthenuria, or if CKD, DM or proteinuria is detected)
- Abdominal ultrasound
- fT₄ assay or cTSH (if hyperthyroidism is suspected and tT₄ is at the upper limit of normal)
- fPLI assay
- Echocardiography
- Biopsy and histopathology
- Insulin-like growth factor 1 (IGF-1) (in insulin-resistant diabetic cats or if acromegaly is suspected)
- Aldosterone and renin assay (in cats with hypokalemia and/or hypertension, whether or not associated with CKD)
- Central nervous system MRI (for cases of acromegaly or hyperadrenocorticism, where there are abnormalities in neurological exam, or if there is no diagnosis after other tests have been completed)

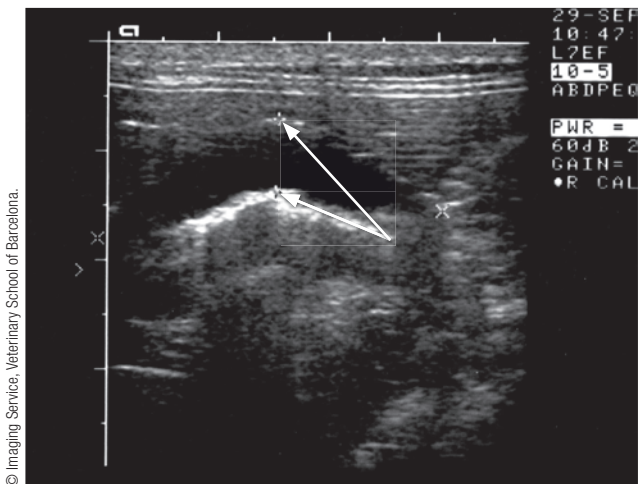


Figure 1. Abdominal ultrasonography can be a valuable diagnostic aid. Here it reveals thickening of the intestinal wall with loss of the normal layering, suggesting infiltrative intestinal disease. Intestinal lymphoma was confirmed by histology.

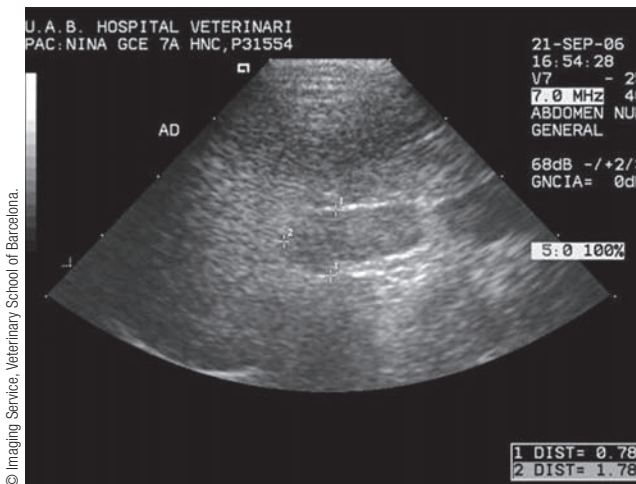


Figure 2. Enlarged bilateral adrenal glands, as revealed by ultrasonography, may suggest hyperadrenocorticism or hyperaldosteronism depending on the clinical findings and biochemical and endocrine tests.

Biopsy. If infiltrative intestinal disease is diagnosed on clinical signs, the only way to determine whether it is inflammatory or neoplastic is by performing intestinal biopsies for histopathology, obtained by guided ultrasonic imaging, endoscopy or exploratory laparotomy. Pancreatic biopsy is sometimes the only method to confirm pancreatitis, although – as noted above – the diagnosis can often be obtained by a combination of ultrasonography and fPLI testing.

Magnetic resonance imaging. MRI of the brain can be useful if acromegaly and/or hyperadrenocorticism is diagnosed or suspected to verify if a pituitary tumor is present. It should also be considered in cats where there is no definitive diagnosis after all the previous diagnostic tests have been performed to rule out intra-cranial neoplasia.

In summary, definitive diagnosis in an older cat that has lost weight can require an extensive work-up, and the clinician must be wary of co-morbidities. Two case studies illustrate this.

■ Clinical case 1

Chips was a 16-year-old spayed female domestic cat presented with weight loss over several months (**Figure 3**), accompanied by occasional episodes of vomiting. The owner noted that she was having difficulty climbing and jumping.

Medical history

Chips had lived with her owners since she was three

months of age and was fed a mixture of dry and wet commercial food; appetite had been good until a few days previously, since when it had diminished. There had been no previous major medical conditions and she was up to date with her vaccinations and anti-parasitic treatments. Over the last few years she had free access outside.

Physical examination

The body condition score was 2/5 with a body weight of 3.2 kg. The cat was well-hydrated and had a rectal temperature of 38.5° C (101.3 ° F). Examination revealed muscle atrophy (particularly of the posterior limbs) and pain on manipulation of the hips. The mucosae were normal, and ocular fundus examination and thoracic auscultation noted no abnormalities. Abdominal palpation demonstrated small kidneys and palpation of the neck revealed moderate bilateral enlargement of the thyroid glands.

Differential diagnosis

The significant findings in this case were weight loss, slight enlargement of the thyroid glands, occasional vomiting and hip pain. The differential diagnosis for the weight loss included the following diseases: metabolic (CKD, hepatopathy, pancreatitis), endocrine (diabetes mellitus, hyperthyroidism), gastrointestinal (infection, inflammatory intestinal disease), neoplastic (lymphoma, carcinoma, metastasis), cardiac (cardiomyopathy), and cognitive dysfunction.

An enlarged thyroid gland was suggestive of hyperthyroidism. The most likely causes of the sporadic vomiting

included metabolic, endocrine, and gastrointestinal diseases. The pelvic pain could have been due primarily to osteoarthritis or inflammatory, compressive or neoplastic lesions of the spinal column.

Diagnostic plan

Blood and urine samples were collected. The main findings (**Table 4**) were azotemia, mild hyperglycemia, hypokalemia, and hyperphosphatemia, elevated tT_4 , proteinuria, elevated UPC and low USG. The rest of the parameters were normal and FeLV/FIV tests were negative, as was the urine culture. Thoracic radiography showed no notable changes but radiographs of the coxofemoral joints revealed degenerative changes in keeping with osteoarthritis. The results of the initial tests were suggestive of proteinuric Stage 2 CKD (International Renal Interest Society staging system for CKD in dogs and cats), hyperthyroidism, and osteoarthritis.

Further testing was warranted, and blood pressure by a Doppler method showed systolic arterial pressure to be 150 mmHg (normal 90-150 mmHg). Abdominal

ultrasonography demonstrated small, hyperechoic kidneys (**Figure 4**), in keeping with diffuse chronic interstitial nephritis, and increased echogenicity in some areas of the pancreas (**Figure 5**) together with the presence of multiple small (0.4-0.6 cm) hypoechoic foci. There was also a small amount of free fluid around the pancreas with mild mesenteric lymphadenopathy, consistent with chronic pancreatitis, nodular hyperplasia, or pancreatic neoplasia. The fPLI was 7.3 $\mu\text{g/L}$ ($N = < 5.3$), compatible with the presence of active pancreatitis; a pancreatic biopsy was not taken given the age of the patient and the presence of other pathologies.

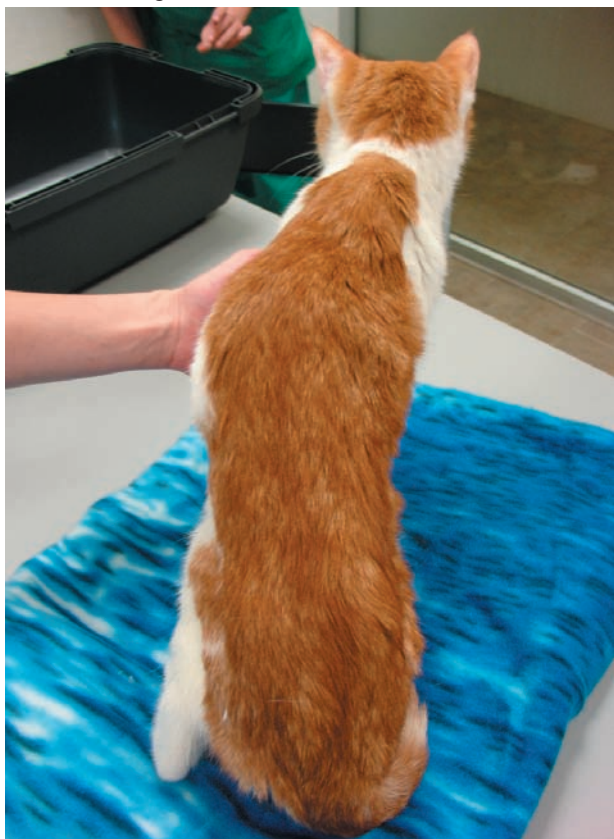
Therapy

Treatment was initiated with the feeding of a prescription diet for renal disease, benazepril 1.25 mg PO q24H (to control the proteinuria), methimazole 2.5 mg PO q24H (to control the hyperthyroidism), maropitant 4 mg PO q24H (to control the nausea), and buprenorphine 0.06 mg IM q12H (to relieve osteoarthritic pain). The low dose of methimazole was chosen with the objective of treating the hyperthyroidism without reducing the glomerular filtration rate and compromising renal perfusion, and a further blood sample was taken after three days to verify that the pre-existing azotemia had not worsened. This showed only a slight increase in comparison with the initial results. The tT_4 decreased to 41.2 mmol/L, and so the initial treatment regime was maintained.

Discussion

This case illustrates how an older cat can suffer from multiple concurrent conditions, which can complicate diagnosis; for example, it can be difficult to establish which disease is causing the clinical signs. It can also make for complicated treatment regimes. In the case of Chips, the gradual weight loss was probably caused by the concomitant presence of three diseases; whilst the occasional vomiting may have been due to any of the conditions, the active pancreatitis was perhaps the main cause of both the vomiting and the poor appetite. Many older cats suffer from mild, chronic subclinical pancreatitis which can flare up as an acute episode with the development of clinical signs. The optimal treatment for chronic pancreatitis is still debatable, although corticosteroids can be useful, particularly if there is concurrent cholangitis or inflammatory intestinal disease. In this case, corticosteroids were not given because of the CKD and hyperthyroidism, but six months after starting treatment, Chips had maintained her weight and the benazepril and methimazole medications were continued.

Figure 3. Dorsoventral view of “Chips” with typical signs of chronic weight loss.



© Dr. Albert Lloret

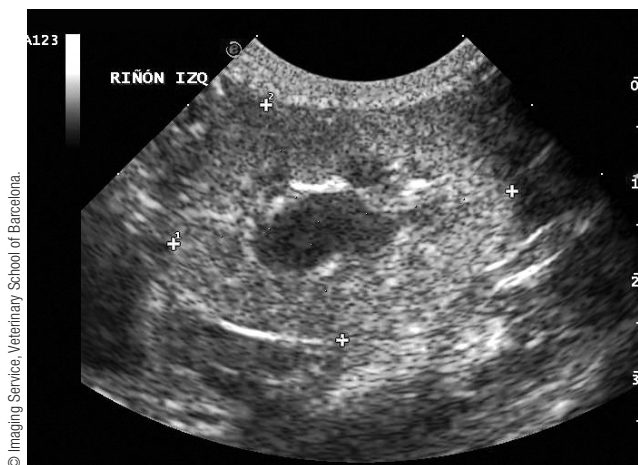

Figure 4. Ultrasound is important when evaluating kidney disease in cats, especially to check for renal or ureteral uroliths. Small, irregular hyperechogenic kidneys in older cats with CKD are usually due to chronic interstitial nephritis.

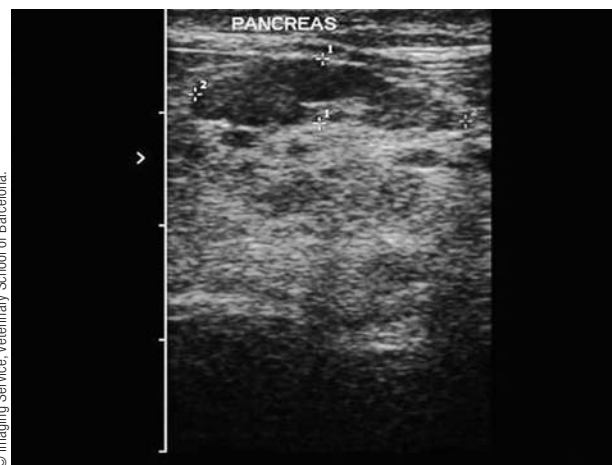

Figure 5. Ultrasound of the pancreas is very useful. In this case the pancreatic tissue is enlarged and shows increased echogenicity, along with fluid around the pancreas, suggesting an inflammatory disease.

The azotemia remained stable, tT_4 was held within the upper half of the normal range and the UPC was 0.8 ($N = < 0.4$). Occasional vomiting was still noted but her quality of life was good.

■ Clinical case 2

Mini, a 13-year-old spayed female tortoiseshell domestic shorthair, was presented for vomiting and anorexia that had started four days previously. The owner had not noted any increase in water intake or urination, and thought she had possibly drunk less than usual. She had not been seen to pass any feces recently.

Medical history

Mini was up to date with vaccinations and antiparasitic treatment and had undergone regular check-ups at the clinic since she was five years of age; no problems had been noted during that period. She lived indoors with no other pets and was fed only a dry commercial food.

Her last recorded weight, taken seven months ago, was 4.78 kg.

Physical examination

Mini was alert and weighed 4.04 kg (approx. 15% weight loss). Rectal temperature was normal and the mucosae were pink; cardiopulmonary auscultation demonstrated no abnormality but dehydration was assessed at 5%.

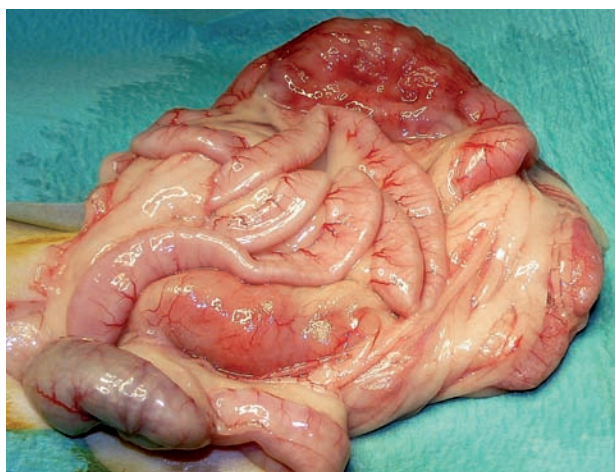Abdominal palpation revealed two walnut-sized masses, one of which seemed to be confluent with the intestine. Pain was elicited on palpation of the second mass. The urinary bladder was slightly distended and the kidneys felt normal in size and shape. No changes were detected on palpation of the liver or spleen, and there were a few well-formed fecal pellets in the lower colon.

Differential diagnosis

The significant findings in this case were the abdominal

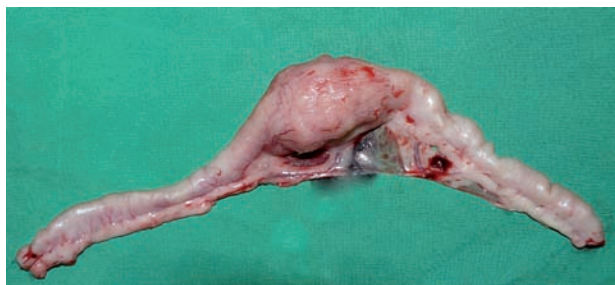Table 4. Significant findings on blood and urine sampling from “Chips”.

Parameter	Result	Reference range
Creatinine	214.8 μ mol/L (2.42 mg/dL)	70.7-141.4 μ mol/L (0.8-1.56 mg/dL)
Urea	65 mmol/L (182 mg/dL)	15-22.8 mmol/L (42-63.9 mg/dL)
Glucose	10.94 mmol/L (196.92 mg/dL)	4.05-7.4 mmol/L (72.9-133.2 mg/dL)
Potassium	3.63 mmol/L (11.23 mg/dL)	4-5.5 mmol/L (15.64-21.5 mg/dL)
Phosphate	2.02 mmol/L (6.25 mg/dL)	1.29-1.93 mmol/L (3.99-5.97 mg/dL)
tT_4	43.7 nmol/L (3.4 μ g/dL)	14.2-41.2 nmol/L (1.1-3.22 μ g/dL)
USG	1.020	1.030-1.055
UPC	1.7	< 0.4



© Dr. Albert Lloret

Figure 6. The intestinal mass and enlarged mesenteric lymph node at surgery.



© Dr. Albert Lloret

Figure 7. The intestinal mass after resection, showing wide surgical margins. These are essential, especially for intestinal adenocarcinomas, where a minimum of 5-10 cm should be allowed.

masses, vomiting, anorexia, weight loss and dehydration. The differential diagnoses included intestinal neoplasia or granuloma, intussusception, foreign body, and necrotizing pancreatitis with inflammation of the abdominal fat. The anorexia and weight loss could be attributed to any of the aforementioned causes and/or to the presence of metabolic or electrolytic changes resulting from vomiting.

Diagnostic plan

Since this was an elderly cat, it was important to determine her renal, hepatic, and thyroid status. The absence of stools in the last few days, along with vomiting, increased the suspicion of an intestinal obstruction. Blood tests (including tT_4 levels and screening for FeLV/FIV), urinalysis and abdominal ultrasonography were performed. The differential blood count, serum biochemistry, and tT_4 were all normal and urinalysis revealed a USG of 1.045 and pH of 6.5; the remainder of the parameters were within normal limits. Abdominal ultrasonography demonstrated one of the masses to be

intestinal in origin and the other to be in keeping with an enlarged mesenteric lymph node.

Many cats with abdominal masses do not exhibit any significant abnormality on blood work, but occasionally a non-regenerative anemia and hypoalbuminemia is found. Hypocobalaminemia is also usually present in cats with intestinal inflammatory diseases or lymphoma, with the latter often causing more severe changes. The presence of an intestinal mass of suspected neoplastic origin in an older cat is most commonly associated with gastrointestinal lymphoma, adenocarcinoma, or mastocytoma. Cytological examination of a fine needle aspirate (FNA) of a mass can provide an exact diagnosis but if there is intestinal obstruction this test may be superfluous. In the absence of obstruction, FNA may be a good option, and if lymphoma is the most likely diagnosis a renal or hepatic ultrasound-guided sample may be performed, because this is easier than an intestinal biopsy and has a high degree of positive correlation. Endoscopic biopsy is another option (if there is no intestinal obstruction) as visualization of a lesion can assist diagnosis, but the assessment of such biopsies is controversial, and in many cases accurate diagnosis requires multiple and/or full thickness samples.

Exploratory laparotomy provides the opportunity to take biopsies from multiple sites of interest and resolve any obstructions, and in this case surgery was recommended, revealing an intestinal mass and the suspected mesenteric lymphadenopathy (**Figure 6**). An enterectomy was performed (**Figure 7**) and a biopsy taken of the lymph node. There were no postoperative complications, and Mini was discharged after 48 hours.

Diagnosis

Histopathology of the intestinal mass confirmed a grade 2 intermediate-sized cell lymphoma with clear margins at either end of the section; there were no neoplastic changes in the mesenteric lymph node.

Outcome

Surgical resection of intestinal lymphoma is often associated with a poor outcome, although in this case surgery was justified because of the intestinal obstruction, which is usually indicative of a high-grade lymphoma. Chemotherapy is also considered necessary in these cases, and if satisfactory can result in prolonged survival times.

Mini had recovered her appetite post-operatively but became anorexic within two days of starting chemotherapy,

although there was no vomiting, pyrexia, or dehydration. Abdominal palpation suggested that the mesenteric lymph node had enlarged, and this was confirmed on ultrasound. A differential blood count revealed leukocytosis and lymphocytosis, with no significant changes in the red cells or platelets. Five days later the owners requested that Mini be euthanized. An autopsy confirmed that the lymphoma now involved the blood, bone marrow, mesenteric lymph nodes, liver, spleen, and omentum.

Discussion

Mini's case shows that even with a Grade 2 lymphoma (most cases are Grade 3 or 4) the outcome can be poor. However since no biopsies of the liver, spleen or bone marrow were taken at surgery, it was impossible to say if the lymphoma had been Grade 4 or 5 from the outset, although the absence of elevated transaminases, ultrasonographic changes of the spleen, or the leukogram would make this unlikely.

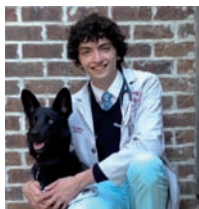Further reading and references

- Roudebush P, Polzin DJ, Ross SJ, *et al.* Therapies for feline chronic kidney disease; what is the evidence? *J Fel Med Surg* 2009;11:195-210.
- Forman MA, Marks SL, De Cock HE. Evaluation of feline pancreatic lipase immunoreactivity and helical computed tomography *versus* conventional testing for the diagnosis of feline pancreatitis. *J Vet Intern Med* 2004;18:807-810.
- Williams DA. Feline exocrine pancreatic disease. In: Bonagura JD, Twedt DC (eds). *Curr Vet Ther XIV Small Anim Pract*, St Louis, Saunders-Elsevier 2009;538-543.
- Wakeling J, Moore K, Elliot J, *et al.* Diagnosis of hyperthyroidism in cats with mild chronic kidney disease. *J Small Anim Pract* 2008;49:287-289.
- Patterson-Kane JC, Kugler BP, Francis K. The possible prognostic significance of immunophenotype in feline alimentary lymphoma: a pilot study. *J Comp Pathol* 2004;30:220-222.
- Moore AS, Ogilvie GK. Lymphoma. In: Moore AS (ed.) *Feline Oncology*. Trenton, NJ. Vet Learn Systems 2001;191-219.
- Valli VE, Jacobs RM, Norris A, *et al.* The histologic classification of 602 cases of feline lymphoproliferative disease using the National Cancer Institute working formulation. *J Vet Diag Invest* 2000;12:295-306.
- Kiselow MA, Rassnick KM, McDonough SP, *et al.* Outcome of cats with low-grade, lymphocytic lymphoma. In *Proceedings*, ESFM Feline Congress 2006;26.
- Waly NE, Gruffydd-Jones TJ, Stokes CR, *et al.* Immunohistochemical diagnosis of alimentary lymphomas and severe intestinal inflammation in cats. *J Comp Pathol* 2005;133:253-260.
- Matus RE. Chemotherapy of lymphoma and leukemia. In: Kirk RW (ed.). *Curr Vet Ther X. Small Anim Pract*. Philadelphia, WB Saunders 1989;482-488.

References

1. <http://www.wsava.org/guidelines/global-nutrition-guidelines>.


Canine hyperadrenocorticism



■ Bradley Bishop, BSc

Mississippi State University College of Veterinary Medicine, Starkville, Mississippi, USA

Bradley Bishop graduated from Mississippi State University with a Bachelor of Science in Biological Sciences in 2011 and is due to graduate from Mississippi State University College of Veterinary Medicine this year. At present he is performing clinical rotations and advanced electives during his final year of veterinary school. His primary area of interest is small animal endocrinology.



■ Patty Lathan, VMD, MS, Dipl. ACVIM

Mississippi State University College of Veterinary Medicine, Starkville, Mississippi, USA

Patty Lathan is an Associate Professor of Small Animal Internal Medicine at the Mississippi State University College of Veterinary Medicine. She attended college at Texas A&M University and veterinary school at the University of Pennsylvania, then completed an internship at Mississippi State University before finishing a residency in small animal internal medicine at Purdue University. Her primary interest is endocrine disease.

■ Introduction

Canine hyperadrenocorticism (HAC or canine Cushing's syndrome) is one of the more frequently encountered endocrinopathies in dogs, characterized by clinical signs of cortisol excess; the most common presenting signs

are polyuria and polydipsia. HAC can be caused by either an adrenal tumor (AT, 15% of cases) or a pituitary tumor, resulting in pituitary-dependent hyperadrenocorticism (PDH, 85% of cases). Iatrogenic hyperadrenocorticism, caused by excessive administration of glucocorticoids, is also possible. Adrenal tumors directly secrete excess cortisol, whereas with pituitary tumors excess adrenocorticotropic hormone (ACTH) is released, stimulating the adrenal cortex to secrete excess cortisol. Most cases of PDH are caused by a microadenoma, a tumor so small that it does not cause neurological signs. However, macroadenomas can also occur, and these may eventually lead to neurological disease.

KEY POINTS

- Naturally-occurring hyperadrenocorticism is a result of excess cortisol secretion, which is caused by either an adrenal or pituitary tumor. Physical examination and history findings are key to making a diagnosis.
- There are a variety of screening and differentiating tests for hyperadrenocorticism, and the clinician needs to exercise judgment in both the choice of test and interpretation of the results.
- Treatment is not recommended in patients if there are no clinical signs.
- Optimal treatment for patients with adrenal tumors is adrenalectomy, whereas medical treatment is recommended in patients with pituitary-dependent disease.

■ Clinical presentation

A thorough history and diligent examination are essential to begin the process of diagnosis. There are many clinical signs that may indicate a patient has HAC – and whilst a dog does not need to have all of the presenting complaints to be diagnosed, the more abnormalities present, the more likely it is that HAC is the correct diagnosis. It is also important to bear in mind that atypical presentations can occur. Patients with HAC are not usually “sick” – so if a dog presents with vomiting, diarrhea, or anorexia, HAC is unlikely to be the primary diagnosis, and any evaluation for it should be delayed until the other disease is identified and treated.

■ History and physical examination

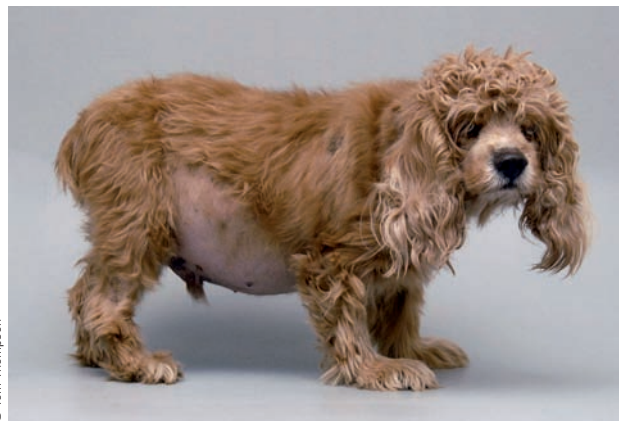The median age at presentation is between 10-12 years, and while any breed can be affected, small breed dogs are especially predisposed to PDH (2). However, approximately half of adrenocortical tumors (AT) are found in dogs weighing more than 20 kilograms. Females are slightly more likely to develop both PDH and AT than males (3).

The most common complaint voiced by owners is polyuria and polydipsia (PU/PD) (3,4); this is because cortisol decreases release of antidiuretic hormone (ADH) from the pituitary, inhibits ADH activity in the kidney, and causes psychogenic polydipsia. Polyphagia is also common, but constant begging to go outside or inappropriate urination are often the clinical signs that drive owners to take their dog to the clinic.

A pot-bellied appearance is common in dogs with HAC. Whilst affected animals are almost always polyphagic, the increase in abdominal size is rarely due to weight gain. Rather, hepatomegaly and weakening of the abdominal musculature from the catabolic effect of excess cortisol results in the pot-bellied appearance. Skin lesions are an extremely common finding; physical examination often reveals a bilaterally symmetric alopecia, sometimes only sparing the head and distal extremities. Other dermatologic signs include thin skin, hyperpigmentation, comedones, pyoderma, and *calcinosis cutis*.

Table 1 summarizes the typical clinical signs, while **Figure 1** depicts a Cocker Spaniel with the classical appearance of the disease.

Figure 1. This Cocker Spaniel has multiple classic clinical signs of hyperadrenocorticism, including a thin hair coat, abdominal distension and *calcinosis cutis*.



© Tom Thompson

Table 1. Initial history and physical examination findings in dogs presenting with HAC.

Most common	Less common
Polyuria	Thin skin
Polydipsia	<i>Calcinosis cutis</i>
Polyphagia	Hyperpigmentation
Abdominal distension	Comedones
Bilaterally symmetric alopecia	Lethargy
Pyoderma	Testicular atrophy
Hepatomegaly	Thromboembolism
Weakness	Ligament rupture

■ Laboratory testing

Prior to performing any HAC screening tests, routine laboratory diagnostics should be undertaken on any animal with suspicious clinical signs. In addition to providing evidence for HAC, these tests will help rule out other differential diagnoses and concurrent conditions. HAC screening tests should not be performed without significant suspicion from a combination of history, clinical signs and laboratory testing. No single abnormality from complete blood count, serum chemistry, or urinalysis is pathognomonic for the disease, but certain results may serve as an indication for further testing (5); common laboratory abnormalities are summarized in **Table 2**.

Complete blood count

Due to excessive production of cortisol, a stress leukogram (neutrophilia, monocytosis, lymphopenia, and eosinopenia) is often observed in affected animals. Mild thrombocytosis and polycythemia are occasionally present (1,5).

Serum chemistry

The most commonly increased value in dogs with HAC is the enzyme alkaline phosphatase (ALP), which is elevated in approximately 90% of cases. An increase in ALP is a sensitive indicator of HAC, but is not specific due to the presence of numerous isoenzymes of ALP (glucocorticoid-induced, hepatic, bone, placental, intestinal). Even though elevated ALP is common, as yet there is no evidence that the degree of elevation correlates with the likelihood of HAC being present, therefore an extreme increase in ALP is no more indicative of the disease than a mild increase. In addition, alanine amino-transferase (ALT) is frequently elevated due to swollen hepatocytes, accumulation of glycogen, or disruption of hepatic blood flow as a result of steroid hepatopathy (1).

Table 2. Common laboratory findings in patients with HAC.

Complete blood count	Serum chemistry	Urinalysis
Neutrophilia Monocytosis Lymphopenia Eosinopenia Thrombocytosis Mild erythrocytosis	Increased ALP Increased ALT Hyperglycemia (mild) Hypercholesterolemia Decreased BUN	Specific gravity < 1.020 Proteinuria Urinary tract infection* *often requires culture for diagnosis

Glucocorticoids result in hyperglycemia via two mechanisms: increased hepatic gluconeogenesis and insulin antagonization. However the increase is generally mild (< 150 mg/dL or 8.3 mmol/L) and concurrent diabetes mellitus is uncommon (5% of HAC cases). Serum cholesterol concentrations are increased in the majority of HAC dogs, as a result of glucocorticoid-stimulated lipolysis.

Blood urea nitrogen (BUN) is frequently decreased, as the diuresis related to PU/PD causes constant urinary loss of BUN and medullary washout.

Urinalysis

Since most affected dogs have PU/PD, urine specific gravity is usually < 1.020. Proteinuria is common, but rarely severe enough to cause hypoalbuminemia or hypoproteinemia. If the proteinuria is severe (urine protein:creatinine ratio > 2-3), another cause of protein-losing nephropathy should be suspected.

Due to immunosuppression from persistently high serum cortisol levels, urine culture should be performed on all suspected cases; approximately 50% of dogs with HAC have a urinary tract infection (UTI) at the time of examination (6). Since cortisol is anti-inflammatory, and the urine is dilute, an active sediment is not always present in HAC dogs with UTI's, so a urine culture should always be performed in affected dogs – and indeed as part of the workup for all PU/PD cases.

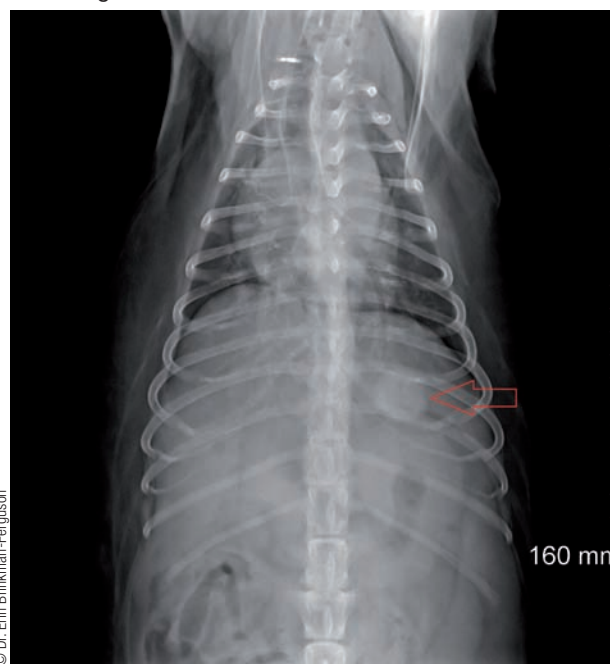
Diagnostic imaging

Diagnostic imaging is not mandatory for diagnosis and treatment of HAC, although it often helps to differentiate PDH from AT. However, given that most affected dogs are geriatric, abdominal and thoracic imaging may also help identify concurrent conditions such as neoplasia that should be addressed prior to treatment of hyperadrenocorticism.

Radiography

The most common radiographic change associated with HAC is hepatomegaly (7). In some dogs with adrenal tumors, unilateral adrenomegaly with mineralization is identified, although the presence of mineralization does not help differentiate between adenoma and carcinoma. If there is *calcinosis cutis*, peripheral soft tissue mineralization may be appreciated. Thoracic radiographs may reveal bronchial and tracheal mineralization, or pulmonary metastases from an adrenocortical carcinoma (**Figure 2**). Approximately 50% of adrenal tumors are carcinomas, and of these approximately 50% will have metastasized by the time of diagnosis (3).

Figure 2. Ventrodorsal thoracic radiograph of a 10-year-old female spayed Cocker Spaniel with HAC shows a mass in the left caudal lung lobe. The mass was incidental, emphasizing the utility of thoracic radiography at time of HAC diagnosis.



© Dr. Erin Brinkman-Ferguson

Abdominal ultrasonography

Ultrasonography is useful for assessing the adrenal glands and liver as well as identifying any concurrent disease. Evaluation of the size and shape of the adrenal glands may help differentiate between AT and PDH. Adrenal glands in PDH are usually bilaterally enlarged (> 6-7 mm diameter), but with a relatively normal shape (**Figure 3**). However, PDH cannot be ruled out if the adrenal glands are not enlarged. If an adrenocortical tumor is present, one adrenal is often enlarged and irregularly shaped with a small, atrophied contralateral gland due to decreased circulating ACTH concentration.

Advanced imaging

Computed tomography (CT) and magnetic resonance imaging (MRI) are both sufficient for the identification of a pituitary macroadenoma (classically defined as a pituitary mass > 10 mm, but more recently as a mass that can be seen with the naked eye), so the modality selected should be based on cost and availability. Advanced imaging of the pituitary is recommended in dogs diagnosed with PDH. In those animals that are already neurologically affected, imaging can be used to confirm the presence of a macroadenoma, whilst for those that have no neurological signs, a scan may either detect the presence of a macroadenoma or help determine if one may develop in the future. Studies have shown that approximately 10-25% of PDH patients develop neurological signs within a year of diagnosis of HAC (8), and that signs are most likely to develop if the pituitary mass is > 10 mm, so radiotherapy is recommended to help shrink pituitary macroadenomas if they are found to be > 8 mm in size. However, in a patient without neurological signs, brain imaging is not recommended unless the owners anticipate requesting radiation therapy should a large tumor be identified (8).

Advanced abdominal imaging is much more sensitive for diagnosis of AT than radiography. If surgical removal of an adrenal gland is indicated, CT or MRI is extremely useful in localizing the tumor and assessing its invasiveness, permitting development of a surgical plan prior to celiotomy.

■ Diagnostic tests

Since the disease can be caused by either a pituitary or an adrenal tumor, both screening and differentiating tests are recommended. The screening test should be performed first, before conducting further investigations to differentiate between PDH and AT (since the prognosis and recommended treatment will vary) once the diagnosis of HAC is confirmed.

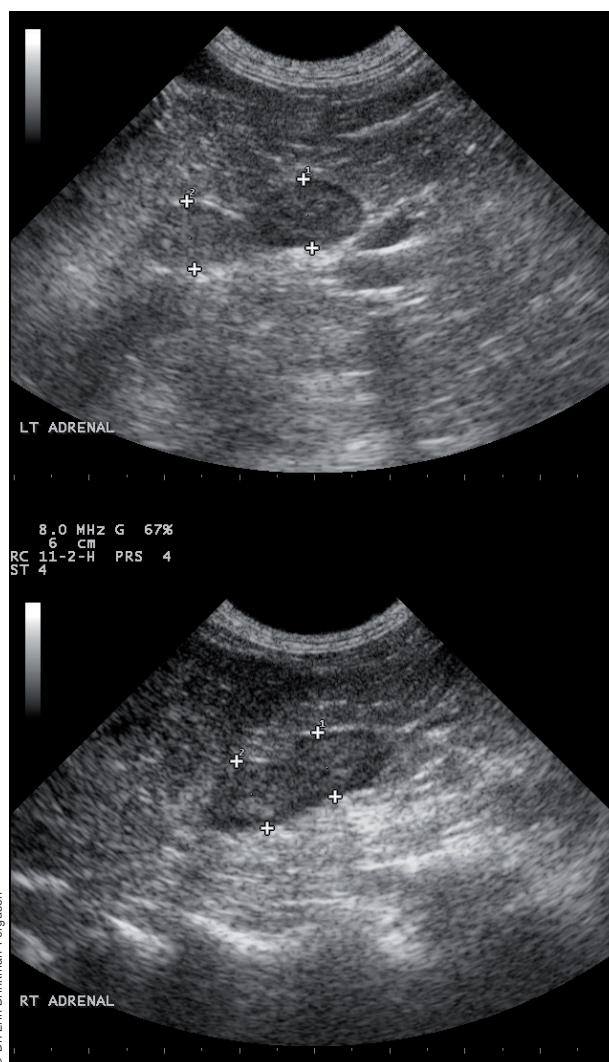


Figure 3. Abdominal ultrasound images from the same dog as in **Figure 2**. The adrenal glands in this 10-year-old female spayed Cocker Spaniel can be seen to be bilaterally enlarged (> 6-7 mm). A combination of clinical signs and diagnostic imaging findings led to increased suspicion of PDH in this dog.

Screening tests

Low-dose dexamethasone suppression test (LDDST)

The LDDST is used to demonstrate decreased sensitivity of the hypothalamic-pituitary-adrenal axis (HPAA) to negative glucocorticoid feedback (5). The normal HPAA is shown in **Figure 4**, whilst **Figure 5** displays the differences between the HPAA of dogs with adrenal tumors and pituitary tumors. In a healthy dog dexamethasone administration will cause suppression of pituitary release of ACTH, resulting in lower plasma cortisol concentration 8 hours later. However, in patients with PDH or AT, the cortisol concentrations will not be adequately suppressed, due to the autonomic production of ACTH and

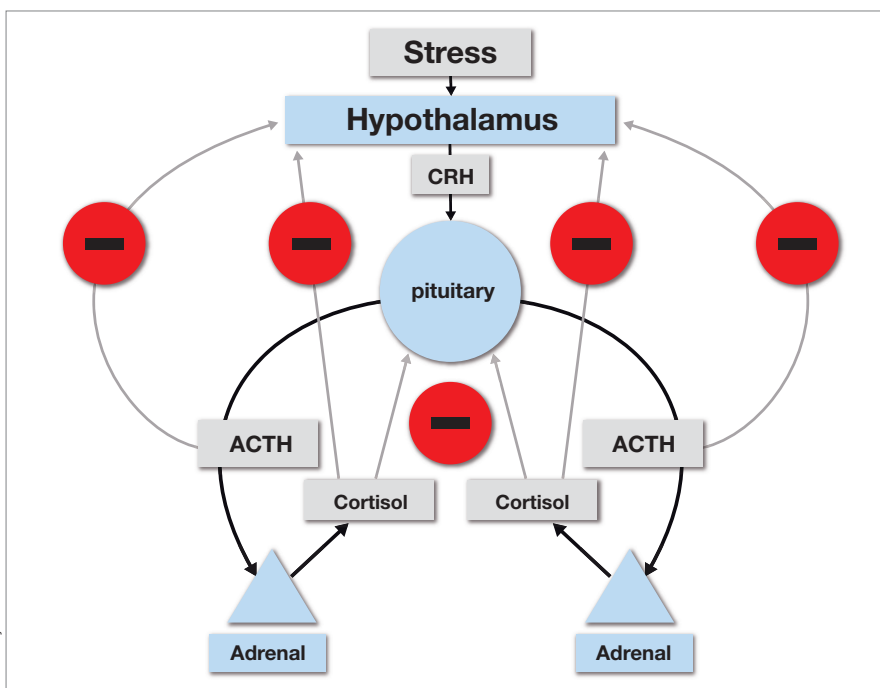


Figure 4. The hypothalamic-pituitary-adrenal axis (HPAA) in a normal animal ensures serum cortisol homeostasis. Stress causes the hypothalamus to secrete corticotropin-releasing hormone (CRH). CRH then stimulates ACTH production from the pituitary gland, and the adrenal glands respond to ACTH stimulation by producing cortisol. In addition to stimulating the adrenal glands, ACTH also feeds back to the hypothalamus to inhibit CRH production. Increased levels of serum cortisol have a negative feedback to the hypothalamus and pituitary to decrease production of CRH and ACTH respectively.

© Dr. Patty Laittan

cortisol, respectively. Dexamethasone is used because it does not interfere with the cortisol assay.

To perform the test a serum sample is drawn prior to administration of 0.01 mg/kg dexamethasone IV to determine the dog's baseline cortisol concentration; repeat blood samples are taken at 4 and 8 hours post-administration and submitted for analysis of cortisol concentration. A diagnosis of HAC is made by examining the level at the 8-hour interval. Due to the spectrum of disease and difference between patients, no specific cut-off point can diagnose every patient, but a cortisol concentration of greater than 1.4 µg/dL (39 nmol/L) at 8 hours post-dexamethasone is commonly seen as failure of suppression and indicative of HAC.

In addition to serving as a screening test, in certain circumstances the LDDST can differentiate between PDH and AT. Once HAC is confirmed by inadequate suppression at 8 hours, further examination of the cortisol concentrations at 4 and 8 hours may be performed. Three different parameters may be used to diagnose PDH using the LDDST: cortisol concentrations less than 50% of baseline at 4 hours, cortisol concentrations less than 50% of baseline at 8 hours, or cortisol concentrations less than 1.4 µg/dL (39 nmol/L) at 4 hours post-dexamethasone administration. Lack of suppression does not allow for differentiation, and further testing must be performed to make a definitive diagnosis.

Sensitivity of the LDDST is excellent and has been reported to be between 85-100% (5). However, the specificity of the test can be low (44-73%) due to stress or if there is concurrent illness, and because of this it should not be performed prior to addressing concurrent diseases. Even with the low specificity, the LDDST is considered the screening test of choice for canine HAC.

ACTH stimulation test

The ACTH stimulation test uses exogenous synthetic ACTH (cosyntropin or tetracosactrin) to test adrenal reserve (5). Due to the increased adrenocortical mass in dogs with HAC, they have the capacity to secrete excessive quantities of cortisol. Sensitivity of ACTH stimulation testing ranges from 57-95%, with higher sensitivity for PDH cases. The specificity is higher (59-93%) than seen with the LDDST. A baseline serum cortisol concentration is obtained prior to IV or IM administration of 5 µg/kg (up to 250 µg/dog) synthetic ACTH. One hour following administration, another serum cortisol concentration should be evaluated. As previously stated, dogs with HAC often produce excessive amounts of cortisol following the administration of ACTH due to the increased adrenocortical mass, so levels of 17-22 µg/dL (470-607 nmol/L) are considered a "gray area" for HAC diagnosis, while concentrations > 22 µg/dL (607 nmol/L) are considered diagnostic. Glucocorticoid, progestagen, and ketoconazole administration are all known to suppress cortisol concentrations, and can result in false

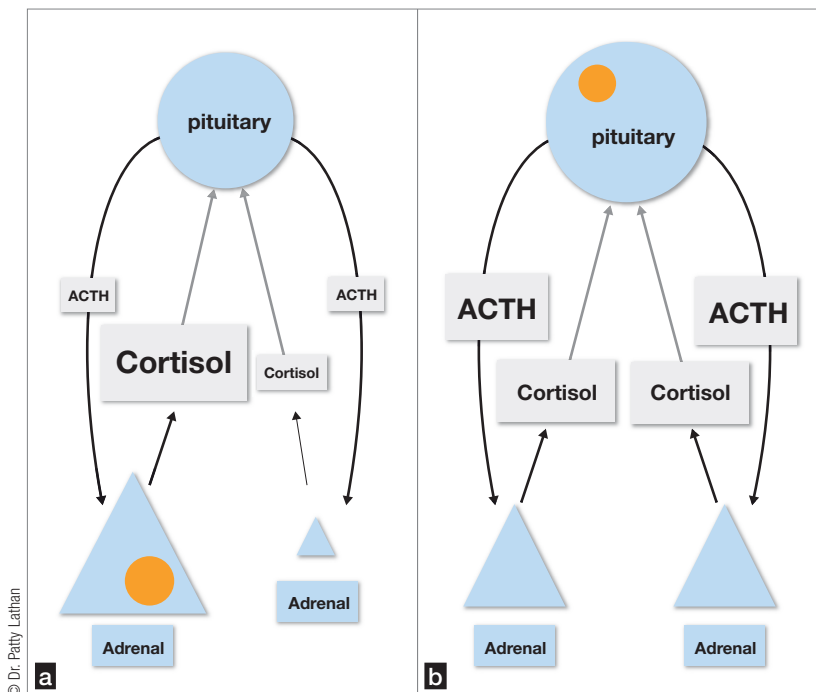


Figure 5. (a) The diagram represents a dog with AT. One adrenal gland is enlarged due to an AT and is producing large quantities of cortisol. This increase in blood cortisol results in decreased ACTH production by the pituitary, which causes the unaffected adrenal gland to atrophy. The affected adrenal acting autonomously produces large quantities of cortisol without being stimulated by ACTH. **(b)** The diagram represents a dog with PDH. The pituitary acts autonomously, producing large quantities of ACTH. Since both adrenal glands are functionally normal, the increased ACTH levels result in bilateral hypertrophy of the adrenal cortices and increased cortisol production. A normal pituitary would decrease ACTH production in this situation, but since it is acting autonomously, the pituitary continues to produce high quantities of ACTH even with high blood cortisol levels.

negative results. Due to the lower sensitivity of the ACTH stimulation test, a patient with a post-ACTH cortisol concentration less than 17 µg/dL, but with clinical signs consistent with HAC, should be tested using a LDDST prior to ruling out the disease.

Urine corticoid:creatinine ratio (UCCR)

Excretion of creatinine is relatively stable, so the UCCR adjusts for changing concentrations of blood and accurately reflects cortisol production in the absence of kidney disease (5). A free-catch urine sample is obtained and the ratio of cortisol vs. creatinine is determined; note that the sample should be obtained from the first urination of the day and for 2 to 3 consecutive days, averaging the results; a ratio of less than 15-20 is considered negative for HAC. The test is extremely sensitive (75-100%), but has a very low specificity (20-25%) when the sample is obtained in the veterinary hospital, due to increased cortisol secretion from the stress of transport and hospitalization. Owner collection of urine at home at least two days after a visit to a veterinarian is suggested. Due to low specificity, UCCR should primarily be used to rule out the likelihood of HAC, rather than to aid in its diagnosis.

Differentiating tests

High-dose dexamethasone suppression test (HDDST)

Dogs with PDH that do not exhibit cortisol suppression with the LDDST may exhibit suppression following the

HDDST (5). This test is performed using 0.1 mg/kg of dexamethasone IV, and otherwise follows the same protocol as the LDDST. Cortisol suppression is defined as serum cortisol levels below the reference range (usually 1.4 µg/dL or 39 nmol/L) at 4 or 8 hours, or serum concentrations less than 50% of baseline at 4 or 8 hours. Whereas dogs with ATs rarely suppress following either LDDST or HDDST, approximately 65% of dogs with PDH show signs of cortisol suppression following the LDDST, and 75% suppress following the HDDST. Given this minimal increase in differentiation *versus* the LDDST, the HDDST is only recommended in cases where endogenous canine ACTH (eACTH) and abdominal ultrasound are not available.

Endogenous ACTH concentration

eACTH is secreted in an episodic manner in normal dogs and in those animals with PDH. eACTH should be below the reference range in dogs with AT, due to the negative feedback of cortisol on the pituitary gland (5). However, dogs with PDH do not have a properly functioning pituitary; as the gland is resistant to negative feedback, this usually results in normal to high eACTH concentrations. However, due to episodic secretion, eACTH concentrations in dogs with PDH may be below the limit of detection of some assays.

The biggest problem with eACTH testing is that proper handling of the sample is of the utmost importance;

failure to follow protocol may result in inaccurate readings. Blood should be instantly transferred to a chilled, silicon-coated plastic tube containing EDTA upon collection. The sample should then be centrifuged within 15 minutes and the plasma immediately decanted into a plastic tube and frozen. The plasma must stay frozen until it is analyzed, so appropriate care and precautions should be considered for shipment. Alternatively, addition of aprotinin prevents ACTH degradation by plasma proteases, but may cause false decreases in readings when used with certain assays. Consultation with the laboratory for specific handling instructions is recommended prior to sample collection.

■ Treatment

There are several options available for treatment of HAC. However, even if the disease is present in a dog, treatment is not recommended if no clinical signs are present. The treatment method selected is dependent upon a variety of factors such as lesion location (PDH or AT), owner finances, and veterinarian preference.

Surgical therapy

Adrenalectomy is the treatment of choice for small, non-invasive adrenal tumors. Dogs with AT have a good long-term prognosis following successful surgery, but intra- and peri-operative mortality is approximately 20-30% (9,10). Computed tomography is recommended to help determine if there is extensive invasion of the surrounding vasculature and tissues (3). Following unilateral adrenalectomy, the patient must be supplemented with a tapering dose of glucocorticoids so that the atrophied contralateral adrenal gland can have time to respond to ACTH and return to normal function.

Trans-sphenoidal hypophysectomy is an effective surgical option available for PDH, but unfortunately there are few locations where this surgery is performed and it requires significant specialty training. A remission rate of 91% after one year and 80% after two years has been reported (11).

Medical therapy

Medical therapy is recommended for PDH, and also for adrenal tumors in which patient or client factors preclude adrenalectomy. The two most common medications used in veterinary medicine are trilostane and mitotane (o,p'-DDD), although availability and product license varies between countries. Studies have failed to show significant differences between the efficacies of these drugs in treating both AT and PDH, and selection of medication

is frequently dependent upon veterinarian experience and preference. In the authors' experience the use of trilostane has a shorter learning curve and is more straightforward than mitotane.

Trilostane, which in many countries is currently the only approved drug for treatment of both PDH and AT in dogs, is a competitive inhibitor of 3 β -hydroxysteroid dehydrogenase. This inhibition decreases the synthesis of cortisol, aldosterone, and androstenedione in the adrenal cortex, although the decrease in cortisol synthesis is most significant.

Trilostane should be given with food, as this significantly increases its gastrointestinal absorption. Its duration of activity is between 10-18 hours, which means that cortisol synthesis will increase as the drug is metabolized; however, clinical signs may or may not return before the next dose is administered. Published protocols for the use of trilostane vary. The authors' preference is to start with a single daily dosing at 2-3 mg/kg in the morning, changing to twice-daily dosing if a dog shows clinical signs (e.g., PU/PD) in the evening, although other authors recommend starting with twice-daily dosing. Between 10-14 days after commencing treatment serum biochemistry and an ACTH stimulation test should be performed to determine the efficacy of the current dose, and since the test must be started 3-5 hours following administration of the trilostane, morning administration is optimal.

Once treatment has commenced, **Table 3** shows the recommended course of action based on post-ACTH serum cortisol levels and clinical signs. Note that the effect of trilostane appears to increase throughout the first month, so the dose is not usually increased at the first recheck unless the post-stimulation cortisol is > 10 μ g/dL (275 nmol/L). Following this first recheck, the protocol may be closely followed, with dosage usually adjusted by 10-25% each time as appropriate. If the dog's post-stimulation cortisol is < 2 μ g/dL (55 nmol/L) and the dog does not show clinical signs of illness or Addisonian crisis, the trilostane may be stopped; if clinical signs reappear, the drug can be re-started at a lower dose.

If there are signs of hypocortisolemia (vomiting, diarrhea, decreased appetite, etc.), trilostane should be discontinued, and if the dog becomes severely unwell and/or has hyponatremia and/or hyperkalemia, it may need hospitalization for treatment as an Addisonian crisis. Alternatively, if the signs are mild, the dog may be discharged with oral dexamethasone (0.1-0.2 mg/kg q24H). Trilostane therapy

should not be re-instituted (at a 10-25% decreased dose) until clinical signs of HAC recur and an ACTH stimulation test demonstrates adequate adrenal reserve.

Following the first recheck, dogs should be rechecked at 14 days, then 30 days, and every 3 months thereafter. During these rechecks, serum chemistry should also be evaluated to assess the electrolytes. Since HAC is a clinical disease, it is necessary to perform ACTH stimulation tests at these intervals to practice optimal medicine, but if a client has limited financial resources and reports that the dog is doing well clinically, a single baseline cortisol may be performed to screen for hypoadrenocorticism, although this will usually result in inferior control of the disease. If the baseline cortisol levels are greater than 2 µg/dL (55 nmol/L) and there are no adverse clinical signs, trilostane therapy may be continued. However, if the baseline is less than this, an ACTH stimulation is required prior to increasing the trilostane dose.

Aside from clinical signs associated with cortisol deficiency, adverse effects are uncommon following trilostane administration. Lethargy and inappetence during the first few days of treatment are sometimes seen. Mild serum chemistry abnormalities (hyperkalemia and azotemia) have been reported. However, idiosyncratic adrenal necrosis occurs in some dogs, an unpredictable response that may occur at any time during treatment with no known cause. These patients will have cortisol deficiency with or without electrolyte abnormalities, and usually need emergency therapy as for a hypoadrenocortical crisis. Although rare, the owner must be warned about the risk so that they know what to look for. Notably, in the authors' experience, if a dog experiences a full Addisonian crisis with electrolyte abnormalities whilst on trilostane, the dog is likely to remain Addisonian for life.

Caution should be exercised when using trilostane in conjunction with angiotensin converting enzyme inhibitors due to the aldosterone-lowering effects of both medications. Mild hyperkalemia (< 7 mmol/L) is not uncommon, but more severe hyperkalemia requires medication adjustment.

Trilostane is commercially available in a variety of capsule concentrations, but very low doses (e.g., 5 mg per day) are occasionally necessary in very small dogs. Compounding trilostane is complicated and commercial pharmacies may use the unapproved base chemical rather than the licensed drug. At least one study documented significant variation in drug content and absorption characteristics when trilostane was prepared from an unapproved source (12), so it is essential to ask a pharmacy to utilize the approved product if compounding the drug.

Mitotane was previously the most commonly prescribed medication for treatment of HAC. The drug causes selective necrosis of the *zona fasciculata* and *zona reticularis* of the adrenal cortex, and usually spares the *zona glomerulosa* (except in cases of overly sensitive patients and inadequate monitoring), so electrolyte concentrations are usually normal in these dogs. Treatment consists of two phases: induction and maintenance. During the induction phase, high dosages of mitotane are given daily for 7-10 days, until any decrease in clinical signs or onset of adverse effects (such as anorexia, lethargy, vomiting, etc.) is observed, and the ACTH stimulation test shows adequate control. A weekly dosage is then given as maintenance, in an effort to prevent the cells destroyed during the induction phase from growing back. Potential side effects include signs of hypoadrenocorticism and liver toxicity.

Table 3. Trilostane therapy actions after ACTH stimulation test.

Serum cortisol concentration	Appropriate action
< 2 µg/dL (55 nmol/L), signs of hypocortisolemia	Treat as Addisonian; do not start trilostane again until an ACTH stimulation test confirms recovery
< 2 µg/dL (55 nmol/L), no clinical signs of illness	Stop therapy until clinical signs recur and begin with lower dose
2-6 µg/dL (55-165 nmol/L)	Continue current therapy
6-9 µg/dL (165-248 nmol/L)	If no clinical signs of HAC are present, continue with current therapy. Increase dose if patient is showing clinical signs
> 9 µg/dL (248 nmol/L)	Increase dose

Trilostane and mitotane are by far the most commonly used drugs for treatment of HAC, but l-deprenyl and ketoconazole have been used in the past. L-deprenyl is a dopamine agonist that works by providing irreversible inhibition of monoamine oxidase type B. The effects of the drug are on the *pars intermedia* of the pituitary gland, which is the location for around 30% of pituitary tumors causing PDH. The drug is extremely well-tolerated with few side effects, but only a small percentage of dogs show a response to treatment, therefore its use is not recommended for PDH. Ketoconazole is an imidazole that inhibits 11 β -hydroxylase and therefore has the ability to inhibit steroidogenesis. Following administration, some dogs experience lowered levels of circulating cortisol, but it is not as consistently effective as mitotane and trilostane,

and is not currently recommended for the treatment of HAC where mitotane and/or trilostane are available (13).

■ Conclusion

Canine hyperadrenocorticism is a common endocrinopathy, but there is currently no single test that allows definitive diagnosis. Treatment can be either medical or surgical, although again there is no one preferred option. Since most cases are due to pituitary tumors, medical treatment is the most common option, although regular monitoring of clinical signs and assessment using blood testing is imperative, as over-treatment can be potentially fatal. However, with proper monitoring and client compliance, dogs can achieve a good quality of life while being treated for hyperadrenocorticism.

References

1. Feldman EC, Nelson RW. Canine hyperadrenocorticism (Cushing's Syndrome). In: *Canine and Feline Endocrinology and Reproduction*. St. Louis, Missouri: Saunders, 2004;252-352.
2. Peterson ME. Diagnosis of hyperadrenocorticism in dogs. *Clin Tech Small Anim Pract* 2007;22(1):2-11.
3. Reusch CE, Feldman EC. Canine hyperadrenocorticism due to adrenocortical neoplasia: pretreatment evaluation of 41 dogs. *J Vet Int Med* 1991;5(1):3-10.
4. Ling GV, Stabenfeldt GH, Comer KM, *et al*. Canine hyperadrenocorticism: pretreatment clinical and laboratory evaluation of 117 cases. *J Am Vet Med Assoc* 1979;174(11):1211-1215.
5. Behrend EN, Kooistra HS, Nelson R, *et al*. Diagnosis of spontaneous canine hyperadrenocorticism: 2012 ACVIM consensus statement (small animal). *J Am Vet Med Assoc* 2013;27(6):1292-1304.
6. Forrester SD, Troy GC, Dalton MN, *et al*. Retrospective evaluation of urinary tract infection in 42 dogs with hyperadrenocorticism or diabetes mellitus or both. *J Vet Int Med* 1999;13(6):557-560.
7. Huntley K, Frazer J, Gibbs C, *et al*. The radiological features of canine Cushing's syndrome: a review of forty-eight cases. *J Small Anim Pract* 1982;23(7):369-380.
8. Bertoy EH, Feldman EC, Nelson RW, *et al*. One-year follow-up evaluation of magnetic resonance imaging of the brain in dogs with pituitary-dependent hyperadrenocorticism. *J Am Vet Med Assoc* 1996;208(8):1268-1273.
9. Schwartz P, Kovak JR, Koprowski A, *et al*. Evaluation of prognostic factors in the surgical treatment of adrenal gland tumors in dogs: 41 cases (1999-2005). *J Am Vet Med Assoc* 2008;232(1):77-84.
10. Barthez PY, Marks SL, Woo J, *et al*. Pheochromocytoma in dogs: 61 cases (1984-1995). *J Vet Int Med* 1997;11(5):272-278.
11. Meij B, Voorhout G, Rijnberk A. Progress in trans-sphenoidal hypophysectomy for treatment of pituitary-dependent hyperadrenocorticism in dogs and cats. *Mol Cell Endocrinol* 2002;197(1-2):89-96.
12. Cook AK, Nieuwoudt CD, Longhofer SL. Pharmaceutical evaluation of compounded trilostane products. *J Am Anim Hosp Assoc* 2012;48(4):228-233.
13. Peterson ME. Medical treatment of canine pituitary dependent hyperadrenocorticism (Cushing's disease). *Vet Clin North Am (Small Anim Pract)* 2001;31(5):11.

CUT-OUT AND KEEP GUIDE...

The three most common oral pathologies in adult cats

■ **Javier Collados, DVM**
Sinergia Veterinaria, Madrid, Spain

KEY POINTS

- The first step in detecting oral disease is to perform an initial oral examination in the awake animal. However, in order to thoroughly detect disease a complete oral examination must be performed under general anesthesia.
- A dental explorer, periodontal probe and intraoral radiography are essential tools for the diagnosis and staging of most dental problems.
- The most commonly diagnosed oral diseases in adult cats are chronic periodontitis, dental fractures, and tooth resorption.

1. Periodontal disease

Advanced periodontal disease is commonly diagnosed in cats (**Figure 1**). A major contributing factor to its development is the lack of adequate oral hygiene at home. The adoption of preventive pediatric health plans and adequate geriatric pre-surgical profiles, as well as the presence of specialists in oral surgery and anesthesia, are crucial aspects for ensuring appropriate periodontal treatment in such patients. Staging of periodontal disease is essential for the decision-making process, which can range from calculus removal and dental polishing to surgical extraction.

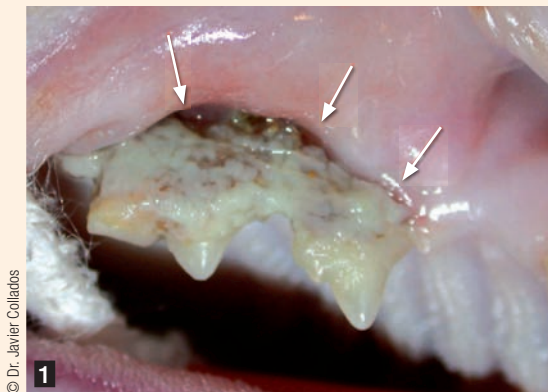
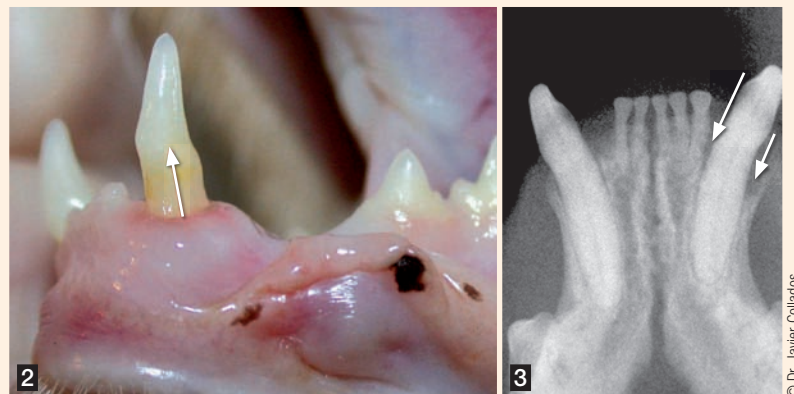


Figure 1. Stage 4 periodontal disease of teeth 107 and 108, with severe gingival recession and furcation stage 3 (furcation exposure), covered by calculus and plaque (1).

Tooth extrusion (**Figure 2**) is a sign of advanced periodontal disease in cats. Adequate periodontal probing and intraoral radiography (**Figure 3**) are very important when staging these teeth, as they are essential components in the decision making process for managing the condition.

Figure 2. Extrusion of tooth 304 due to advanced periodontal disease.

Figure 3. An occlusal intraoral radiograph of the mandibular canines and incisors shows signs consistent with bone loss due to periodontal disease.



2. Dental fractures

A tooth fracture is characterized by structural alteration (and in most cases loss) of dental tissue secondary to external trauma to the oral cavity. Note that fractures are frequently missed on the initial oral examination performed on a conscious animal. As in periodontal disease, classification is essential for decision making. This is particularly important in adult patients, since fractures involving exposure of the pulp chamber or cavity (complicated fractures, root fractures) that have not been adequately treated can lead to clear signs of pulp disease, such as dental abscesses, fistulas, etc. (Figure 4 and 5).

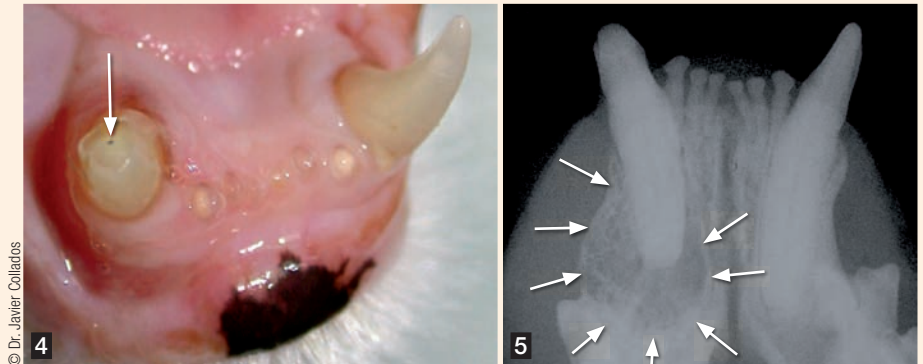


Figure 4. Complicated crown fracture of tooth 404 (note the severe abrasion of the lower incisors, as well as an enamel defect on tooth 304).

Figure 5. Intraoral radiograph of the mandibular canines and incisors shows signs consistent with severe periapical disease and regional osteolysis of tooth 404.

3. Tooth resorption

Tooth resorption (TR) is a primary dental disease characterized by progressive tissue destruction of one or more permanent teeth due to the action of odontoclastic cells. The condition frequently manifests with resorption of the crown and/or neck of the tooth, along with reactive gingival hyperplasia (Figure 6).

The underlying cause is complex and has not been clearly established. Although TR is not unique to adult animals, its progression in different stages and the appearance of obvious signs in the oral cavity are usually observed in adult animals. Nevertheless, radiography is essential for the diagnosis and treatment of TR in cats.

In some cases there may be no indication that the crown of the tooth is affected, despite radiological evidence of severe root resorption (Figure 7 and 8).

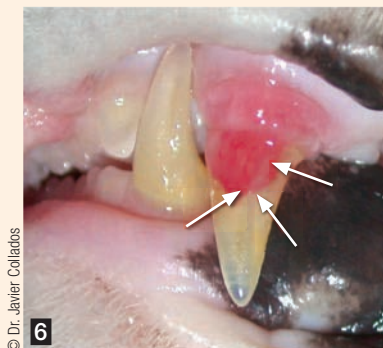
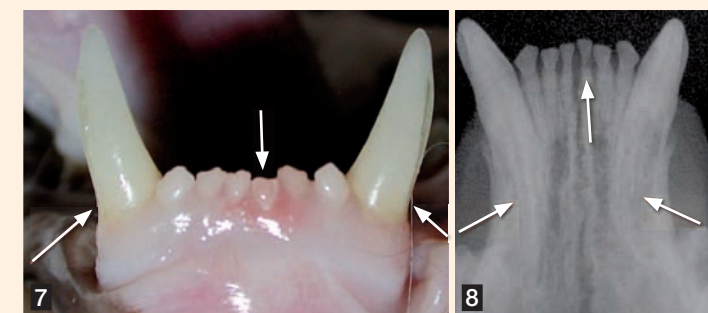


Figure 6. Signs of tooth resorption. There is evident dental resorption in the mesiovestibular gingival third of the crown of tooth 204. Reactive gingival hyperplasia covers the defect.

Figure 7. Clinical examination of teeth 304 and 404 reveals no signs of dental resorption at the level of the crown, and mild gingivitis around tooth 301.

Figure 8. Despite the lack of clinical signs, intraoral radiography shows signs of advanced tooth root resorption (class TR4c) of teeth 304 and 404, and signs of tooth resorption in tooth 301 (2).



Note teeth are identified using the American Veterinary Dental College (AVDC) classification system.

Acknowledgement: many thanks to Dr. Carlos Rice for reviewing the English version of the original Spanish article.

References

(1) www.avdc.org/nomenclature.html#periostages (downloaded May 15, 2014).

(2) www.avdc.org/nomenclature.html#TRstage (downloaded May 15, 2014).

EVECCS
2015
congress
June 12 - 14

14th EVECCS Congress

LYON - FRANCE

June 12-14, 2015

Small animal streams (refresher and advanced)
Veterinary nursing stream
Workshops

"Kidneys – The Filters of Life"

ROYAL CANIN

scil Veterinary Excellence

B. BRAUN
SHARING EXPERTISE

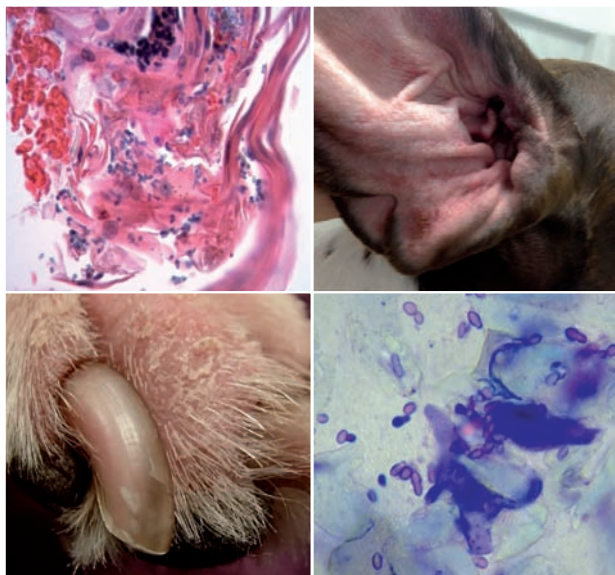


www.eveccs2015.org

VetAgro Sup

VETERINARY
focus

The worldwide journal for the companion animal veterinarian




IN OUR NEXT ISSUE...

In the next *Veterinary Focus*, we will look at different aspects of dermatology:

- **Anal pruritus in dogs**
Elisa Maina and Chiara Noli, Italy
- **Alternatives to corticosteroids for the itchy dog**
Neil McEwan, UK
- **Methicillin-resistant pyoderma in dogs**
Ana Oliveira, Portugal
- **Demodicosis in cats and dogs**
Stephen Waisglass, Canada
- **Pemphigus**
Amy Shumaker, USA
- **Malassezia dermatitis**
Kat Doerr, USA
- **Hints and tips on ear cleaning**
Alberto Martin Cordero, Mexico

ROYAL CANIN

We welcome offers to write ideas for papers and suggestions for topics and authors, which should be directed to the editor. *Veterinary Focus* is fully covered by copyright. No part of this publication may be reproduced, copied or transmitted in any form or by any means (including graphic, electronic or mechanical), without the written consent of the publishers © Royal Canin 2015. Proprietary names (trademarks) have not been specially identified. It cannot, however, be conducted from the omission of such information that they are non-proprietary names and as such can be used by everyone. The publishers cannot take any responsibility for information provided on dosages and methods of application. Details of this kind must be checked for correctness by the individual user in the appropriate literature. While every effort has been made by the translators to ensure the accuracy of their translations, no responsibility for the correctness of the original articles and thus no resulting claims against professional negligence can be accepted in this connection. Views expressed by authors or contributors do not necessarily reflect the views of the publishers, editors or editorial advisors.



SAVE THE DATE

25th 10th-12th September 2015
ECVIM-CA CONGRESS
LISBON | PORTUGAL

WWW.ECVIMCONGRESS.ORG