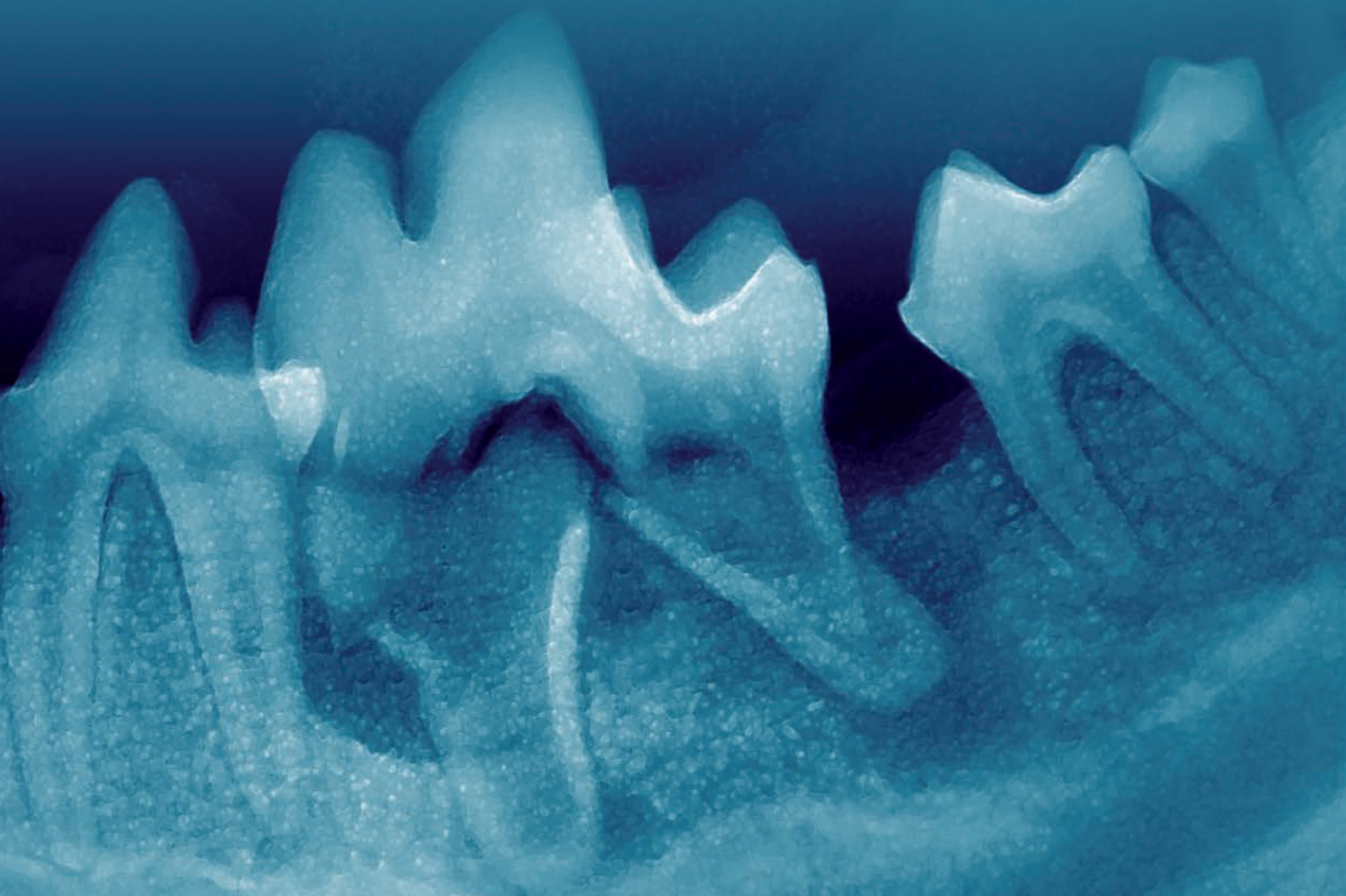


# VETERINARY focus

#22.3  
2012 - 10\$/10€

The worldwide journal for the companion animal veterinarian



## Oral disease in dogs and cats

Juvenile dentistry in dogs and cats • Therapeutic dilemmas in oral cancer • Fractures of the maxilla and mandible in cats • Epidemiology of periodontal disease in older cats • Systemic implications of periodontal disease • Fillings, crowns, and implants • Veterinary dental radiology – an overview • Dental disease in dogs and cats



From left to right: Yann Quéau, Pauline Devlin, Franziska Conrad, Elena Fernandez, Craig Datz, Philippe Marniquet, Joanna Gale, Laura Diana, Giulio Giannotti and Ewan McNeill.

# Scientific knowledge is made to be shared

The scientific realm is constantly being challenged by society at large, in that careful research and rational progress can be vulnerable to unfounded rumors and subjected to unsubstantiated beliefs. This, in turn, can lead to decisions being taken, in key domains such as the political and public worlds, based on pure speculation without any rigorous scientific support.

Royal Canin is wary of such shortcuts and takes pride in a commitment to a scientific approach and to continuously challenge habits or dogmas for the greater benefit of cats and dogs.

That is why, for instance, Royal Canin is against any anthropomorphic approach towards our pets, and does not give in to marketing trends or fashion until it is proven scientifically.

Waltham and Royal Canin's research on RSS (relative supersaturation) in reducing the risk of urinary calculi illustrates the efficacy of such scientific collaboration in finding a way to manage pets with both struvite and oxalate stones. In the field of hydrolysed diets – essential for the management of pets with food allergies – Royal Canin has recently developed Anallergenic ND, the first diet to be based on feather protein and which offers the lowest molecular weight ever achieved in a dog diet. This product required 10 years of research and now offers new options for the practitioner.

But scientific knowledge is made to be shared, which is why Royal Canin allocates so many resources to produce and distribute scientific content adapted to the expectations and needs of the veterinary surgeon. With its encyclopedias, Veterinary Focus, Focus Special Editions and various guides, Royal Canin is keen to play its part in the ongoing training of veterinarians and to promote specialization, especially in areas where nutrition is key.

The Veterinary Focus editorial committee's enthusiasm and skill has brought the journal to the forefront when it comes to imparting veterinary knowledge; as well as printing more than 80,000 copies of each issue, Veterinary Focus is now also available on iPad and Android tablets.

Created by the Waltham Centre for Pet Nutrition 23 years ago, Veterinary Focus has been edited by Royal Canin for the past 6 years and we hope it fulfils your needs; we trust you enjoy this latest issue on dentistry topics.



*The Editorial Committee of Veterinary Focus*

**02 Juvenile dentistry in dogs and cats**

*Jan Schreyer*

**10 Oral neoplasia – an overview**

*Lassara McCartan and David Argyle*

**17 How I approach... Fractures of the maxilla and mandible in cats**

*Markus Eickhoff*

**23 Epidemiology of periodontal disease in older cats**

*Elizabeth Lund*

**25 Systemic implications of periodontal disease**

*Alessandro De Simoi*

**31 Fillings, crowns, and implants**

*Nicolas Girard*

**38 Veterinary dental radiology – an overview**

*Michael Bailey*

**45 Cut-out and Keep... Dental disease in dogs and cats**

*Javier Collados*



“Should enlightenment grow in the practice of dentistry, we might attain to progress and engender new ideas...” So wrote the man regarded as the father of modern dentistry, Pierre Fauchard, in the year 1746, and he did much to advance the science, not least by producing the first textbook on the subject. As well as

describing a comprehensive system for the practice of dentistry, covering various operative and restorative techniques including denture construction, the volume also noted that dietary components could, for better or worse, affect dental health. However the history of oral medicine goes back much further than this; the tomb of an Egyptian scribe who died some 4500 years ago carries an inscription that refers to him as “one who dealt with teeth” – making him the earliest known individual to be identified as a specialist in this area – but even this is comparatively modern, as proof for the practice of dentistry goes back to perhaps 7000 years BC, with evidence that some civilizations from this era had a systematic approach, expert skills and dedicated tools for tooth-related disorders.

Nowadays dentistry is of course much more than just teeth – it is the branch of medicine that deals with the study, diagnosis, prevention and treatment of all diseases and disorders of the oral cavity and the entire maxillofacial area, and the many different specialties recognized within it - such as endodontics, orthodontics, and oral and maxillofacial surgery - are now developing in their own right within the veterinary sphere too. Ancient civilizations recognized that good knowledge of dentistry was necessary for complete overall health, and this is still true today; as such this issue of Veterinary Focus brings together some of the latest ideas and concepts in oral disease. Pierre Fauchard, we trust, would have approved.

**Ewan McNeill - Editor in chief**

**Editorial committee**

- Franziska Conrad, DVM, Scientific Communications, Royal Canin, Germany
- Craig Datz, DVM, Dipl. ACVN, Nutrition and Scientific Affairs Manager, Royal Canin, USA
- Pauline Devlin, BSc, PhD, Scientific Communications and External Affairs, Royal Canin, UK
- Laura Diana, DVM, Dipl. FCV, UBA, Scientific Communications, Royal Canin, Argentina
- María Elena Fernández, DVM, Scientific Communications, Royal Canin, Spain
- Joanna Gale, BVetMed, CertLAS, MRCVS, Science and Technical Communications Manager, WALTHAM Centre for Pet Nutrition, UK
- Giulio Giannotti, BSc, Product Manager, Royal Canin, Italy

- Hervé Marc, Global Corporate Affairs Manager, Royal Canin, France
  - Philippe Marniquet, DVM, Dipl. ESSEC, Veterinary Communication Manager, Royal Canin, France
  - Yann Quéau, DVM, Dipl. ACVN, Research Nutritionist, Royal Canin France
- Translation control**
- Imke Engelke, DVM (German)
  - Noemi Del Castillo, PhD (Spanish)
  - Giulio Giannotti, BSc (Italian)
  - Prof. Robert Moraillon, DVM (French)
  - Matthias Ma, DVM (Chinese)
  - Yoshiko Nakamura, DVM (Japanese)
  - Boris Shulyak, PhD (Russian)
- Deputy publisher:** Buena Media Plus  
**CEO:** Bernardo Gallitelli

**Address:** 85, avenue Pierre Grenier  
92100 Boulogne - France  
**Phone:** +33 (0) 1 72 44 62 00

**Editor**  
• Ewan McNeill, BVMS, Cert VR, MRCVS  
**Editorial secretaries**  
• Laurent Cathalan  
lcathalan@buena-media.fr  
• Olivia Amos

**Artwork**  
• Pierre Ménard  
• Youri Xeri (front cover)

**Printed in the European Union**  
ISSN 1354-0157  
**Circulation:** 80,000 copies  
**Legal deposit:** October 2012

Veterinary Focus is also published in French, German, Chinese, Italian, Polish, Spanish, Japanese & Russian.  
The licensing arrangements for therapeutic agents intended for use in small animal species vary greatly worldwide. In the absence of a specific license, consideration should be given to issuing an appropriate cautionary warning prior to administration of any such drug.



# Juvenile dentistry in dogs and cats



■ **Jan Schreyer, DVM, Dipl. EVDC**  
Tierärztliche Gemeinschaftspraxis, Chemnitz, Germany

Dr. Schreyer completed his veterinary studies at the University of Leipzig in 1993 and was awarded his doctorate in 1997. Since 1993 he has worked with his wife in his own small animal practice where the focus of his work is dental medicine. In 2004 he received his diploma from the EVDC. He was President of the European Veterinary Dental Society 2010-2012 and is currently Vice-President of the German Veterinary Dental Medicine Society.

## ■ Introduction

The incidence and severity of many oral problems (e.g. periodontal disease) increase with age; however young animals can also suffer from oral or dental disorders. The timely diagnosis and treatment of these diseases is essential and can often prevent the development of serious oral problems in later life; it is therefore important to inspect the mouth of young animals during every examination. Related to this, the question often arises as to whether an oral abnormality is hereditary

or not, and in many cases this cannot be easily determined; careful history-taking (e.g. trauma, infection, similar changes in related animals) may help, and if a potentially hereditary disease is present, advice on good breeding practice should be given. Whether hereditary or not, proper treatment should always be the primary focus and this article reviews some common oral and dental problems in young dogs and cats in the period before the second dentition has fully erupted.

## ■ Developmental disorders of teeth Number of teeth

Absence of all (anodontia) or almost all (oligodontia) teeth is rare; if present it is frequently related to a generalized disorder (e.g. ectodermal dysplasia). In contrast, one or a few missing teeth (hypodontia) is a more common finding (**Figure 1**). In particular, in brachycephalic, small and toy dog breeds the first premolars or last molars are often missing. Congenital aplasia of teeth is usually hereditary but trauma or infection during tooth development (< 4<sup>th</sup> month of life) can also lead to missing teeth. Hypodontia of permanent dentition is more common than with primary dentition. When a milk tooth is missing, in most (but not all) cases its adult successor is also missing. Radiography should always be used if teeth are absent in order to exclude the possibility of retained or impacted teeth. Hypodontia is mainly a cosmetic problem and requires no therapy, but depending on the breed standard some animals may be excluded from breeding (1,2). An excess of teeth (hyperdontia) can occur in both primary and adult dentition, and again this can be inherited or be related

## KEY POINTS

- Oral examination should be a part of every clinical examination; timely detection and treatment of juvenile oral disease can often prevent subsequent problems.
- A correct and definitive diagnosis of oral disease is often only possible with the help of intra-oral dental radiographs.
- If teeth are clinically absent, radiography is essential in order to exclude the possibility of retained and impacted teeth.
- Tooth fractures, even in milk teeth, always require treatment.
- Persistent milk teeth should always be extracted as soon as the corresponding adult tooth erupts.

to problems during tooth development. Most frequently the incisors or premolars are involved (**Figure 2**). Again radiographs must be taken in order to differentiate supernumerary teeth from incompletely separated teeth (see below) and retained milk teeth. Supernumerary teeth can cause problems with eruption, crowding or deviation of adjacent teeth. Moreover, teeth that are crowded together accumulate more plaque, predisposing to periodontal disease. When this happens, the tooth which is most abnormal in terms of size, shape or position should be extracted. However if the hyperdontia causes no clinical problem, no therapy is needed (1,2).

### Alteration in shape

#### • Gemination, fusion and concrescence

Gemination, or twinning, is the partial or complete splitting of a dental germ. The most frequent result is a tooth with a root and 2 crowns that are separate to a greater or lesser extent. Gemination is often seen in the incisors and can occur in both milk and adult teeth (**Figure 3a and b**).

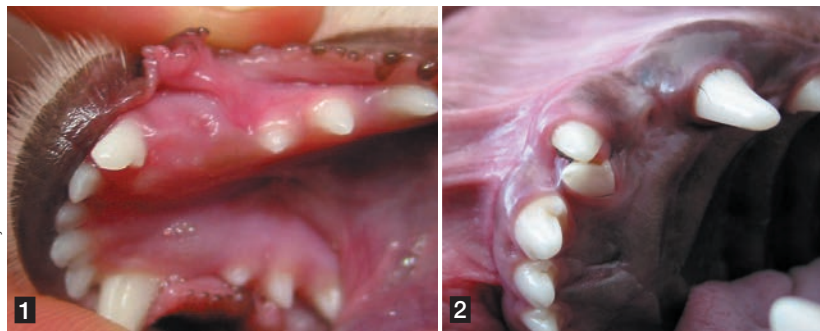
Fusion is where two dental germs fuse together, and can involve the entire length of the tooth or just the root area, depending on the timepoint at which it occurs during tooth development. The pulp of both teeth can also be fused (**Figure 4a and b**). Both etiologies are unknown, although trauma and/or a genetic component have been suggested (1).

Concrescence is the fusion of two adjacent teeth by the root cementum; crowding of the roots or trauma are considered to be possible causes.

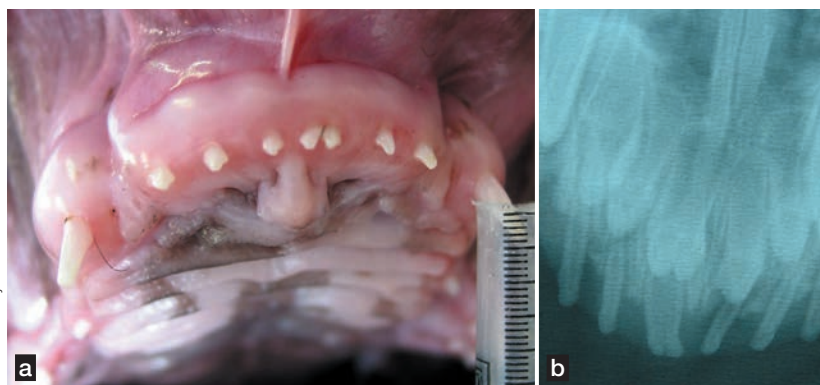
All three conditions typically require no treatment, unless changes lead to clinical problems such as periodontal or endodontic disease. Where treatment is advisable, pre-operative radiographs are essential to plan treatment, as roots are often abnormal in number or shape, and abnormal pulp conditions may be present (1).

#### • Dilaceration

This is defined as a kinking of the root or crown of a tooth and is usually caused by trauma during tooth development (**Figure 5a-c**). Dilacerations of the crown may be a purely esthetic problem but the surface is often rough and irregular, leading to increased plaque retention and subsequent periodontal disease. Dilacerations in the root area lead to problems with extraction or endodontic treatment. Pre-operative radiographs are again a prerequisite in these cases. Serious dilacerations can occasionally affect the eruption of affected teeth (1,3).



**Figure 1.** Missing right lower canine tooth in a Pomeranian.  
**Figure 2.** An extra incisor tooth in the left maxilla of a Labrador retriever.

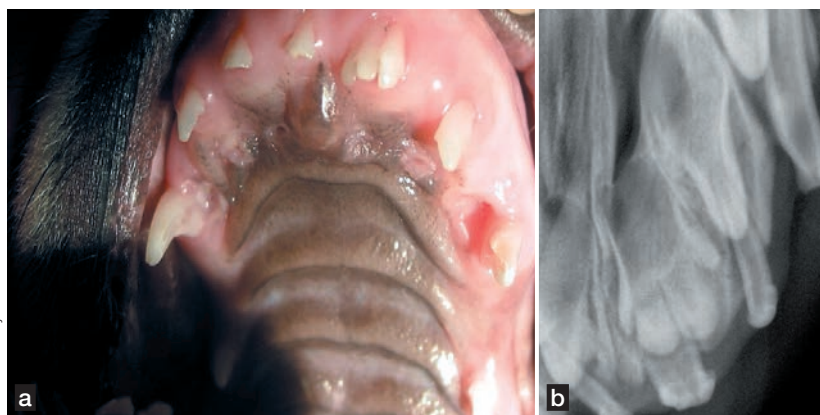


**Figure 3.** Gemination of the upper left first deciduous incisor tooth in a Boxer.

**a.** Two crowns are visible on examination (note the increased number of teeth in this quadrant).  
**b.** Radiography demonstrates that both crowns have the same root; the adult tooth also shows gemination of its crown.

**Figure 4.** Fusion of the first and second deciduous incisor teeth in the left maxilla of a cross-breed dog.

**a.** A broad, deformed crown can be seen in the area of the milk I1 on examination (note the reduced number of teeth).  
**b.** Radiography shows the deformed tooth crown on a fused root; the permanent tooth also shows the same changes. There is also a fracture of the left deciduous canine tooth.



• **Dens invaginatus**

*Dens invaginatus* (or *dens in dente*) is a rare condition of unknown etiology where the enamel and dentine invaginate into the pulp chamber during development; the invagination can be limited to the crown or may extend into the roots. Clinically this can lead to exposure of the pulp, predisposing to infection and subsequent pulp necrosis and periapical inflammation. Periodontal disease may also occur due to increased plaque retention (1,3).

• **Supernumerary roots**

Accessory tooth roots are most frequently found in the dog at upper P3 and the maxillary second and third premolar in the cat, but are occasionally found in other teeth (**Figure 6**). Radiological evaluation is important when planning extraction or endodontic treatment of the teeth concerned (1).

■ **Structural defects of hard dental tissues**

Various developmental problems, with many different causes, can lead to structural defects (dysplasias) of the hard tissues (enamel and dentine) of the teeth. Typically these dysplasias are acquired (e.g. via trauma, infection) and may affect either the enamel or dentine in isolation, or the entire tooth (odontodysplasia) may be involved.

There are three types of enamel dysplasia: enamel hypoplasia, enamel hypomaturation and enamel hypomineralization. Enamel hypoplasia is characterized by an insufficient quantity of enamel. The defects can be focal or multifocal, and the crowns of affected teeth can show both dysplastic enamel and areas with normal

enamel formation. In enamel hypomaturation and hypomineralization the enamel matrix development is disturbed, leading to the formation of soft enamel which is quickly eroded.

Congenital (genetically related) dysplasias are very rare and include *amelogenesis imperfecta* (enamel dysplasia) and *dentinogenesis imperfecta* (dentine dysplasia). Acquired enamel dysplasias are common in dogs but rather rare in cats. The defects are due to external influences during enamel formation (up to about the 4<sup>th</sup> month of life) and the extent of enamel damage depends on the intensity of the insult, the duration of its effect and the stage of enamel formation at the time of the damage. In principle, any systemic disease, such as distemper virus, as well as severe nutritional deficits at an early age, can lead to enamel dysplasia during tooth development in many or all teeth. Areas of normal enamel may be present as some enamel may have developed before the insult occurs (**Figure 7**).

Note that local effects such as trauma or inflammation (e.g. bite injuries, milk tooth fractures with pulp exposure and subsequent periapical inflammation, incorrect extraction of milk teeth) can also lead to enamel dysplasia, but these typically affect individual teeth (**Figure 8**).

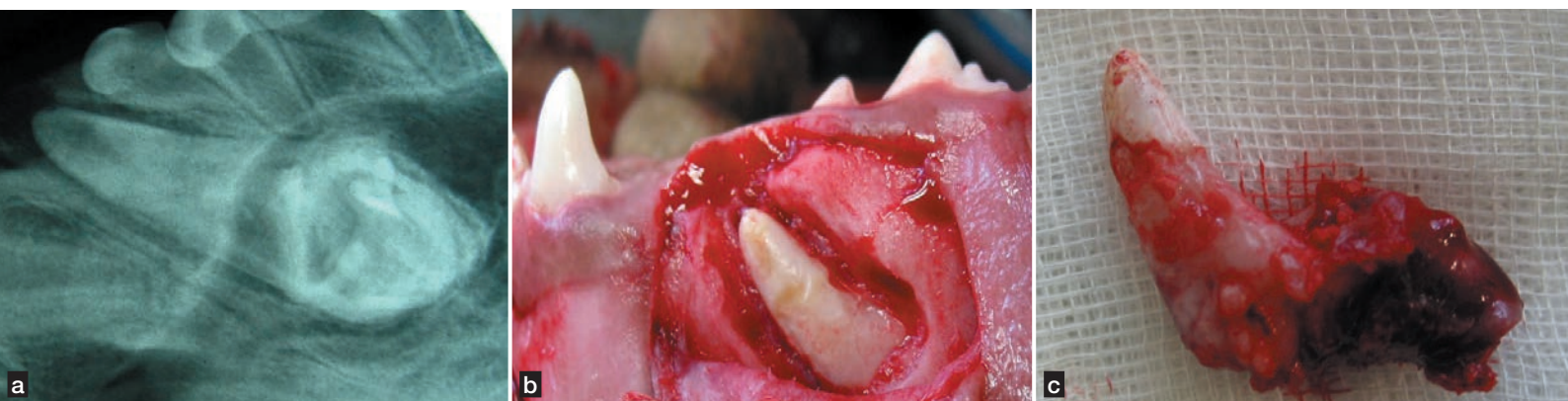Clinically, enamel dysplastic teeth show variable but extensive defects of the enamel. When the teeth erupt the defects are usually white in colour, although sometimes the enamel can be transparent. The defects quickly become yellow or brown due to deposition of food pigments, and the brittle enamel can easily flake off with chewing. Freshly exposed dentine is painful as the

**Figure 5.** Dilaceration of the right maxillary canine tooth in a Newfoundland dog.

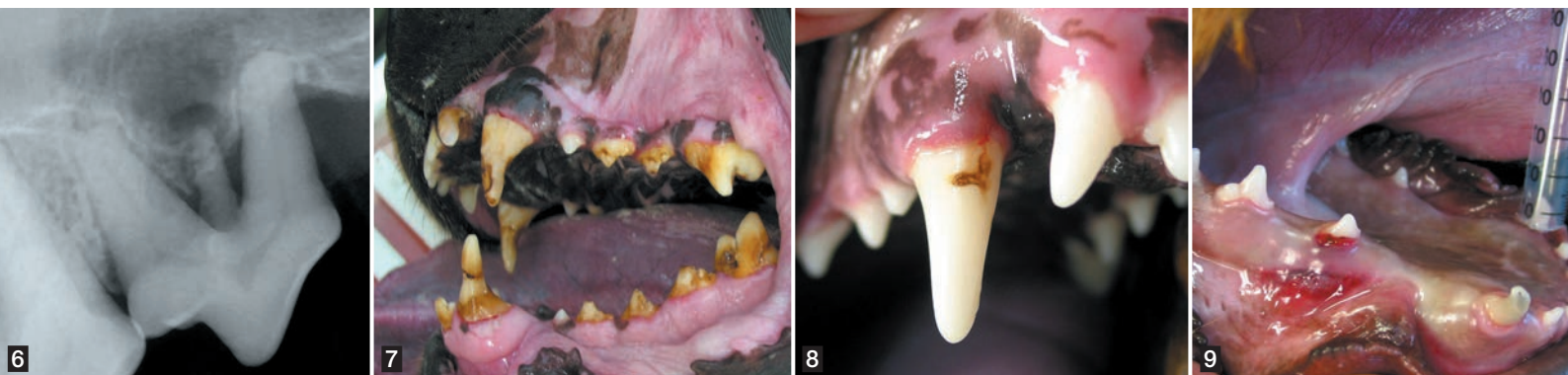**a.** Radiography shows an unmistakably abnormal root.

**b.** An intra-operative photograph during removal of the tooth; note the obvious enamel defect on the crown.

**c.** The extracted tooth showing major enamel defects of the crown and a completely deformed root.



© Dr. Jan Schreyer



© Dr. Jan Schreyer

**Figure 6.** Extra root on P3 in the right maxilla in a mongrel; note the considerable periodontal bone resorption and the lucency around the apex of the extra root which indicates endodontic disease.

**Figure 7.** Generalized enamel hypoplasia in a mongrel; the two first premolars are not affected, as the enamel on these teeth was formed before the insult responsible for the damaged enamel.

**Figure 8.** Localized enamel defect on the upper right canine tooth of a mongrel.

**Figure 9.** Fracture of the lower right canine tooth in an Airedale terrier puppy; the dental pulp is necrotic and infection has spread to the bone, forming a fistula in the area of P2.

dentine tubules become exposed, but the pain subsides over time as a result of reparative dentine laid down by the odontoblasts of the dental pulp. However, in severe cases the irritation can lead to pulpitis or pulp necrosis, and teeth showing enamel dysplasia should be evaluated by radiography in order to rule out complications such as periapical lesions.

Affected teeth can have a very rough surface, leading to increased accumulation of plaque and tartar and thus a higher risk of periodontal disease. Treatment aims to seal the exposed dentine tubules; localized defects should be filled with composite, but for very extensive enamel defects the tooth can be crowned. These measures also restore a smooth surface to the tooth, reducing the risk of periodontal disease. Despite this, such teeth need good oral home care (daily tooth brushing) and the use of dental diets can be helpful to reduce the accumulation of plaque and the formation of tartar. Teeth that already show periapical lesions require endodontic therapy or should be extracted (1,2,4,5).

## ■ Dental fractures

### Milk tooth fractures

The fracture of a milk tooth with pulp exposure, as with a permanent tooth, leads to pulpitis and subsequently

pulp necrosis. The inflammation and infection will spread via the apical delta to the surrounding bone and may damage the permanent tooth germ (**Figure 9**). Moreover, the physiological resorption of the milk tooth root is disrupted, so that the permanent tooth cannot erupt and remains impacted in the jaw, or erupts in an abnormal position. Because of this a milk tooth fracture always requires treatment; this usually means extracting the affected tooth (2-4).

### Fracture of immature permanent teeth

Whereas extraction is the treatment of choice for a broken milk tooth, the preferred treatment for a fractured permanent tooth is to preserve it, especially if the tooth is functionally important. Immature permanent teeth are characterized on radiography by thin dentine and an absence of root closure; conventional root canal treatment is not possible here. Uncomplicated fractures (where pulp is not exposed) should be treated by composite restoration; where a fracture is very near to the pulp, the site of the near-pulpal exposure is first sealed by indirect pulp capping (to preserve the pulp vitality) and then a composite restoration is applied to the entire fracture area (to seal any remaining exposed dentine tubules and mechanically protect the indirect pulp cap). If there is a complicated fracture (exposed pulp), the vitality of the pulp must be assessed. Where the pulp is vital, a partial pulpectomy performed under sterile conditions, followed by direct pulp capping and fracture site restoration, is necessary (**Table 1**). The prognosis for this sort of treatment depends primarily on the duration of pulp exposure, as the pulp starts to deteriorate after 48 hours (**Figure 10**).

In immature fractured teeth with a necrotic pulp, apexification (to obtain a hard tissue root closure) can be attempted (**Table 2**). The prognosis for this, however, is guarded. For all the treatment options described for fractured immature permanent teeth, periodic radiological follow-up is required for timely identification and

treatment of any periapical pathological changes that may occur (2-4,6-8).

## ■ Disorders during permanent tooth eruption

### Persistent deciduous teeth

Prior to exfoliation the roots of each milk tooth are resorbed, so that it falls out to make space for the permanent tooth. Persistent milk teeth are teeth that, at the time of eruption of their permanent successors, are still present. They are frequently found in dogs of small and toy breeds but are rare in larger breeds and cats; a hereditary component is suspected. Persistent milk teeth frequently lead to displacement of the permanent teeth as the physiological position of the latter is blocked by the former. The permanent teeth mostly erupt lingual or palatally to the milk teeth; only the maxillary canine always erupts mesial to its milk tooth predecessor (**Figure 11a and b**). The crowding that results from persistent milk teeth predisposes to periodontal disease. For these reasons such teeth should always be extracted.

Pre-operative radiography usually facilitates identification of the correct tooth and also shows to what extent the milk tooth root has been resorbed. The milk teeth must be extracted carefully as they have long, thin roots that break easily; damage to the permanent dentition must be avoided. In difficult cases, and to remove fractured root remnants, an open (surgical) extraction technique is recommended (1-4,9).

### Impacted and embedded teeth

Embedded and impacted teeth are teeth that have not erupted. With impacted teeth there is a physical barrier in the eruption path which prevents the tooth from erupting (e.g. other teeth, milk tooth remnants, very tough gums), whilst no such obstacle can be found with embedded teeth. Embedded and impacted teeth must be differentiated from missing teeth, and therefore radiography is mandatory whenever a tooth is clinically absent. Teeth that remain in the jaw can lead to formation of a dentigerous cyst, which can result in wide-spread bone absorption and damage to neighboring teeth (**Figure 12**).

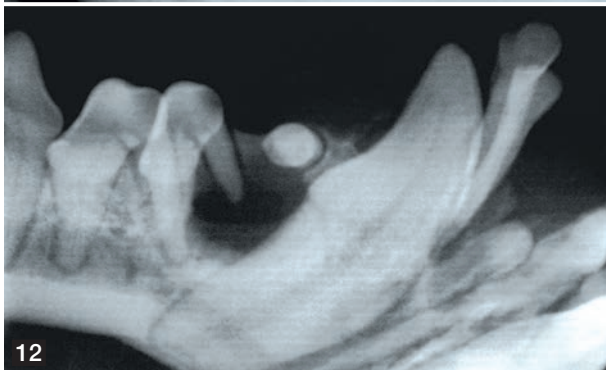
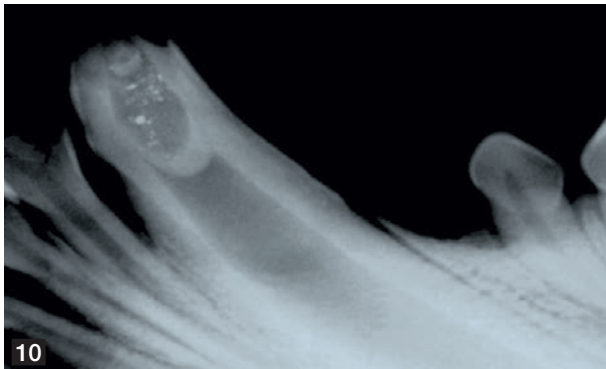
**Figure 10.** Radiograph of the lower left canine tooth 6 months after a fracture at the age of 4 months which was treated by a partial pulpotomy and direct pulp capping (note the dentine bridge under the filling).

**Figure 12.** Radiograph showing a retained P1 in the right mandible with development of a large dentigerous cyst in a pug (note I1 is also retained).

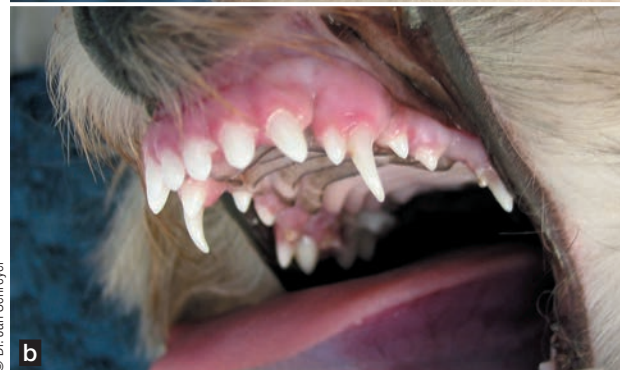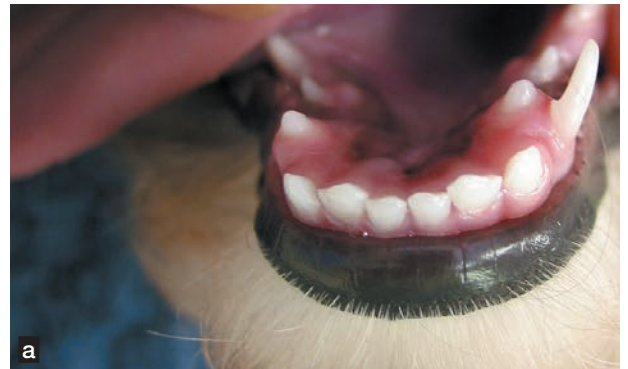**Figure 11.** Persistent milk canine teeth in a Yorkshire terrier.

**a.** In the mandible the adult canine tooth erupts lingual to the milk tooth.

**b.** The permanent maxillary canine erupts mesially to the milk tooth.



© Dr. Jan Schreyer



© Dr. Jan Schreyer



With timely diagnosis of retained or impacted teeth before completion of root development, the obstacle in the eruption path can be removed and the crown can be freed to allow the tooth to erupt. If removal of the obstacle is not possible, the affected tooth should either be extracted or undergo regular radiological monitoring. If a cyst is present, the tooth and the entire cyst lining must be removed in order for the cyst to heal. With very widespread cysts, the defect can be filled with a bone graft (1-3).

### ■ Dental and skeletal malocclusions

Malocclusions are more common in the dog than in the cat. Treatment is indicated wherever the animal's health is impaired, but is not required for purely cosmetic reasons. Abnormal tooth position with normal jaw length is known as dento-alveolar malocclusion; malocclusions due to a discrepancy in jaw length are known as baso-skeletal malocclusions. If there is no clear cause, or there are jaw abnormalities that cannot be explained by development or trauma, hereditary influences should be assumed. The malocclusion may already exist in the primary dentition or only occur in permanent dentition. Treatment options for malocclusions include extraction or crown reduction of the affected tooth, or orthodontic corrections.

Linguoversion, or lingual displacement of the lower canine teeth in dogs, is a common malocclusion that always requires treatment. Full details are outwith the scope of this article but some brief notes are appropriate. If the lower deciduous canine teeth are lingually displaced and impinge on the palate, this may lead to interlocking of the maxilla and mandible which can affect jaw growth. Frequently, dogs with this problem already have a retrognathic mandible (**Figure 13**) and here the lower canines should be extracted as early as possible; this immediately eliminates pain caused by the teeth impinging on the palate and allows the proper genetic development of the lower jaw.

The approach to the problem in the adult patient should, on the contrary, involve retention of the affected teeth; options include orthodontic correction of the malocclusion or shortening of the lower canine teeth. Orthodontic correction involves the use of expansion screws or inclined planes which move the teeth into a position that avoids trauma to the palate (**Figure 14a and b**). Shortening the lower canine teeth immediately eliminates the pain experienced when the teeth impinge on the maxilla; however, endodontic treatment is required with this option as in almost all cases the pulp is opened

**Table 1. Partial pulpectomy and direct pulp capping (2,5,6).**

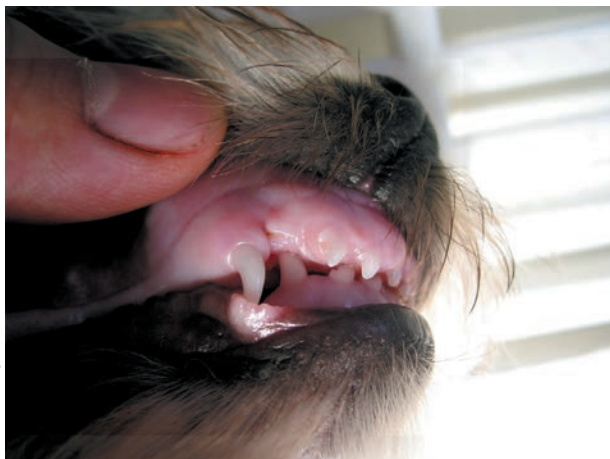Step 1	Establish the vitality of the pulp; it should be red and bleed on careful probing.
Step 2	Perform dental radiography to rule out signs of pulp necrosis (periapical lucency, pulp diameter enlarged when compared to the opposite side).
Step 3	Isolate the tooth to be treated via a coffer dam and disinfect with chlorhexidine gluconate.
Step 4	Remove the inflamed portion of the pulp and, using sterile irrigation, create a sufficiently deep cavity for the filling.
Step 5	Control bleeding using moist sterile paper tips or cotton pellets.
Step 6	Direct capping with calcium hydroxide or mineral trioxide aggregate.
Step 7	Apply an intermediate layer as base for the final restoration.
Step 8	Apply the final restoration.
Step 9	Post-operative radiography to evaluate.
Step 10	Repeat radiography after 6 months.

**Table 2. Apexification (2,4).**

Step 1	Radiography to establish root length.
Step 2	Isolate the tooth to be treated using a coffer dam and disinfect with chlorhexidine gluconate.
Step 3	Remove necrotic pulp, carefully clean the root canal under sterile irrigation (avoid over-instrumentation) and dry with sterile paper tips.
Step 4	Completely fill the root canal with calcium hydroxide to promote formation of hard tissue at the apex.
Step 5	Apply temporary restoration.
Step 6	Replace the calcium hydroxide filling at regular (4-8 weeks) intervals after radiographic assessment to check for formation of a hard tissue root closure.
Step 7	Conventional root canal treatment (RCT).
Step 8	Post-operative radiography to evaluate.
Step 9	Repeat radiographic evaluation after 6 months.

**ALTERNATIVE (7)**

Steps 1-3	As steps 1-3 above.
Step 4	Seal the open apex with mineral trioxide aggregate (MTA), place an intermediate layer of glass ionomer cement over the MTA and immediately finish the RCT and restoration.
Step 5	Radiography to evaluate.
Step 6	Repeat radiography evaluation after 6 months.



© Dr. Jan Schreyer

**Figure 13.** Linguoversion of the lower milk canine teeth in a 9-week-old Yorkshire terrier causing an interlock of the upper and lower jaw; there is a 3 mm shortening of the mandible.

when the tooth is shortened. In addition a partial pulpotomy and direct pulp capping should be carried out, as the roots of the teeth concerned are generally not yet mature (**Table 1**). For full details on orthodontic correction, the clinician is referred to the relevant literature (1-3,10,11).

### ■ Cleft palates

A cleft palate is formed by missing or incomplete fusion of the palatine shelves during fetal development, and presents clinically as a longitudinal defect of the primary (incisive bone) and/or secondary palate (maxillary and palatine bone and soft palate) (**Figure 15**). This

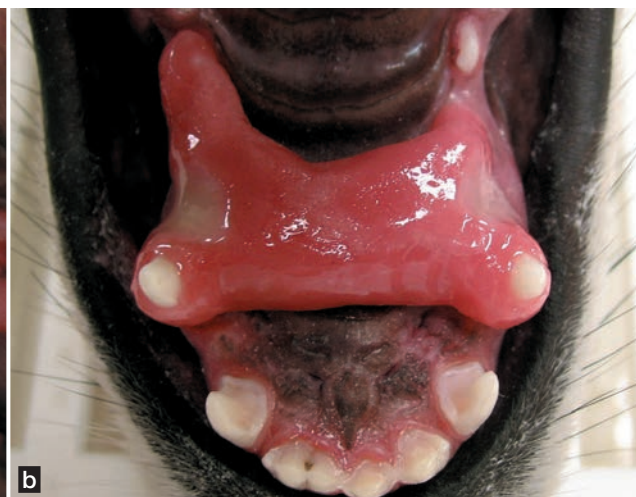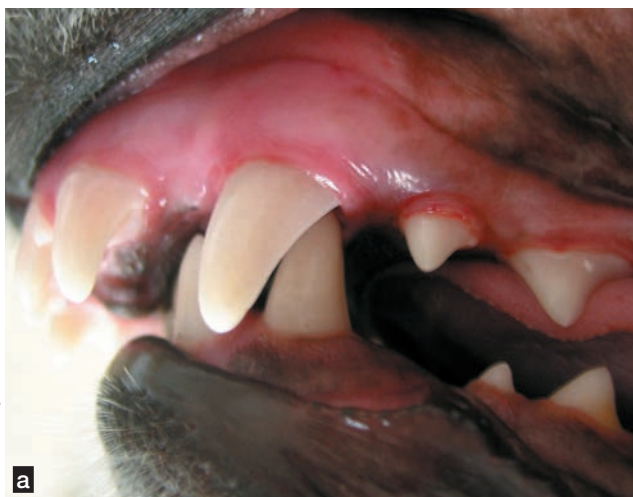results in the affected animal being unable to suckle; food is frequently inhaled into the respiratory tract, leading to pneumonia. Clinically an affected animal demonstrates coughing and sneezing, with milk noted at the nostrils when suckling. Such animals are often retarded in their physical development and are frequently euthanized. Should a surgical closure of the defect be planned, the animal must be fed several times a day by tube until attaining a reasonable size; surgery can usually be attempted at 2-4 months of age when the animal is big enough to allow the extensive mobilization of the oral tissues necessary to permit closure of the cleft palate. The surgical intervention must be carefully planned as the first attempt offers the best chance of success; despite this, in many cases follow-up operations are needed to completely close the defect.

The two methods most often employed to close the cleft palate are the bi-pedicle advancement technique and the overlapping flap technique. For the first, the medial edges of the palate in the area of the cleft palate are incised and the mucosa of the palate undermined. Lateral releasing incisions ensure the necessary mobility of the resulting mucoperiosteal flaps (**Figure 15**). Blood supply to the area from the major palatine artery must be preserved and the flaps must be mobilized as much as possible to allow tension-free closure of the defect; the lateral release incisions heal by secondary granulation. The disadvantage of this method is that sutures are positioned over the defect and have no bony support. For the overlapping flap technique, a flap from the palatine

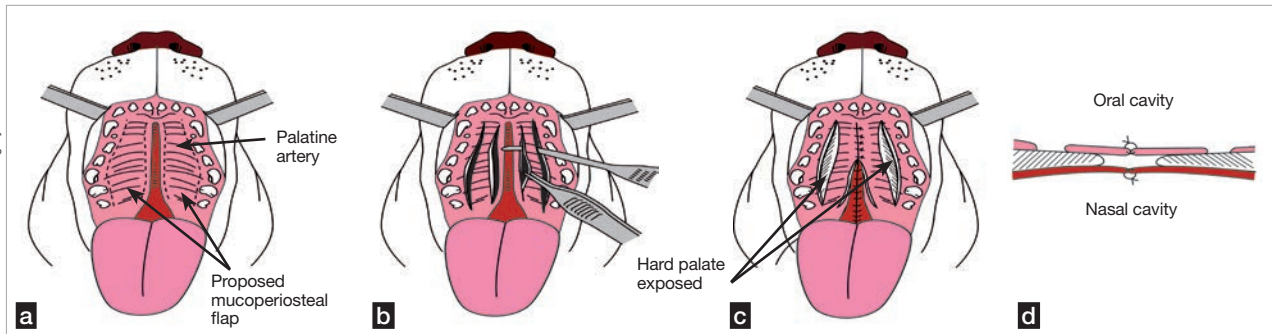
**Figure 14.** Linguoversion is a common malocclusion that always requires treatment.

**a.** Linguoversion of the lower canine teeth in a 7-month-old Rhodesian ridgeback, the lower teeth impinge on the maxilla behind the upper canines; there is an 11 mm shortening of the mandible.

**b.** A bite plate with inclined plane has been fitted to move the lower canines caudally and labially.



© Dr. Jan Schreyer



**Figure 15.** Bi-pedicle advancement flap technique for cleft palate repair.

- a.** Prepare the mucoperiosteal flaps by making parallel incisions along the length of the hard palate.
- b.** Undermine the tissue of the palate to permit mobility of the flaps.
- c.** Closure is by interrupted sutures.
- d.** Closure should be in two layers to ensure optimal apposition and healing.

mucosa is prepared on one side of the cleft palate, with the incision made parallel to the teeth and the base of the flap located at the cleft. The flap is folded over the defect, drawn to the opposite side of the cleft and sutured in position, so that the former oral epithelium forms the floor of the nose and the connective tissue side faces the oral cavity. Here too preservation of the blood supply from the major palatine artery is vital. The advantage of this method is that the sutures are supported by bone on one side of the defect; the disadvantage is that the technique is more difficult, requiring extensive preparation and leaving a large area of exposed bone to granulate (1-4, 12, 13).

## Conclusion

The clinician that dismisses dental disease or defects in young animals on the erroneous assumption that the development of adult dentition will remedy most problems does no service to the animal. Good knowledge of the various dental conditions that can exist in young animals, along with an awareness of the pathology and a conscientious approach to treatment, will ensure that a puppy or kitten that develops a problem will receive appropriate care and thus deliver long-term benefits for the animal concerned.

## References

1. Verhaert L. Developmental oral and dental conditions. In: Tutt C, Deepröse J, Crossley D. (eds) *BSAVA Manual of Canine and Feline Dentistry* 3<sup>rd</sup> ed. Gloucester: BSAVA 2007;77-95.
2. Eickhoff M. Das junge Tier. In: Eickhoff M. *Zahn-, Mund- und Kieferheilkunde bei Klein- und Heimtieren*. Stuttgart: Enke Verlag 2005;42-61.
3. Hale FA. Juvenile Veterinary Dentistry. In: Holmstrom SE (ed). *Vet Clin North Am Small Anim Pract. Dentistry* 2005;35(4):789-817.
4. Wiggs RB, Lobprise HB. Pedodontics. In: Wiggs RB, Lobprise HB (eds) *Veterinary Dentistry – Principals and Practice*. Philadelphia: Lippincott-Raven, 1997;167-185.
5. Taney KG, Smith MM. Composite restoration of enamel defects. *J Vet Dent* 2007;24(2):130-134
6. Niemiec BA. Fundamentals of endodontics. In: Holmstrom SE (ed). *Vet Clin North Am Small Anim Pract. Dentistry* 2005;35(4):837-868.
7. Niemiec BA, Mulligan TW. Vital pulp therapy. *J Vet Dent* 2001;18(3):154-156.
8. Juriga S, Manfra M, Maretta S, Niederberger V. Mineral Trioxide Aggregate (MTA) for apexification of non-vital immature permanent teeth. *J Vet Dent* 2007; 24(4):274-277.
9. Hobson P. Extraction of retained primary canine teeth in the dog. *J Vet Dent* 2005;22(2):132-137
10. Ulbricht RD, Manfra M, Maretta S. Orthodontic treatment using a direct acrylic inclined plane. *J Vet Dent* 2005;22(1):60-65.
11. Legendre LF. Building a telescopic inclined plane intraorally. *J Vet Dent* 2010; 27(1):62-65.
12. Taney K. Secondary cleft palate repair. *J Vet Dent* 2008;25(2):150-153.
13. Beckman B. Repair of secondary cleft palate in the dog. *J Vet Dent* 2011;28(1):58.

# Oral neoplasia - an overview



## ■ Lassara McCartan MVB, MRCVS

Royal (Dick) School of Veterinary Studies, University of Edinburgh, UK

Dr. McCartan graduated from University College Dublin in 2006 and spent more than two years in small animal and equine private practice before undertaking an oncology internship at the University of Wisconsin - Madison. She then remained in Madison to begin the first half of her oncology residency training, which she is currently completing at Edinburgh. She has a special interest in new anticancer therapeutics as well as maintaining excellent quality of life in veterinary oncology patients.



## ■ David Argyle BVMS, PhD, Dipl. ECVIM-CA (Oncology), MRCVS

Royal (Dick) School of Veterinary Studies, University of Edinburgh, UK

Dr. Argyle graduated from the University of Glasgow and after a period in practice returned to Glasgow to complete a PhD in Oncology/Immunology. He was senior lecturer in clinical oncology at Glasgow until 2002 when he became head of veterinary oncology at the University of Wisconsin. In 2005 he returned to Edinburgh University to the William Dick Chair of Veterinary Clinical Studies and became the dean for international and postgraduate research for both medicine and veterinary medicine in 2009. He is currently Head of School and Dean for the veterinary college. He is an RCVS/European specialist in Veterinary Oncology, and co-scientific editor of the Journal of Veterinary and Comparative Oncology. His major research interests are cancer and stem cell biology.

## KEY POINTS

- The most common oral tumors in dogs are malignant melanoma, squamous cell carcinoma, fibrosarcoma and acanthomatous ameloblastoma.
- The clinical stage, site and histological grade are prognostic for oral neoplasia, and therapeutic options rely on surgery and radiotherapy.
- Aspiration of the draining mandibular lymph node and imaging of the thoracic cavity are both essential for proper work-up of oral tumors.
- Squamous cell carcinoma is the most common oral tumor of cats; these are challenging to treat and carry a grave prognosis.

## ■ Introduction

Oral cancer is frequently encountered in both feline and canine patients; dogs are more often affected than cats, with oral tumors accounting for 6% of canine cancers (1) and 3% of feline cancers (2). The most common oral tumors in dogs are malignant melanoma, squamous cell carcinoma, fibrosarcoma and acanthomatous ameloblastoma. In cats squamous cell carcinoma is by far the most commonly diagnosed oral tumor, followed by oral fibrosarcoma. This article aims to give a general overview of oral and oropharyngeal malignancies in the dog and cat, the common clinical signs associated with these tumors, their appropriate diagnostic work-up, and current therapeutic options and prognosis.

## ■ Diagnostic approach and staging

The majority of cases will present with a noted oral mass; however oral lesions can often be missed by owners, especially if located caudally in the mouth.

Typical clinical signs include halitosis, increased salivation, dysphagia, loose teeth, weight loss, pain on opening the mouth and (less commonly) exophthalmos or facial asymmetry. No specific paraneoplastic conditions are associated with oral tumors.

The diagnostic work-up of any animal presenting with an oral mass should include a thorough history and physical examination, followed by determination of the diagnosis and staging. Diagnosis of oral tumors is typically via histopathology, requiring a wide incisional biopsy of the lesion under general anesthetic. Initially cytology samples can be undertaken, but oral lesions frequently have secondary inflammation, infection and necrosis, and cytology can often be non-diagnostic. Oral lesions typically have a vast blood supply and preparation for adequate hemostasis should be considered prior to biopsy. The use of electrocautery can distort the specimen and should only be used for hemostasis following blade incision or punch biopsy. To avoid seeding of tumor cells to normal skin, biopsy should always be taken from within the oral cavity and not via overlying dermis. Curative-intent resection for small lesions (especially those of the labial mucosa) may be considered at the time of initial work-up, but excisional biopsy of more extensive disease is not recommended (3).

The general anesthetic will - apart from facilitating biopsy - firstly allow a thorough oral examination. Close inspection of the pharynx, tonsils and hard palate should be undertaken, as well as the gross margins of the lesion itself. Secondly, oral radiographs or a computed tomography (CT) scan of the head should be undertaken to assess for microscopic disease extent. A CT scan allows for greater detail and can serve to analyze more precisely the location and extent of the mass as well as underlying bone lysis. Following advanced imaging, surgical resectability and discussion of best surgical approach, as well as likelihood of obtaining wide surgical margins, can be considered. Additionally contrast uptake in the draining lymph nodes can be assessed. CT also allows for radiotherapy treatment planning where surgical resection is not appropriate or is declined by the owner.

Further staging should routinely include aspiration of the draining mandibular lymph node if palpable (even if considered normal on palpation) and aspiration of the tonsils (should they appear grossly abnormal). Regional lymph nodes include the mandibular, parotid and medial retropharyngeal, however generally only the mandibular nodes are palpable. Thoracic cavity

imaging is essential to assess for distant metastasis via either three-view thoracic radiographs or extension of the CT through the thoracic cavity.

The World Health Organization (WHO) clinical staging system for oral tumors can be applied to oral neoplasias in dogs (**Table 1**) and should be considered in each case, as the clinical stage of disease can be prognostic for oral tumors, especially for malignant melanoma.

Oral malignancies are usually locally aggressive with a low to intermediate metastatic potential (apart from

**Table 1. WHO clinical staging system for oral tumors.**

<b>T: Primary tumor</b>			
<ul style="list-style-type: none"> <li>• <b>Tis</b> Pre-invasive (<i>in situ</i>)</li> <li>• <b>T1</b> Tumor &lt; 2 cm in diameter               <ul style="list-style-type: none"> <li>- T1a without bone invasion</li> <li>- T1b with bone invasion</li> </ul> </li> <li>• <b>T2</b> Tumor 2-4 cm in diameter               <ul style="list-style-type: none"> <li>- T2a without bone invasion</li> <li>- T2b with bone invasion</li> </ul> </li> <li>• <b>T3</b> Tumor &gt; 4 cm in diameter               <ul style="list-style-type: none"> <li>- T3a without bone invasion</li> <li>- T3b with bone invasion</li> </ul> </li> </ul>			
<b>N: Regional lymph node</b>			
<ul style="list-style-type: none"> <li>• <b>N0</b> No regional LN metastasis</li> <li>• <b>N1</b> Moveable ipsilateral nodes               <ul style="list-style-type: none"> <li>- N1a no evidence of lymph node metastasis</li> <li>- N1b evidence of lymph node metastasis</li> </ul> </li> <li>• <b>N2</b> Moveable contralateral or bilateral lymph nodes               <ul style="list-style-type: none"> <li>- N2a no evidence of lymph node metastasis</li> <li>- N2b evidence of lymph node metastasis</li> </ul> </li> <li>• <b>N3</b> Fixed lymph nodes</li> </ul>			
<b>M: Distant metastasis</b>			
<ul style="list-style-type: none"> <li>• <b>M0</b> No distant metastasis</li> <li>• <b>M1</b> Distant metastasis</li> </ul>			
<b>Stage I</b>	T1	N0, N1a, N2a	M0
<b>Stage II</b>	T2	N0, N1a, N2a	M0
<b>Stage III</b>	T3	N0, N1a, N2a	M0
<b>Stage IV</b>	Any T	N1b	M0
	Any T	N2b, N3	M0
	Any T	Any N	M1

malignant melanoma). They typically occur in animals > 8 years old and all commonly cause bone lysis. Breeds at increased risk of developing oral tumors include the cocker spaniel, German shepherd dog, German shorthaired pointer, Weimaraner, golden retriever, Gordon setter, miniature poodle, chow chow and the boxer (3).

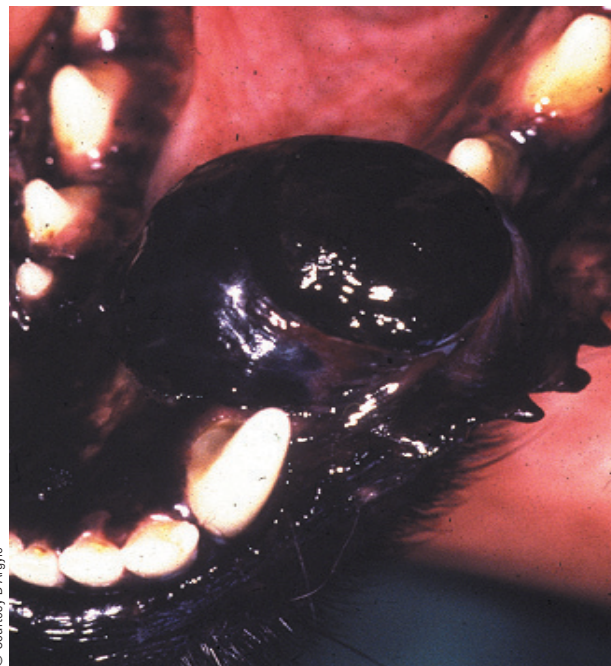Surgery and radiotherapy are the mainstays of therapy for any oral tumor. The extent of the surgical approach will be dictated by the location and size of the lesion. In most cases bone resection will be necessary and this expectation should be outlined to the owners to allow for increased local tumor control. The functional and cosmetic outcome for most patients following mandibulectomy (segmental or hemi), maxillectomy (segmental) or orbitectomy is generally very good and owners satisfaction deemed to be high. With most oral tumors, 2 cm margins are required for consideration of reasonable local control; this can be very challenging in the case of caudally located tumors or tumors which breach the midline of the palate.

Radiotherapy can be instigated as a primary therapy, as a curative intent protocol or a palliative therapy, or as an adjunct to incomplete or marginal surgical excision of an oral tumor. Here consideration of the biological activity of the tumor type and estimation of the responsiveness of the tumor either in the gross disease or microscopic disease setting should be considered in order to determine an appropriate treatment protocol for each patient.

## ■ Canine oral tumors

### Malignant melanoma

Malignant melanoma is the most common canine oral tumor, accounting for 30-40% of all oral malignancies. Typically occurring in dogs > 10 years old, smaller breeds (especially the cocker spaniel) are over-represented, as well as dogs with darkly pigmented mucosa (4). The mass can occur at any oral location, but in order of decreasing frequency they are found on the gingiva, lips, tongue and hard palate (5). Approximately 2/3 are said to be pigmented (**Figure 1**) and 1/3 amelanotic; they are commonly ulcerated and frequently have bone involvement. The histopathology of an oral melanoma can be confusing and they can often be misdiagnosed as poorly differentiated sarcomas or carcinomas. Melan-A is an immunohistochemical marker used as a melanoma-specific marker (4), however its sensitivity drops with increasing degrees of differentiation (3).



**Figure 1.** A pigmented melanoma on the mandible of a dog.

These tumors are locally aggressive and have a high metastatic potential. The typical sites of metastasis include the regional lymph nodes (up to 74%) and the lungs (up to 67%). The WHO staging system for canine malignant melanoma is prognostic, with tumor size being of most relevance. The metastatic rate is size, site and stage dependent. Other poor prognostic factors include incomplete surgical margins, location (caudal mandible and rostral maxilla), mitotic index > 3, bone lysis (5), and (more recently documented) high ki-67 value protein levels on biopsy assay (6).

Surgery and radiotherapy both allow for generally excellent local tumor control. The concern in treating this neoplasm lies in the limitations of currently available viable systemic therapeutics and the fact that these patients die from distant metastatic disease.

Standard of care in a case where distant metastatic disease has not been documented is considered to be surgical resection of the mass with wide margins. Surgery is considered fast and financially acceptable in the majority of cases and can often carry a curative intent. Radiotherapy can be utilized in the case of incomplete/narrow surgical excision or instead of resection of the gross tumor where surgery is not deemed appropriate. Here hypo-fractionated protocols of 6-9 Gy weekly to a dose of 24-36 Gy have been utilized with excellent local control response rates.

Malignant melanoma is considered to be relatively resistant to chemotherapy. Platinum agents are used most frequently for both systemic control and/or radiosensitization. Both carboplatin and melphalan have been outlined as potential agents, but documented overall response rates are < 30% (3).

The prognosis for dogs with malignant melanoma is poor. A stage I melanoma treated with standard therapies including surgery, radiotherapy and chemotherapy has a median survival time of 12-14 months, with most dogs dying from metastatic disease rather than local recurrence (5). Because of this, ongoing investigation into systemic therapies to target secondary metastatic disease is required; immunotherapy is one such therapeutic potential, and in some countries a DNA vaccine is licensed for dogs with oral melanoma. The vaccine encodes for a human version of a protein called tyrosinase which is present on both human and canine melanoma cancer cells. Vaccination stimulates the dog to produce tyrosinase; the dog's immune system subsequently generates a response towards the protein, which then attacks the tyrosinase present on the melanoma cells (7). The vaccine is given intradermally every 2 weeks for a course of 4 treatments and then boosted every 6 months; although expensive, it has few side effects.

The over-expression of COX-2 in cutaneous, oral and ocular melanomas has led to the principle that NSAIDs may have a role to play in treating this malignancy (8). Ongoing research is looking at the expression of KIT, a transmembrane tyrosine kinase receptor present in malignant melanoma, and its utilization as a target for

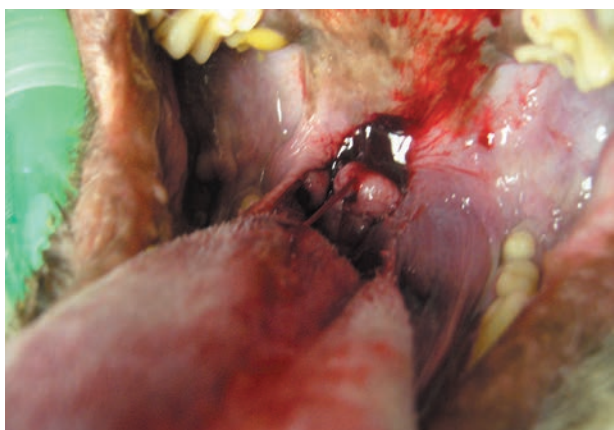novel anti-cancer therapeutics. The potential role of tyrosine kinase inhibitors for treatment of this tumor remains in the early stages.

### Squamous cell carcinoma

Squamous cell carcinoma (SCC) is the second most common oral tumor in dogs, accounting for 17-25% of cases (3). Two separate disease entities should be considered; tonsillar SCC and non-tonsillar SCC. The overall prognosis for non-tonsillar SCC is good, especially for small and rostrally located lesions. These tumors are typically locally aggressive, frequently causing bone lysis, but are considered to have a low metastatic potential. Regional lymph node metastatic disease is reported to be up to 10% and distant metastatic disease to the lungs reported in 3-36% of cases (3). Tonsillar SCC (**Figure 2**) has a much higher metastatic potential; up to 77% of cases will have regional metastatic development and 42-63% distant metastasis (9). Here local tumor recurrence following surgical or radiation therapy is common.

For non-tonsillar SCC, as with any oral tumor, location and size is significant, and here the challenge is local tumor control. Despite a low metastatic potential full staging should be undertaken in these patients prior to definitive therapy. Local tumor can be controlled with surgery or radiotherapy, and in many cases it is considered ideal to use a combination of both. Outcome is better for mandibular lesions rather than lesions of the maxilla. Following mandibulectomy a recurrence rate of 8% was reported when a minimum margin of 1 cm was achieved, with a 91% one-year survival rate and median survival time between 19-26 months. Following maxillectomy local recurrence rates were 29%, with a 57% one-year survival rate and median survival time of 10-19 months (10). A 2 cm surgical margin is recommended for SCC removal. If surgery is not feasible (due to size or location), or where surgical margins are incomplete or narrow, definitive radiation therapy is appropriate. Various studies have looked at survival time following radiation treatment; in one study of 19 dogs treated with full course radiotherapy the overall progression-free survival time was 36 months, and here local tumor recurrence, rather than regional metastatic development, was the typical reason for treatment failure, and another report recorded a median disease-free interval and survival of 12 and 14 months respectively for dogs treated with full course radiotherapy (10). Local tumor control is improved with smaller tumors, those located rostrally, on the mandible and in patients that are younger in age.

**Figure 2.** A left-sided tonsillar squamous cell carcinoma (SCC) in a dog. Note the large growth laterally and the attached pedunculated mass within the caudal pharynx.



© Courtesy L. McCartan

Chemotherapy is not typically indicated for oral SCC, but may be utilized in dogs with identified metastatic disease, those with a heavy tumor burden, or where owners decline surgery and/or radiotherapy. Here consideration of a platinum agent is appropriate. NSAIDs are a reasonable adjunctive in standard of care options, along with chemotherapy or as a stand-alone therapy, where more aggressive therapeutics have been declined.

### Fibrosarcoma

Oral fibrosarcoma (FSA) is the third most common oral tumor in dogs. This tumor will in many cases have a very benign histopathology and can sometimes be misdiagnosed as non-neoplastic. However it will commonly show an extremely aggressive biological behavior, growing rapidly and causing severe bone destruction and facial deformity; this subset is often referred to as biologically high grade, histologically low grade FSA. Fibrosarcomas have a predilection for the hard palate and maxilla, and while typically being very locally aggressive, metastasize to the regional lymph nodes and lungs in < 30% of cases (3). Once again the size and location of the tumor are prognostic. Multimodality therapy utilizing both surgery and radiation therapy is considered standard of care for these patients. Historically, when surgery is utilized alone the survival rates are typically reported as not exceeding one year, however a more recent publication has outlined more favorable local control and survival times (overall survival 24.8 months) than previous reports (11). This may be due to advancing surgical techniques as well as the increased use of CT imaging prior to surgery. When planning resection of an oral FSA the aim should be to obtain the widest possible margins, but surgical

excision should still be considered if 2 cm margins are not expected (11). Radiation therapy to a large tumor volume is considered less ideal and this tumor is regarded as being relatively radiation-resistant. Outcomes are improved where surgery and radiotherapy are used in combination.

With a generally recognized low metastatic rate the role of chemotherapy here has not been fully identified and the focus should remain on local disease control.

### Acanthomatous ameloblastoma

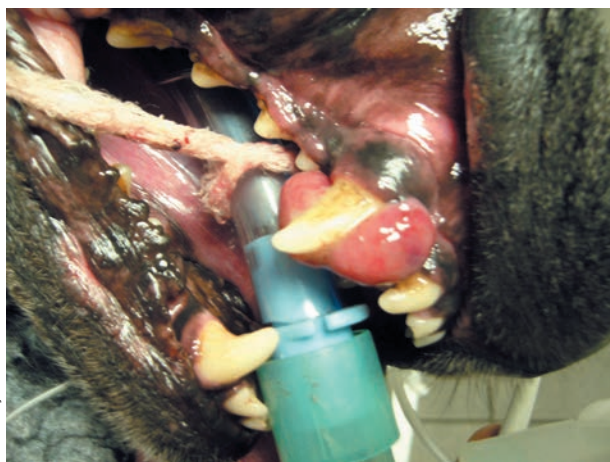Canine acanthomatous ameloblastoma (CAA) is characterized as a benign odontogenic tumor or epulis. The term epulis is a descriptive term applied to expansile gingival lesions. Odontogenic tumors are generally considered rare and there has been much confusion regarding their nomenclature and origin as well as other reactive lesions of the gingiva. The acanthomatous epulis has microscopic features in common with human ameloblastoma. However its clinically invasive nature, commonly with destruction of underlying bone (unlike other odontogenic tumors) is similar to the human intra-osseous ameloblastoma. The tumor is now termed CAA because it is considered its own entity with no precise human equivalent (12).

CAA most commonly affects the rostral mandible, and golden retrievers, akitas, cocker spaniels and Shetland sheepdogs are over-represented breeds (3,12). The typical appearance is cauliflower-like, red and ulcerated (**Figure 3**). While considered locally aggressive, the tumors have not been known to metastasize and hence local control is the mainstay of therapy. Surgery to include mandibulectomy or maxillectomy is usually employed and local recurrence rates with wide excision are low. A CT scan to determine the exact extent of underlying bone involvement is advantageous (**Figure 4**). Definitive radiation therapy can also be employed where wide surgical margins are deemed unlikely or in order to preserve function or cosmesis. Radiation has been found to have excellent response rates with local recurrence rates (up to 18%) reported; recurrence is more likely in larger tumors (13). Intra-lesional bleomycin is another option that has been described for CAA treatment (14).

The prognosis with this tumor type is excellent and, for most patients, eventual death is unrelated to the odontogenic tumor.

A recent publication has described a less aggressive surgical rim excision for the treatment of this tumor

**Figure 3.** An acanthomatous ameloblastoma on the maxilla of a German shepherd crossbreed.



© Courtesy M. Rennick

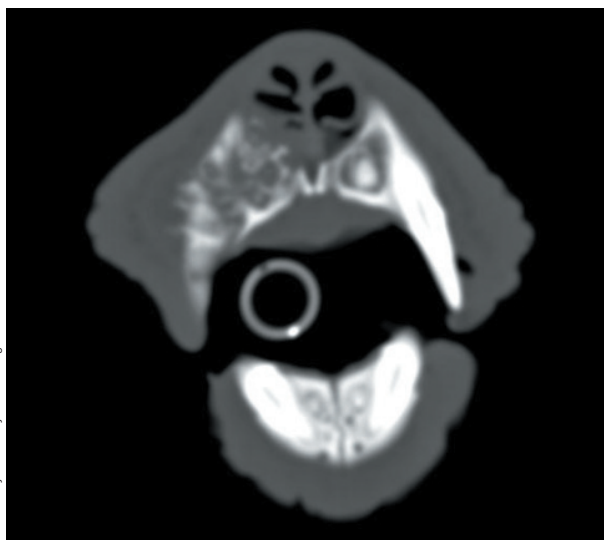


type. Here the ventral cortical bone of the mandible or dorsal portion of the maxilla is left intact while the tumor, surrounding teeth and periodontal structures are removed. Obvious advantages include decreased mandibular drift and improved dental occlusion. In 9 cases that had follow-up from 3 months to 5 years no recurrence was recorded and high client satisfaction was documented (15). The lesions selected for such surgical intervention were small (< 2 cm) and had bone involvement of < 3 mm, which may indicate that wide traditional excision should continue to be appropriate for larger lesions.

### ■ Feline oral tumors Squamous cell carcinoma

This is the most common oral tumor of cats, accounting for approximately 65% of oral tumors seen. It can arise from any oral mucosal surface, including the sublingual region, the tonsils and the pharynx. The tumor is very locally aggressive and commonly causes underlying bone lysis. The regional lymph node and distant metastatic rate is low and estimated at 10%. Epidemiological studies suggest that various risk factors may predispose to the development of SCC but no prospective, controlled studies have yet been undertaken to further advance this possibility (16). The average age of cats affected is 10-12 years; any oral lesion in an older cat should be biopsied promptly as early diagnosis may improve the prognosis. Many cats will present because the owners have noted an oral mass and the most common clinical signs include ptyalism, halitosis and, in some cases, dysphagia. Staging should be as for canine oral tumor and include cytology of the regional mandibular lymph node and three-view thoracic radiographs. While oral radiographs can be helpful - and may be reasonable - to determine underlying bone lysis, CT imaging allows for greater accuracy in assessing bone involvement and should be undertaken in all cases where aggressive therapy is being considered.

SCC remains very challenging to treat and carries a grave prognosis. While surgery and radiation therapy can be undertaken, the median survival time is short, with survival times > 3 months uncommon and a one-year survival rate < 10%. However the prognosis is potentially improved for those patients with small and rostrally located lesions where wide surgical excision can be undertaken and/or adjuvant radiotherapy employed. Resection of the mandible plus curative intent radiotherapy gives a median survival of 14 months. In the majority of cases surgery alone does not offer a significantly extended survival time as the disease is



**Figure 4.** A CT scan reveals underlying bone lysis at the level of the upper right canine tooth due to a CAA. The scan also revealed lysis of a portion of the root of the first premolar and allowed for accurate surgical planning.

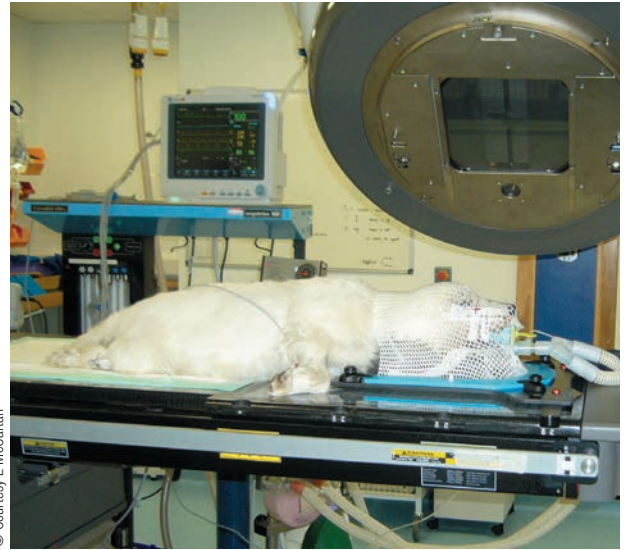
so locally invasive and wide margins are typically unachievable. Likewise palliative radiotherapy is not proven to improve survival significantly over untreated cases. No chemotherapy to date has been shown to be effective as treatment. Historically results were improved with the combination of radiotherapy and radiation sensitizers, but rapid recurrence was documented. A recent paper has described an accelerated radiation protocol with concurrent chemotherapy; cats received 14 fractions of 3.5 Gy for a total of 49 Gy in a nine-day period while receiving concurrent intravenous carboplatin. The protocol was intense but well-tolerated with a median survival time of 169 days; cats with disease of the tonsils or cheek had an increased survival time (17).

Pain management and the consideration of NSAIDs and antibiotic therapy, as well as frequent quality of life assessments, are crucial in the medical management of these cases.

### ■ Conclusion

The etiology of oral cancer in dogs and cats is poorly documented. Comparatively the most common oral cancer in humans, SCC is associated with alcohol and tobacco use. Similarly here the clinical stage, site and histological grade are prognostic and therapeutic options rely on surgery and radiotherapy. The initial diagnostic work-up of oral tumors in dogs and cats is crucial to determine the definitive diagnosis, clinical

staging and appropriate therapeutic options, as well as the prognosis in each case. With the exception of malignant melanoma, local disease control is typically the main aim for the most common tumors. Recent advancements and refinement of our ability to deliver radiotherapy (**Figure 5**) to veterinary patients should result in its increased utilization in the treatment of these tumors and as part of a multimodality therapeutic approach using both surgery and chemotherapy where appropriate.



© Courtesy L. McCartan

**Figure 5.** A canine patient prepared to receive radiotherapy for an oral tumor. Note the beam direction shell made from a thermoplastic material to allow for greater accuracy in patient positioning and hence treatment field.

## References

- Hoyt RF, Withrow SJ, Hoyt RF, *et al.* Oral malignancy in the dog. *J Am Anim Hosp Assoc* 1984;20:83-92.
- Stebbins KE, Morse CC, Goldschmidt MH. Feline oral neoplasia: a ten-year survey. *Vet Pathol* 1989;26:121-8.
- Liptak JM, Withrow SJ. Oral Tumors. In: Withrow, SJ and Vail, DM eds. *Small Animal Clinical Oncology* 4<sup>th</sup> ed. St Louis, Missouri: Saunders Elsevier; 2007:455-510.
- Ramos-Vara JA, Beissenherz ME, Miller MA, *et al.* Retrospective study of 338 canine oral melanomas with clinical, histologic, and immunohistochemical review of 129 cases. *Vet Pathol* 2000;37(6):597-608.
- Bergman PJ. Canine oral melanoma. *Clin Tech Small Anim Pract* 2007;22(2):55-60.
- Bergin IL, Smedley RC, Esplin DG, *et al.* Prognostic evaluation of Ki67 threshold value in canine oral melanoma. *Vet Pathol* 2011;48(1):41-53.
- USDA licenses DNA vaccine for treatment of melanoma in dogs. *J Am Vet Med Assoc* 2010;236(5):495.
- Pires I, Garcia A, Prada J, *et al.* COX-1 and COX-2 expression in canine cutaneous, oral and ocular melanocytic tumors. *J Comp Pathol* 2010;143(2-3):142-9.
- Clarke BS, Mannion PA, White RAS. Rib metastases from a non-tonsillar squamous cell carcinoma in a dog. *J Small Anim Pract* 2011;52(3):163-7.
- Grier CK, Mayer MN. Radiation therapy of canine nontonsillar squamous cell carcinoma. *Can Vet J - Revue Vétérinaire Canadienne* 2007;48(11):1189-91.
- Frazier SA, Johns SM, Ortega J, *et al.* Outcome in dogs with surgically resected oral fibrosarcoma (1997-2008). *Vet Comp Oncol* 2012;10(1):33-43.
- Fiani N, Verstraete FJM, Kass PH, *et al.* Clinicopathologic characterization of odontogenic tumors and focal fibrous hyperplasia in dogs: 152 cases (1995-2005). *J Am Vet Med Assoc* 2011;238(4):495-500.
- Mayer MN, Anthony JM. Radiation therapy for oral tumors: Canine acanthomatous ameloblastoma. *Can Vet J - Revue Vétérinaire Canadienne* 2007;48(1):99-101.
- Kelly JM, Belding BA, Schaefer AK. Acanthomatous ameloblastoma in dogs treated with intralesional bleomycin. *Vet Comp Oncol* 2010;8(2):81-6.
- Murray RL, Aitken ML, Gottfried SD. The use of rim excision as a treatment for canine acanthomatous ameloblastoma. *J Am Anim Hosp Assoc* 2010;46(2):91-6.
- Moore A. Treatment choices for oral cancer in cats; What is possible? What is reasonable? *J Fel Med Surg* 2009;11(1):23-31.
- Fidel J, Lyons J, Tripp C, *et al.* Treatment of oral squamous cell carcinoma with accelerated radiation therapy and concomitant carboplatin in cats. *J Vet Int Med* 2011;25(3):504-10.

## HOW I APPROACH...

# Fractures of the maxilla and mandible in cats



■ **Markus Eickhoff** DVM, DMD  
Weissach, Stuttgart, Germany

Dr. Eickhoff qualified as a dentist in 1993 from Johann Wolfgang von Goethe University in Frankfurt before graduating in 1999 as a veterinarian from Giessen's Justus Liebig University. As a past president of the German Veterinary Dental Society, Dr. Eickhoff runs a veterinary practice dedicated to dental, oral and maxillofacial medicine and has authored three textbooks on the subject.

### ■ Introduction

Jaw fractures account for 5-7% of all fractures in cats and are frequently caused by car accidents or by falls from a height (**Figure 1**). Jaw fractures are in many ways very different to fractures in other areas; in particular, there are differences in treatment options when a fractured section contains one or more teeth. Preserving tooth vitality and ensuring a natural occlusion are major factors during treatment; teeth can also have an important role in repositioning and stabilizing the fracture. Rapid, functional restoration is the most important consideration for treatment, as this is vital to permit the cat to feed properly. However, the fracture is often part of a multiple trauma problem

and jaw reconstruction is not the first priority; typically stabilization of the animal and treatment for shock are of primary importance. In general a cat that has been involved in an accident is immediately taken to the veterinarian by its owner; however an injured animal may only return to the owner's home some days after the trauma, and evidence of acute injury - and in particular a possible jaw fracture - may not be obvious.

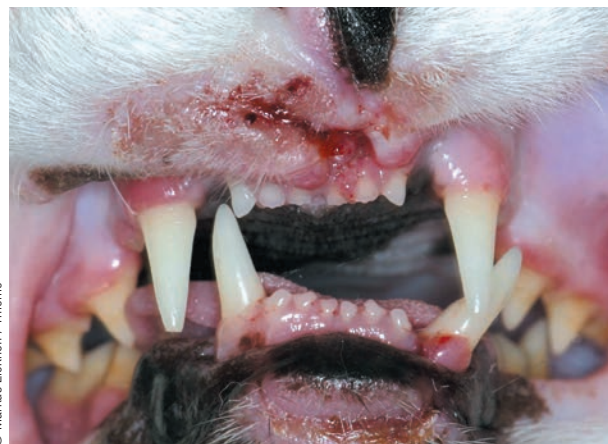### ■ Diagnosis

Abnormal movement of part of the jaw and crepitus are definitive indications of a fracture. Lack of symmetry, such as swelling, enophthalmos or exophthalmos, or lateral and rostro-caudal differences in jaw closing

## KEY POINTS

- The main focus when treating feline jaw fractures is to restore functional occlusion.
- Jaw fractures are often only one component in a multiple trauma case.
- Care must be taken to ensure that fracture treatment does not affect tooth viability.
- Fracture assessment requires good radiographic technique and can be augmented by CT and MRI imaging.

**Figure 1.** A cat post trauma; note the malocclusion caused by a fracture close to the canine tooth.



© Markus Eickhoff / Thieme

are not in themselves diagnostic of a fracture. If the jaw cannot close because the mandible is abnormally positioned, a fracture or a temporomandibular joint luxation may be present.

Fractures are usually identified by radiographs taken from several angles, *i.e.* dorsoventral/ventrodorsal and lateral views, as well as oblique projections to eliminate the superimposition of individual structures. Where there is a fracture of the maxilla, or if there is fracture of the caudal mandible, diagnosis may require radiography combined with 3D imaging (*i.e.* CT, MRI). If a fracture involves teeth it is helpful to obtain high-definition images of the fracture area using intra-oral radiographs.

Fractures and soft tissue injuries are often concomitant, such that there is bleeding in the mouth, increased salivation, and missing or displaced teeth, resulting in a painful, inflamed oral cavity which does not make for easy examination. The compact feline dentition means that even minor displacement of a tooth can lead to difficulty in closing the jaw; if this is noted the clinician should be alert for a potential fracture.

### ■ Fractures of the maxilla

The maxilla consists of paired maxilla, incisive and palatine bones, united in midline as the medial palatine suture. The main blood supply is via the infraorbital and palatine major arteries. The infraorbital artery enters via the maxillary foramen in the pterygopalatine fossa, runs through the infraorbital canal and exits via the infraorbital foramen. The palatine major artery enters at the major palatine foramen and runs rostrally either side of the palatine sulcus.

If the maxilla is fractured, displacement is generally minimal; damage is most commonly noted in the area of the medial palatine suture. At the same time the fractured bones may be displaced vertically and/or horizontally, leading to an abnormal occlusion. Trauma frequently causes formation of a cleft palate, with the risk that food or foreign bodies may be aspirated. Stabilizing a fracture in this area is not always possible due to the mass of the structures involved. The best course of action, if possible, is to align and stabilize the bones using cerclage wire and an acrylic splint. To do this, wires are placed around the teeth, using a drill to position them as appropriate; the fracture is then reduced and stabilized, with the wires embedded in an acrylic splint which is then secured to the teeth. In many cases a splint by itself can be sufficient for stabilization.

When a cleft palate is present and the bones around the palatine suture cannot be repaired, I advise soft-tissue closure of the cleft palate. If there is a wide defect, either a bi-pedicle advancement technique or an overlapping flap technique may be used.

- Bi-pedicle advancement technique: after debridement of the wound edges, bilateral para-marginal incisions are made a few millimeters palatally to the premolars and molars. The entire area between the cleft palate and the paramarginal incision is undermined, together with the palatine artery, so that each flap is only connected rostrally and caudally to the palatine mucosa. When suturing the flaps in midline, a multi-layer - and thus secure - closure is desirable, and an absorbable synthetic membrane may be inserted under the mucosa to assist healing. Finally the lateral palatine incisions are closed with interrupted sutures (see **Figure 15**, p.9).
- Overlapping flap technique: the prime aim of this technique is to ensure the sutures are supported by bone. On one side of the cleft palate a flap is prepared by a para-marginal incision while protecting the palatine artery, the edge of the cleft palate remaining untouched. The flap is then turned over (so that the roof of the mouth now forms the floor of the nasal cavity) and drawn across and under the palatine mucosa adjacent to the cleft palate before suturing it in place. This technique is problematic in cats as mobilization of the palatine artery can be difficult, but it is vital to preserve the vascular supply to the flap; if the artery is damaged or torn, necrosis of the flap is to be expected. Moreover, if the initial trauma causes laceration of the area around the cleft palate, there is a risk that a fistula may subsequently develop.

The exposed position and the length of the upper canine teeth predispose them to involvement in maxillary fractures; trauma may cause a tooth to be luxated laterally along with the buccal bone. If there is early intervention, replacement may be a possibility, stabilizing the tooth with an acrylic splint. After healing, tooth vitality should be checked via radiography (assessing pulp width and the periapical area) and endodontic treatment performed if required.

Where there are multiple fractures in the maxillary area with displacement of the fracture fragments, a mini plate may be employed for reconstruction of the maxilla; maximum protection of the tooth roots is essential with this technique.

## ■ Fractures of the mandible

The mandible consists of right and left hemimandibula, with a syndesmotic (ligamentous) or synchondrotic (cartilaginous) union at the symphysis. A synostosis (osseous union) may occur during a cat's life, but generally slight movement remains between the two halves of the mandible. The mandible is differentiated into the horizontal ramus and the vertical ramus, the teeth being located in the alveolar bone of the horizontal ramus. Blood vessels and nerves enter the mandible via the mandibular foramen on the inside aspect of the vertical ramus and then run rostrally through the mandibular canal parallel to the ventral margin of the mandible, before reappearing again at the mental foramen at the level of the third premolar tooth. The mandible is connected to the base of the skull in the region of the temporal bone via the temporomandibular joint. The cat's skull has a very deep fossa with pronounced caudal and rostral limitations, the retroarticular process and the post-glenoid process respectively. The temporomandibular joint is an incongruent hinge joint, separated by an intra-articular fibrocartilaginous disc into dorsal and ventral compartments, and is almost entirely limited to a single hinge movement, with very little lateral movement; this delivers the biting function which is ideal for the carnivorous feline dentition. The carnivorous function is completed by the anisognathous jaw, whereby the lower teeth are set closer together than the upper teeth.

The large masticatory muscles (masseter, pterygoideus and temporalis) insert on the lateral and medial surfaces of the vertical ramus proximal to the temporomandibular joint, and close the jaw; rostrally the digastricus and sublingual muscles open the jaw. The jaws are designed

to cope with the demands of mastication, in that the trabeculae of the cancellous bone correspond to the lines of greatest tension, and the cortical thickness varies depending on the load bearing; the ventral border of the lower jaw, where there is a large compression load, is very thick.

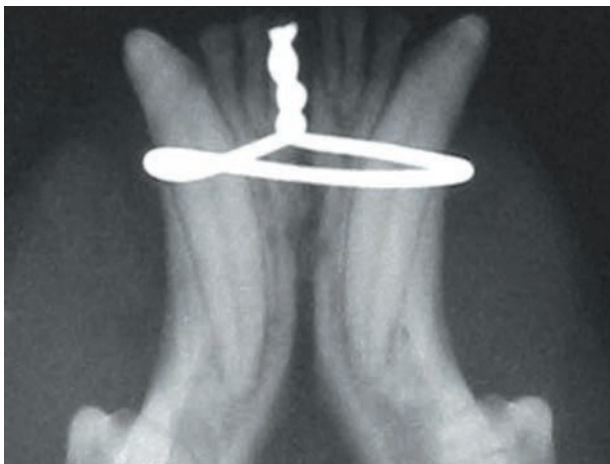The pull of the masticatory muscles and the course of a fracture line can create either favorable or unfavorable conditions for fracture healing. Note that the ventral edge of the mandible corresponds to the compression load, whilst the alveolar crest is associated with the tensile load, so that fracture repair may utilize a neutralization technique on the ventral aspect, or tension banding on the dorsal aspect, or both. However the presence of teeth on the tensile side can make conventional internal fixation problematic, and a modified treatment approach is often necessary if the fracture site involves teeth.

For fractures of both maxilla and mandible it is desirable to assess dental occlusion when reducing the fracture. Rather than temporarily removing the endotracheal tube for assessment, I prefer to intubate the patient via a pharyngostomy, which allows repeated evaluation of alignment throughout surgery. This technique is also useful when dealing with fractures of the caudal section of the mandible, when fixation via temporary immobilization of the canine teeth may be desirable.

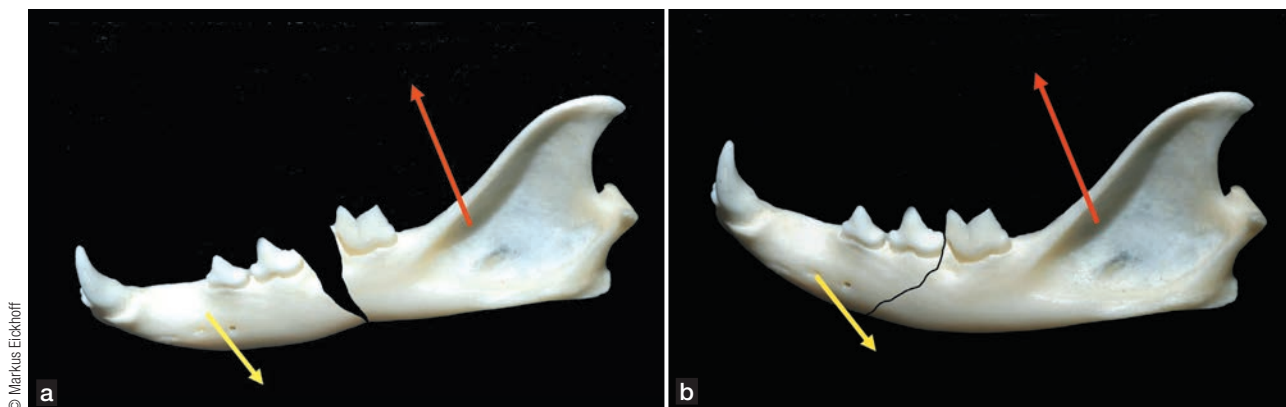
### Fractures of the mandibular symphysis

Given that the mandibular symphysis does not generally fuse via ossification, technically speaking it represents a preformed fracture site and this connection frequently separates, especially when a cat falls from a great height (the high-rise syndrome); as a cat drops, it often manages to rotate in mid-air, landing on all four feet to break its fall. However the cat's lower jaw often hits the floor at the same time, leading in many cases to a symphyseal separation. The muscles distract the left and right mandibular rami from one another, vertically and/or horizontally, and this is easily appreciated both clinically and radiographically. Standard treatment of this separation is by application of a circummandibular cerclage wire placed caudal to the lower canine teeth (**Figure 2**), with the wire tightened once left and right hemi-mandibles are aligned; the twist may be located either intra- or extra-orally. In either case the wire can be placed by use of a hollow guide such as a hypodermic needle. If the wire is to be twisted within the mouth, it may be preferable to place the twist on the lingual aspect of the incisors and bury it in the mucosa; lateral placement of the twist may impinge on one of

**Figure 2.** Separation of the mandibular symphysis repaired by use of a cerclage wire.



© Markus Eickhoff / Thieme



**Figure 3.** Fracture of the body of the mandible; the yellow arrow shows the direction of pull by muscles that open the jaw; the red arrow shows the direction of pull by muscles that close the jaw.  
**a.** Gaping of the fracture line and poor alignment.  
**b.** Good alignment of the fracture with compression in the area of the fracture line.

the upper canine teeth. Where the wire is to be twisted extra-orally, it is again placed via a guide and buried in the skin under the mandible. The size of wire used varies depending on the size of the cat, but is typically 0.3-1 mm in diameter.

Care must be taken that placement of the wire does not cause the crowns of the lower canine teeth to converge, as this can lead to poor occlusion and may even prevent the jaw from closing. To prevent this, a composite bridge may be secured between the lower canines. Note that treatment of a symphyseal fracture using a bone screw or transverse pin is not recommended as this will damage the roots of the canine teeth.

### Fracture of the horizontal mandible

As noted above, with a fracture of the mandibular body, depending on the course of the fracture line, the muscles may cause either a dislocation or a stabilization of the fracture; I refer to this as a unfavorable or favorable fracture accordingly. With a caudoventral fracture line, the pull of the musculature leads to distraction at the fracture gap (**Figure 3a**). With a caudodorsal fracture line the opposite happens – there is compression of the fracture gap (**Figure 3b**). If there are no teeth in the fractured section, the use of a bone plate (e.g. a miniplate) can be considered, but if teeth are present, the use of wire cerclage or a non-invasive method, such as an acrylic splint, is preferred. Note that when positioning the drill holes for wire placement one must take great care to avoid damaging tooth roots or the mandibular canal. The same problem arises when using a bone plate as the screw holes are pre-determined. On the ventral edge of the mandible, inserting a miniplate is relatively trouble-free but by itself it may not be suf-

ficiently strong for the load-bearing required. Therefore where a fracture involves teeth that are subject to traction, stabilization should ensure that the teeth are protected, and rather than employ a bone plate, an alternative procedure such as an acrylic splint, wire cerclage or a combination of both is preferred.

With a favorable fracture line, dorsal cerclage can give sufficient stability; with an unfavorable line, two cerclage wires are essential (**Figure 4a-d**). Alternatively, non-invasive treatment using an acrylic splint attached to the tooth arcade is possible, alone or in combination with cerclage. Additional stabilization of the splint may be obtained using wires placed between the teeth. Note that some acrylics give off heat as they set, and cold-cure materials are to be preferred in order to prevent thermal damage to the teeth. Before the acrylic has set it is imperative to ensure that occlusion is optimal; the teeth should be etched with phosphoric acid to produce a retentive surface, as the carnivorous shape of the teeth does not predispose the acrylic to bond to the enamel.

Immobilization of the fracture area via an external dressing is usually very difficult due to the shape of the cat's head, and use of either a tape muzzle or ligatures retained by buttons to reduce the fracture may not achieve total immobility, such that small movements at the fracture site remain; this can prevent bone healing and may lead to the creation of a pseudoarthrosis. If the oral cavity is fixed in a closed position for fracture repair, a feeding tube is obviously necessary.

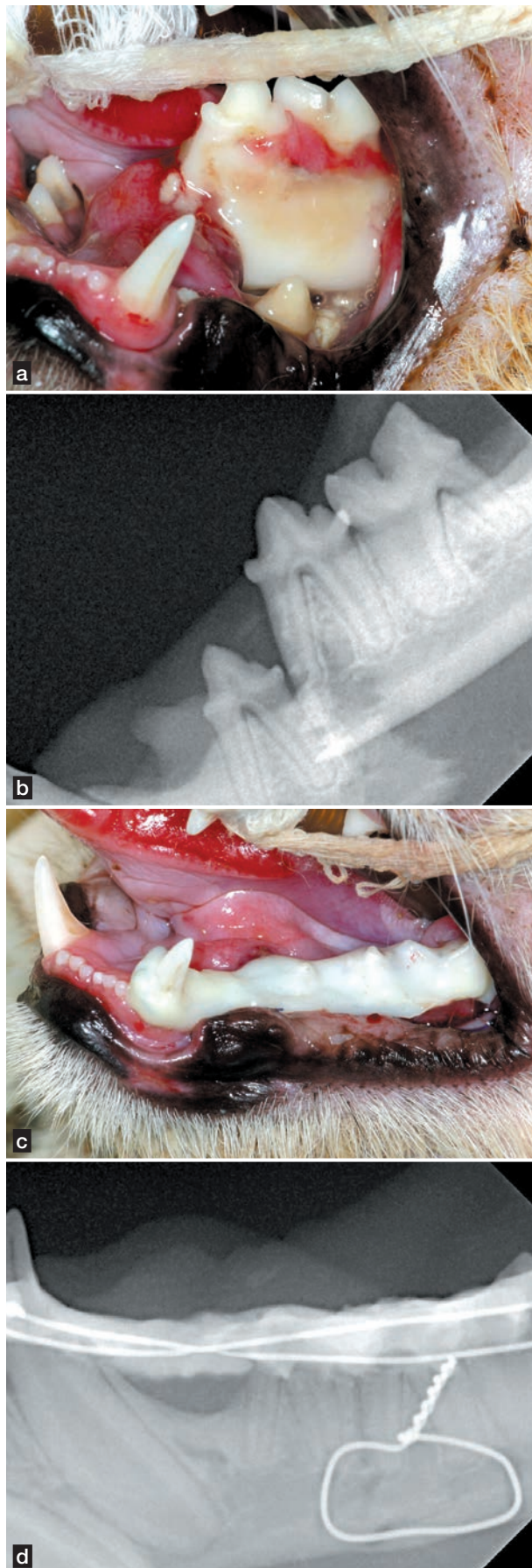
Where there are multiple fragments or a large bone defect, the use of an external fixator can be considered,

but again care should be taken to protect the teeth as much as possible. Two Kirschner wires per fragment are sufficient, inserted at different angles before aligning them close to the jaw and setting them in acrylic. Note that use of an intramedullary pin, e.g. placed in the mandibular canal is obsolete.

### Fractures of the vertical mandible

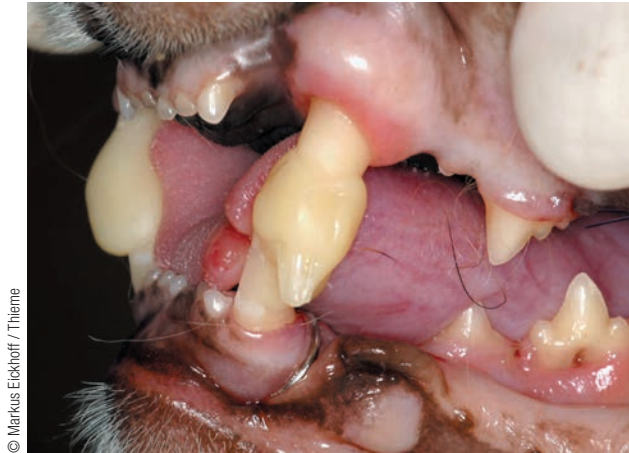Where the thin-walled vertical ramus is fractured, the medial and lateral muscle masses may hold the fragments in alignment and offer sufficient stability. However, depending on the fracture gap, muscle contraction may cause over-riding of the bones with shortening of the vertical ramus; here treatment using wire cerclage or a miniplate may be considered.

Fractures of the joint process may be identified clinically when the jaw cannot be closed on the damaged side. Fractures at this site are challenging in terms of radiographic diagnosis, and standard projections are frequently not sufficient to assess the fracture. With a lateral oblique projection it is possible to highlight the joint, but better still is a CT or MRI image. Because of the small anatomical size, a temporomandibular joint process fracture is very difficult or impossible to treat surgically, but the movement of the mandible can create a pseudoarthrosis. In many cases, despite the lack of healing, the pseudoarthrosis is sufficiently functional and no further treatment is required, as long as occlusion is not impeded. Callus formation can cause ankylosis of the joint, and resection of the temporomandibular joint head may be necessary. As direct treatment at the fracture site is usually not possible, there is the alternative of immobilizing the mandible via temporary fixation to the maxilla, a so-called intermaxillary (or maxilla-mandibular) block, whereby the four canines are held in a fixed position by a composite bridge (**Figure 5**). Fixation with the mouth fully closed guarantees a good occlusion, but it is necessary to place an esophageal tube for feeding. Fixation in a semi-open position must be accurate in order to prevent subsequent poor occlusion, but in many cases will allow the



**Figure 4.** Mandible fracture with displacement.  
**a.** The caudal section of the mandible is pulled towards the base of the skull whilst the rostral section is displaced ventrally.  
**b.** Radiography clearly demonstrates the displaced section of mandible.  
**c.** The fracture was reduced and fixed using an acrylic splint and cerclage wire.  
**d.** Post-operative radiograph showing realignment of the jaw with splint and wires.

© Markus Eickhoff



© Markus Eickhoff / Thieme

**Figure 5.** Use of composite on the canine teeth to stabilize a fracture close to the temporomandibular joint.

patient independent intake of liquid food. As above, the use of a tape muzzle or ligatures to close the oral cavity when dealing with a temporomandibular joint fracture is, due to the obvious possibility of mandibular movement, very much a secondary preference.

The intermaxillary block should be kept in place for 2-3 weeks; this is usually sufficient for healing and prevents remodeling of the immobilized joint. The wire cerclages, plates and splints described above can be removed after six weeks.

### ■ Teeth in the fracture gap

In many cases teeth present within a fracture must be left *in situ* to guarantee stabilization or to enable an acrylic splint to be placed. Contraindications for leaving a tooth in the fracture area include an exacerbated periodontal event, a severe loosening of the tooth, or a clearly infected crack in the tooth. Where an essential tooth is fractured, temporary endodontic treatment is required to prevent pulpitis and to avoid impaired fracture healing. Definitive endodontic treatment can then be performed after the fracture has healed, or alternatively the tooth can be removed. Because the fracture gap is often in direct communication with the mouth and its associated bacteria, antibiotic treatment should be given in order to support healing, and anti-inflammatory and analgesic treatment is also obligatory.

### ■ Conclusion


The main focus when treating a feline jaw fracture is to restore functional occlusion; this is to be preferred to perfect alignment of the fracture fragments as judged by radiology. During treatment one should take care to protect the teeth as far as possible, as they are frequently needed for stabilizing the fracture, and although wire cerclage and osteosynthesis plates are very useful, non-invasive techniques using acrylic can often be very effective.

### Further reading

- Bellows J. *Feline Dentistry: oral assessment, treatment and preventive care*. 1<sup>st</sup> ed. Wiley: Blackwell 2010.
- Tutt C, Deepprose J, Crossley D. Eds. *Manual of canine and feline dentistry*. 3<sup>rd</sup> ed. Gloucester: BSAVA 2007.
- Eickhoff M. *Zahn- Mund- und Kieferheilkunde bei Klein- und Heimtieren*. 1<sup>st</sup> ed. Stuttgart: Enke Verlag 2005.
- Niemic BA. *Small animal dental, oral and maxillofacial disease*. 1<sup>st</sup> ed. London: Manson 2010.
- Verstraete FJM, Lommer MJ. *Oral and maxillofacial surgery in dogs and cats*. 1<sup>st</sup> ed. Philadelphia: Saunders 2012.



# Epidemiology of periodontal disease in older cats



■ **Elizabeth Lund, DVM, MPH, PhD**  
Banfield Pet Hospital, Portland, Oregon, USA



Dr. Lund joined Banfield in 2006 as Senior Director of Research for the Applied Research & Knowledge team. As an epidemiologist, Dr. Lund's experience over the last 22 years has included research in academia, industry and public health. In addition to her DVM, she also has a Master's degree in public health and a PhD in epidemiology/informatics.

**Oral cavity disease is the most prevalent diagnosis in both dogs and cats (1). Not only are many of these disorders preventable, the reported associations between periodontal disease and systemic illness in both animals (2-4) and humans (5,6) should motivate the clinician towards proactive measures which will positively impact the overall quality of life for both pet and owner.**

## ■ **Methods of analysis**

For this population analysis, feline in-patients seen in 2006 that were  $\geq 5$  years of age and had received one or more diagnoses in the oral disease category were selected. These cases were compared to a sample of 5,000 feline in-patients with a similar age distribution but with no oral disease diagnosis. Overall prevalence rates for all oral diseases, including periodontal disease diagnoses, were generated from the Banfield in-patient population. Prevalence of the clinical signs reported for the population with periodontal disease (dental calculus; gingivitis; gingival recession; periodontal pockets and/or subgingival calculus) were also estimated. Logistic regression was used to determine risk factors important in predicting which cats are most likely to be diagnosed with periodontal disease. Potential risk factors included in the model were age, breed, gender, region and concurrent diagnosis (*i.e.* overweight, obesity, heart murmur, chronic kidney disease, aggressive behavior, diabetes mellitus, dermatitis, feline immunodeficiency virus [FIV], acute renal injury, hypertrophic cardiomyopathy or feline leukemia virus [FeLV]). To quantify risk, the relative risk (RR) was estimated using the odds ratio (OR) (7) for the association between age, breed, gender and the concurrent diseases of interest.

For the analysis, we used a p-value of .05 to determine statistical significance.

## ■ **Results**

There were 103,934 in-patient cats aged  $\geq 5$  years identified from Banfield hospital records during 2006, of which 55,455 (53.4%) were diagnosed with oral disease; 16,374 (15.8%) of cats were diagnosed with periodontal disease. Of this group, the following clinical signs were reported: tartar (94.2%)\*, swelling or inflammation of gums (69.5%), infected pockets in gums (18.1%), gum recession (17.7%) and halitosis (13.0%). The mean age of the case group was 9.8 years, while the mean age of the control population was 9.7 years.

**Table 1. Prevalence of specific oral and/or periodontal disease diagnoses for cats with periodontal problems.**

Disease	Case Population (n=16,374)
Dental calculus *	39.7%
Gingivitis	28.6%
Periodontal disease, grade 2 **	25.1%
Periodontal disease, grade 1 **	20.6%
Periodontal disease (unspecified) **	16.2%
Periodontal disease, grade 3 **	15.9%
Periodontal disease, grade 4 **	4.6%
Gingival recession	1.7%
Periodontal pockets	0.4%
Subgingival calculus	0.04%

**Table 1** details prevalence in the periodontal disease case group for selected oral and periodontal conditions, whilst **Table 2** lists the prevalence for diseases hypothesized to be associated with periodontal disease for the case group vs. the control population. Statistically significant results from the multivariate analysis can be found in **Table 3**.

### Discussion

Based on the multivariate analysis, older cats with periodontal disease are more likely to be spayed or neutered than those without periodontal disease, and are more likely to be Himalayan, Siamese or Persian. They are also more likely to be concurrently diagnosed as overweight or obese and to have a heart murmur, aggression, diabetes mellitus or FIV recorded in their medical record. The odds of being diagnosed as overweight or obese or with a heart murmur were about five times greater for cats with periodontal disease as compared with those without. The concurrent diagnosis of aggressive behavior is an interesting finding and may reflect a behavioral response to the pain that can accompany severe periodontal disease.

**Table 2. Prevalence of selected diagnoses for cats with and without periodontal disease.**

Disease/condition	Cases (n=16,374)	Controls (n=5,000)
Overweight	15.6%	3.5%
Obesity	5.0%	1.1%
Heart murmur	5.0%	1.2%
Chronic renal failure	3.3%	3.1%
Aggressive behavior	2.1%	0.8%
Diabetes mellitus	1.9%	1.1%
Dermatitis	1.8%	1.3%
FIV	0.7%	0.3%
Acute renal failure	0.5%	0.4%
Hypertrophic cardiomyopathy	0.3%	0.1%
FeLV	0.2%	0.2%

**Table 3. Multivariate results: predictors of periodontal disease in cats ≥ 5 years of age.**

Variable in model	Relative risk***	Confidence interval
Overweight	5.0	4.3-5.9
Heart murmur	4.5	3.5-5.9
Obesity	4.5	3.4-5.9
FIV	2.8	1.6-4.9
Aggressive behavior	2.2	1.5-3.0
Himalayan	1.6	1.3-2.0
Diabetes mellitus	1.5	1.1-2.0
Spayed/neutered	1.5	1.2-1.8
Persian	1.3	1.1-1.6
Siamese	1.3	1.1-1.5

\* Note that the figures for calculus and tartar vary because dental calculus is a diagnosis and tartar is an examination finding - if tartar was noted on examination but wasn't severe enough to warrant an intervention, calculus was not diagnosed.

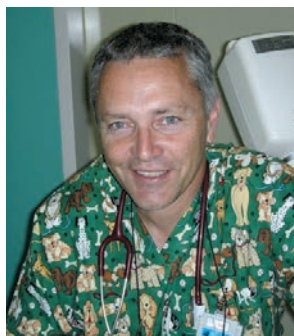\*\* Periodontal disease was graded as follows: grade 1: inflammation; grade 2: inflammation, swollen gums and early bone loss; grade 3: inflammation, swelling, bone loss and loose teeth; grade 4: inflammation, swelling, pus, bone loss and loose teeth.

\*\*\* Estimated using the odds ratio. A relative risk (RR) > 1 suggests a positive association between an outcome and a factor; whereas RR < 1 suggests an inverse relationship between a factor and disease outcome; RR = 1 reflects no association.

### References

- Lund EM, Armstrong PJ, Kolar LM, *et al.* Health status and population characteristics of dogs and cats examined at private veterinary practices in the United States. *J Am Med Vet Assoc* 214;1999:1336-1341.
- Logan EI. Dietary influences on periodontal health in dogs and cats. *Vet Clin North Am Small Anim Pract* 2006;36:1385-401.
- Glickman LT, Glickman NW, Moore GE, *et al.* Evaluation of the risk of endocarditis and other cardiovascular events on the basis of the severity of periodontal disease in dogs. *J Am Vet Med Assoc* 2009;234(4):486-94.
- Glickman LT, Glickman NW, Moore GE, *et al.* Association between chronic azotemic kidney disease and the severity of periodontal disease in dogs. *Prev Vet Med* 2011;99(2-4):193-200.
- Iacopino AM. Periodontitis and diabetes interrelationships: role of inflammation. *Ann Periodontol* 2001;6:125-137.
- Beck JD, Offenbacher S. The association between periodontal diseases and cardiovascular diseases: A state-of-the-science review. *Ann Periodontol* 2001;6:9-15.
- Odds ratio and Relative risk. Wikipedia. Available at: [http://en.wikipedia.org/wiki/Relative\\_risk](http://en.wikipedia.org/wiki/Relative_risk). Accessed June 8, 2012.

# Systemic implications of periodontal disease



■ **Alessandro De Simoi**, Med Vet, Dipl. EVDC  
Clinica Veterinaria Feltrina, Feltre, Italy

Dr. De Simoi graduated from the University of Bologna in 1990 and obtained his EVDC diploma in 2008. His main interests are dentistry and maxillofacial surgery in small animals and horses. Between 2001-2003 he trained at the European School for Advanced Veterinary Studies in Luxemburg and has also spent periods in the UK (at the Bell Equine Veterinary Clinic and the Royal Dick School of Veterinary Studies) and the USA (at the University of Pennsylvania). He has participated in numerous national and international meetings and conferences on veterinary dentistry, and has presented courses on the subject in Switzerland and France. He served as secretary of the Italian Society of Veterinary Dentistry and Oral Surgery from 2001-2004, and is currently Vice-President of the society.

## ■ Introduction

Periodontal disease is the most common infectious disease found in small animals with a prevalence that approaches 80% (1); prevalence increases with age and diminishes as body size increases – it is much more common in smaller animals compared to those of medium and large size (1). The periodontium comprises the gingiva, cementum, dental alveolar ligament and alveolar bone, which together contribute to the support of the tooth. Periodontal disease is caused by bacterial plaque, and can be subdivided into two parts:

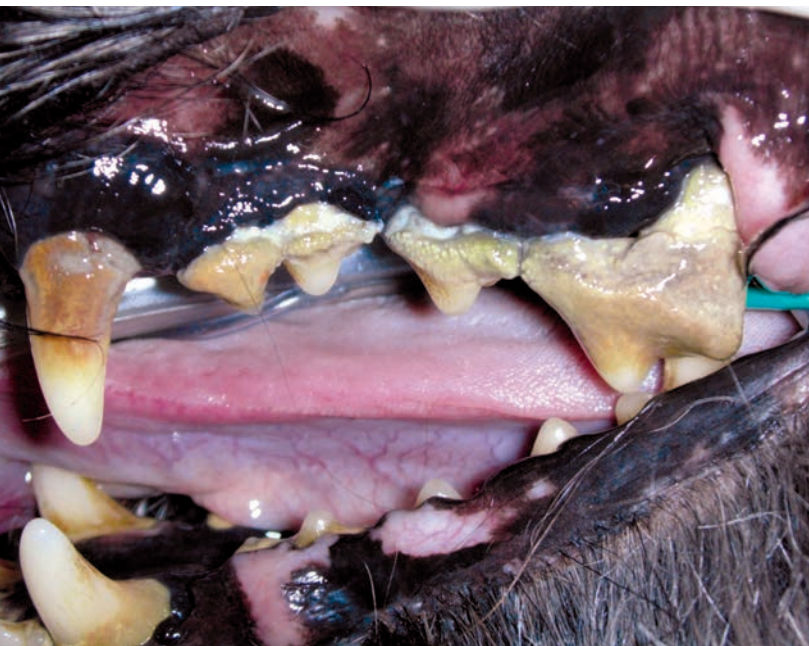gingivitis and periodontitis. Gingivitis is a reversible inflammation of the gums, because once the cause (bacterial plaque) has been removed, the inflammation recedes. Periodontitis, on the other hand, is an irreversible inflammatory condition of non-gingival tissue (the alveodental ligament, cementum and alveolar bone) and is assessed by measuring the loss of attachment of the tooth. Periodontitis may be either inactive (quiescent), where there is no evidence of gingival inflammation (and if there has been loss of tooth attachment this may have occurred some time previously), or active, where there is ongoing destruction of tissue (**Figure 1**). Although it is recognized that periodontitis is an infectious disease, and more than 700 bacterial species have been identified as being capable of colonizing the biofilm of the subgingival sulcus, Koch's postulates\* do not apply (2).

Gingivitis, even if untreated, does not always result in periodontitis; the development of periodontal disease is in fact determined by an imbalance between the bacterial population and the host immune system. Immune capability, stress, age, nutritional and metabolic status, breed and endocrine disease are all factors that may aid or prevent the progression of periodontal disease. If the disease progresses, the bony destruction

## KEY POINTS

- Periodontal disease is the most common infectious disease found in small animals.
- It has been suggested that periodontal disease can be a major factor in various systemic illnesses including cardiovascular problems, reproductive disorders, liver disease and diabetes.
- Various hypotheses have been suggested as to how periodontitis may influence systemic disease but as yet there is no definitive proof of a link.
- Periodontal disease can be prevented by meticulous removal of bacterial plaque with tooth brushing and oral hygiene.

\* 1. The microorganism must be found in abundance in an animal suffering from the disease, but should not be found in healthy animals. 2. The microorganism must be isolated from a diseased animal and grown in culture. 3. The cultured microorganism should then cause disease when introduced into a healthy animal. 4. The microorganism must be re-isolated from this experimentally infected animal and identified as being identical to the original causative agent.



© Dr. De Simoni

**Figure 1.** Active severe periodontitis in a dog.

and apical migration of the supporting connective tissue will cause loosening and eventual loss of one or more teeth.

Periodontal disease is a focal infection. This concept, introduced more than a century ago, describes a localized, chronic disease, which represents a source of microorganisms, toxins, and products of bacterial and tissue degradation, capable of reaching distant organs and tissues (3). The surface area involved in periodontitis has been measured in affected toy breeds and found to range between 3.18-29.8 cm<sup>2</sup> (4) and so the area of diseased tissue can represent a considerable proportion of the dog's total body surface area.

During the development of periodontitis the bacteria present in periodontal pockets can reach the bloodstream, causing bacteremia, and, although in healthy individuals these are intercepted by the reticuloendothelial system (5), the continuous prolonged exposure to bacteremia may be associated with systemic disease associated with distant organs and systems (6-7). The systemic implications of periodontal disease are not, however, limited to the bacterial load. Inflammatory chemical mediators, bacterial endotoxins and toxins from tissue degradation can also be involved, either by direct harmful effects or because they cause immune reactions in organs distant to the oral cavity.

### ■ Cardiovascular implications

More than 50 studies in human medicine have been published examining the relationship between periodontal disease and cardiovascular disease (CVD), and most of them agree that there is a direct correlation between the two. For example, constituents of periodontopathic bacteria were detected in atherosclerotic plaques (8), whilst other studies concluded that there is a significant correlation between periodontal disease and CVD (9-10).

The same is true in veterinary medicine, where studies have also demonstrated a positive correlation between the presence of periodontal disease and histopathologic changes affecting the heart and other internal organs (4-7, 11-13). Nevertheless, international scientific opinion is not unanimous on the importance of oral infections in the genesis of systemic disease; this is because there is currently no conclusive evidence of a direct link between periodontal disease and other diseases (14).

### ■ Reproductive disorders

It has been shown that pregnant women with periodontitis are up to 7.5 times more likely to give birth prematurely, and for their babies to have low birthweight. This finding correlates with the increase in pro-inflammatory cytokines triggered by circulating bacterial lipoproteins. In some cases periodontopathic bacteria were detected directly within the amniotic fluid (15).

### ■ Diabetes mellitus

High circulatory levels of inflammatory chemical mediators such as interleukin 6 (IL6), tumor necrosis factor (TNF) and C-reactive protein (CRP) may increase insulin resistance and thus prevent correct control of blood glucose in diabetic patients. One report noted that treating periodontal infection in a diabetic dog allowed subsequent control of blood sugar levels with insulin therapy (16).

### ■ Liver disease

Hepatic degeneration, steatosis, and intrahepatic abscesses have been described and associated with periodontitis in both humans and dogs (7). A recent publication noted that liver function tests improved after periodontal therapy in humans, and reported that infection with the bacteria *Porphyromonas gingivalis* may be a risk factor in the development and progression of hepatic steatosis and steatohepatitis (17).

### ■ Etiopathogenic hypotheses

Given that it is difficult to clearly identify the mechanisms

that link oral and systemic disease, different hypotheses have been proposed to explain this relationship, namely direct infection, systemic inflammation with endothelial damage, and molecular mimicry between bacterial antigens and autoantigens.

### Direct infection hypothesis

Bacteria such as *Streptococcus spp.*, *Staphylococcus spp.*, *P. gingivalis* and their byproducts can cross the vascular barrier and enter the systemic circulation. A transient bacteremia has been demonstrated after chewing and tooth-brushing and during dental prophylaxis and surgery; however bacteremia is generally of little or no clinical significance in healthy subjects. It was, however, demonstrated experimentally that bacteremia with *P. gingivalis* induces the appearance of atherosclerosis in susceptible pigs and mice. Several periodontopathogens were then isolated either directly or recognized through PCR in organs and tissues at sites distant to the oral cavity. A recent study showed that *P. gingivalis* was present in 100% cases of atherosclerotic plaques in humans (18,19).

### Systemic inflammation hypothesis

According to this hypothesis periodontitis causes an increase in circulating cytokines which can directly damage the endothelium of blood vessels, leading to the formation of lesions that affect the heart and other internal organs. It has been demonstrated that pro-inflammatory cytokines such as TNF and IL6 can

cause anabolic mutations in myocytes through the activation of intracellular signals leading to myocardial hypertrophy (20). In several studies high levels of CRP have been observed in cases of chronic periodontitis (21) whilst one recent study (22) demonstrated that people who underwent intensive periodontal therapy (scaling and root planing) had significantly reduced elasticity of their brachial artery 24 hours post-therapy when compared to a control group. This was related to the increase in CRP and IL6 during periodontal therapy. However 60 and 180 days after the dental work, the vascular elasticity was significantly greater in the group subjected to periodontal therapy compared to the control group; this increase was attributed to the beneficial effects of the periodontal treatment.

### Molecular cross-reactivity hypothesis

According to the molecular cross-reactivity hypothesis the development of systemic disease is the consequence of an immune response induced by bacterial heat-shock proteins (HSPs). All cells (including endothelial cells) which are subject to stress in various forms express HSP, and bacterial HSPs are a further antigenic challenge during infections. The immune system is not always able to distinguish between bacterial and autologous HSPs, so that during a periodontitis infection cross-reactive T-lymphocytes are activated and antibodies are produced which may cause an autoimmune response to antigenically similar host tissues (23). In the case of atherosclerosis it has been demonstrated that endothelial cells express a human HSP called HSP60; however several periodontopathic bacterial species have also been found to produce their own HSP60 which is very similar to the autologous stress protein. The bacterial HSPs induce the synthesis of targeted antibodies which may attack the host cells. Several studies have shown that periodontal infection may contribute to atherosclerosis and cardiovascular disease through molecular mimicry mechanisms (24-25).

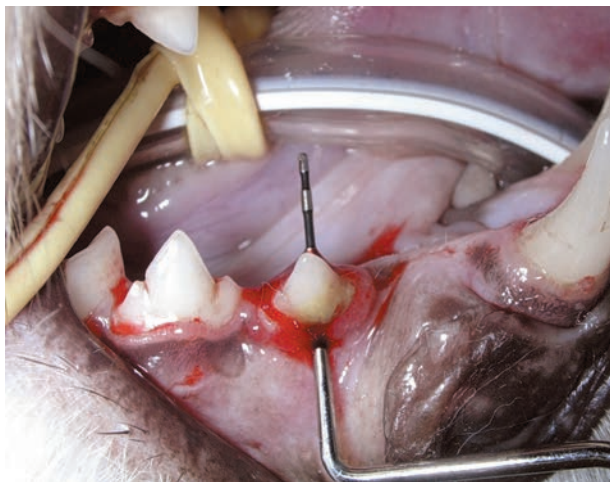
### ■ Diagnosis of periodontal disease

Generally, periodontal disease starts with few or no clinical signs and the main reason for the owner to request an evaluation of the oral cavity is because their pet has developed halitosis. Accurate diagnosis cannot be based solely on visual inspection of the oral cavity; general anesthesia followed by a periodontal examination involving the use of a probe (**Figure 2**) and intraoral radiography is essential. Various periodontal probes are available but all are designed to

**Figure 2.** A periodontal probe with colored bands to allow measurement of gingival pocket depth.



© Dr. De Simoi



© Dr. De Simoi

**Figure 3.** A furcation lesion; the probe can be easily inserted between the roots of the tooth.

allow pocket depth measurement and assessment of gingival hyperplasia or recession. With the probe one can also evaluate the degree of tooth mobility and the presence of furcation lesions in double or triple rooted teeth (**Figure 3**). The probe should be gently introduced into the gingival sulcus (**Figures 4-5**), ideally evaluating 4-6 points around the circumference of each tooth; apparently healthy buccal teeth may have deep pockets either palatally or lingually. All observations must be recorded on a dental chart in order to provide an overall assessment.

### ■ Prevention and treatment of periodontal disease

Periodontal disease can be prevented by meticulous

removal of bacterial plaque with tooth brushing and oral hygiene. Some commercial diets may help in reducing coronal plaque but the crucial factor is the removal of subgingival plaque. The aim is not to sterilize the oral cavity but to prevent the bacterial biofilm changing from a mixed commensal population dominated by aerobic bacteria to a population that is predominantly anerobic. Treatment of periodontal disease should be performed with the animal anesthetized and the trachea intubated; once the arcades have been accurately charted and intra-oral radiographs have been analyzed (**Figures 6-7**) supra- and subgingival scaling is performed, followed by more complex procedures such as tooth extraction or periodontal surgery as indicated.

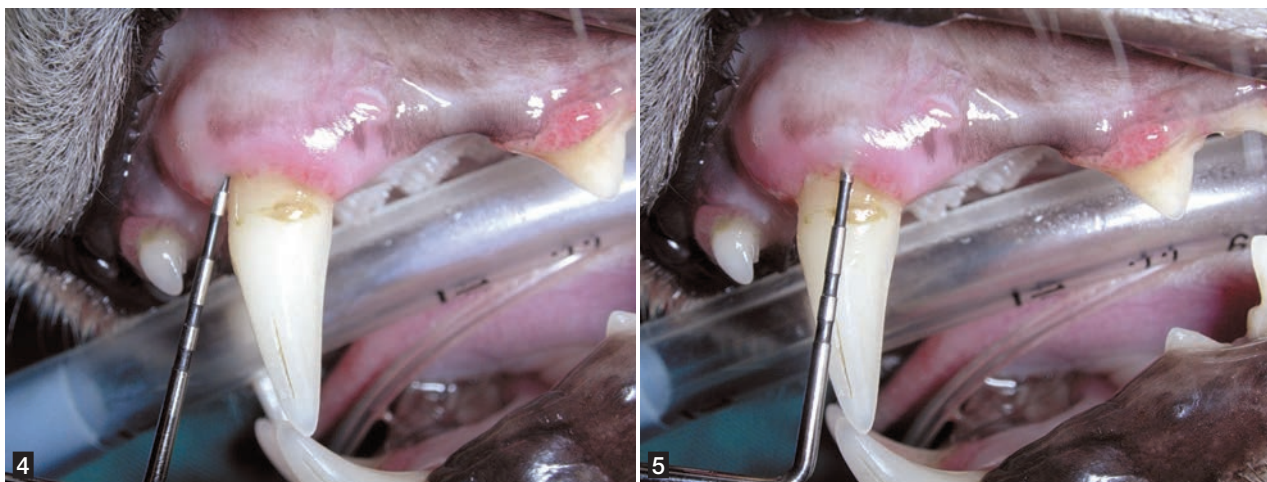
### ■ Antibiotic usage

Severe and extensive periodontal disease in an otherwise healthy subject should not be treated with antibiotics long term; the correct treatment is to remove the cause (plaque, tartar, irreparably compromised teeth) by scaling the teeth and performing tooth extraction as necessary. Antibiotics should be used for two main purposes: to treat local infection and to prevent bacteremia.

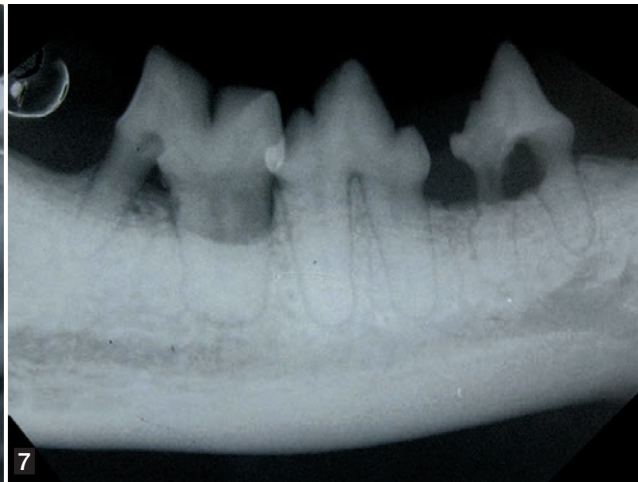
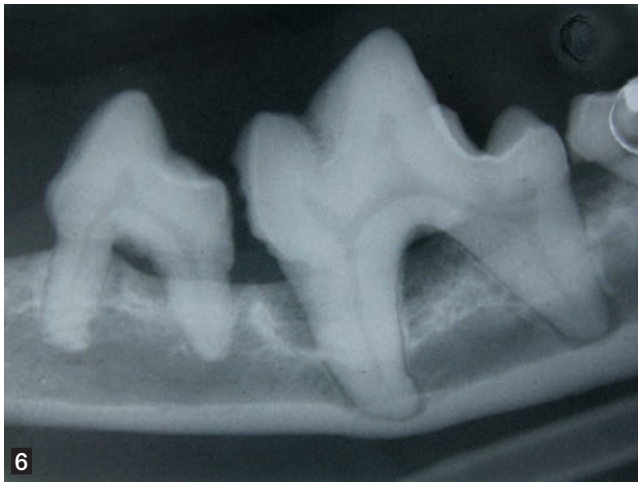
### Treatment of local infection

If periodontal disease has caused osteomyelitis of the maxilla or mandible, antibiotic therapy is recommended, starting a few days before surgery and continuing for several weeks afterwards. The use of antibiotics a few days before surgery is also indicated where ulcerative gingival lesions have developed (even if there is only a small accumulation of plaque), in cases of chronic

**Figures 4 and 5.** On examination a probe should be gently introduced into the gingival sulcus at 4-6 points around the circumference of each tooth; note how the depth varies with this tooth.



© Dr. De Simoi



**Figures 6 and 7.** Intra-oral radiographs are essential when assessing dogs and cats with possible periodontitis. Note the loss of alveolar bone around the affected teeth.

ulcerative paradental stomatitis in dogs (**Figures 8a and b**), and in cats with stomatitis.

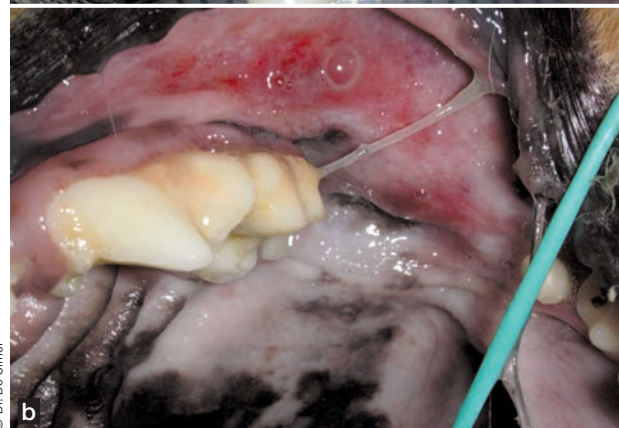
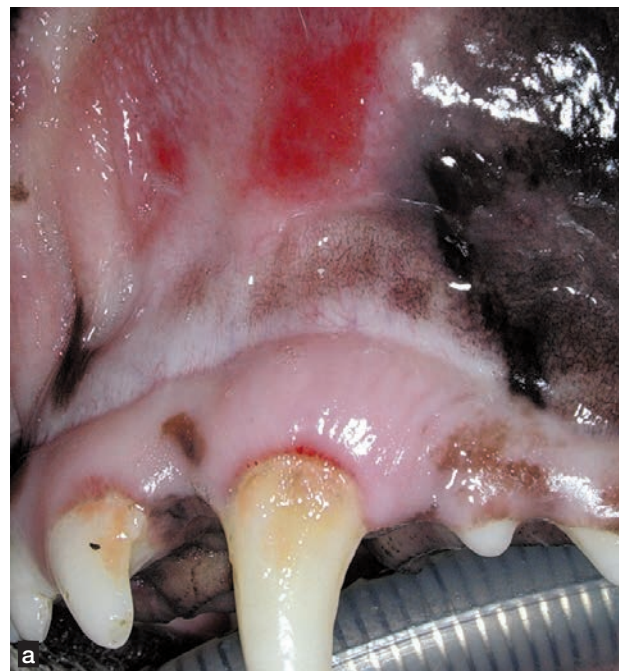### Prophylaxis of bacteremia

Bacteremia is common in patients with active gingivitis and periodontitis, from normal daily activities such as grooming and chewing of food. In healthy subjects this is quickly countered by the activity of the reticulo-endothelial system. In the case of periodontitis patients with serious systemic disease such as heart problems, subjects with joint or eye replacements, splenectomized subjects or with hyperadrenocorticism, and when cellular metabolism is depressed by systemic disease, the risk that tissues distant to the mouth may be affected justifies the use of perioperative antibiotics. In these cases the choice is a broad-spectrum bactericidal antibiotic that can be administered intravenously at induction of anesthesia and repeated if the operation lasts more than two hours. It is also possible to administer a single dose orally on the morning of the surgery.

### Conclusion

At present there is no unequivocal evidence of a direct relationship between periodontal disease and systemic effects, even though there are various hypotheses that explain the relationship between the two conditions. However, much evidence suggests that periodontal disease may promote and maintain inflammation in organs distant to the mouth, and that even in the early stages of periodontitis the body can react with the synthesis of acute phase proteins, thereby demonstrating the stimulation of a systemic disease induced by inflammation within the oral cavity.

**Figures 8a and b.** Ulcerative gingival lesions in a dog with chronic ulcerative paradental stomatitis.



The health of the periodontium is not only important for the maintenance of the teeth. Periodontal disease can have a significant impact on overall health and may be responsible for morbidity and mortality, especially in certain susceptible dog breeds. Preventive measures such as oral hygiene, the use of chew toys, and the feeding of products specifically designed to reduce the accumulation of bacterial plaque and calculus should be considered when managing periodontitis. Dental

health food products typically consist of a kibble with a conformation and structure that deliver a mechanical abrasive action, but some products also contain sodium polyphosphate which will chelate the salivary calcium, slowing the mineralization of plaque and consequently the formation of tartar. These foods may therefore be recommended as an aid in a general plan to reduce the risk of periodontal disease.

## References

- Lund EM, Armstrong PJ, Kirk CA, *et al.* Health status and population characteristics of dogs and cats examined at private veterinary practices in the United States. *J Am Vet Med Assoc* 1999;214:1336-1341.
- Haffajee AD, Socransky SS. Introduction to microbial aspects of periodontal biofilm communities, development and treatment. *Periodontol* 2000;2006; 42:7-12.
- Vieira CL, Caramels B. The history of dentistry and medicine relationship: could the mouth finally return to the body? *Oral Dis* 2009;15(8):538-46.
- Pavlica Z, Petelin M, Juntos P, *et al.* Periodontal disease burden and pathological changes in organs of dogs. *J Vet Dent* 2008;25(2):97-105.
- Silver JG, Martin L, McBride BC. Recovery and clearance of oral micro-organism following experimental bacteremia in dogs. *Arch Oral Biol* 1975;20:675-9.
- Glickman LT, Glickman NW, Moore GE, *et al.* Evaluation of the risk of endocarditis and other cardiovascular events on the basis of the severity of periodontal disease in dogs. *J Am Vet Med Assoc* 2009;234:486-494.
- DeBowes LJ, Mosler D, Logan E, *et al.* Association of periodontal disease and histologic lesions in multiple organs from 45 dogs. *J Vet Dent* 1996;13:57-60.
- Paquette DW. The periodontal infection-systemic disease link: a review of the truth or myth. *J Int Acad Periodontol* 2002;4(3):101-9.
- Janket SJ, Baird A, Chuang S, *et al.* Meta-analysis of periodontal disease and risk of coronary heart disease and stroke. *Oral Surg Oral Med Oral Pathol* 2003;95:559-596.
- Khader YS, Albashairah ZSM, Alomari MA. Periodontal disease and the risk of coronary heart and cerebrovascular disease: a meta-analysis. *J Periodontol* 2004;75:1046-1153.
- Glickman LT, Glickman NW, Moore GE, *et al.* Association between chronic azotemic kidney disease and the severity of periodontal disease in dogs. *Prev Vet Med.* 2011 May 1;99(2-4):193-200. Epub 2011 Feb 23.
- Peddle GD, Drobatz KJ, Harvey CE, *et al.* Association of periodontal disease, oral procedures, and other clinical findings with bacterial endocarditis in dogs. *J Am Vet Med Assoc.* 2009 Jan 1;234(1):100-7.
- Yu G, Yu Y, Li YN, *et al.* Effect of periodontitis on susceptibility to atrial fibrillation in an animal model. *J Electrocardiol.* 2010 Jul-Aug;43(4):359-66. Epub 2009 Dec 29.
- O'Reilly PG, Claffey NM. A history of oral sepsis as a cause of disease. *Periodontol* 2000. 2000;23:13-18.
- Baskaradoss JK, Geevarghese A, Al Dosari AA. Causes of adverse pregnancy outcomes and the role of maternal periodontal status - a review of the literature. *Open Dent J* 2012;6:79-84. Epub 2012 May 9.
- van Nice E. Management of multiple dental infections in a dog with diabetes mellitus. *J Vet Dent* 2006;23(1):18-25.
- Yoneda M, Naka S, Nakano K, *et al.* Involvement of a periodontal pathogen, Porphyromonas gingivalis on the pathogenesis of non-alcoholic fatty liver disease. *BMC Gastroenterol* 2012;12:16.
- Ford PJ, Gemmel E, Hamlet SM *et al.* Cross-reactivity of GroEL antibodies with human heat shock protein 60 and quantification of pathogens in arteriosclerosis. *Oral Microbiol Immunol* 2005;20:296-302.
- Deshpande RG, Khan MB, Genco CA. Invasion of aortic and heart endothelial cells by Porphyromonas gingivalis. *Infect Immun* 1998;66:5337-5343.
- Franeck E, Blach A, Witula A, *et al.* Association between chronic periodontal disease and left ventricular hypertrophy in kidney transplant recipients. *Transplantation* 2005;80:3-5.
- Amar S, Gokce N, Morgan S, *et al.* Periodontal disease is associated with brachial artery endothelial dysfunction and systemic inflammation. *Arterioscler Thromb Vasc Biol* 2003;23:1245-1249.
- Tonetti MS, D'Aiuto F, Nibali L, *et al.* Treatment of periodontitis and endothelial function. *N Engl J Med* 2007;356:911-920.
- Polla BS. A role for heat shock proteins in inflammation? *Immunol Today* 1988;9:134-137.
- Wick G, Perschinka H, Xu Q. Autoimmunity and atherosclerosis. *Am Heart J* 1999;138:444-449.
- Ando T, Kato T, Ishihara K, *et al.* Heat shock proteins in the human periodontal disease process. *Microbiol Immunol* 1995;39:321-327.



# Fillings, crowns, and implants



■ **Nicolas Girard, DVM, Dipl. EVDC**  
Centre VetDentis, Saint-Laurent-du-Var, France

Dr. Girard graduated from the National Veterinary School of Toulouse in 1987. After a decade working in first opinion small animal practice, he commenced a residency in dentistry accredited by the European College of Veterinary Dentistry and attained the EVDC diploma in 2006. Dr. Girard is president of the French Veterinary Odontostomatology Study Group (GEROS) and a member of the European Veterinary Dental Society (EVDS). He currently works in his own referral practice specializing exclusively in veterinary stomatology and dentistry.

## ■ Introduction

Damaged teeth are common but often go unnoticed, or the consequences are ignored or at best underestimated. Damage is usually traumatic and is most commonly seen following excessive tug-of-war games with abrasive or breakable toys. The importance of a thorough medical examination that includes assessment of the oral cavity, combined with a good under-

standing of the potential consequences of dental trauma, cannot be over-emphasized. Advances in dental treatments have enabled easier access to modern surgical techniques to preserve, strengthen, or replace damaged or missing teeth. The practitioner should be familiar with these options, be capable of making an accurate diagnosis, and be able to formulate a therapeutic plan.

## KEY POINTS

- Dental trauma is synonymous with facial pain, but the latter is often underestimated; treatment should be implemented as early as possible.
- Root canal treatment is generally satisfactory, although the period between injury and treatment is an important prognostic factor.
- Intra-oral radiography is the preferred diagnostic test, allowing accurate assessment of a lesion and enabling each step of the therapeutic process to be monitored. Long-term radiographic follow-up is always recommended.
- The advantages of dental prostheses are often underestimated, but they must always be used appropriately and only after effective endodontal and periodontal treatment.
- When considering use of an implant, careful evaluation of the mechanical forces in play is essential.

## ■ Clinical indications for endodontic treatment

The most obvious clinical sign, and the most important for both practitioner and patient, is pain. This is always present with dental trauma, but often goes unnoticed by the owner and requires good observation of the animal or careful history taking (**Table 1**). The dental pulp, composed of connective tissue, blood vessels, lymphatics and nerves, extends continuously from the tooth into the periapical periodontal space via the root apex. Pain is therefore experienced when mechanical or thermal stimuli cause inflammation of the dental pulp, and the sensation is increased when the periapical periodontium is compressed by biting and as inflammation develops through the acute and chronic phases. The owner becomes accustomed to the animal's condition and lacks knowledge about the expression of pain, thus delaying detection. Broken teeth also provide an ideal site for bacterial colonization; infection develops instantaneously in the pulp canal, but it takes several days for the local signs (periapical periodontitis) to become apparent (1). Since the tooth is a closed system, despite the persistence of periapical inflammation, disease development depends on host factors

(periapical environment, age, general immune status) and may present as an acute disease (abscess, fistula, suppurative inflammation) or chronic inflammation (granuloma, cyst) (**Figure 1**). Irreversible periapical inflammation can also occur after trauma that causes contusion rather than fracture. These lesions are common in small breeds and can cause severe damage if they are left untreated.

**■ Clinical indications for a dental prosthesis**

Functional deficits, such as malocclusion resulting from a broken crown, are often regarded as the deciding factor for treatment. The owner, convinced that restoring tooth height will re-establish a correct bite, generally underestimates the pain resulting from periapical inflammation. In other situations it is the clinician who advises a prosthesis, with the aim of strengthening the devitalized tooth. The prime objectives of any prosthesis are to provide better protection against mechanical wear, future damage, and potential bacterial contamination of the pulp canal.

Recent advances in dental restoration resins have led to varying opinions as to the best approach to broken teeth. Some clinicians argue that periodontal management, root canal treatment and appropriate restoration of the dental access is sufficient to re-establish good function, irrespective of the height of the remaining crown. As a restored tooth is never as strong as the original, the owner/handler must be made aware that a deficient crown has limitations as to its function, and that it is necessary to minimize shocks and avoid

**Table 1. Dental traumas and possible causes.**

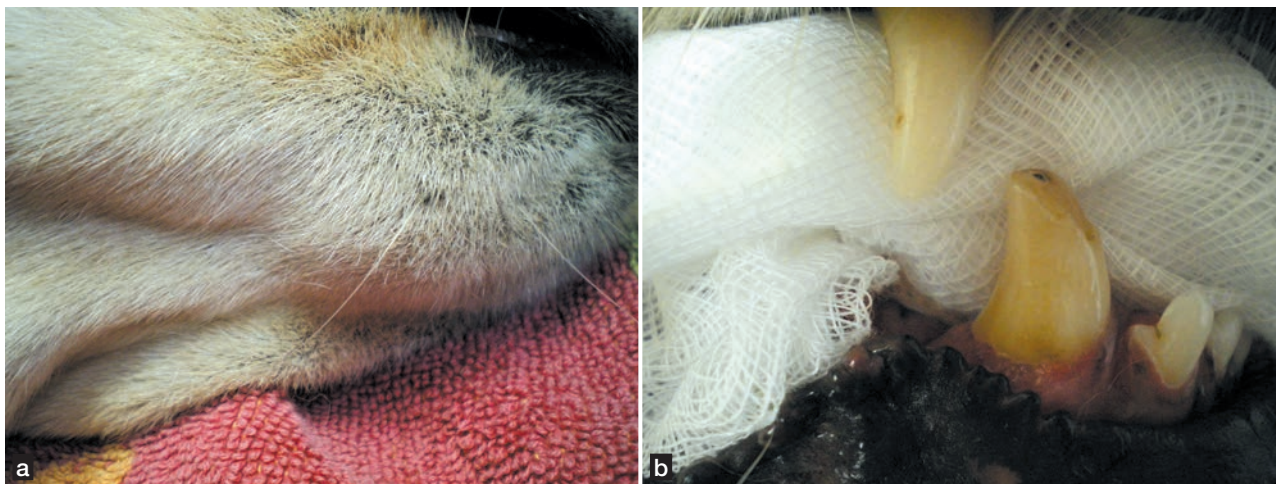
Dental fracture	Road traffic accident, fall, jaw fracture (simple, <i>i.e.</i> without exposure of the dental pulp, <i>vs.</i> complicated, <i>i.e.</i> with exposure of the dental pulp).
Dental abrasion	Metal bar, tennis ball, premature wear against an object (simple <i>vs.</i> complicated).
Dental attrition	Dental malocclusion, premature wear against another tooth (simple <i>vs.</i> complicated).
Dental luxation	Road traffic accident, fall, jaw fracture/contusion (no dental displacement); lateral luxation (moderate displacement without rupture of the dental vasculature); avulsion (displacement and rupture of the dental vasculature).

excessive biting forces by appropriate training. For other clinicians, human studies point to the advantages of dental prostheses, notably by improving mechanical strength and protecting the devitalized tooth from fluids gaining access by microleakage (**Figure 2**) (2). However no veterinary studies have yet been undertaken to support or refute either approach, leaving the practitioner to make the decision, taking into account the animal's well-being and the efficacy of the prosthesis.

Functional defects are always accompanied by an esthetic defect, but the latter is rarely taken into consid-

**Figure 1.** Disease resulting from tooth damage can take a variety of forms.

- a.** Diffuse osteomyelitis, intra-oral fistula and inflammation on the chin of a Labrador associated with dental trauma.
- b.** On opening the mouth a complicated fracture of the lower canine tooth is visible.



© Nicolas Girard

eration, in that direct restoration (*i.e.* restoring the defect in a one-step procedure) is performed without attempting to re-establish the original height, or indirect restoration is achieved via a metal (rather than ceramic) dental crown, as appearance is rarely an issue. Occasionally (*e.g.* with show dogs) owners request a ceramic crown to restore the original appearance of the tooth, but given the relative fragility of such prostheses, such requests should be very carefully assessed by the practitioner (**Figure 3**).

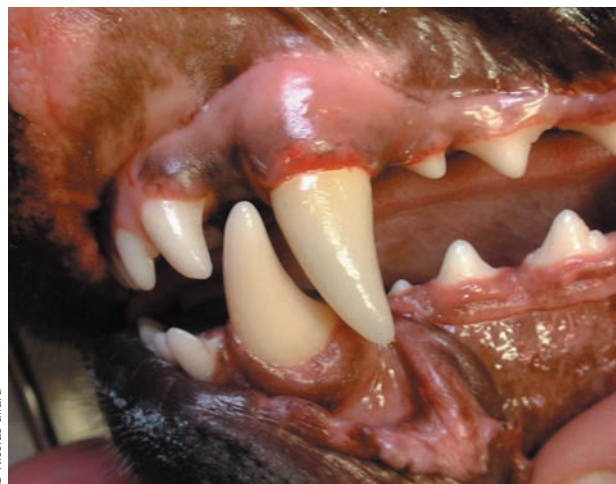Human advances in implantology to resolve periodontal problems have naturally led some to attempt these techniques on animals. The advantages and disadvantages should be carefully discussed with the owner and should include advice on the limitations and prognosis associated with such treatments. There are of course fundamental distinctions between veterinary and human indications (*e.g.* dental agenesis, dental avulsion, and dental extraction) to be considered (3).

### ■ Patient and tooth assessment

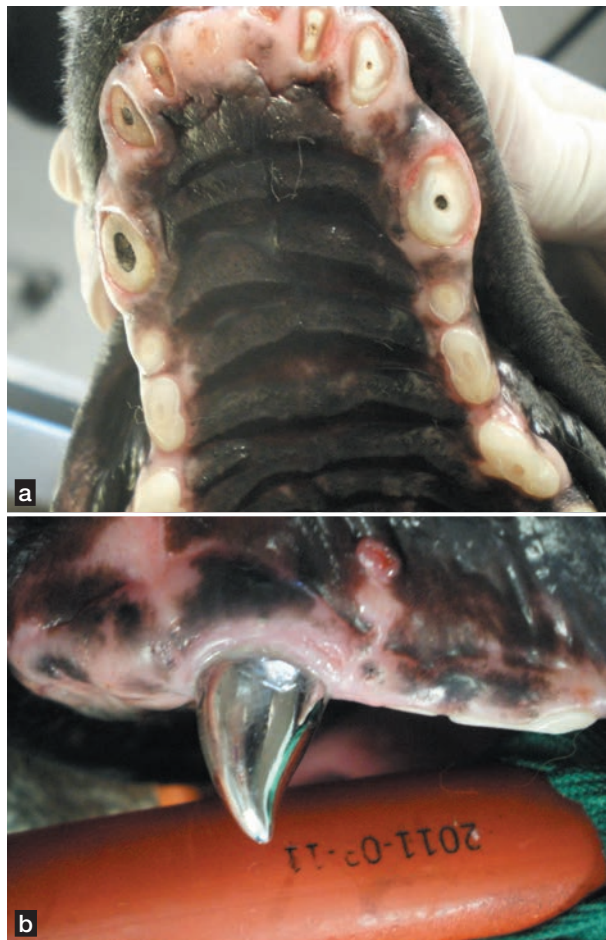The dental examination must always be preceded by a full clinical examination and a neurological examination where necessary. Particular attention should be paid to the temporomandibular joints, the bony maxillofacial structures, and the oral mucosa. The examination of a damaged tooth starts with the animal conscious but is completed under general anesthetic. During the conscious examination note the following;

- Any difference in color of all or part of the dental crown (4) (**Figure 4**).

**Figure 3.** A ceramic dental crown fitted to the left maxillary canine of a boxer after appropriate endodontic treatment.



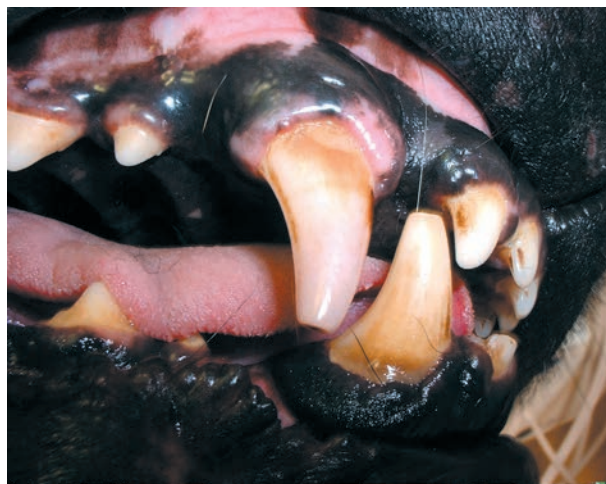© Nicolas Girard



© Nicolas Girard

**Figure 2.** A dental prosthesis may be indicated in a number of situations.  
**a.** Severe dental abrasion on a Belgian Malinois.  
**b.** A molded metal dental prosthesis fitted after endodontic treatment and periodontal surgery to elongate the crown (note the surrounding periodontal area has no inflammation).

**Figure 4.** Discoloration and abrasion of the left maxillary canine tooth indicative of pulp necrosis.



© Nicolas Girard

**Table 2. Assessment and treatment for dental trauma.**

Degree of pulpitis	Delay in treating	Degree of periapical periodontitis	Treatment
Reversible pulpitis	0-2 days	Absent	Partial pulpectomy or root canal treatment
Irreversible pulpitis	2-7 days	Absent	One-session root canal treatment
Pulp necrosis	Delay > 15 days	Moderate	One-session root canal treatment
Pulp necrosis	Delay > 15 days	Severe (osteomyelitis, pain, inflammation)	Two-session root canal treatment

- The structural integrity of the crown
- Any reaction when the tooth is percussed
- The dental occlusion

The simplest and most useful technique is scanning the surface of the tooth using a probe. This will immediately identify any opening to the pulp cavity; if present, an opening has a considerable bearing on possible complications and therapeutic options.

Under anesthesia the following are essential;

- Assessment of the periodontal integrity (using a probe to estimate any subgingival extension of the fracture).
- Intra-oral radiography to assess the dental canal: root wall ratio, and to check for any periapical inflammation.

The treatment protocol and prognosis must be clearly explained to the owner. A precise clinical diagnosis is essential, and the final choice of endodontic treatment and/or restoration with a dental prosthesis must consider;

- The medical status of the patient (*i.e.* age, history, cardiovascular and metabolic status).
- The dental occlusion and what the mechanical forces are likely to be.
- The state of the periodontal tissue (checking for periodontal disease and assessing if restorative surgery is feasible).
- If orodental hygiene is satisfactory.
- Appropriate endodontic treatment (**Table 2**).
- Dental radiography (to look for periapical lesions, ankylosis or root resorption).
- Use of dental models that accurately reproduce the mandibular and maxillary dental arcades.

**Materials, techniques, and after-care**

Endodontic treatments vary depending on the time since the pulp trauma. Treatment of a live tooth must be undertaken at a maximum of 48 hours post-trauma. Recent studies combining imaging and periapical histology after infection of the root canal confirm the speed of onset of periapical inflammation (1).

Partial pulpotomy and pulp capping is performed under aseptic surgical conditions, *i.e.* sterile instruments, disinfection of the oral cavity and the dental surface to be treated, and the use of a sterile dental dam. The key to effective treatment lies in the quality of the restoration and especially the control of any leakage. The infected coronal pulp is removed using a dental burr that is slightly larger than the diameter of the dental canal. After controlling the hemorrhage, the pulp is capped using a dressing (calcium hydroxide or a hydroxyapatite mixture) that promotes healing. Localized aseptic necrosis develops on contact with the pulp, with the formation of a dentine scar or bridge; this can be confirmed via radiography, but the bridge in itself is not a hermetic barrier against fluids, and the key to effective treatment lies in the quality of the restoration, especially how watertight it is.

Good knowledge of the qualities and limitations of the various dental materials is important and facilitates handling and implementation. For restoration, the physical and mechanical protection of the pulp cap is essential. A sandwich technique is employed, using a base composed of a glass-ionomer cement (selected on the basis of good resilience and impermeability to leakage) which will protect the pulp cap and support the restoration. The crown opening is then restored using a composite resin chosen for its mechanical resistance and esthetic properties.

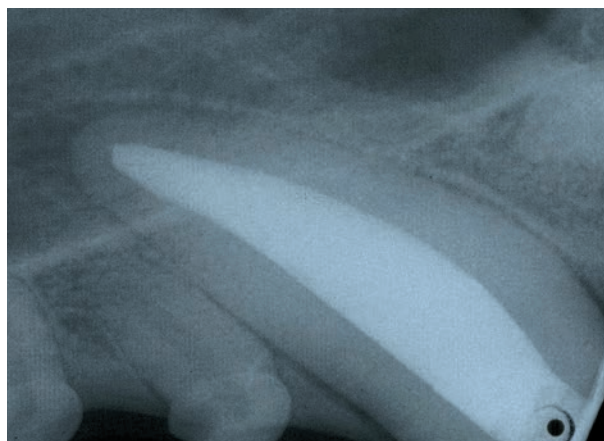
Treatment of contaminated dental pulp within 48 hours of trauma has a success rate of 88% (5). However, if pulp infection is treated between 48 hours and 7 days after the insult the success rate drops to 41%, and infections older than 1-3 weeks have a satisfactory prognosis of only 23%. These results from a veterinary study concur with human recommendations for which the best chance of therapeutic success (95%) is with reversible pulpitis treated within 24 hours (6).

Root canal treatment is the treatment of choice for pulp trauma older than 48 hours. This involves the complete elimination of the pulp and mechanical debridement of the walls of the dental canal, which is then disinfected (chemical debridement) and totally filled before the coronal access is restored. Surgical techniques vary, essentially differing by the method used to fill the canal. Methods to disinfect and shape the dental canal vary little but these steps are essential for effective treatment. When preparing the canal, shaping it enables more effective use of the instruments and allows the irrigation fluid to circulate more easily; if the canal is properly opened the fluid can reach the finest branches of the pulp system, which will optimize disinfection. Elimination of the pulp is certainly important, but complete mechanical debridement followed by chemical debridement of the dentine walls is essential to disinfect the root canal. The canal should be tapered, ideally approximately 10% (*i.e.* by 0.1 mm every 1 mm) (7,8). This is especially important at the apical third of the root. A three-dimensional filling of the canal is employed to prevent bacterial recolonization. Cement is essential when filling the canal with gutta-percha; applied as an ultrathin layer, it ensures that the gutta percha fills the dental canal perfectly to provide a watertight barrier against bacteria (**Figure 5**).

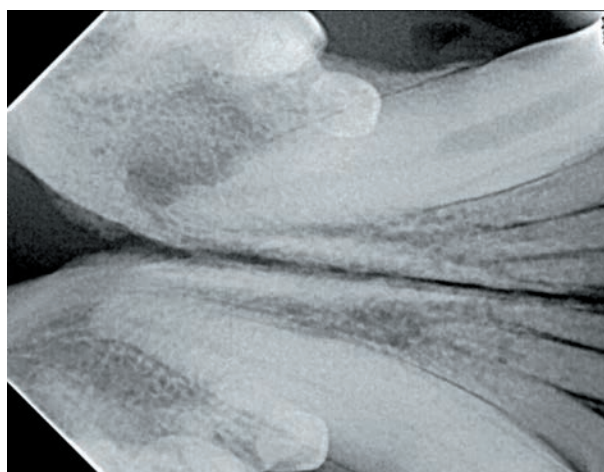
Success rates for endodontic treatment have rarely been studied in veterinary dentistry. However it is important to stress two major differences compared to human dentistry:

- Treatment is often instigated long after the initial insult and the periapical periodontitis is well advanced.
- The canal anatomy is complex and a canal may be as long as 40-42 mm, making effective mechanical and chemical debridement difficult.

One retrospective study noted that treatment for irreversible pulpitis offers a clinical and radiographic success rate of ~ 85%, but if pulp necrosis has developed, the success rate drops to ~45% (9). However, if one only considers animals with no clinical signs (pain,

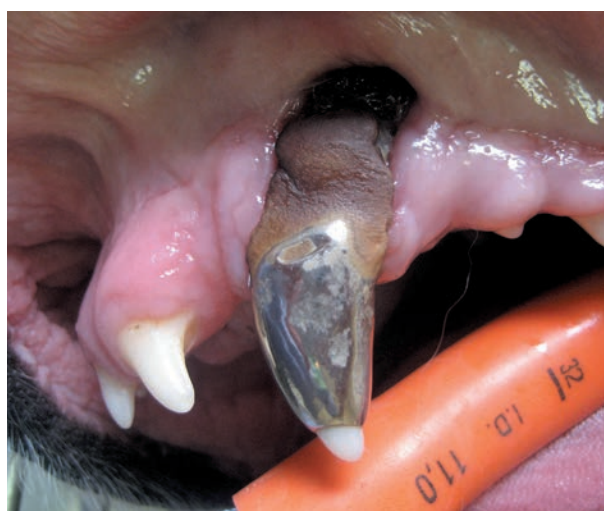

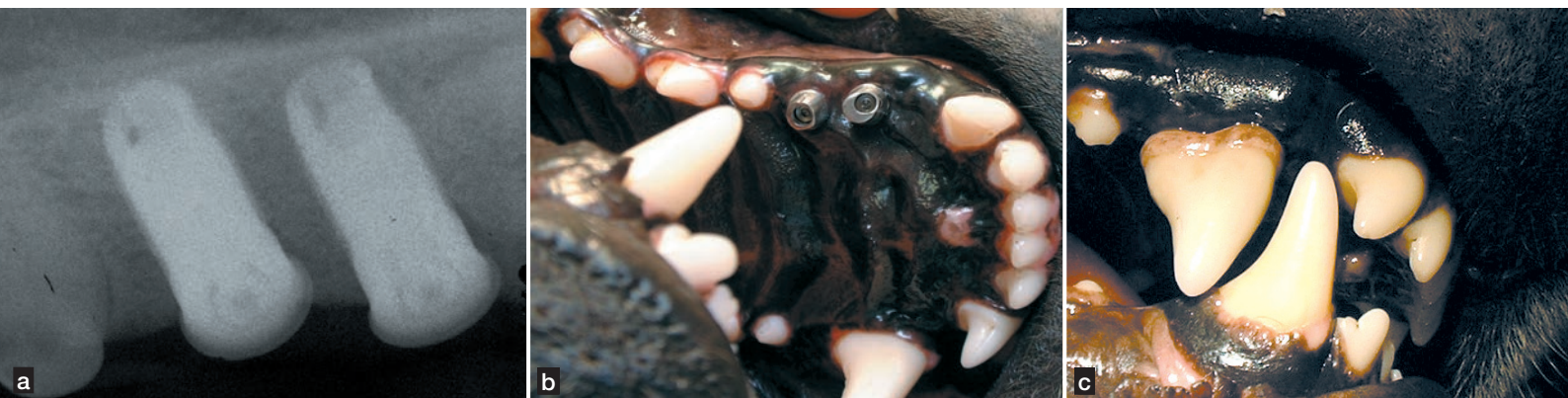**Figure 5.** Radiograph showing the final filling.



**Figure 6.** Diffuse periapical osteomyelitis of the mandibular canine tooth; this will require a two-session root canal treatment.

**Figure 7.** Major prosthesis failure due to a lack of understanding and failure to master the essential rules of endodontic/periodontal treatment and dental restoration.





**Figure 8.** A periodontal implant and prosthesis in a dog.  
**a.** Radiograph showing good osseointegration of two implants in the alveolar bone at the level of the right maxillary canine of a large breed dog following avulsion of the tooth.  
**b.** Two suprastructures are screwed into the implants and used to support the prosthesis.  
**c.** The final ceramic dental crown supported by the two implants.

inflammation) and no radiographic signs of aggravation, the overall success rates of root canal treatment are close to those reported for human dentistry at around 96% (9). These results may explain why opinions vary between practitioners, but should also alert clinicians to a probable underestimation of the chronic pain experienced by treated animals. It is therefore important to recommend an additional disinfection step if there is established periapical periodontitis, even though this means a second general anesthetic (**Figure 6**). To achieve this, calcium hydroxide is applied to the dental canal at the end of the canal preparation phase. It is protected from external contamination by a temporary hard filling material which is left *in situ* for 15 days; definitive filling of the canal is then performed as a second procedure, thus allowing greater healing of the periapical periodontitis. The advantage of this two-session treatment was highlighted by a prospective study using 2D and 3D dental imagery and histology (10). The disadvantages of an additional general anesthetic should be assessed against parameters such as pain, status of the pulp inflammation (pulpitis vs. pulp necrosis) and the degree of periapical inflammation (11).

### ■ Indirect dental restoration

Indirect restorations involve several surgical procedures, and the choice between the different possible restorations should consider the extent of the tooth damage, the mechanical stress that will be supported by the restored tooth, and the need to control dental plaque, as well as financial and esthetic aspects.

Ideally a crown will have both excellent retention and optimal mechanical resistance. The quality of the retention of the restoration is directly related to the percentage of a tooth's surface area covered by the prosthesis, and a full crown, *i.e.* one that completely covers a damaged tooth, is thus largely preferred in veterinary dentistry. A molded metal prosthesis strengthens the damaged tooth by spreading occlusal forces over a large surface area, and by eliminating forces directed onto the actual site of the fracture. It is important to ensure that the crown itself does not weaken the tooth (12). To achieve this one must consider the five main principles of dental preparation prior to crown placement;

- Preservation of the tooth structure
- Retention and resistance of the crown
- Durability of the crown
- Integrity of the crown margins
- Respect for the underlying periodontal tissues

The tooth is prepared during an initial general anesthetic. The axial surfaces must be reduced using a conical diamond burr to allow retention of the molded crown; the amount of enamel removed should be minimal (0.5 mm depth) and it is desirable to attain an optimal angle of reduction of 6° (12). This is not easy; a study of preparation angles performed by human dental students showed that the ability to achieve this theoretically ideal angle varied markedly (13). The retention of the dental prosthesis is a result of micromechanical and chemical bonding, and it is recognized that whilst a significant part of crown retention is related to the qual-

ity of the adhesion of the dental resin, a minimal reduction angle is also fundamental for effective retention (13). Poor preparation is the primary cause of crown dehiscence. The quality of the shape of the margin at the base of the crown, the optional use of an intra-canal retention post, and the final supragingival prosthetic coverage (which should remain above the gum line) are all essential parameters that the clinician must master.

A silicon impression made during surgery is sent to a specialist laboratory which prepares the dental crown using a metal alloy (nickel-cobalt or cobalt-chromium); this offers good resistance to mechanical forces. During a second anesthetic the crown is positioned, adjusted if necessary, and finally sealed with a suitable liquid resin. Treatment is deemed a failure if the tooth fractures under the crown or the crown becomes detached; mid-term therapeutic success (3 years post-procedure) is assessed to be ~80% (13), and it would appear that the failure rate is directly related to residual tooth height, *i.e.* the lower the crown, the poorer the retention (**Figure 7**).

## ■ Conclusion

The use of dental prostheses in veterinary medicine need to be carefully considered. The esthetic appearance is rarely the primary consideration; protecting the pulp and ensuring a pain-free tooth are paramount, and any prosthesis must always be used appropriately and only after effective endodontic and periodontal treatment. Finally it may be worthwhile noting that the ethics and practicalities of replacing a missing tooth should always be fully discussed with the owner. The four possible restorative techniques (a removable prosthesis, a removable or fixed partial denture or bridge, or a prosthesis supported by a periodontal implant (**Figure 8**)) all carry risks; the mechanical forces exerted by a dog, as well as the difficulties associated with ensuring satisfactory behavioral control, make such treatments problematic and must be clearly explained to the owner before proceeding.

## References

1. Tanumaru-Filho M, Jorge EG, Duarte MA, *et al.* Comparative radiographic and histological analyses of periapical lesion development. *Oral Surg Oral Med Oral Pathol Oral Radiol Endo* 2009;107(3):442-447.
2. Coffman CR, Visser L. Crown restoration of the endotically treated tooth: literature review. *J Vet Dent* 2007;24(1):9-12.
3. Ruhanau J, Olsen T, Greven V, *et al.* Dental implant of the mandibular first molar tooth in a dog. *J Vet Dent* 2003;20(2):84-90.
4. Hale FA. Localized intrinsic staining of teeth due to pulpitis and pulp necrosis in dogs. *J Vet Dent* 2001;18(1):14-20.
5. Clarke DE. Vital pulp therapy for complicated crown fracture of permanent canine teeth in dogs: a three-year retrospective study. *J Vet Dent* 2001;18: 117-21.
6. Trope M, Chivian N, Sigursson A, *et al.* Traumatic injuries. In: Cohen S, Burns RC eds. *Pathways of the pulp*. St Louis: CV Mosby; 2002:603-49.
7. Macthou P. Irrigation investigation in endodontics. Master's thesis, Paris, 1980 Paris 7.
8. Ruddle CJ. Cleaning and shaping the root canal system. In: Cohen S, Burns RC eds. *Pathways of the pulp*. St Louis: CV Mosby; 2002:231-91.
9. Kuntsi-Vaattovaara HK, Verstraete FJM, Kass P. Results of root canal treatment in dogs: 127 cases (1995-2000). *J Am Vet Med Assoc* 2002;220(6):775-9.
10. Garcia de Paula-Silva FW, Santamaria M Jr, Leonardo MR. Cone beam computerized tomography, radiographic, and histological evaluation of periapical repair in dogs post endodontic treatment. *Oral Surg Oral Med Oral Pathol Oral Radiol Endod* 2009;108:796-805.
11. Gesi A, Hakeberg M, Warfvinge J, *et al.* Incidence of periapical lesion and clinical symptoms after pulpectomy: a clinical and radiologic evaluation of 1-versus 2-session treatment. *Oral Surg Oral Med Oral Pathol Oral Radiol Endod* 2006;101:379-388.
12. Schilinburg HT, Hobo S, Whitsett LD, *et al.* Principles of tooth preparation. In: Shilinburg HT, Hobo S, Whitsett LD, *et al.* eds. *Fundamentals of fixed prosthodontics*. 3<sup>rd</sup> ed. Chicago: Quintessence; 1997:119-137.
13. Soukup JW, Snyder CJ, Karls TN, *et al.* Achievable convergence angles and the effect of preparation design on the clinical outcome of full veneer crowns in dogs. *J Vet Dent* 2011;28(2):78-82.

# Veterinary dental radiology – an overview



■ **Michael Bailey, DVM, Dipl. ACVR**  
Banfield Pet Hospital, Portland, Oregon, USA

Dr. Bailey is a 1982 graduate of the Tuskegee University School of Veterinary Medicine in Alabama. After completing a radiology residency at Michigan State University he remained there as an assistant professor of Veterinary Radiology before moving to The Ohio State University, where he pioneered veterinary radiologic telemedicine. Leaving academia, Dr. Bailey opened the first veterinary CT imaging center in Ohio, offering ultrasound, radiological and endoscopy services for the private practitioner. He is now head radiologist for Banfield Pet Hospital. Dr. Bailey has presented at numerous international veterinary and human meetings on radiographic and ultrasound imaging and medical informatics, and has published over 30 articles on these subjects.

## ■ Introduction

Dental care is necessary to promote optimal health and quality of life (1,2), but the most visible part of the tooth, the crown, is only a small portion of the dental anatomy, with the majority of dental morphology and potential disease situated - and therefore hidden - sub-gingivally.

Early detection of disease has been shown to simplify treatment, improve overall patient outcomes for common diseases (3,4) and prevent the need for more expensive, invasive care resulting from missed diagnoses

or late-stage oral health issues and associated systemic disease (5,6). Dental radiography is therefore an essential tool for both the diagnosis and treatment of dental disease and to maintain whole body health. Radiology can also demonstrate disease to the client, encouraging an understanding for the need of an appropriate treatment plan.

To be a valuable tool dental radiology depends on optimal image quality obtained by good technique, *i.e.* proper exposure and positioning. Understanding the geometric influences of the X-ray beam will ensure the best possible results, and following basic radiographic principles will reduce health risks as far as possible.

## KEY POINTS

- **Dental radiography is an essential tool for the diagnosis and treatment of both dental disease and whole body health.**
- **Radiation doses are low in dental radiography but no exposure can be considered risk free; by following basic guidelines the risk can be minimized.**
- **Digital dental radiography is now widely available and offers many advantages to the clinician.**
- **Technical errors can occur at any stage in dental radiology and can be due to various factors; good technique should minimize errors.**

## ■ Radiation safety

Although radiation doses to the patient and workers are low in dental radiography (7,8), no exposure can be considered risk-free; the principle of As Low As Reasonably Achievable (ALARA) should always be followed to minimize unnecessary radiation exposure to personnel, patient, and the general public (9). The three guiding principles of ALARA, Distance, Shielding and Time, are easy to remember. Utilize distance wherever practical by maximizing the distance from any X-ray source; an operator must stand at least 6 feet (2 meters) from a useful beam that is angled away from personnel. The inverse square law applies; a person 6 feet from a primary beam will receive ~75% less radiation than someone standing 3 feet from the beam (10). The direct primary beam should never be directed towards an entrance or other non-protected areas and no-one should ever stand in the path of the



beam. If the benefit of distance is not achievable then shielding, such as approved barriers or personal protective devices (e.g. aprons) should be employed. Time should always be a consideration; personnel should strive to minimize time spent near an X-ray source by using the shortest exposure possible, obtaining the fewest images needed for diagnosis, processing film using optimized time-temperature methods, using high speed X-ray film or digital radiology, and optimizing X-ray technique (9,10). It is generally agreed that settings greater than 60 kVp are the optimal operating potential for intraoral imaging, maintaining image contrast while reducing radiation absorption by soft tissue and bone (9,10).

The type of image receptor used has a direct effect on the radiation exposure required. Film-based imaging still predominates in veterinary medicine and there are currently three speeds of intraoral films available for dental radiology, D, E and F speed. Many clinicians use the slower D speed films because of its perceived greater contrast resolution. The original E-speed films reduced the amount of radiation required by ~50%; however these produced a lower contrast image, were sensitive to age and depleted processing solutions, and lost their high speed advantage at higher densities (11). Subsequent E-speed emulsions have improved (11,12) and the newer F group films offer dose reductions of 20-25% compared with even E-speed film (12,13). Recent studies have demonstrated that there is no loss of diagnostic image quality with faster speed films, which can allow up to 80% decrease in exposure factors (12,13).

The recent move to digital dental radiology has had a significant benefit of reducing radiation exposure by 50-80% while achieving an image comparable to dental film systems (14).

### ■ General X-ray generators

General radiographic systems can be used for dental radiology but are not very convenient (**Figure 1**). Using D-speed intraoral films with a standard X-ray generator, the operator should reduce the film-collimator distance to 12-16 inches (30-40 cm), collimate to the film size, employ the smallest focal spot (if available), and select 60-85 kVp at 100 mA and an exposure time of 1/10<sup>th</sup> sec (=10 mAs) dependent on patient size; the film should be exposed and processed using an approved method. As with standard radiographs, a technique chart should be developed to allow repeatability of first-time images. If the dental radiograph is underexposed but shows adequate penetration, double the mAs by doubling time. If the image is over-exposed, halve the mAs by

halving the time. If penetration is inadequate, increase the kVp by 15% which will double the radiographic density; conversely, reducing the kVp by 15% reduces density. Remember contrast is inversely proportional to kVp, so a decreased kVp will give more contrast whilst reduced contrast is achieved with an increased kVp. Because of a resulting change in radiographic density a concurrent inverse doubling or halving of the mAs setting is required to maintain density.

### ■ Dental X-ray generators

Dedicated dental radiography units are relatively inexpensive, low maintenance and allow for accurate image positioning with minimum patient manipulation. They are compact, maneuverable, have user-friendly controls and limit the amount of radiation scatter. The kVp and mA are often preset, or the settings are limited to those appropriate for dental anatomy.

Until relatively recently, most dental X-ray generators were half-wave self rectified units and applied alternating current (AC) to the tube when generating X-rays. With an AC generator, voltage across the tube produces a sinusoidal power output, generating X-ray photons with a wide range of energies. Low energy (non-useful) photons are removed by filtration; the average, useful, photon energy released by an AC tube for a given kVp is only 33% of the peak photon energy selected. A consequence or benefit of this is that high contrast images are obtained.

**Figure 1.** A general X-ray generator can be used for dental work but manipulating the machine to achieve satisfactory image angles can be difficult.



© Michael Bailey



© Michael Bailey

**Figure 2.** Dental generators with different PID lengths; the dental unit with a longer PID will produce a higher quality image but will require more power to generate X-ray photons.

New dental X-ray generators apply a near-constant electrical potential to the tube and are often referred to as direct current (DC), constant potential or digital generators. These produce a relatively constant stream of useful high energy photons; this higher energy output means that a DC generated image has inherently lower contrast compared to an AC generator but the actual exposure (photons arriving at the image receptor) will be higher and tissue absorption lower (15,16).

Although both AC and DC generators provide satisfactory exposures the latter are more consistent. All dental X-ray units, regardless of the generator type, use a Position Indicating Device (PID) (or cone) (**Figure 2**) attached to the front of the collimator. Typically the PID length will be 4, 6, 8, 12 or 16 inches. The short 4 inch cones require the least amount of radiation to be produced by the generator, and are therefore often found

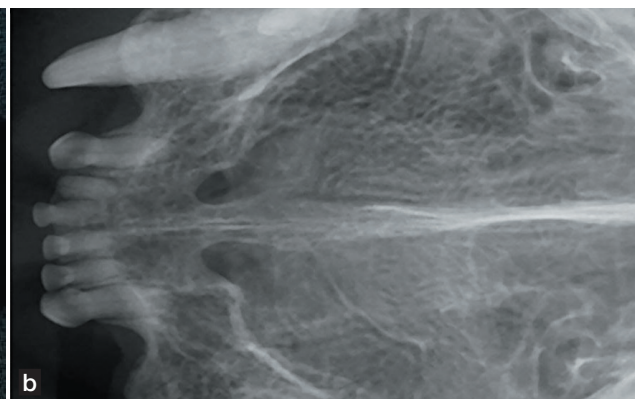
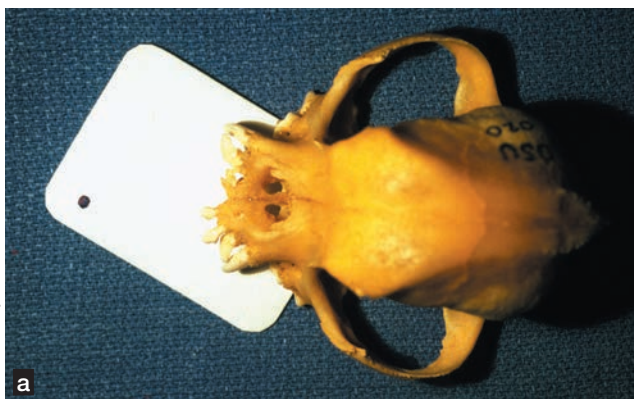on low power units, but they result in more scatter radiation and hence less image contrast and more patient exposure, as well as loss of image detail. A longer cone gives improved image quality with better detail, superior contrast (due to reduced scatter) and lower patient exposure. A trade-off exists between the choice of PID and the required exposure factors; the inverse square law means that if the PID length is doubled (e.g. from 4 inches to 8 inches) only 25% of the generated photons arrive at the image receptor. To ensure the image density remains the same for both PIDs it is necessary to increase the radiation generated by a factor of 4 when doubling the PID distance and if the distance is tripled (from 4 to 12 inches PID) the radiation generated must be increased by a factor of 9 to maintain the same density. There is a significant diagnostic benefit to an increased PID length which results in enhanced image quality by decreasing edge distortion known as penumbra (15,16).

Dental films come in five sizes (0, 1, 2, 3, and 4) with the most common sizes being 2 & 4. Size 4 is an occlusal film and as the largest size available can only be used in large breed dogs or for whole mouth or nasal radiographs in cats or small dogs (**Figure 3a and b**). For smaller dogs and cats a single root radiograph is most commonly obtained with a size 2 film. Dental film has a bubble on the upper left hand corner; the convex surface of the bubble should always be placed towards the X-ray beam source. Note that a dental film pack has multiple layers that include a white plastic outer layer, front and back paper layers, the film, and a silver lead foil layer; the foil can be an environmental contaminant, and for health reasons caution should be taken when handling it during radiograph processing (17).

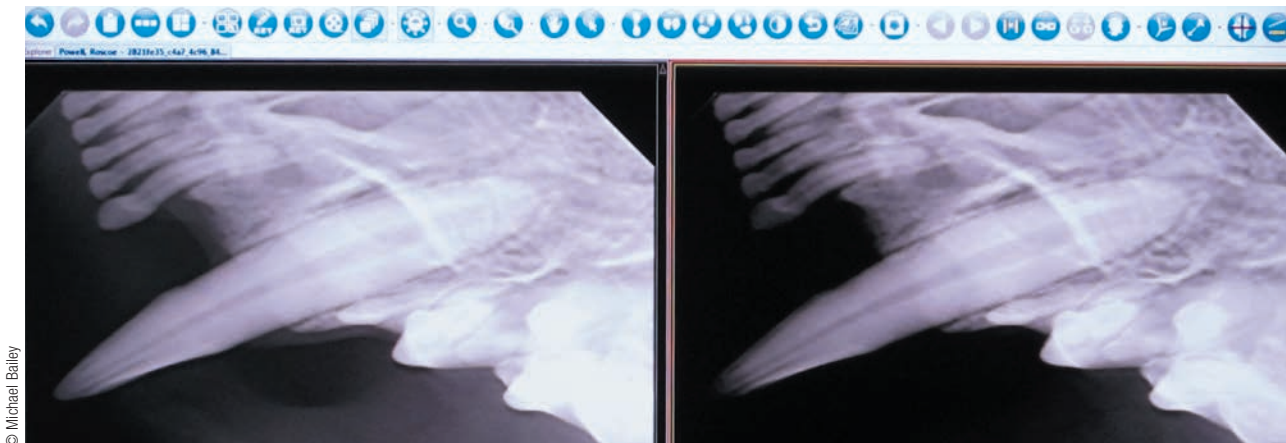
### ■ Processing

Film processing procedures can affect the quality of the

**Figure 3.** Size 4 dental films may be used for high detail nasal radiographs.



© Michael Bailey



**Figure 4.** Computer software offers the ability to manipulate digital radiographs, as can be seen here with differing contrasts of the same radiograph.

radiographic image. Poor processing can severely compromise the diagnostic quality and may result in increased radiation exposure for both patient and personnel. Chair-side processing is an easy and inexpensive dip-tank method that provides excellent, rapid results as long as fresh chemicals and a time/temperature chart (instead of the unreliable “by-sight method”) are used. The time/temperature compensation chart is a quick and easy guide for users to adjust temperature-dependent processing times to ensure proper and consistent development and fixing.

All solutions, including wash water, should be at the same temperature (within 5°C/10°F) to ensure proper processing. Films must be secured by holder clips to avoid fingerprints and to reduce chemical skin contact.

The use of automatic processors allows greater film consistency and is time-efficient. Dental film is too small to pass through a standard large-format processor unless a dental film carrier/transport system is employed, the transporter doubling as a permanent film mount. Small-format, dental X-ray specific automatic processors are available but they can be expensive and require a large throughput of films to be cost effective.

Note that if converting from D-speed to F-speed film the appropriate safelight filter is also required; F-speed films allow reduction of mAs (60% if using an automatic process or 50% if using manual tanks).

Technical errors can occur at any stage in dental radiology. This can be due to film placement, patient positioning, angle of the X-ray beam, exposure, processing,

storage or any combination of the above. **Table 1** addresses the most common problems encountered.

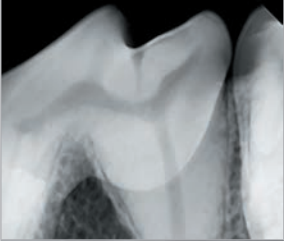
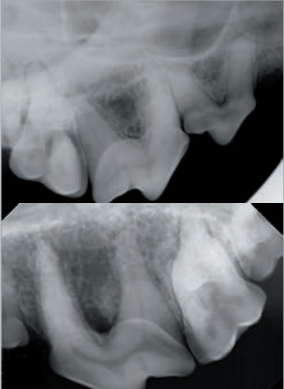
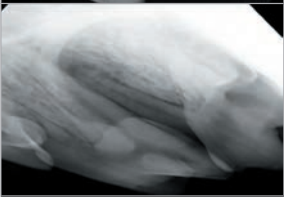

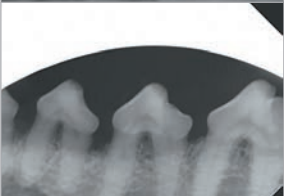

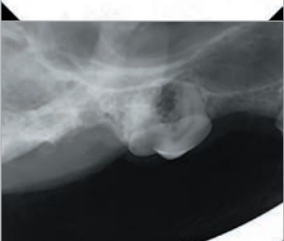
### ■ Digital dental radiology

Digital dental radiography is now widely available and comes in two forms: direct and indirect.

- Direct radiology (DR) systems employ solid-state sensors (14) that detect radiation and deliver an almost immediate radiographic image to the attached computer. However DR sensors are currently limited in size, equivalent to film sizes 1 and 2.
- Indirect systems, or computed radiology (CR), use photo-stimulable phosphor (PSP) plates that are exposed then digitally scanned by a laser processor and converted to an image on a computer; the image is then erased from the plate immediately after processing, leaving it ready for reuse. The advantage of this technology is that the size and thickness of the phosphor plates are almost identical to those of traditional film. However the intra-oral sensors may degrade if scratched, and the time needed to scan (and then erase) an exposed plate is longer than with a DR system.

Both forms give diagnostic results (14) but the DR system offers a limited size selection while CR systems, with their varying plate sizes, offer flexibility. Digital machines greatly reduce (by 50-80%) the exposure necessary compared to film systems, and the images can be electronically stored and manipulated as necessary for radiographic evaluation of dental disease (**Figure 4**).

**Table 1. Common errors in dental radiography.**

Error	Image	Description	Correction
<b>Inadequate coverage of area under investigation</b>		Improper or incomplete dental anatomy recorded.	Align X-ray beam to include all necessary anatomy; reposition film and PID.
<b>Foreshortening</b>		Image shortened/smaller than actual object length. Too much alveolar bone visible.	Adjust the vertical angulation of the X-ray beam; <ul style="list-style-type: none"> <li>• Film parallel to object.</li> <li>• Centralize beam at 90° to object.</li> </ul>
<b>Elongation</b>		Image stretched/longer than actual object; apices are elongated.	Correct film placement; adjust the vertical angulation of the PID; <ul style="list-style-type: none"> <li>• Film parallel to object.</li> <li>• Centralize beam at 90° to object.</li> </ul>
<b>Overlapping</b>		<ul style="list-style-type: none"> <li>• Surfaces of the teeth are closed together.</li> <li>• Teeth superimposed.</li> <li>• Bone crest around teeth difficult to see.</li> </ul>	Correct horizontal angle of PID: X-ray beam should be adjusted so that it is directed at 90° to area under investigation.
<b>Cone-cutting</b>		Unexposed zone where X-rays did not strike film/receptor.	Center the X-ray beam over the entire film/receptor.
<b>Underexposure</b>		Light or low density image.	Increase exposure by increasing mAs. A technique chart will reduce exposure errors.
<b>Image size distortion</b>		Distortion of size, uneven magnification	Eliminate cause of geometric distortion; <ul style="list-style-type: none"> <li>• Use longer cone</li> <li>• Film and object must be parallel</li> <li>• Centralize beam at 90° to object.</li> </ul>

Conventional film displays 16 shades of gray, which is a narrow range for diagnostic imaging. Digital dental radiographs, by comparison, offer up to 65,536 shades of gray and a digital image may be enhanced, correcting various parameters to produce a more diagnostic image and better visualization of disease. Studies have shown that altering contrast and brightness have the greatest effect on diagnostic accuracy (18) and a single image can be enhanced to reveal features or details of diagnostic importance without additional exposures. The pros and cons are summarized in **Table 2**.

### ■ DICOM and telemedicine

Film images can be read anywhere - assuming an adequate light source – and therefore have a universal utility. Digital radiology has come of age but hardware and software compatibility issues exist between different manufacturers; inter-operability of images across all manufactures is essential, and Digital Image Communication in Medicine (DICOM) is an international open standard for medical images created to promote this concept (19); whilst this standard has been adopted for medical radiography, not all dental systems are as yet compatible.

Telemedicine - delivering healthcare services via electronic means (20) - facilitates earlier and more accurate care not previously deliverable by accessing highly trained consultants at a distance, thus affording better diagnostic abilities. Digital imaging – assuming compatibility issues do not exist – makes the many benefits of telemedicine a reality for veterinary medicine, and also offers improved professional education and reduced costs with a more efficient and timely delivery of care (21).

### ■ Positioning of the dental radiograph image

There are two intra-oral radiograph techniques commonly utilized in veterinary dentistry. The simpler is the parallel technique; the oral anatomy means that its use is limited to the caudal mandible, but will visualize the molars and caudal premolars. The X-ray beam is set at an angle of 90° to the film, which is placed on the lingual surface of the teeth (22).

The alternative technique is the bisecting angle, which minimizes distortions of the teeth and is used for the rostral teeth, maxilla and mandible, and the caudal maxillary teeth. With this technique the beam is aimed at an imaginary line bisecting the plane of the tooth and the plane of the film (22).

A full radiographic survey will include 8 radiographs:

- occlusal view of the maxillary incisors.
- lateral view of the maxillary canine teeth.
- rostral maxilla-P1-P3-M2.
- caudal maxilla-P4-M2.
- occlusal view of the mandibular incisors and canine teeth.
- lateral view of the mandibular canine teeth.
- rostral mandible-P1-P4.
- caudal mandibular-P4-M3.

All but the last employ a bisecting angle technique, which requires a parallel technique. The upper fourth pre-

**Table 2. Digital dental radiography.**

ADVANTAGES
<ul style="list-style-type: none"> <li>• Immediate image production with solid-state devices.</li> <li>• Improved contrast resolution.</li> <li>• Ability to computer-enhance features.</li> <li>• Image can be duplicated and distributed as necessary (e.g. the patient file, referring veterinarian or telemedicine consultant).</li> <li>• Security mechanisms allow identification of original images and differentiation from altered images.</li> <li>• Easy storage and retrieval of the image, including integration with practice management software systems.</li> <li>• 50-80% reduction in radiation needed to expose an image.</li> <li>• Elimination of hazardous processing chemicals.</li> <li>• Reduced anesthetic time.</li> <li>• Thin, flexible plates which provide easy placement in confined spaces (CR systems).</li> <li>• DICOM compatibility allows practitioners with different equipment and software to share, view and enhance the same images.</li> </ul>
DISADVANTAGES
<ul style="list-style-type: none"> <li>• Sensors are initially expensive (although over time they are less expensive than film-based radiology).</li> <li>• DR sensors are currently limited in size.</li> <li>• System requires a computer in the dental area.</li> <li>• Extra time may be needed for input of computer data.</li> <li>• Lack of DICOM compatibility can be a problem.</li> </ul>

molar requires additional radiographs to permit adequate visualization of all three roots using the SLOB (Same Lingual Opposite Buccal) rule. The methodology of performing the above studies is covered in various publications (e.g. 22-24) to which the clinician is referred as necessary.

### ■ Dental radiography critique

Various organizations, including the American Veterinary Dental College and the Academy of Veterinary Dentistry, have established guidelines which, if followed, will produce meaningful diagnostic films. These are as follows:

- Exposure and developing technique are adequate.
- Contrast and density of the radiograph are correct.
- No artifacts appear on the film.
- Radiographs are well positioned.
- Proper angulation has been used: foreshortening or elongation should be avoided.
- All teeth to be evaluated are clearly visible and complete; there should be adequate visualization of all roots

and apices with at least 3 mm of periapical bone visible.

- Maxillary cheek teeth and incisors should have the roots facing upward and the crowns downward.
- Mandibular cheek teeth and incisors should have the crowns facing upward and the roots downward.
- When viewing the right side of the mouth, the rostral teeth are on the right side.
- When viewing the left side of the mouth, the rostral teeth are on the left side.

### ■ Conclusion

There is no doubt that dental radiology can be frustrating and is underutilized in veterinary medicine, yet good imaging is essential when investigating dental disease. Recent advances in dental films, better X-ray generator technology, and new digital dental radiology systems are all significant developments; with the correct equipment, and the ability to detect and eliminate common radiographic faults, the clinician should be able to obtain excellent images which will permit better diagnosis and treatment of patients.

## References

1. Harvey CE. Periodontal disease in dogs. Etiopathogenesis, prevalence, and significance. *Vet Clin North Am Small Animal Pract* 1998;28(5):1111-1128.
2. Lund EM, Armstrong PJ, Kirk CA, et al. Health status and population characteristics of dogs and cats examined at private veterinary practices in the United States. *J Am Vet Med Assoc* 1999;214(9):1336-1341.
3. Lommer MJ, Vertraete FJ. Prevalence of odontoclastic resorption lesions and periapical radiographic lucencies in cats: 265 cases (1995-1998). *J Am Vet Med Assoc* 2000;217(12):1866-1869.
4. DuPont GA. Radiographic evaluation and treatment of feline dental resorptive lesions. *Vet Clin North Am Small Anim Pract* 2005;943-962.
5. DeBowes LJ, Mosier D, Logan E, et al. Association of periodontal disease and histologic lesions in multiple organs from 45 dogs. *J Vet Dent* 1996;13(2):57-60.
6. Glickman LT, Glickman NW, Moore GE, et al. Evaluation of the risk of endocarditis and other cardiovascular events on the basis of the severity of periodontal disease in dogs. *J Am Vet Med Assoc* 2009;234(4):486-494.
7. Freeman JP, Brand JW. Radiation doses of commonly used dental radiographic surveys. *Oral Surg Oral Med Oral Pathol Oral Radio Endo* 1994;77(3):285-9.
8. Gibbs SJ, Pujol A Jr, Chen TS, et al. Patient risk from intra-oral dental radiography. *Dentomaxillofac Radiol* 1988;17(1):15-23.
9. National Council for Radiation Protection & Measurements. Radiation protection in dentistry. Bethesda, Md.: National Council for Radiation Protection & Measurements; 2003.
10. European Commission, Radiation Protection 136, European guidelines on radiation protection in dental radiology. The safe use of radiographs in dental practice. Directorate General for Energy and Transport, Directorate H- Unit H.4-radiation Protection 2004.
11. Horton PS, Francis H, Sippy FJ, et al. A clinical comparison of speed group D and E dental X-ray films. Original Research Article. *Oral Surg Oral Med Oral Pathol Oral Radio Endo* 1984;58(1):104-108.
12. White SC, Yoon DC. Comparison of sensitometric and diagnostic performance of two films. *Comp Cont Ed Dentistry* 2000;21:530-2,534,536 passim.
13. FDA, The Nationwide Evaluation of X-ray Trends (NEXT), Dental radiography: doses and film speed, 2009.
14. Mupparapu M. Digital dental radiography - a review of the solid-state and semi-direct digital detector. *Orofac J Sci* 2011;3(1):40.
15. USAF. Dental evaluation & consultation services. Synopsis of Intra-Oral X-ray Units (Project 05-02) (4/05).
16. Bellows J. Dental radiography. In: Bellows J, ed. *Small animal dental equipment, materials and techniques, a primer*. Oxford: Blackwell Publishing, 2004;63-103.
17. Suji LJS, Wainman BC, Ruwan K, et al. Foil backing used in intraoral radiographic dental film: a source of environmental lead. *J Can Dent Assoc* 2005;71(1):35-8.
18. Gormez O, Yilmaz HH. Image post-processing in dental practice. *Eur J Dent* 2009;3(4):343-347.
19. Dean Bidgood W, Horii SC, Prior FW, et al. Understanding and using DICOM, the data interchange standard for biomedical imaging. *J Am Med Inform Assoc* 1997;4(3):199-212.
20. American Dental Association Standards Committee on Dental Informatics. Technical report no. 1023-2005: Implementation requirements for DICOM in dentistry. Chicago: American Dental Association; 2005.
21. Hjeltn NM. Benefits and drawbacks of telemedicine. *J Telemed Telecare* 2005;11(2):60-70.
22. Mulligan TW, Williams CA, Aller MS. *Atlas of Canine & Feline Dental Radiography*. Trenton: Veterinary Learning Systems, 1998;27-44.
23. Brook NA. How to obtain the best dental radiographs. *Vet Med Supp* Oct 1, 2007.
24. Holmstrom SE, Frost-Fitch P, Eisner ER. *Veterinary Dental Techniques for the Small Animal Practitioner*. 3<sup>rd</sup> ed. Philadelphia: WB Saunders, 2004;131-174.

## CUT-OUT AND KEEP...

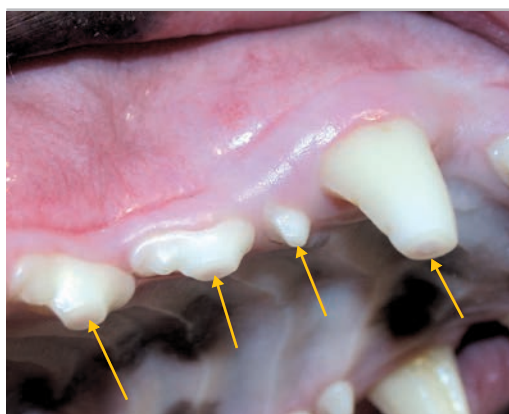
# Dental disease in dogs and cats

■ **Javier Collados, DVM**

Dentistry and Oral Surgery, Sinergia Veterinaria, Madrid, Spain

## KEY POINTS

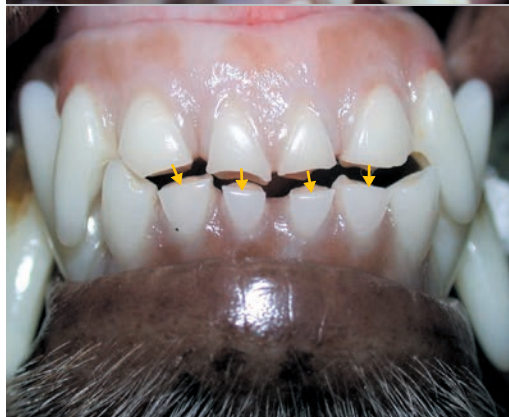- Detection of dental disease requires an initial oral examination, followed by a definitive oral examination under general anesthesia.
- Suitable dental instruments (e.g. explorer, periodontal probe) along with additional diagnostic tests as necessary (such as dental radiographs) are essential for accurate diagnosis.
- Dental, rather than conventional, radiographs are required for correct diagnosis.



### Abrasion

**Loss of dental tissue through abnormal mechanical action, caused by foreign objects in the oral cavity (e.g. tennis balls, stones, cage bars).**

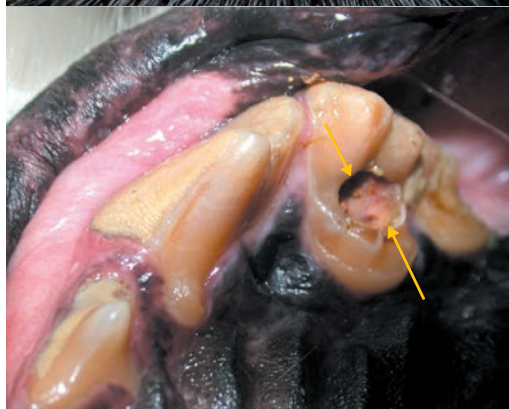
- **Prevalence:** common in dogs; rare in cats.
- **Diagnosis:** visual examination and dental explorer.
- **Key point:** use an explorer to assess if pulp exposure is present. Determine whether the change in color on the occlusal surface of an affected tooth is due to tertiary dentine (brown discoloration) or pulp exposure (black discoloration).



### Abnormal attrition

**Physiological loss of dental tissue due to contact between the occlusal surfaces of the teeth during mastication. Usually mild but in some cases (e.g. certain malocclusions) can become abnormal and severe.**

- **Prevalence:** relatively common in dogs; sometimes seen in cats.
- **Diagnosis:** visual examination and dental explorer.
- **Key point:** as with abrasions, it is essential to use an explorer to assess whether or not pulp exposure is present. Dental radiology may be necessary to determine the extent of the disease.



### Dental caries

**Demineralization and destruction of calcified tooth tissue caused by bacteria.**

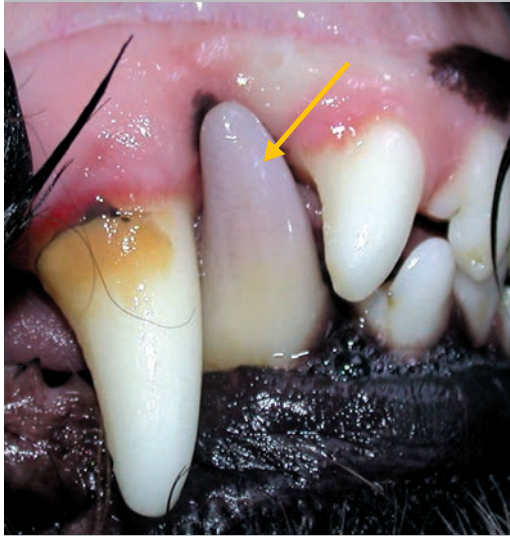- **Prevalence:** uncommon in dogs, extremely rare in cats.
- **Diagnosis:** visual examination, explorer and dental radiography (to determine the extent of the lesion).
- **Key point:** the most commonly affected tooth in dogs is the maxillary first molar. Always examine the first, second and third mandibular molars if the first maxillary molar is affected, as they occlude with it and can also be affected.

© Javier Collados

© Javier Collados

© Javier Collados



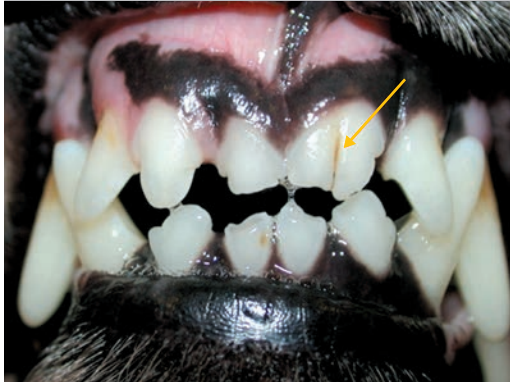

© Javier Collados

## Tooth discoloration

A color change (which can vary markedly) on part or all of the crown of the tooth. It can accompany, and be related to, other dental diseases (e.g. tooth fracture).

- **Prevalence:** relatively common in dogs, occasionally seen in cats (relatively common in conjunction with complicated fractures).
- **Diagnosis:** visual examination.
- **Key point:** etiology varies (e.g. trauma, physical, chemical), and the pulp may be necrotic, so dental radiography is always indicated.

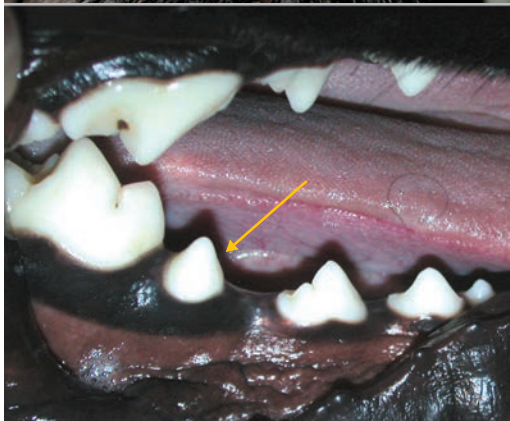

© Javier Collados

## Fusion

Where the dentine of two individual teeth fuses together, leading to fewer teeth than normal.

- **Prevalence:** uncommon in dogs, very rare in cats.
- **Diagnosis:** visual examination and explorer.
- **Key point:** severe morphological change can lead to pulp pathologies. Dental radiography is indicated.

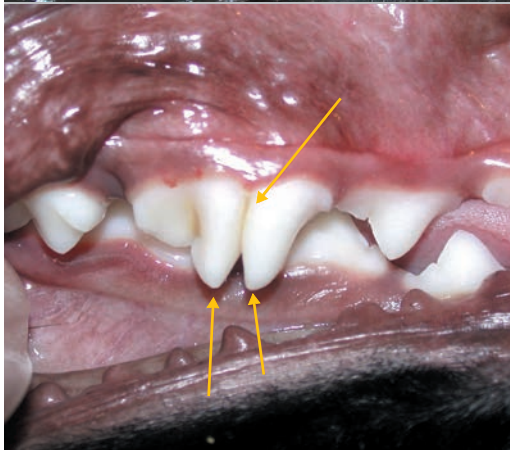


© Javier Collados

## Microdontia

A change in the size of a tooth, whereby affected teeth are smaller than normal. If multirooted teeth are involved, the number of roots are often altered.

- **Prevalence:** uncommon in dogs, very rare in cats.
- **Diagnosis:** visual examination.
- **Key points:** dental radiography to detect any changes in the shape and number of roots is indicated.



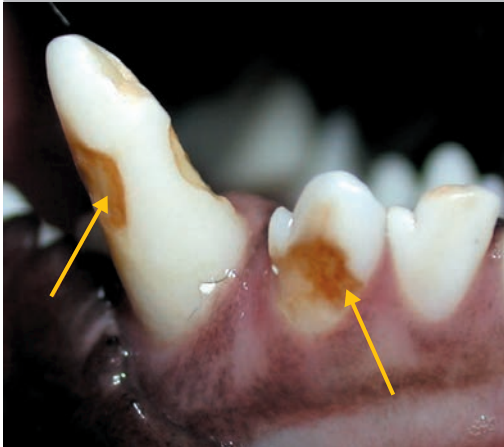
© Javier Collados

## Gemination

Where two teeth try to develop from the same bud. Usually a tooth has two crowns, separated by a crack. There is no reduction in the number of teeth.

- **Prevalence:** uncommon in dogs, very rare in cats.
- **Diagnosis:** visual examination and explorer.
- **Key point:** the morphological change can lead to pulp pathologies. Monitoring using radiography is always indicated.

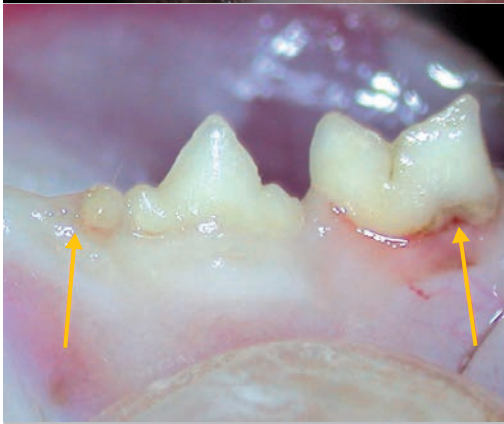




## Enamel hypoplasia

**A defect in amelogenesis (enamel development) whereby insufficient enamel is deposited.**

- **Prevalence:** relatively common in dogs, very rare in cats.
- **Diagnosis:** visual examination and explorer.
- **Key point:** should not be confused with enamel hypomineralization (amelogenesis alteration with inappropriate mineralization of the enamel). Etiology varies; the most common are viral infections and localized trauma.

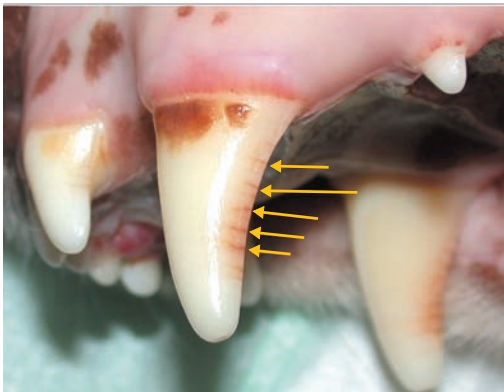

## Resorption

**Progressive destruction of permanent tooth tissue, due to the action of clastic cells. The etiology is complex and has not yet been clearly defined.**

- **Prevalence:** uncommon in dogs but common in cats (feline oral resorption lesion - FORL).
- **Diagnosis:** visual examination, explorer and dental radiography.
- **Key points:** radiography is essential to assess the extent of the lesion, allow classification and permit formulation of a treatment plan.

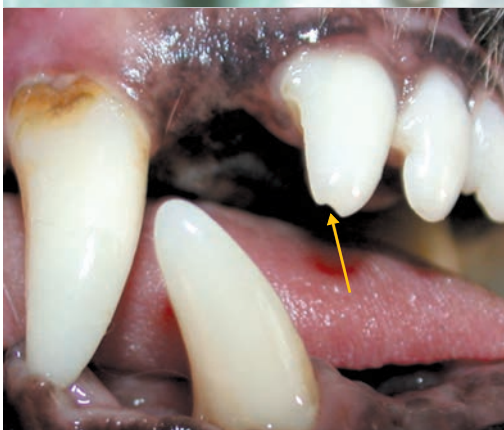
## DENTAL FRACTURES\*



## Enamel infraction (EI)

**A fracture or crack in the enamel without loss of substance.**

- **Prevalence:** uncommon in dogs, very uncommon in cats (cannot be detected with the naked eye).
- **Diagnosis:** visual examination.
- **Key point:** pulp pathology is unlikely but a dental radiography is indicated.

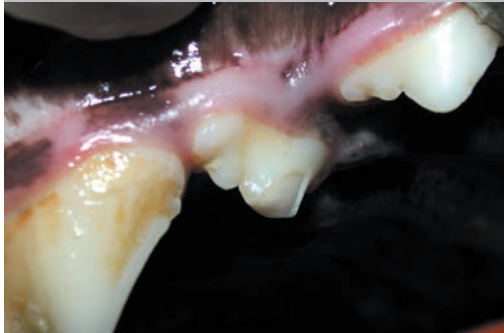


## Enamel fracture (EF)

**A fracture affecting only the enamel with loss of substance.**

- **Prevalence:** relatively common in dogs, relatively uncommon in cats.
- **Diagnosis:** visual examination and explorer.
- **Key point:** the use of an explorer may be necessary to differentiate it from other types of fractures (e.g. an uncomplicated crown fracture). Dental radiography is indicated.

\*Abbreviations refer to American Veterinary Dental College tooth fracture classification system

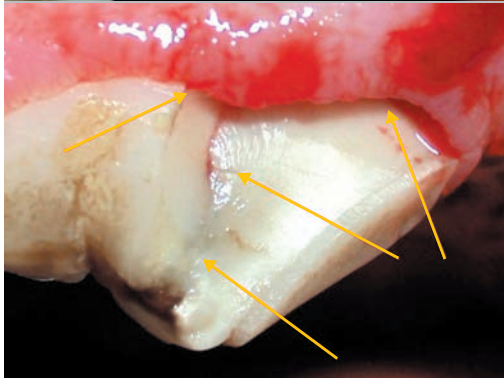


© Javier Collados

### Uncomplicated crown fracture (UCF)

**A fracture of the crown without pulp exposure.**

- **Prevalence:** relatively common in both dogs and cats.
- **Diagnosis:** visual examination and explorer.
- **Key point:** radiography is indicated; appropriate treatment (e.g. indirect pulp cap) may be necessary.

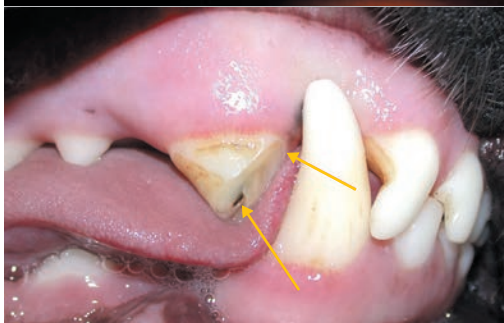


© Javier Collados

### Uncomplicated crown-root fracture (UCRF)

**Fracture of the crown and root without pulp exposure.**

- **Prevalence:** relatively uncommon in dogs, rare in cats.
- **Diagnosis:** visual examination, explorer and dental radiography (to determine the extent of the damage).
- **Key point:** dental radiography if the periodontal area is compromised; appropriate treatment (root canal and/or periodontal treatment) may be indicated.

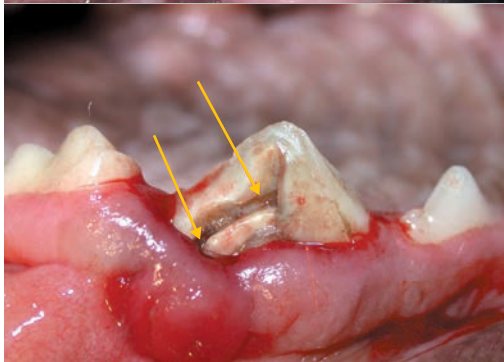


© Javier Collados

### Complicated crown fracture (CCF)

**Fracture of the crown with pulp exposure.**

- **Prevalence:** common in both dogs and cats.
- **Diagnosis:** visual examination and explorer.
- **Key point:** after dental radiography, treatment is essential (root canal treatment or extraction).

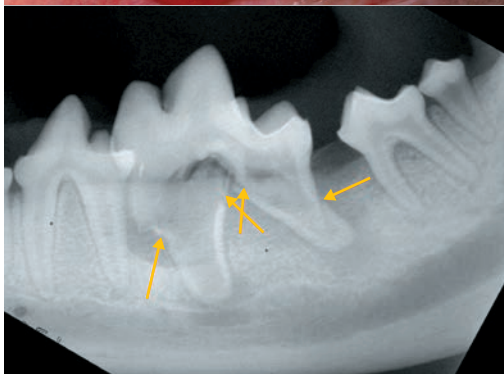


© Javier Collados

### Complicated crown-root fracture (CCRF)

**A fracture of both crown and root with pulp exposure.**

- **Prevalence:** common in both dogs and cats.
- **Diagnosis:** visual examination, explorer and dental radiography (to determine the extent of the damage).
- **Key point:** following dental radiography, treatment is essential (root canal and periodontic treatment if feasible, or extraction).



© Javier Collados

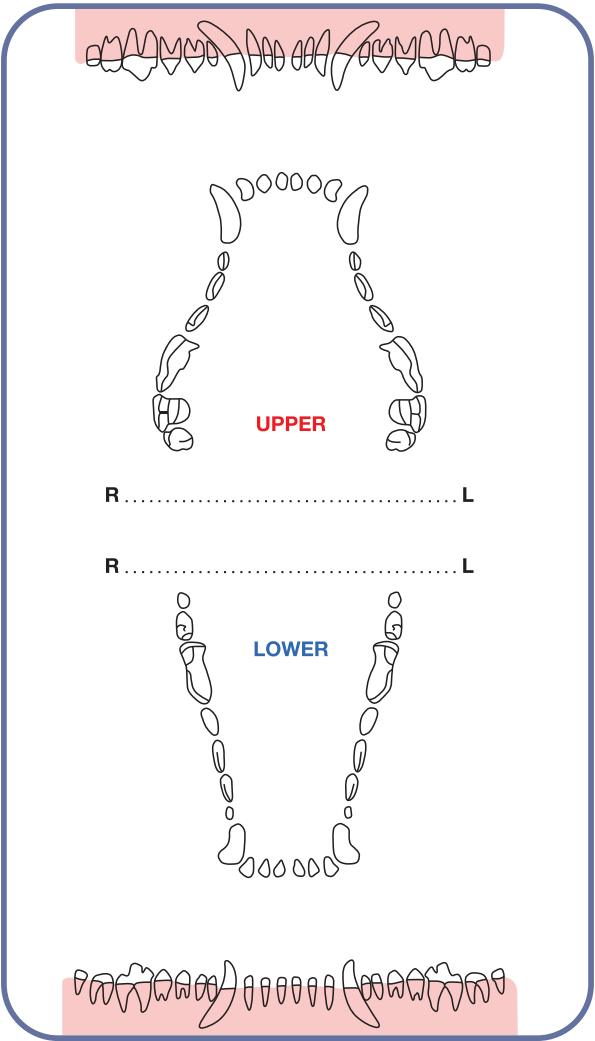
### Root fracture (RF)

**Fracture of the dental root alone.**

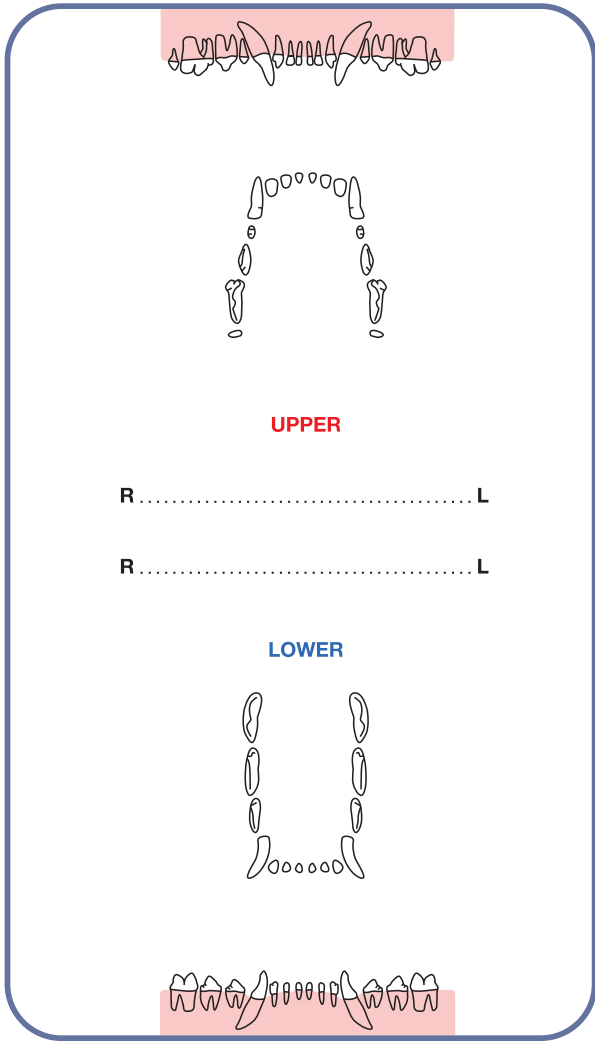
- **Prevalence:** relatively uncommon in dogs, rare in cats.
- **Diagnosis:** explorer (to assess the degree of crown movement) and dental radiography.
- **Key point:** dental radiography for the diagnosis is essential. Treatment is extraction.

# Canine and feline permanent dentition charts

## Dog permanent dentition



## Cat permanent dentition



We welcome offers to write ideas for papers and suggestions for topics and authors, which should be directed to the editor. Veterinary Focus is fully covered by copyright. No part of this publication may be reproduced, copied or transmitted in any form or by any means (including graphic, electronic or mechanical), without the written consent of the publishers © Royal Canin 2012. Proprietary names (trademarks) have not been specially identified. It cannot, however, be conducted from the omission of such information that they are non-proprietary names and as such can be used by everyone. The publishers cannot take any responsibility for information provided on dosages and methods of application. Details of this kind must be checked for correctness by the individual user in the appropriate literature. While every effort has been made by the translators to ensure the accuracy of their translations, no responsibility for the correctness of the original articles and thus no resulting claims against professional negligence can be accepted in this connection. Views expressed by authors or contributors do not necessarily reflect the views of the publishers, editors or editorial advisors.

# Continuing Education *with Bite!*

**22<sup>nd</sup>** and **12<sup>th</sup>**

European  
Congress  
of Veterinary  
Dentistry

World  
Veterinary  
Dental  
Congress

**23-25 May 2013**

[www.evds.info](http://www.evds.info)



CZECH VETERINARY  
DENTAL SOCIETY



**PRAGUE – CZECH REPUBLIC**