VETERINARY
focus
#27.1
2017 – $10/10€
The worldwide journal for the companion animal veterinarian

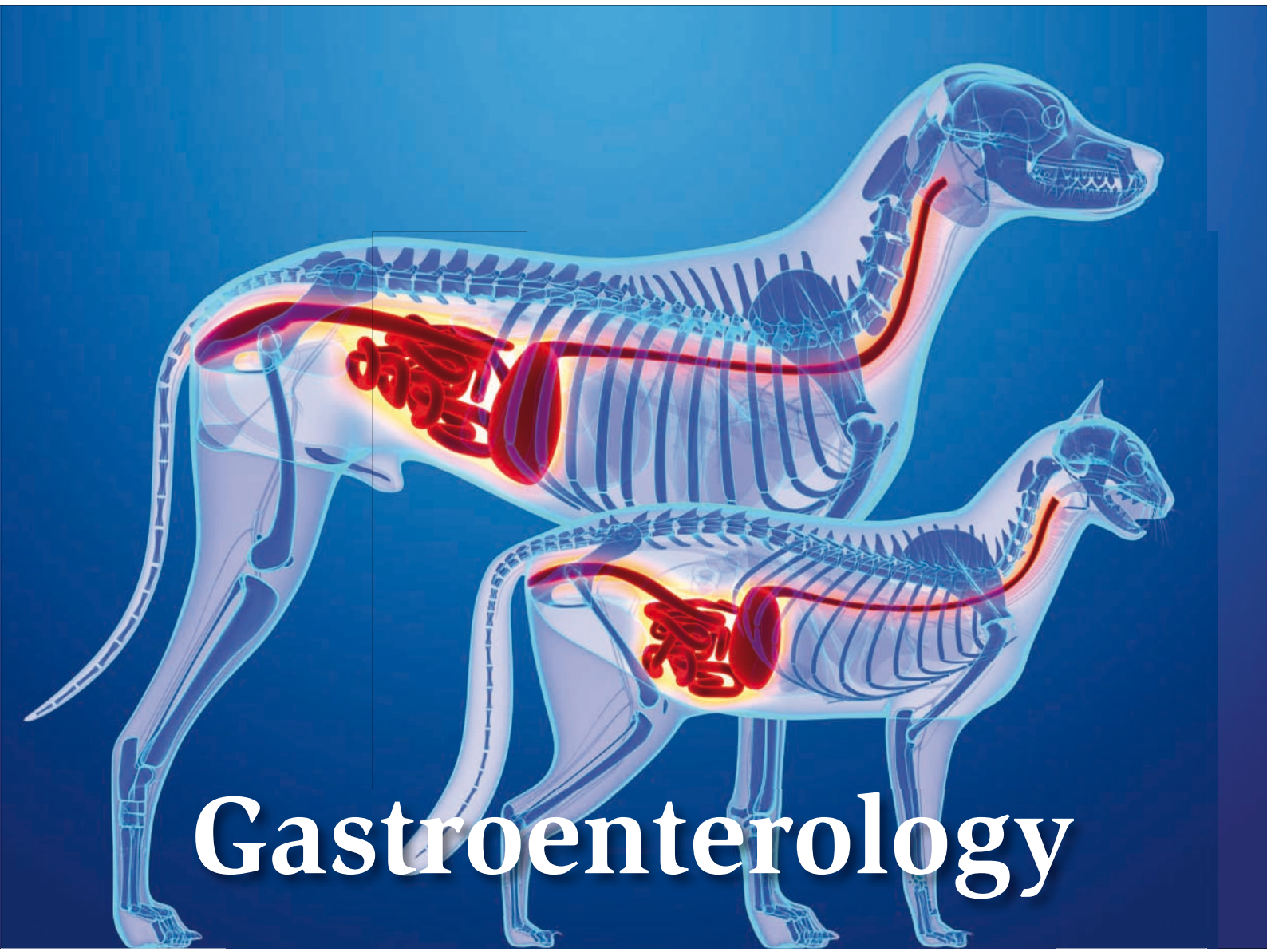

Gastroenterology

Chronic enteropathy in cats • Canine pancreatitis • Feline esophagitis • Canine protein-losing enteropathies • Prevalence of chronic gastrointestinal signs in cats • Gastrointestinal endoscopy in dogs • How I approach… The cat with chronic diarrhea • A short guide to… Nasal feeding tubes

ROYAL CANIN®

A Breath of Fresh Air
...All Things Respiratory

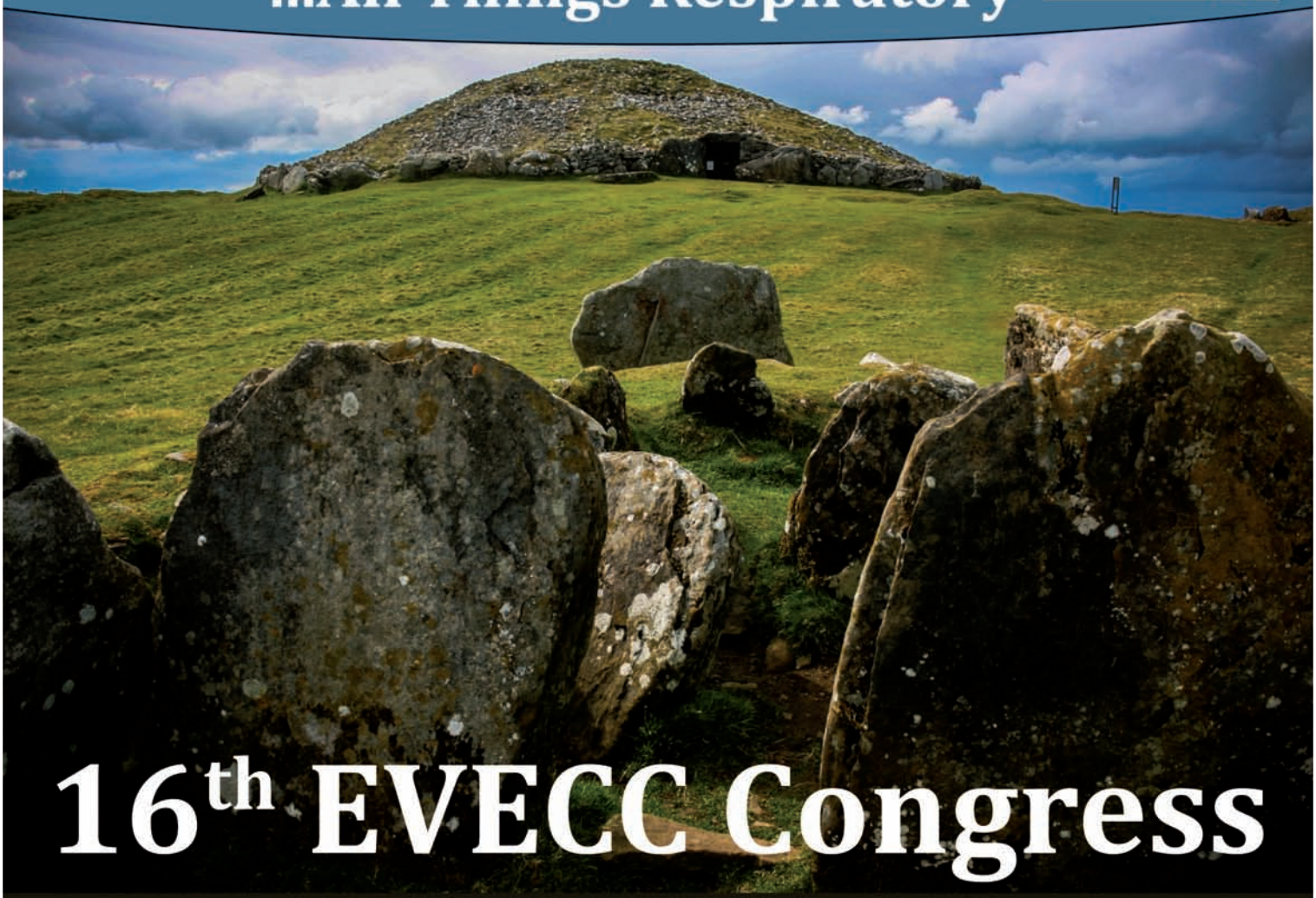

16th EVECC Congress

Dublin, Ireland

June 22nd - 24th, 2017

Refresher, advanced & nursing streams
Labs, abstracts, posters & more

www.evecc-congress.org

ROYAL CANIN

B|BRAUN SHARING EXPERTISE

scil veterinary excellence

ECVECC

E D I T O R I A L

02 **Chronic enteropathy in cats**
Suliman Al-Ghazlat and Christian Eriksson de Rezende

09 **Canine pancreatitis**
Melinda A. Wood and Craig Datz

14 **Feline esophagitis**
Toshihiro Watari

20 **Canine protein-losing enteropathies**
Rance Sellon

25 **Prevalence of chronic gastrointestinal signs in cats**
Emi Saito and Silke Kleinhenz

27 **Gastrointestinal endoscopy in dogs**
Franck Jolivet and Olivier Dossin

35 **How I approach... The cat with chronic diarrhea**
Craig Webb

42 **A short guide to... Nasal feeding tubes in dogs**
Joris Robben and Chiara Valtolina

The logical, rational approach advocated by today's scientific world contrasts greatly with methods used by previous civilizations in the search for knowledge. Indeed, many different empires and cultures employed a huge and bewildering number of stratagems over the centuries in an attempt to gain knowledge of one sort or another, and at times it seems that superstition, the occult and fantastic rituals were more important than systematic discovery or analytical reasoning. And perhaps no method was quite as strange as the ancient Etruscan art of haruspicy, which involved inspecting the entrails of a sacrificed animal in order to obtain information otherwise unavailable by more empirical investigation. Key to its success was the intervention of the haruspex, a man blessed with the supernatural ability to divine what the intestines and other viscera revealed, and however grotesque this may seem today, the practice was often regarded as offering better results than more mainstream techniques such as astrology or prophetic visions.

But sifting through entrails was by no means the only way in which knowledge was sought, and some methods from centuries past are still with us today – interpreting Tarot cards, reading the lines on someone's hand, or staring into the depths of a crystal ball. Common to most of these more unusual attempts at divination is the idea that – as with haruspicy – we need a medium as a conduit to attain true knowledge; so we have the cartomancer, necessary to interpret mystical cards; the chiromancer, who can reach hidden knowledge through studying a person's palm; and the clairvoyant, able to plumb the depths of the misty sphere.

All of which seems a far cry from the scientific world and our desire for knowledge, yet in some ways this issue of *Veterinary Focus* has something in common with the implausible methods of old. The approach is more logical, but one may divine some similarities; our mediums are the authors, the entrails – or inner workings of the journal – offer enlightenment, and the whole is a pathway for learning, offering new insights into the mysteries of gastrointestinal medicine and disease.

Ewan McNeill – Editor-in-chief

***Veterinary Focus* – Vol 27 n°1 – 2017**

Editorial committee
- Franziska Conrad, DVM, Scientific Communications, Royal Canin, Germany
- Craig Datz, DVM, Dipl. ACVN, Senior Scientific Affairs Manager, Royal Canin, USA
- Pauline Devlin, BSc, PhD, Scientific Communications and External Affairs, Royal Canin, UK
- María Elena Fernández, DVM, Chile
- Joanna Gale, BVetMed, CertLAS, MRCVS, Science and Technical Communications Manager, WALTHAM Centre for Pet Nutrition, UK
- Philippe Marniquet, DVM, Dipl. ESSEC, Veterinarian Prescribers Marketing Manager, Royal Canin, France
- Sally Perea, DVM, Dipl. ACVN, Nutritionist, Royal Canin, USA
- Anne van den Wildenberg, DVM Technical Manager, Royal Canin Netherlands
- Melinda A. Wood, DVM, MS, Dipl. ACVIM, Scientific Affairs Manager, Royal Canin, USA

Translation control
- Elisabeth Landes, DVM (German)
- Noemí Del Castillo, PhD (Spanish)
- Matthias Ma, DVM (Chinese)
- Minoru Fukuyama, DVM (Japanese)
- Boris Shulyak, PhD (Russian)

Deputy publisher:
Buena Media Plus
Bernardo Gallitelli and Didier Olivreau
Address: 90, rue de Paris 92100 Boulogne-Billancourt, France
Phone: +33 (0) 1 72 44 62 00

Editor-in-chief: Ewan McNeill, BVMS, Cert VR, MRCVS
Editorial secretary
- Laurent Cathalan
  lcathalan@buena-media.fr

Artwork
- Pierre Ménard

Printed in the European Union
ISSN 2430-7874
Circulation: 70,000 copies
Legal deposit: March 2017
Cover: Shutterstock

Veterinary Focus is also published in French, German, Chinese, Italian, Polish, Spanish, Japanese & Russian.

The licensing arrangements for therapeutic agents intended for use in small animal species vary greatly worldwide. In the absence of a specific license, consideration should be given to issuing an appropriate cautionary warning prior to administration of any such drug.

Find the most recent issues of *Veterinary Focus* on IVIS website: www.ivis.org.

PEFC 10-31-1668

ROYAL CANIN®

Chronic enteropathy in cats

Suliman Al-Ghazlat, DVM, Dipl. ACVIM
BluePearl Veterinary Partners, Paramus, New Jersey, USA

Dr Al-Ghazlat graduated from Jordan University of Science and Technology in 1999. He completed an internship in Small Animal Medicine and Surgery at Purdue University and a residency in Small Animal Internal Medicine at the Animal Medical Center, New York; he is currently an internist in private practice.

Christian Eriksson de Rezende, DVM, MS, Dipl. ACVIM
BluePearl Veterinary Partners, Paramus, New Jersey, USA

Dr Eriksson de Rezende graduated from The Ohio State University College of Veterinary Medicine in 2006. He completed a residency in Small Animal Internal Medicine at Michigan State University in 2010 and has worked for BluePearl Veterinary Partners since then.

KEY POINTS

- **Clinical signs, physical examination, bloodwork and imaging findings for inflammatory bowel disease and small cell intestinal lymphoma often overlap, but treatment and prognosis for the two diseases are different, and accurate diagnosis is essential.**
- **Definitive diagnosis of both conditions requires histopathologic evaluation; full-thickness tissue samples appear to be superior to endoscopic biopsy samples. Adding advanced diagnostic methods to traditional histopathology may improve the accuracy of diagnosis.**
- **Novel or hydrolized diets may ameliorate the symptoms of IBD, but corticosteroids may be necessary to sustain disease remission.**
- **In cases of refractory IBD, the clinician should consider lack of client compliance with treatment, other comorbidities, or a misdiagnosis before altering therapy.**
- **Owners should be aware that cats with small cell lymphoma can have a favorable prognosis.**

Introduction

Inflammatory bowel disease (IBD) and small cell lymphosarcoma (ScLSA) of the gastrointestinal tract (GIT) are common diseases in cats that cause similar clinical signs. IBD refers to a group of idiopathic and chronic inflammatory disorders characterized by persistent or recurrent gastrointestinal signs, and is a diagnosis of exclusion. The etiology and pathogenesis of IBD is likely multifactorial, involving the interaction of host genetics, immune system and the intestinal microenvironment. The etiology of ScLSA is similarly complex, poorly understood and again likely multifactorial. The emergence of GIT ScLSA has created a diagnostic and treatment challenge for the feline patient with chronic enteropathy. Efforts to standardize the reporting of endoscopy and histopathology findings, in addition to advanced diagnostics such as Immunohistochemistry (IHC) and polymerase chain reaction (PCR), represent a great help to the feline practitioner.

Feline chronic enteropathy

Evaluating a feline patient with chronic signs of GIT disease (vomiting, diarrhea, weight loss and/or variation of appetite) should start with a thorough, sequential, non-invasive diagnostic work-up and a well-implemented therapeutic trial tailored to each specific patient. The goal is to exclude extra-GI disorders, GIT parasites, food- or antibiotic-responsive enteropathy, and intestinal structural abnormalities before narrowing down the differential diagnosis to IBD or ScLSA ***(Table 1 and Figures 1-3).*** Differentiating ScLSA from IBD is difficult and requires relatively invasive and costly diagnostics (1-8).

Table 1. Suggested diagnostic work-up for cats with chronic GIT signs.

Minimum database (complete blood count, biochemistry profile and urinalysis) to assess disease severity and to screen for underlying or concurrent extra GI disease.
Fecal testing for parasites or a broad-spectrum dewormer treatment trial; therapeutic trials for food- and antibiotic-responsive disease may also be appropriate, depending on the case.
Thyroid hormone levels for cats > 6 years of age especially if there is weight loss, polyphagia, vomiting and/or occasional diarrhea.
Pancreatitis testing for cats presenting for lethargy, dehydration, hyporexia, vomiting and diarrhea.
Exocrine pancreatic insufficiency tests for cats with weight loss, diarrhea and increased appetite.
Cobalamin level assessment to determine the severity and localization of the GIT disease and to evaluate the need for supplementation.
Abdominal imaging: Radiographs may identify masses, organomegaly or may show decreased serosal detail suggestive of effusions or emaciation. Ultrasound better assesses the GIT architecture, appearance of other organs, and lymphadenopathy.
Specific testing for regional infectious disease when appropriate (*e.g.,* histoplasmosis).
Endoscopic/surgical biopsy if previous diagnostics fail to identify the underlying cause.

The lack of diagnostic and therapeutic standards for cats with chronic enteropathy creates great challenges for the practitioner. Because IBD is poorly understood and has vague diagnostic criteria, the syndrome is probably over/misdiagnosed (1). Multiple specialty associations have made excellent efforts over the last decade to provide guidelines and standards for history taking, physical examination, laboratory diagnostic tests, imaging procedures, endoscopic and biopsy procedures, histopathologic interpretation, therapeutic trials, and patient response and outcome in dogs and cats with chronic GIT disease (1,4-7). By methodically fulfilling the criteria for the clinical diagnosis of IBD ***(Table 2),*** the clinician may avoid expensive and invasive testing in addition to unnecessary long-term anti-inflammatory therapy (1).

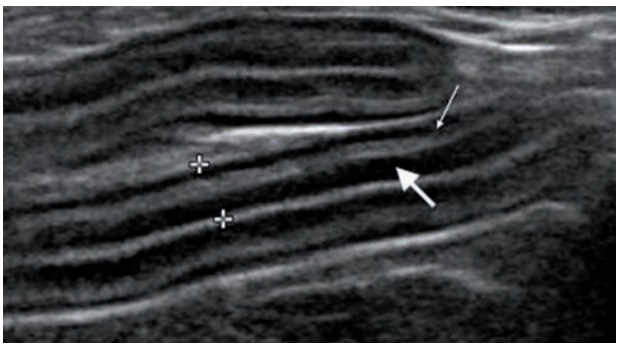

© S. Al-Ghazlat & C. Eriksson de Rezende

Figure 1. Ultrasonographic longitudinal image of the jejunum of a cat diagnosed with inflammatory bowel disease. The mucosal layer (large arrow) is more prominent than the muscularis layer (thin arrow) but this finding does not exclude the possibility of ScLSA. The overall bowel wall thickness (between calipers) was increased at 3.2 mm.

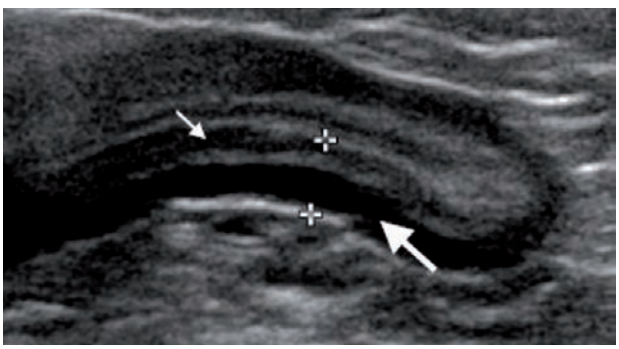

© S. Al-Ghazlat & C. Eriksson de Rezende

Figure 2. Ultrasonographic longitudinal image of the jejunum of a cat diagnosed with ScLSA. The muscularis layer (thick arrow) is prominent and thicker than the mucosal layer (thin arrow). The overall bowel wall thickness (between calipers) was increased at 4.2 mm.

Figure 3. Ultrasonographic longitudinal image of a markedly thickened loop of jejunum measuring 6.9 mm in thickness (between calipers) with complete obliteration of normal architecture. This patient was diagnosed with ScLSA.

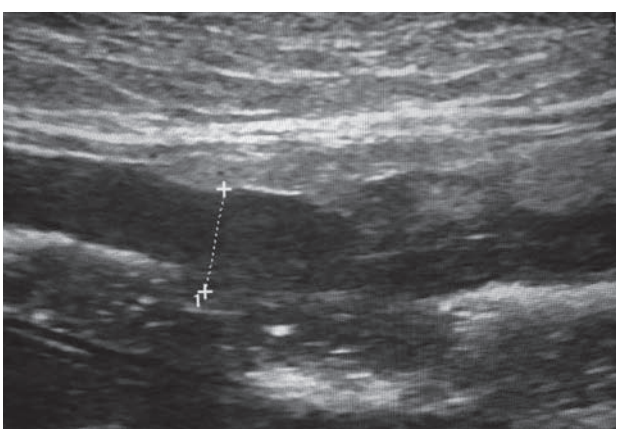

© S. Al-Ghazlat & C. Eriksson de Rezende

Lymphosarcoma (LSA) is the most common hematopoietic neoplasia in cats and can occur in multiple anatomic locations, but the GIT is the most frequently affected site (8). ScLSA of the feline GIT is an emerging disease with a poorly understood but likely multifactorial pathogenesis. Risk factors may include chronic inflammation, *Helicobacter* infection, retroviruses (FeLV, FIV), and exposure to cigarette smoke (8-11). ScLSA and IBD are both characterized by infiltration of the GIT with small lymphocytes and have overlapping findings in history, physical exam, bloodwork, imaging and histopathology. In spite of the similarities, the course of the disease, treatment options and the prognosis are different for these two conditions, highlighting the importance for an accurate diagnosis ***(Table 3).***

Diagnostic biopsy dilemmas

Intestinal biopsy for histological evaluation is often recommended once a thorough diagnostic work-up and therapeutic trials fail to identify the cause of a chronic enteropathy. Although histologic evaluation is the test of choice for diagnosis of IBD or LSA, multiple factors can make this problematic. These factors include inadequate sample size, poor sample processing, segmental disease, the coexistence of ScLSA and inflammation in the same patient, the overlap in histologic features between the two entities, and differences of opinion among pathologists (1,3,5). The potential for progression of IBD to LSA further complicates the diagnosis (9).

Among the key challenges associated with GIT biopsy is the need to obtain tissue at the correct location and of adequate depth. The inability to assess architectural integrity of all tissue compartments in endoscopic biopsy specimens and the fact that some patients have segmental pathology have fueled the debate regarding the best method required (*i.e.,* endoscopy or full-thickness surgical biopsy) to differentiate IBD from ScLSA (5).

A few studies supported the use of full-thickness biopsy by showing that LSA (unlike IBD) frequently infiltrates beyond the mucosa into the deeper layers, destroying normal tissue architecture (5). Furthermore, the common sites of feline intestinal LSA are the ileocecocolic junction and the jejunum, and neither site is routinely sampled at gastroduodenoscopy. A decade ago, a prospective study on 22 cats that underwent gastroduodenoscopy immediately prior to laparotomy or laparoscopic surgery concluded that endoscopic biopsies are inadequate for differentiating IBD from GIT LSA, and that full-thickness intestinal samples should be obtained

Table 2. Criteria for the clinical diagnosis of IBD (1).

Chronic (> 2 weeks) persistent or recurrent gastrointestinal signs.
Inadequate response to dietary, antibiotic, and anthelmintic therapies.
Histopathologic evidence of mucosal inflammation.
Inability to document other causes of gastrointestinal signs or inflammation.
Clinical response to anti-inflammatory or immunosuppressive agents.

Table 3. A comparison of various factors for IBD and ScLSA (12,13).

Signalment	No clear gender, age, or breed predisposition. Cats with LSA tend to be older, with median age ranges from 9-13 years.
Clinical signs	Common clinical signs are non-specific for both conditions and may include weight loss, variation in appetite, vomiting, diarrhea and lethargy.
Physical examination	Thin body condition, thickened intestines, and mesenteric lymphadenopathy can be found in both conditions. Abdominal masses may be palpated in cats with LSA.
Clinical pathology	CBC and chemistry are typically normal in cats with IBD. Anemia and hypoalbuminemia are found in 50% of cats with LSA. Hypocobalaminemia is a frequent finding in both conditions.
Diagnostic imaging	Abdominal radiographs are rarely useful. Common ultrasonographic changes in both conditions are GIT wall thickening, mesenteric lymphadenopathy, and decreased motility. Findings that support LSA include loss of normal wall layering, disproportionally thick muscularis, focal intestinal mass effects, and ascites.

ROYAL CANIN®

for accurate diagnosis (2). However, the study had a serious limitation in that the endoscope could not traverse the pylorus in 8 cats, and therefore some duodenal samples were obtained blindly. It is likely that endoscopically obtained samples would have performed better if the duodenum had been successfully intubated.

The ACVIM* has stated that biopsy is not appropriate in every animal with chronic GIT disease, but where biopsy is indicated an endoscopic method is the preferred choice (1). This statement acknowledges the advantages of surgical biopsy, such as the ability to collect full-thickness samples and to observe and sample other abdominal organs. On the other hand, endoscopy permits the operator to see mucosal changes and direct biopsy acquisition at these locations ***(Figure 4)*** with collection of multiple tissue samples from various intestinal sites. Endoscopy also permits diagnosis of selected lesions (*e.g.,* ulceration, erosion, lymphangiectasia). A large retrospective study on GIT samples collected from a total of 63 cats (50 surgical samples and 13 endoscopic samples) revealed clear evidence that both false negatives and positives are possible for the histopathological diagnosis of ScLSA even when evaluating full-thickness samples (5). One retrospective study revealed that standard gastroduodenoscopy resulted in misdiagnosis in 44% of the study population; for 8 of the 18 cats diagnosed with LSA, neoplastic cells were found in the ileal tissue alone, and the authors suggested performing both upper and lower GIT endoscopy to improve the accuracy of samples (14).

IHC and PCR

Confirming a diagnosis of GIT ScLSA against IBD based on traditional histopathology can be challenging for the many reasons mentioned above. Multiple advanced diagnostic tests have been researched to help the pathologist reach an accurate diagnosis. Of these, IHC and PCR have gained the most attention (5-8,15,16). The detection of a clonal population of cells in a lesion represents an important criterion for the diagnosis of neoplasia. PCR is a methodology that can be used to detect clonality in lymphocytes. IHC assesses the phenotypic uniformity of a lymphocytic infiltrate, making it a useful adjunct to histopathology in further characterizing a lesion. Multiple studies showed that the sensitivity and specificity of IHC and PCR make them valuable adjunctive tools for accurately differentiating ScLSA from IBD, even from small amounts of tissue such as endoscopically obtained biopsies (5-8,16) ***(Figures 5 and 6).*** In addition, immunophenotyping and clonality testing might be of prognostic value in cases of feline GIT LSA (15,16).

*American College of Veterinary Internal Medicine

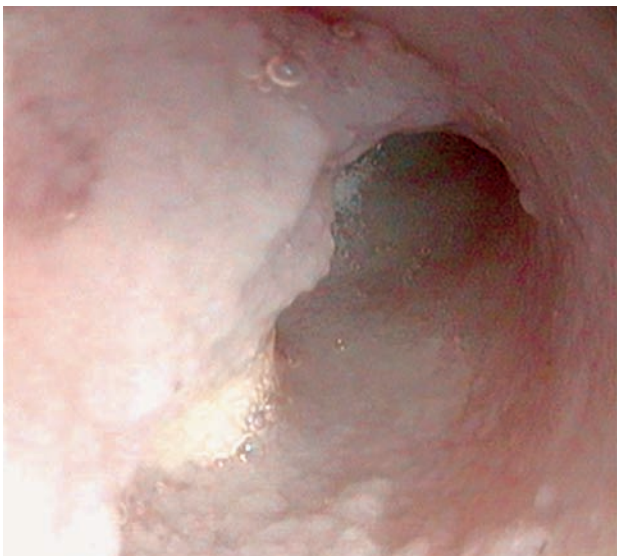

© S. Al-Ghazlat & C. Eriksson de Rezende

Figure 4. Endoscopic image of the proximal duodenum from a 12-year-old spayed domestic shorthair cat that presented for chronic vomiting and weight loss. Note the granularity of the duodenal mucosa. Histopathology was diagnostic for moderate to severe chronic lymphoplasmacytic inflammation.

One study looked at the impact of adding IHC and PCR results to the traditional histopathology for diagnosis of GIT LSA or IBD (5). The study cats were classified as either IBD (19 cases) or intestinal LSA (44 cases), based on routine histologic examination alone. When IHC and PCR results were used in conjunction with the histopathology, 10 of the original 19 IBD cases were reclassified as lymphoma and 3 of 44 ScLSA cases were reclassified as IBD. The study demonstrates that a significant number of cats with intestinal ScLSA or IBD are misdiagnosed when using traditional histopathology alone, even with surgical sampling. Based on the results, the author suggested a novel diagnostic approach utilizing a stepwise testing strategy; this involves initially evaluating intestinal biopsy specimens with a histomorphologic assessment, followed by IHC, and finally PCR. This systematic approach will likely decrease the likelihood of misdiagnosis, and help guide the clinician to formulate an appropriate therapy and more accurate prognosis.

IBD treatment

Treatment for presumptive or diagnosed IBD includes dietary modification, cobalamin supplementation (when indicated), antimicrobials with immunomodulatory properties, and immunosuppressive therapy.

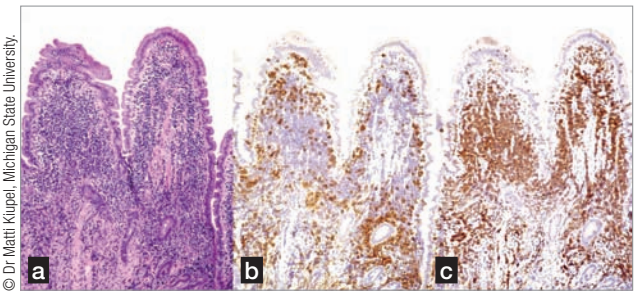

© Dr Matti Kiupel, Michigan State University.

Figure 5. Histopathology images from the small intestine of a cat diagnosed with IBD. **(a)** The mucosa of the small intestinal tract is characterized by a diffuse lymphoplasmacytic infiltration (H&E stain); **(b)** note that some of the inflammatory cells stain positive for CD20, a marker for B cells; **(c)** some cells stain positive for CD3, a T cell marker.

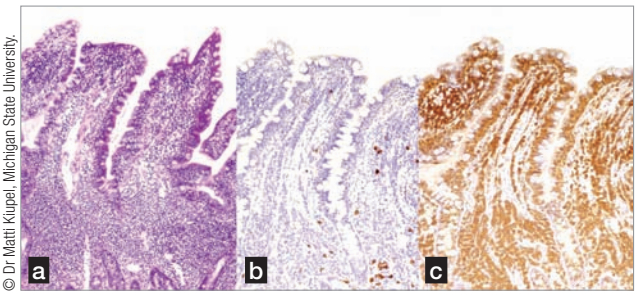

© Dr Matti Kiupel, Michigan State University.

Figure 6. Histopathology images from the small intestine of a cat diagnosed with ScLSA. H&E staining showed a marked diffuse infiltrative pattern affecting the mucosa and villi **(a);** note that the staining pattern fades when immunohistochemistry against B cells is performed **(b)** but is positive when immunohistochemistry against T cells is performed, confirming a predominantly T cell infiltrate **(c).**

Dietary modification

The use of a highly digestible diet with a novel source of protein (*e.g.,* rabbit, venison) or a hydrolyzed diet is recommended for cats with suspected or confirmed IBD. Clinical signs may improve within 4-8 days after dietary modification. Some studies have shown that diet trials can help improve clinical signs but that immunosuppressive therapy was necessary to sustain remission (17). If the patient is inappetent, an appetite stimulant (*e.g.,* mirtazapine 1/8-1/4 of a 15 mg tablet per cat Q48-72 h or cyproheptadine 1-2 mg per cat Q12 h) may be necessary. Sometimes glucocorticoids may need to be started before a dietary change can be accomplished.

Probiotics and symbiotics

The efficacy of probiotics for adjunct treatment of feline IBD or ScLSA has not been established; however, studies in cats have shown that probiotics can improve the intestinal environment and immune system function (18). Once started, probiotics may need to be continued indefinitely, but selecting the best product is difficult due to a large variation in quality control among commercial products. Symbiotics contain prebiotic sugars (*e.g.,* inulin, fructo-oligosaccharides) and probiotic bacteria, and a recent review article revealed that cats with chronic diarrhea had improved fecal scores after being fed a proprietary symbiotic for 21 days (19).

Cobalamin

Cobalamin (Vitamin B12) is a cofactor for normal nucleic acid synthesis and is absorbed by specific receptors in the ileum. Pathology in this area may result in hypocobalaminemia, and subcutaneous supplementation ***(Table 4)*** may result in improvement of clinical signs and optimal response to immunosuppressive therapy (12). Oral supplementation may be an alternative, but efficacy and dosing guidelines have not been established for cats.

Immunosuppressive therapy

Corticosteroids are the cornerstone of therapy for both IBD and ScLSA. In cats, prednisolone is preferred over prednisone due to its higher bioavailability. Several tapering regimens are available for the treatment of IBD ***(Table 4),*** with the goal of achieving the lowest effective dose that keeps the patient free from clinical signs. Rarely, prednisolone can be discontinued and the patient maintained on a novel diet and possibly an antimicrobial (*e.g.,* metronidazole). Flavored additives of animal origin should be avoided if a compounded form of prednisolone is used, as they may interfere with disease remission.

Individual cats can vary in their response to prednisolone, and if therapy is ineffective the clinician should consider using a different type of corticosteroid (*e.g.,* dexamethasone or methylprednisolone), although drawbacks with the latter include unpredictable bioavailability and development of diabetes mellitus. Budesonide is an orally administered glucocorticoid that has a high first-pass removal from the liver, potentially causing fewer systemic side effects; its efficacy in cats with IBD has not been established, but empirical dosages of 0.5-0.75 mg Q24 h per cat have been suggested (20).

Some clinicians reserve the use of chlorambucil in conjunction with steroids for patients with severe or relapsing IBD (21). Usually, it is given every 48-72 hours depending on the patient's weight ***(Table 4)*** (20). Initially, a CBC should be monitored every 2-4 weeks for declining neutrophil or platelet counts, which can indicate bone marrow toxicity.

ROYAL CANIN®

Cyclosporine has been used anecdotally to treat IBD in cats with some success at a dose of 5 mg/kg once to twice daily (20). Side effects may include vomiting, diarrhea and anorexia, which may require a change in dose or frequency. Hepatopathies, urinary tract infections and recrudescence of dormant toxoplasmosis can also occur. Azathioprine is not generally recommended in cats due to reports of severe bone marrow suppression and idiosyncratic fatal leukopenia and thrombocytopenia (23).

Antimicrobials

Metronidazole can be used as a sole agent in patients with mild inflammation, or in conjunction with a glucocorticoid. Neurotoxicity (disorientation, ataxia, seizures, blindness) is the main adverse effect and is usually reversible upon discontinuation of the drug (20).

ScLSA treatment

The optimal diet for cats with ScLSA should be similar to those with IBD (*e.g.,* highly digestible nutrients, with single ingredients if possible), with an appetite stimulant if appropriate. Prednisolone is commonly started at an immunosuppressive dose and then tapered to every other day once remission has been achieved. Chlorambucil is used with a corticosteroid at the start of therapy, typically either continuously (*e.g.,* Q48-72 h) or as a bolus (20 mg/m^2 PO every 2-3 weeks) (24); the duration of clinical remission appears similar with either protocol. Again, CBCs should be monitored and the drug discontinued if segmented neutrophil and platelet counts are persistently below 1,500 and/or 75,000 cells/µL, respectively (25). If a cat fails or no longer responds to glucocorticoid-chlorambucil therapy, rescue protocols (*e.g.,* cyclophosphamide) may be attempted (24).

Prognosis

The prognosis for cats with small cell lymphoma can be favorable, with some reporting a 92% response rate for a median of > 2.5 years (26). Feline IBD can be well managed with a combination of dietary modification and

Table 4. Common drugs used for treating inflammatory bowel disease in cats (20-22).

Drug	Mechanism	Indication	Dose	Side effects
Prednisolone	Immune suppression	Lack of response to diet change/ antimicrobial therapy or confirmed IBD on histopathology	2-4 mg/kg/day for 2-3 weeks then tapered by 25-50% every 2-4 weeks until lowest effective dose controlling symptoms is achieved	PU/PD Polyphagia Cardiomyopathy Infections
Methyl-prednisolone	Immune suppression	Alternative for patients that refuse oral medication	10 mg/kg SC every 2-4 weeks, tapered to every 4-8 weeks	As above Diabetes mellitus
Chlorambucil	Alkylating agent	ScLSA or refractory cases of IBD	Cats > 4 kg: 2 mg PO Q48 h Cats < 4 kg: 2 mg PO Q72 h	Bone marrow suppression Neurotoxicity
Cyclosporine	Inhibits T cell function	Severe or refractory cases of IBD	5 mg/kg PO Q12-24 h	Vomiting, diarrhea, hepatopathy
Azathioprine	Interferes with DNA synthesis	Severe or refractory cases of IBD	0.3 mg/kg PO Q48 h	Severe bone marrow suppression
Metronidazole	Anaerobic activity Possible immunomodulatory properties	Severe or refractory cases of IBD	10-15 mg/kg/day PO SID (25 mg/kg/day if using metronidazole benzoate)	Neurotoxicity with chronic use
Cobalamin (B12)	Cofactor for methylation	Cobalamin levels < 300 ng/L	250 mg SC/cat once a week for 6 weeks, then 1 dose after 30 days and retesting after 30 days. Continue monthly injection if levels within normal range.	None reported

immunosuppression; however, the client must be informed that the objective of treatment is to improve clinical signs and that a cure is unlikely. A guarded prognosis may be warranted for severely debilitated patients or those with major histologic gastrointestinal lesions, eosinophilic enteritis or hypereosinophilic syndrome (27). In IBD cases, refractory to treatment, the clinician should question the client's compliance with therapy (*e.g.,* was the diet changed or the medication administered?), presence of comorbidites (*e.g.,* pancreatitis, cholangitis) and the accuracy of the original diagnosis (27). In the latter case, the clinician should discuss collecting gastrointestinal biopsies for histologic assessment and immunohistochemistry/PCR for antigen receptor rearrangement as necessary (5).

References

1. Washabau RJ, Day MJ, Willard MD, *et al.* WSAVA International Gastrointestinal Standardization Group.: Endoscopic, biopsy, and histopathologic guidelines for the evaluation of gastrointestinal inflammation in companion animals. *J Vet Intern Med* 2010;24(1):10-26.
2. Evans SE, Bonczynski JJ, Broussard JD, *et al.* Comparison of endoscopic and full-thickness biopsy specimens for diagnosis of inflammatory bowel disease and alimentary tract lymphoma in cats. *J Am Vet Med Assoc* 2006; 229(9):1447-1450.
3. Willard MD, Jergens AE, Duncan RB, *et al.* Interobserver variation among histopathologic evaluations of intestinal tissues from dogs and cats. *J Am Vet Med Assoc* 2002;220(8):1177-1182.
4. Day MJ, Bilzer T, Mansell J, *et al.* Histopathological standards for the diagnosis of gastrointestinal inflammation in endoscopic biopsy samples from the dog and cat. WSAVA Gastrointestinal Standardization Group. *J Comp Pathol* 2008:137:S1-S43.
5. Kiupel M, Smedley RC, Pfent C, *et al.* Diagnostic algorithm to differentiate lymphoma from inflammation in feline intestinal biopsy specimens. *Vet Pathol* 2011;48:212-222.
6. Waly NE, Gruffydd-Jones TJ, Stokes CR, *et al.* Immunohistochemical diagnosis of alimentary lymphomas and severe intestinal inflammation in cats. *J Comp Pathol* 2005;133:253-260.
7. Moore PF, Woo JC, Vernau W, *et al.* Characterization of feline T-cell receptor gamma (TCRG) variable region genes for the molecular diagnosis of feline intestinal T-cell lymphoma. *Vet Immunol Immunopathol* 2005;106:167-178.
8. Louwerens M, London CL, Pedersen NC, *et al.* Feline lymphoma in the post-feline leukemia virus era. *J Vet Intern Med* 2005;19(4):329-335.
9. Davenport DJ, Leib NS and Roth L. Progression of lymphocytic-plasmacytic enteritis to gastrointestinal lymphosarcoma in three cats. In: *Proceedings*, Veterinary Cancer Society 7th Annual Conference: 1987 suppl.
10. Bridgeford EC, Marini RP, Feng Y, *et al.* Gastric *Helicobacter* species as a cause of feline gastric lymphoma. *Vet Immunol Immunopathol* 2008;123:106-113.
11. Bertone ER, Snyder LA, Moore AS. Environmental tobacco smoke and risk of malignant lymphoma in pet cats. *Am J Epidemiol* 2002;156(3):268-273.
12. Ruaux CG, Steiner JM, Williams DA. Early biochemical and clinical responses to cobalamin supplementation in cats with signs of gastrointestinal disease and severe hypocobalaminemia. *J Vet Intern Med* 2005;19(2):155-160.
13. Zwingenberger AL, Marks SL, Baker TW, *et al.* Ultrasonographic evaluation of the muscularis propria in cats with diffuse small intestinal lymphoma or inflammatory bowel disease. *J Vet Intern Med* 2010;24(2):289-292.
14. Scott KD, Zoran DL, Mansell J, *et al.* Utility of endoscopic biopsies of the duodenum and ileum for the diagnosis of inflammatory bowel disease and small cell lymphoma in cats. *J Vet Intern Med* 2011;25(6):1253-1257.
15. Sabattini E, Botero ME, Turba F, *et al.* Differentiating feline inflammatory bowel disease from alimentary lymphoma in duodenal endoscopic biopsies. *J Small Anim Pract* 2016;57(8):396-401.
16. Patterson-Kane JC, Kugler BP and Francis K. The possible prognostic significance of immunophenotype in feline alimentary lymphoma: a pilot study. *J Comp Pathol* 2004;130:220-222.
17. Dennis JS, Kruger JM, Mullaney TP. Lymphocytic-plasmacytic gastroenteritis in cats: 14 cases (1985-1990). *J Am Vet Med Assoc* 1992;200:1712-1718.
18. Marshall-Jones ZV, Baillon MLA, Croft JM, *et al.* Effects of *Lactobacillus acidophilus* DSM13241 as a probiotic in healthy adult cats. *Am J Vet Res* 2006;67:1005-1012.
19. Wynn SG. Probiotics in veterinary practice. *J Am Vet Med Assoc* 2009;234:606-613.
20. Trepanier L. Idiopathic inflammatory bowel disease in cats – rational treatment selection. *J Feline Med Surg* 2009;11:32-38.
21. Willard MD. Feline inflammatory bowel disease: a review. *J Feline Med Surg* 1999;1:155-164.
22. Ferguson D, Gaschen F. Feline idiopathic inflammatory bowel disease. *J Feline Med Surg* 2009;19(2):20-30.
23. Krecic MR. Feline inflammatory bowel disease: treatment, prognosis, and new developments. *Compend Contin Educ Vet* 2001;23:964-973.
24. Stein TJ, Pellin M, Steinberg H, *et al.* Treatment of feline gastrointestinal small-cell lymphoma with chlorambucil and glucocorticoids. *J Am Anim Hosp Assoc* 2010;46:413-417.
25. Wilson HM. Feline alimentary lymphoma: demystifying the enigma. *Top Comp Anim Med* 2008;23:177-184.
26. Kiselow MA, Rassnick KM, McDonough SP, *et al.* Outcome of cats with low-grade lymphocytic lymphoma: 41 cases (1995-2005). *J Am Vet Med Assoc* 2008;232(3):405-410.
27. Jergens AE. Managing the refractory case of feline IBD. *J Feline Med Surg* 2003;5:47-50.

ROYAL CANIN®

Canine pancreatitis



Melinda A. Wood, DVM, MS, Dipl. ACVIM
Royal Canin USA, St. Charles, Missouri, USA

Dr Wood received her DVM from The Ohio State University College of Veterinary Medicine in 2003. She completed an internship at Carolina Veterinary Specialists in Charlotte, NC, and an Internal Medicine residency and MS in Biomedical and Veterinary Sciences at Virginia-Maryland Regional College of Veterinary Medicine. She was in private practice for seven years before joining Royal Canin, where she is currently Scientific Affairs manager.

Craig Datz, DVM, MS, Dipl. ABVP, Dipl. ACVN
College of Veterinary Medicine, University of Missouri, Columbia, USA

A 1987 graduate of the Virginia-Maryland Regional College of Veterinary Medicine, Dr Datz has worked in both private companion animal practice and at the University of Missouri College of Veterinary Medicine; he is currently the Nutrition and Scientific Affairs manager for Royal Canin USA and also an adjunct associate professor at the University of Missouri.

Introduction

Canine pancreatitis is an inflammatory disease of the pancreas that may be acute or chronic in nature. In acute cases, there are no permanent changes to the pancreas, whereas fibrosis and atrophy of the pancreas develop in the chronic scenario (1). Despite recent advances in available analytical tests, establishing a diagnosis can be challenging.

KEY POINTS

- **Pancreatitis in dogs may be acute or chronic in nature, and although several etiological factors have been suggested, the trigger for the onset of disease is typically idiopathic.**
- **Pancreatitis develops because of premature activation of trypsinogen to trypsin within the pancreas, leading to pancreatic cell destruction. In some cases, the systemic effects can be severe and lead to multiorgan failure.**
- **The clinical signs of pancreatitis may range from mild to severe and life-threatening; the most sensitive and specific serum marker currently available is the canine pancreatic lipase immunoreactivity assay.**
- **Nutrition can play a key role in therapy; several studies have demonstrated the safety and efficacy of providing assisted enteral nutrition to dogs with pancreatitis.**

The cause for pancreatitis in an individual dog is typically idiopathic, but several risk factors have been suggested, including dietary indiscretion, obesity, and endocrine diseases such as diabetes mellitus, hyperadrenocorticism, and hypothyroidism and hypertriglyceridemia (2-5). Numerous drugs have been implicated as possible causes of pancreatitis, including potassium bromide, phenobarbital, thiazide diuretics and furosemide, L-asparginase, azathioprine and organophosphates (3,6,7), and babesiosis has also been reported to be a causative agent (7).

Several studies have shown Miniature Schnauzers and Yorkshire Terriers to be at increased risk for developing acute pancreatitis (2-4). A study of chronic pancreatitis in US dogs demonstrated an increased prevalence in toy and non-sporting breeds (8), but a UK study on the same condition reported an increased risk in Cavalier King Charles Spaniels, English Cocker Spaniels, Boxers and Collies (9).

Pathophysiology

Under normal conditions, several mechanisms protect the pancreas from autodigestion by digestive enzymes. Proteolytic enzymes synthesized within the pancreas are stored as inactive zymogens and are activated only once they have entered the duodenum. Pancreatic acinar cells synthesize and secrete pancreatic secretory trypsin

inhibitor, and plasma contains several anti-proteases which both limit intra-pancreatic proenzyme activation and inactivate proteolytic enzymes if they have been released into the circulation (7,10).

Pancreatitis develops because of premature activation of trypsinogen to trypsin within the acinar cells of the pancreas, leading to pancreatic cell destruction. Trypsin activation triggers activation of all other pancreatic zymogens, causing pancreatic autodigestion, inflammation and necrosis, as well as a systemic inflammatory reaction. In some cases, the effects can be severe and lead to multiorgan failure (7,10).

Clinical signs and diagnosis

Clinical signs of pancreatitis in dogs may range from mild to severe and life-threatening, and can include vomiting, lethargy, anorexia or decreased appetite, diarrhea and abdominal pain (8,11). Patients with chronic pancreatitis generally present with low-grade, intermittent clinical signs, although they can present acutely (1). Dogs may assume the classic "prayer" position with forelimbs extended along the ground and raised hindlimbs ***(Figure 1).*** Physical exam findings will vary depending on the severity of disease, but may include abdominal pain ***(Figure 2),*** dehydration, fever, and icterus if secondary post-hepatic bile duct obstruction is present (8,11).

Biochemical and hematologic findings in affected dogs are non-specific and can include elevated liver enzymes, hyperbilirubinemia, azotemia, hypoalbuminemia, hypocalcemia, hypokalemia, anemia, thrombocytopenia, leukocytosis and (less commonly) leukopenia (3,11). Previously, elevated serum lipase and amylase were used as markers for pancreatitis, but they are no longer recommended due to their lack of sensitivity and specificity. This is because both amylase and lipase originate from several tissues in addition to the pancreas, and traditional assays are not able to differentiate tissue of origin (12).

The canine pancreatic lipase immunoreactivity (cPLI) assay is the most sensitive and specific serum marker currently available for canine pancreatitis. Studies have evaluated the assay for detection of both clinical and histopathological pancreatitis cases, and it is notable that not all patients in the histopathological studies showed clinical signs of pancreatitis. The sensitivity of cPLI has been shown to improve in patients with moderate to severe pancreatitis. Furthermore, the assay loses specificity when a lower cut-off value (200 µg/L) is used for a positive diagnosis (12-14). A cage-side commercial assay is also available and has been shown to be highly sensitive (14); pancreatitis in dogs with a negative result on this test is unlikely.

© E McNeill/S Kellam/J Daft

Figure 1. Dogs with pancreatitis may assume the classic "prayer" position with their forelimbs extended along the ground and raised hindlimbs.

More recently, a new assay for lipase activity has been developed using the substrate 1,2-o-dilauryl-rac-glycero glutaric acid-(6'-methylresorufin) ester (DGGR) and validated in dogs (15). This assay has been shown to have high agreement with the cPLI assay (16).

Diagnostic imaging

Pancreatitis may be suspected but not definitively diagnosed, based on abdominal radiographs. Radiographic findings in affected dogs have been reported to include loss of detail or increased radio-opacity in the right cranial abdomen, displacement of the duodenum to the right or pyloric antrum to the left, and gas in the descending duodenum or transverse colon (11). However, in this

Figure 2. Physical exam findings will vary depending on the severity of the pancreatitis, but abdominal pain is often noted.

© E McNeill/S Kellam/J Daft

ROYAL CANIN®

study radiographic abnormalities suggestive of acute pancreatitis were present in only 24% of dogs with fatal acute pancreatitis.

The most commonly used diagnostic imaging tool for examining the canine pancreas is abdominal ultrasound. Changes seen ultrasonographically with acute pancreatitis include an enlarged, hypoechoic pancreas, often with hyperechoic peri-pancreatic mesentery ***(Figure 3).*** Additional abnormalities such as pancreatic pseudocysts, abscesses or masses, and peritoneal effusion may also be present (6,11,17). Hyperechoic areas within the pancreas may be seen, which could represent fibrosis (12). However, when used alone, the sensitivity of abdominal ultrasound to diagnose acute pancreatitis in dogs is generally low, reported in one study to be 68% (11).

Computed tomography (CT) is the most valuable imaging modality for diagnosing pancreatitis in people, but has been evaluated less in dogs. CT angiography findings in dogs with acute pancreatitis in a recent pilot study included an enlarged, homogeneously to heterogeneously attenuating and contrast-enhancing pancreas, with ill-defined borders in all dogs (18). Although this was a small study, the results were promising, as CT angiography allowed the entire pancreas and common bile duct to be imaged; this proved to be superior to ultrasound in some of the dogs, where superimposition of gastrointestinal gas and fluid limited the ultrasound examination.

Therapy

Because there is no specific cure, treatment is limited to supportive measures (6). The main complications of moderate to severe acute pancreatitis to be managed are anorexia, vomiting, abdominal pain, dehydration, electrolyte imbalances, and sometimes systemic inflammatory response syndrome (SIRS) (19,20). The following is a brief review of medical management and a more in-depth guide to nutritional management.

Fluid therapy

Continuous intravenous fluids are necessary for all but the mildest cases (19). Most dogs have a history of inappetence or vomiting ***(Figure 4),*** and fluids are required to restore hydration and replace electrolytes, with Lactated Ringer's (Hartmann's) solution the initial fluid of choice. Potassium supplementation may also be required. Colloids such as hydroxyethyl starch or fresh frozen plasma may be useful if there is decreased oncotic pressure (*e.g.,* with hypoalbuminemia) but animals should be monitored closely for adverse effects such as coagulopathy (19,21).

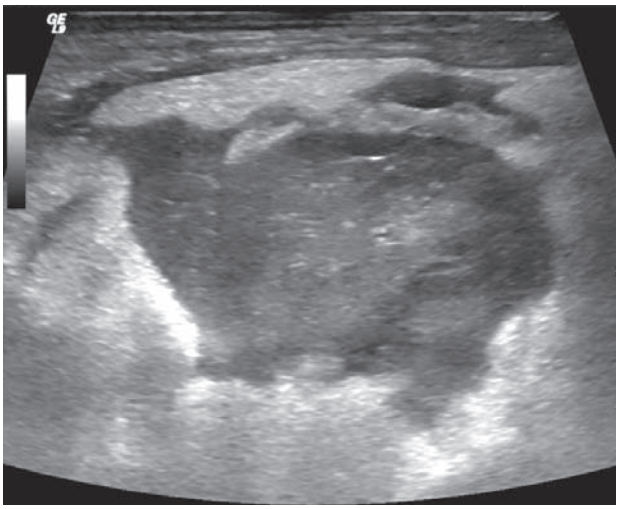

© Andrew Holdsworth/SCVS

Figure 3. Changes seen ultrasonographically with acute pancreatitis include an enlarged, hypoechoic pancreas, often with hyperechoic peri-pancreatic mesentery.

© Shutterstock

Figure 4. Most dogs with pancreatitis have a history of vomiting or inappetence.

Antiemetics

Vomiting causes significant morbidity and worsening of dehydration and acid-base/electrolyte imbalance. Newer drugs such as maropitant and serotonin receptor antagonists (ondansetron, dolasetron) are more effective than older drugs such as metoclopramide (19) in reducing the incidence of emesis.

Analgesics

Abdominal pain may be difficult to recognize in affected dogs, so analgesics should be provided for most cases. Opioids (*mu* agonists) are typically the most effective drugs at relieving abdominal pain. NMDA antagonists (*e.g.,* ketamine) and local anesthetics (*e.g.,* lidocaine) may be used as a continuous rate infusion, either alone or in combination (19).

Corticosteroids

While corticosteroids have historically been regarded as a risk factor for pancreatitis, more recent evidence suggests they are not a cause and may in fact be beneficial in treatment. Low physiologic doses of short-acting corticosteroids are occasionally used to help manage moderate to severe inflammation (SIRS) associated with pancreatitis (19).

Nutrition

Traditional recommendations for the management of acute pancreatitis in dogs included fasting to "rest the pancreas" (22). It was thought that recommending *nil per os* (NPO) for 48-72 hours (or up to 5 days of anorexia) would reduce pancreatic stimulation and excessive release of enzymes (19,22). However, the pathogenesis most likely involves intracellular activation of proteolytic enzymes rather than excessive pancreatic stimulation (6), and there are numerous adverse consequences with prolonged NPO therapy. Protein malnutrition can lead to a catabolic state and hypoproteinemia. The gastrointestinal barrier may be compromised due to a combination of decreased intestinal blood flow, villus atrophy and decreased local immunoglobulin production, which is a risk factor for bacterial translocation and SIRS. Additionally, a loss of intestinal motility or even ileus can lead to worsening of vomiting and diarrhea (6).

Several studies have demonstrated the safety and efficacy of providing assisted enteral nutrition to dogs with experimental or naturally occurring pancreatitis (23-26). Total parenteral nutrition (TPN) has also been recommended, especially in cases of severe or refractory vomiting, although it can be associated with a higher rate of complications (6). Assisted enteral feeding is less expensive, readily available in general practice, and most likely safer; support early in the disease process, rather than later, is now becoming more widely recommended (6,20,26).

Feeding tubes are available in various sizes and materials. For cases of acute pancreatitis, the most common types are nasogastric (NG) tubes and esophagostomy (E) tubes (6). NG-tubes are easy to insert without the need for sedation and can remain in place for up to 7 days, which is usually long enough to allow recovery and resumption of voluntary intake. Only liquid diets can be fed through NG-tubes, which limits the choice of products. E-tube placement requires general anesthesia and a surgical approach, and critical patients should be stabilized before being anesthetized. A variety of diets can be fed through E-tubes; most wet (canned) dog foods can be blended with water so that the consistency is thin enough to flow through the tube without clogging (27,28).

The ideal diet for supporting dogs with pancreatitis has not yet been determined. In most cases, a highly digestible fat-restricted diet is the most appropriate choice (6,19,27) as high-fat diets are a potential risk for both pancreatitis and hyperlipidemia. A commonly accepted recommendation is to select commercial canine diets that do not exceed 20 grams of fat per 1,000 kcal (approximately 7% fat on a dry matter basis) (29). Several veterinary therapeutic diets are available that are formulated for gastrointestinal disease and are also fat-restricted. However, diets that are intended for management of obesity or fiber-responsive conditions may not be appropriate, as they are not highly digestible and require larger volumes of food to meet energy requirements. Commercially available liquid diets may not be fat-restricted but can be used in NG-tubes as long as careful monitoring is done to assess for post-feeding nausea, vomiting, abdominal discomfort, or other unwanted signs (27). Low-fat liquid diets are available in some countries.

A starting point for assisted feeding (NG- or E-tube) is to calculate the resting energy requirement ***(Table 1),*** the daily amount in kilocalories appropriate for a dog recovering from illness (6,19,27,28). Dogs with mild pancreatitis often start eating voluntarily within three days of the onset of anorexia, and in such cases feeding tubes are not necessary, but a gradual return to full feeding can be achieved using these guidelines. In dogs with moderate to severe pancreatitis, enteral nutrition (placement of a feeding tube) is recommended if anorexia has persisted for three days or longer and voluntary intake is not occurring (27,28).

After recovery and discharge from the hospital, home care of patients with acute or chronic pancreatitis often includes medication and ongoing feeding of therapeutic

Table 1. Calculating the RER.

The resting energy requirement (RER) of a dog =

$$70 \times BW(kg)^{0.75}$$

A typical protocol is to give 1/3 of the calculated RER on day 1 of feeding, 2/3 of the RER on day 2, and the full RER on the third and subsequent days. For example, the RER for a 7kg dog is 301 kcal ($70 \times 7^{0.75}$), so the amount fed would be 100 kcal on day 1, 200 kcal on day 2, and 300 kcal on day 3. Note that the daily amount should be divided into several small feeds, usually 4-6 times a day.

ROYAL CANIN®

diets (1,20,27). If the dog has hyperlipidemia or is at high risk of relapse, then food should be limited to highly digestible fat-restricted diets as noted previously (27,29). Other dogs may be able to tolerate diets that are moderate in fat (up to 40 grams/1,000 kcal or 15% on a dry matter basis) but, for most cases, higher-fat diets should be avoided long term, as well as table scraps and treats that contain excessive dietary fat.

References

1. Watson P. Chronic pancreatitis in dogs. *Top Comp Anim Med* 2012;27(3):133-139.
2. Lem KY, Fosgate GT, Norby B, *et al.* Associations between dietary factors and pancreatitis in dogs. *J Am Vet Med* Assoc 2008;233(9):1425-1431.
3. Cook AK, Breitschwerdt EB, Levine JF. Risk factors associated with acute pancreatitis in dogs: 101 cases (1985-1990). *J Am Vet Med Assoc* 1993;203(5):673-679.
4. Hess RS, Saunders HM, Van Winkle TJ, *et al.* Evaluation of risk factors for fatal acute pancreatitis in dogs. *J Am Vet Med Assoc* 1999;214(1):46-51.
5. Xenoulis PG, Suchodolski JS, Ruaux CG, *et al.* Association between serum triglycerides and canine pancreatic lipase immunoreactivity concentrations in Miniature Schnauzers. *J Am Anim Hosp Assoc* 2010;46:229-234.
6. Jensen KB, Chan DL. Nutritional management of acute pancreatitis in dogs and cats. *J Vet Emerg Crit Care* 2014;24(3):240-250.
7. Kalli I, Adamama-Moraitou K, Rallis TS. Acute pancreatitis in dogs: a review article. *Eur J Comp Anim Prac* 2009;19(2):147-155.
8. Bostrom BM, Xenoulis PG, Newman SJ, *et al.* Chronic pancreatitis in dogs: a retrospective study of clinical, clinicopathological, and histopathological findings in 61 cases. *Vet J* 2013;195(1):73-79.
9. Watson PJ, Roulois AJ, Scase T, *et al.* Prevalence and breed distribution of chronic pancreatitis at post-mortem examination in first-opinion dogs. *J Small Anim Pract* 2007;48:609-618.
10. Mansfield C. Pathophysiology of acute pancreatitis: potential application from experimental models and human medicine to dogs. *J Vet Intern Med* 2012;26(4):875-887.
11. Hess RS, Saunders HM, Van Winkle TJ, *et al.* Clinical, clinicopathologic, radiographic, and ultrasonographic abnormalities in dogs with fatal acute pancreatitis: 70 cases (1986-1995). *J Am Vet Med Assoc* 1998;213(5):665-670.
12. Xenoulis PG. Diagnosis of pancreatitis in dogs and cats. *J Small Anim Pract* 2015;56(1):13-26.
13. Trivedi S, Marks SL, Kass PH, *et al.* Sensitivity and specificity of canine pancreas-specific lipase (cPL) and other markers for pancreatitis in 70 dogs with and without histopathologic evidence of pancreatitis. *J Vet Intern Med* 2011;25(6):1241-1247.
14. McCord K, Morley PS, Armstrong J, *et al.* A multi-institutional study evaluating the diagnostic utility of the spec cPL™ and SNAP® cPL™ in clinical acute pancreatitis in 84 dogs. *J Vet Intern Med* 2012;26(4):888-896.
15. Graca R, Messick J, Minter H, *et al.* Validation and diagnostic efficacy of a lipase assay using the substrate 1,2-o-dilauryl-rac-glycero glutaric acid-(6'-methylresorufin)-ester for the diagnosis of acute pancreatitis in dogs. *Vet Clin Pathol* 2005;34(1):39-43.
16. Kook PH, Kohler N, Hartnack S, *et al.* Agreement of serum Spec cPL with the 1,2-o-dilauryl-rac-glycero glutaric acid-(6'-methylresorufin) ester (DGGR) lipase assay and with pancreatic ultrasonography in dogs with suspected pancreatitis. *J Vet Intern Med* 2014;28(3):863-870.
17. Van Enkevort BA, O'Brien RT, Young KM. Pancreatic pseudocysts in 4 dogs and 2 cats: ultrasonographic and clinicopathologic findings. *J Vet Intern Med* 1999;13(4):309-313.
18. Adrian AM, Twedt DC, Kraft SL, *et al.* Computed tomographic angiography under sedation in the diagnosis of suspected canine pancreatitis: a pilot study. *J Vet Intern Med* 2015;29(1):97-103.
19. Mansfield C, Beths T. Management of acute pancreatitis in dogs: a critical appraisal with focus on feeding and analgesia. *J Small Anim Pract* 2015;56:27-39.
20. Ruaux CG. Treatment of canine pancreatitis. In Bonagura JD, Twedt DC, eds. *Kirk's Current Veterinary Therapy XV.* St. Louis: Elsevier Saunders, 2014;561-565.
21. Gauthier V, Holowaychuk MK, Kerr CL, *et al.* Effect of synthetic colloid administration on coagulation in healthy dogs and dogs with systemic inflammation. *J Vet Intern Med* 2015;29:276-285.
22. Simpson KW. Diseases of the pancreas. In: Tams TR. *Handbook of Small Animal Gastroenterology* 2nd ed. Philadelphia: Saunders, 2003;363-364.
23. Qin HL, Su ZD, Hu LG, *et al.* Parenteral versus early intrajejunal nutrition: effect on pancreatitic natural course, entero-hormones release and its efficacy on dogs with acute pancreatitis. *World J Gastroenterol* 2003;9:2270-2273.
24. Qin HL, Su ZD, Hu LG, *et al.* Effect of parenteral and early intrajejunal nutrition on pancreatic digestive enzyme synthesis, storage and discharge in dog models of acute pancreatitis. *World J Gastroenterol* 2007;13:1123-1128.
25. Mansfield CS, James FE, Steiner JM, *et al.* A pilot study to assess tolerability of early enteral nutrition via esophagostomy tube feeding in dogs with severe acute pancreatitis. *J Vet Intern Med* 2011;25:419-425.
26. Harris JP, Parnell NK, Saker KE. Evaluating the impact of early-targeted nutrition on clinical outcomes for dogs with severe acute pancreatitis. *J Anim Physiol Anim Nutr (Berl)* 2014;98:1189.
27. Villaverde C. Nutritional management of exocrine pancreatic diseases. In: Fascetti AJ, Delaney SJ, eds. *Applied Veterinary Clinical Nutrition.* West Sussex, UK: Wiley-Blackwell, 2012;221-233.
28. Larsen JA. Enteral nutrition and tube feeding. In: Fascetti AJ, Delaney SJ, eds. *Applied Veterinary Clinical Nutrition*. West Sussex, UK: Wiley-Blackwell, 2012;329-352.
29. Xenoulis PG, Steiner JM. Lipid metabolism and hyperlipidemia in dogs. *Vet J* 2010;183:12-21.

Feline esophagitis

Toshihiro Watari, BVSc, MVSc, PhD
College of Bioresource Sciences, Nihon University, Japan

Dr Watari qualified from the Graduate School of Veterinary Medicine, Nippon Veterinary and Zootechnical College (current Nippon Veterinary and Life Science University) in 1986 and is currently professor of Veterinary Internal Medicine at Nihon University. His particular interests are gastrointestinal endoscopy and hematology.

Introduction

Although feline esophagitis is not an uncommon condition, it is often missed because of its typically non-specific or subclinical presentation. Mild esophagitis is usually self-limiting, but an esophageal stricture may develop secondary to severe esophagitis, resulting in obstruction of the passage of food. Once formed, strictures require treatment by endoscopic balloon dilation or other invasive methods, and it is therefore best to treat esophagitis in the early phases wherever possible. Knowledge of the underlying anatomical features and the risk factors that predispose a cat to esophagitis is essential to better managing this underdiagnosed condition.

KEY POINTS

- **Feline esophagitis may be subclinical in nature or can often cause non-specific clinical signs; it is probably underdiagnosed in general practice.**
- **The most common etiology appears to be gastroesophageal reflux, which may be exacerbated by general anesthetic. Tetracycline antibiotics have also been shown to cause esophagitis.**
- **Treatment is based on drug therapy to inhibit gastric acid secretion and promote gastric emptying.**
- **Sustained or severe esophagitis and the resulting fibrotic changes can lead to formation of an esophageal stricture. Such strictures are best treated by endoscopic balloon dilation.**

Anatomy of the esophagus

The esophagus is the hollow tube that transports food from the pharynx to the stomach. It runs alongside the trachea from the pharynx to the thoracic inlet and then traverses the mediastinum before passing through the diaphragm to enter the stomach. The esophagus has four physiologically normal constrictions; at its origin in the pharynx, at the thoracic inlet, at the level of tracheal bifurcation, and at the esophageal hiatus where it passes through the diaphragm.

The esophageal wall consists of the innermost mucosal epithelia, the lamina propria, the muscularis mucosa, the submucosa, and the two outermost layers of muscle fibers. In dogs, the muscular coat is composed of striated muscle throughout the entire length of the esophagus. In cats, the esophagus has both striated and smooth muscle; the proximal two-thirds are composed of striated muscle, while the distal third is composed of smooth muscle. Consequently, the distal portion of the feline esophagus (caudal to the base of the heart) has circular mucosal folds ***(Figure 1),*** which can be seen to form a characteristic "herringbone" pattern on contrast radiography. This difference in musculature explains why dogs with megaesophagus typically fail to respond to prokinetic drugs, while these agents may be successful in inducing distal esophageal motility in cats with the same disorder.

Etiology of esophagitis

The most common cause of esophagitis appears to be gastroesophageal reflux, with exposure to gastric secretions causing damage to the esophageal mucosa. In particular, reflux may occur during general anesthesia, and it has been suggested that relatively little contact time (20 minutes or longer) is required for stomach acid to raise the risk of esophagitis. Gastroesophageal reflux can also occur secondary to hiatal hernia ***(Figure 2)*** where displacement of the cranial part of the stomach into the thorax reduces the pressure on the cardia and allows

ROYAL CANIN®

reflux of gastric juices. Another major risk factor in cats is administration of tetracyclines, which can adhere to the esophageal lining when administered without adequate water, leading to esophagitis; owners should be informed of this risk when such medications are prescribed. Mechanical injury of the mucosa from esophageal foreign bodies is another possible etiology, although this is more commonly seen in dogs.

Clinical signs and diagnosis

Non-specific signs such as anorexia and hypersalivation are primary signs of esophagitis. However, mild esophagitis may be asymptomatic and can go unnoticed by the owner until a stricture forms and causes regurgitation. Given the non-specific presentation, esophagitis should be suspected and included in the differential diagnosis list whenever vomiting/regurgitation, inappetence, and/or hypersalivation are noted, and the probability is increased if the cat has a history of previous anesthetic procedures, oral antibiotic use (and in particular tetracyclines), and/or is prone to possible foreign body ingestion.

Hematology and serum biochemistry are usually normal in affected animals unless there is severe inflammation. Plain radiography may reveal retention of air within the esophagus, and contrast radiography is rarely diagnostic unless mucosal inflammation is very severe. Currently, esophagoscopy is the most important and reliable method of evaluating suspected esophagitis. This allows visualization of any inflammation within the esophagus and lesions can be easily biopsied for histopathology. It is worth noting that healthy esophageal mucosa is very firm and difficult to grasp using biopsy forceps. In humans, differentiation between esophagitis and esophageal cancer is essential at this point, but it is not usually necessary in cats, as esophageal tumors are very rare in this species. However, if neoplasia is suspected, biopsy is recommended for histopathological evaluation.

Treatment

The treatment for esophagitis is based on minimizing reflux by inhibiting gastric acid secretion and promoting gastric emptying. H_2 blockers and proton pump inhibitors are used to inhibit acid secretion, while prokinetic agents (such as dopamine D_2 receptor antagonists and serotonin 5-HT_4 receptor agonists) can be used to encourage stomach emptying. Additionally, mucosal protective agents such as sucralfate may be employed to support the esophageal endothelium, and antibiotics should be prescribed if severe infection secondary to inflammation is suspected. A percutaneous endoscopic

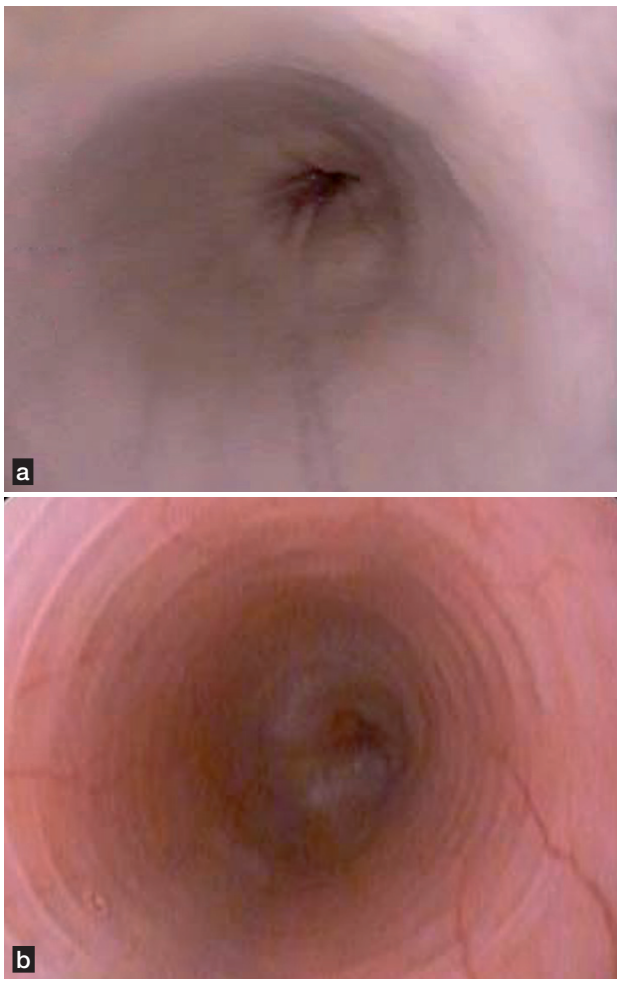

© Toshihiro Watari

Figure 1. An endoscopic comparison of the distal esophagus of the dog **(a)** and cat **(b).** The striations are clearly visible in the latter photo.

Figure 2. An endoscopic view of esophagitis in a cat secondary to hiatal hernia.

© Toshihiro Watari

gastrostomy (PEG) tube should be considered for cases where there has been prolonged esophagitis. If esophagitis is secondary to hiatal hernia, surgery is indicated to restore the normal anatomy.

Esophagitis must be treated as early as possible, as prolonged inflammation can cause an esophageal stricture secondary to scar tissue formation. Some practitioners opt to use proton pump inhibitors or prokinetic agents prophylactically before any anesthetic procedure in cats to prevent reflux esophagitis. Alternatively, sucralfate suspension may be administered after anesthetic induction to provide protection against any refluxed gastric contents.

Esophageal stricture

It is not uncommon for severe or prolonged esophagitis and the resulting fibrotic changes to lead to an esophageal stricture in cats. As the treatment for an esophageal stricture can be both lengthy and costly, it is essential to emphasize that wherever possible early detection and effective treatment of esophagitis is desirable before there is progression to a stricture. Efforts should always be made to prevent recurrence in any cat that has had esophagitis previously. As noted above, because tetracycline antibiotics can be a common cause of esophagitis, they can also predispose to stricture formation, and it is imperative that owners are advised to administer such medications with water or food.

Clinical signs and diagnosis

Regurgitation of food, often immediately after eating, is commonly seen once an esophageal stricture develops ***(Box 1).*** Depending on the width of the stricture, cats may only regurgitate solid foodstuffs and tolerate water or liquid diets. Anorexia is rare. If an esophageal stricture is suspected, contrast thoracic radiography should be performed; diagnosis is based on stenosis of the esophageal lumen and distention proximal to the site of stenosis. Note that stenosis should not be confused with the physiologically normal narrowing of the esophagus associated with peristalsis. If a stenosis is not clearly observed with liquid barium but a stricture is still suspected, the contrast agent may be mixed with food to make a thick gruel in order to facilitate radiographic diagnosis.

Subsequent esophagoscopy aids the diagnosis and allows treatment at the same time. In kittens which start to regurgitate solid food at the time of weaning, or in young cats where there is no history of antibiotic therapy, a vascular ring anomaly must be included as a possible cause, and esophagoscopy may aid in making a definitive diagnosis. With a vascular ring anomaly, the esophagus is entrapped by the great arteries in the thorax and the lumen of the esophagus will appear to be compressed externally on endoscopy. With a stricture secondary to esophagitis, there will be no indication of extraluminal compression ***(Figure 3).*** When a vascular ring anomaly is suspected, contrast computed tomography (if available) can aid diagnosis, as it will allow imaging of the esophagus and the surrounding vasculature.

Treatment

Removal of the stricture is the only option where clinical signs persist. Potential treatments include surgical resection

Figure 3. Esophageal compression caused by a vascular ring anomaly **(a)** and secondary esophageal stricture **(b)** viewed endoscopically.

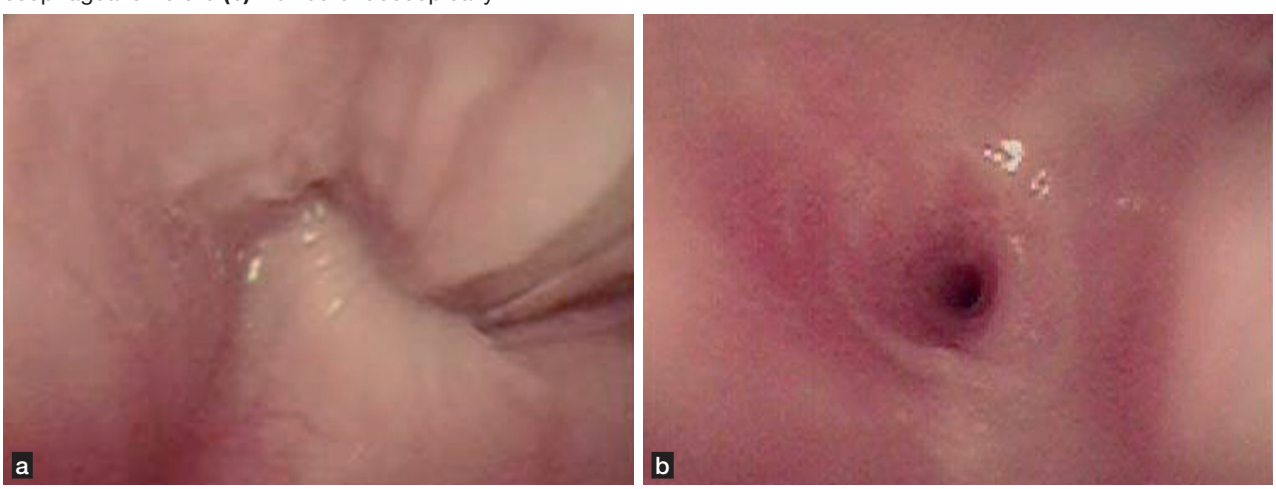

© Toshihiro Watari

ROYAL CANIN®

Box 1. Case study.

A 3-month-old female domestic shorthair kitten was referred with the presenting sign of regurgitation shortly after eating. The kitten had been rescued two months earlier and adopted by the current owner. Regurgitation of food, but not milk, started soon after an oral antibiotic had been prescribed by a local veterinarian for conjunctivitis.

Contrast thoracic radiography demonstrated esophageal narrowing at the level of the base of the heart and distention of the esophagus proximal to this point ***(Figure 1).*** Endoscopy revealed a stricture approximately 14 cm from the proximal end of the esophagus ***(Figure 2);*** the luminal diameter at the site of the stricture was 2 mm. The treatment of choice was balloon dilation via esophagoscopy, using an 8-mm balloon. After inflation, the balloon was kept in place for 3 minutes and then deflated; the luminal diameter was judged to be satisfactory on visual evaluation ***(Figure 3).*** After recovery from anesthesia, sucralfate suspension, antibiotics, famotidine and mosapride citrate were administered. A second endoscopy two weeks later confirmed the luminal diameter at the site of the stricture remained at 8 mm, and no further treatment was necessary.

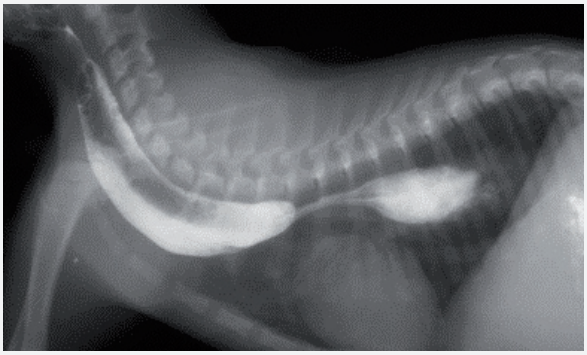

© Toshihiro Watari

Figure 1. Contrast thoracic radiography can be employed to diagnose an esophageal stricture; note the extreme dilation of the esophagus proximal to the stricture.

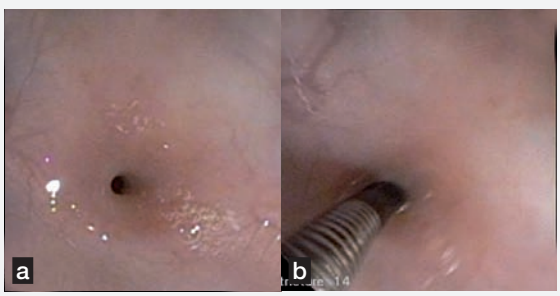

© Toshihiro Watari

Figure 2. Endoscopic appearance of an esophageal stricture **(a).** The diameter of the esophagus at the site of the stricture as measured with forceps was 2 mm **(b).**

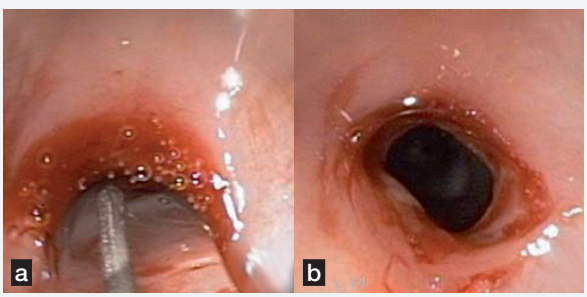

© Toshihiro Watari

Figure 3. The stricture during **(a)** and after **(b)** balloon dilation; note the diameter of the lumen post-treatment compared to that shown in **Figure 2a.**

of the stricture, bougienage, and endoscopic balloon catheter dilation. Partial esophagectomy is not always successful, as there is an increased risk of anastomotic dehiscence due to the relatively poor vascularization of the esophagus. There is also the risk that the stricture may reform following surgery. Bougienage carries a risk of esophageal perforation, as it is typically performed without endoscopic guidance, and it is difficult to confirm whether the dilator is correctly positioned at the site of the stricture.

Endoscopic balloon catheter dilation is a safer choice and allows visualization of balloon placement within the stricture ***(Box 2).*** In addition, outward expansion of the narrowed segment is unlikely to cause perforation. A balloon dilator can be inserted through the instrument channel of the endoscope if the channel diameter is sufficiently large. This option is not always possible with cats, as a small endoscope may be required, and in this situation the alternative is to carefully advance the catheter alongside the endoscope. Once the tip of the

catheter reaches the site of the stricture, the middle of the balloon is positioned near the center of the stricture, and the balloon filled with water using a special inflation syringe ***(Figure 4).*** This is essential as the integrated pressure gauge on the syringe permits the operator to judge the optimal pressure required for inflation of the balloon. Based on the type of balloon catheter system used, the author prefers to keep the balloon *in situ* for three minutes once it has been inflated to the recommended pressure before removing the water and deflating and retracting the dilator. The process ruptures the esophageal mucosa and exposes the submucosal tissue; although this causes new inflammation at the site of the stricture, this can be controlled by effective drug therapy. Successful resolution of the stricture usually requires multiple balloon dilations; the author prefers to repeat the procedure at 14-day intervals until the luminal diameter is large enough to allow easy passage of the endoscope ***(Box 2).*** If a stricture reforms post-dilation (most commonly due to the associated inflammation), the cat may benefit from PEG tube feeding; the patient can be allowed to swallow water and sucralfate suspension but the PEG tube helps to prevent further damage to the esophageal mucosa from the passage of food.

Box 2. A review on the use of balloon dilation for feline esophageal stricture.

Seven cases of feline secondary esophageal stricture diagnosed at the author's university are summarized in the table below. Except for one cat that was six years of age at presentation, all the cats were two years or younger; there was no sex predilection. All cats presented with regurgitation; six of the cats had a stricture in the thoracic esophagus and one cat had a cervical esophageal stricture. The strictures varied from 2-5 mm in diameter. Dilation was performed using 5.5-6.0 mm endoscopes and an 8-mm balloon. In all cases, the inflated balloon was held in place for three minutes, with sucralfate applied locally before the cat recovered from anesthesia. Post-dilation medical therapy included oral sucralfate, antibiotics, famotidine, metoclopramide, and mosapride citrate. In all cases, a satisfactory outcome was obtained after a maximum of three dilations, with no sign of stricture reformation, except the 6-year-old cat with cervical esophageal involvement which required 17 dilation procedures before the problem resolved.The cause of the stricture was attributed to chronic vomiting in three cats and antibiotic treatment in two cases. The remaining two cats did not have a history of vomiting, antibiotic therapy or anesthetic procedures, and the cause was not determined. The results suggest that endoscopic confirmation of diagnosis and balloon dilation are favorable approaches for esophageal stricture secondary to esophagitis. Clients should be informed that multiple procedures (at least three, but possibly more than ten, times) may be necessary for satisfactory long-term improvement. In terms of prevention, owners should be made aware that a cat with frequent vomiting risks reflux esophagitis, and educated to ensure adequate water intake if administering antibiotics.

A summary of seven cats with esophageal stricture treated by endoscopic balloon dilation.

Case number	Age	Sex	Site of lesion*	Stricture diameter	No. of dilations performed
1	1 year	M/N	T	4 mm	2
2	3 months	F	T	2 mm	1
3	5 months	M	T	4 mm	3
4	6 years	M/N	C	5 mm	17
5	2 months	F	T	2 mm	2
6	2 years	F	T	2 mm	2
7	2 years	M	T	3 mm	3

*C = cervical esophagus; T = thoracic esophagus.

ROYAL CANIN®

Table 1. Common drugs and dosages for treating feline esophagitis.

Drug name	Mode of action	Dose	Comments
Famotidine	H_2 blocker	0.1-0.2 mg/kg PO, IV Q12-24 h	Reduce dose by 50% in animals with renal impairment
Omeprazole	Proton pump inhibitor	0.7-1 mg/kg PO, Q24 h	Do not crush enteric-coated tablets or capsules. Increased benefit may be seen dosing at 1 mg/kg Q12 h
Metoclopramide	D_2 antagonist	0.2-0.5 mg/kg PO, Q8 h	Extrapyramidal reactions can be seen if D_2 receptor is intensely inhibited
Mosapride citrate	5-HT_4 agonist	0.25-1 mg/kg PO, Q12 h	Not available in all countries
Sucralfate	Forms a chemical diffusion barrier	0.25-0.5 g per cat PO Q8-12 h	Any other medications should be administered two hours before sucralfate; concurrent administration may result in absorption of other drugs being inhibited

Post-dilation medical therapy includes sucralfate suspension, gastric acid secretory inhibitors, and prokinetic agents similar to the management of esophagitis ***(Table 1).*** Appropriate antibiotics should also be administered.

Conclusion

Feline esophagitis is often underdiagnosed unless there are overt clinical signs. Prophylactic sucralfate, gastric acid secretory inhibitors and promotility drugs should be considered for cats with known risk factors for esophagitis. Cats presenting with regurgitation should undergo contrast radiography and/or endoscopy for definitive diagnosis, and balloon dilation is the preferred treatment if a stricture is confirmed.

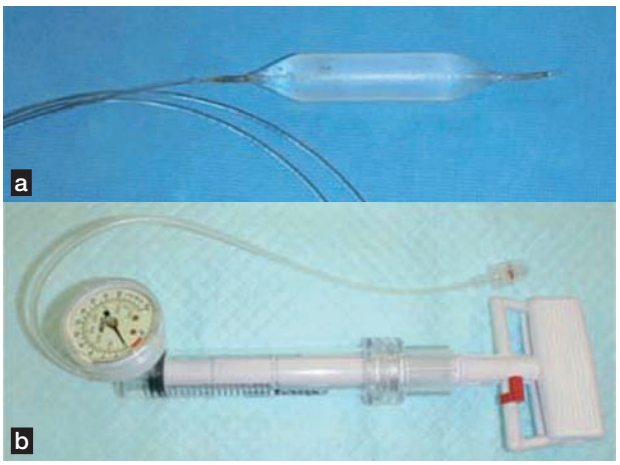

© Toshihiro Watari

Figure 4. Equipment for treating strictures; balloon dilators **(a)** and inflation syringe **(b).**

Further reading

- Gaschen F. Disorders of esophageal, gastric and intestinal motility in cats. In: Little (ed). *August's Consultations in Feline Internal Medicine* Vol 7. St. Louis: Elsevier, 2016;117-128.
- Washabau RJ. Regurgitation. In: Washabau and Day (eds). *Canine and Feline Gastroenterology.* St. Louis: Elsevier, 2013;157-161.
- Washabau RJ, Venker-van-Haagen A, Sherding RG, *et al.* The esophagus. In: Washabau and Day (eds). *Canine and Feline Gastroenterology.* St. Louis: Elsevier, 2013;570-605.
- Sherding RG and Johnson SE. Esophagoscopy. In: Tams and Rawlings (eds). *Small Animal Endoscopy* 3rd Ed. St. Louis: Elsevier, 2011;41-95.

Canine protein-losing enteropathies

Rance Sellon, DVM, Dipl. ACVIM (Internal Medicine and Oncology)
Washington State University (WSU) College of Veterinary Medicine, Pullman, USA

Dr Sellon graduated from the Texas A&M University College of Veterinary Medicine in 1987 and is currently an associate professor at WSU. He is board-certified in the specialties of Small Animal Internal Medicine and Oncology, although he has very broad clinical interests.

Introduction

Protein-losing enteropathy (PLE) reflects a collection of gastrointestinal (GI) diseases characterized by enteric loss of proteins, principally albumin, but also globulins in some cases. Enteric protein loss in dogs can occur through any segment of the GI tract, but oral cavity and esophageal diseases are rare causes of PLE. Disease of the stomach and colon can occasionally cause PLE, but chronic diseases of the small intestine are the most common reasons. This article will provide an overview of the clinical features, diagnostic and treatment considerations for the most common etiologies of canine small intestinal PLE ***(Table 1)*** but more detailed information for many of the individual causes of PLE can be found elsewhere (1).

KEY POINTS

- **Protein-losing enteropathies (PLE) cause enteric protein loss, principally albumin, and most often reflect small intestinal disease.**
- **Clinical signs of PLE usually result from intestinal dysfunction (vomiting, diarrhea, weight loss) and/or hypoalbuminemia (body cavity effusion, peripheral edema).**
- **Dogs without signs of gastrointestinal (GI) disease can have a PLE, but other causes of hypoalbuminemia should be excluded before pursuing GI disease.**
- **Definitive diagnosis of common causes of PLE requires intestinal biopsy.**
- **Diet and immunosuppressive drugs play an important role in the management of dogs with PLE not attributed to neoplastic disease.**

Signalment and clinical features

Any dog can develop a PLE, but several breeds, including Yorkshire Terriers, Rottweilers, Wheaten Terriers, Norwegian Lundehunds, and German Shepherds are predisposed. Canine PLE may develop at any age, and the clinical signs can be variable, although weight loss (which may be seen with a normal or decreased appetite), vomiting and/or diarrhea are commonly noted. Some dogs develop hematemesis or melena if proximal GI tract bleeding occurs. In patients exhibiting diarrhea, features usually, but not always, localize diarrhea to the small intestine. However, not all patients with a PLE exhibit vomiting and/or diarrhea, so the absence of these signs should not lessen the suspicion of a PLE if other clinical aspects are consistent. Some owners will report abdominal distension (from ascites) or peripheral edema, or changes in respiratory rate or character (from pleural effusion) as the primary clinical sign. Occasional patients with a PLE are diagnosed after hypoalbuminemia is found incidentally on a serum biochemical profile and other causes of hypoalbuminemia have been excluded. Uncommonly, seizures secondary to hypocalcemia may be seen (2).

Physical examination abnormalities in dogs with PLE are also variable. Poor body condition could be expected in animals that have experienced weight loss. Peripheral edema, abdominal distension, and a palpable fluid wave are possible in patients with severe hypoalbuminemia. In some cases, there may be thickened loops of bowel or intestinal masses, so a careful and thorough abdominal palpation is a critical component of the physical examination, especially when abdominal effusion is absent. A rectal examination may reveal enlarged sublumbar lymph nodes in dogs with GI lymphoma or other infiltrative GI disease. Melena, which can also be detected by a rectal examination, can be a feature of some dogs with bleeding upper GI tract lesions.

ROYAL CANIN®

Diagnostic considerations

Laboratory tests

A common approach to the patient with clinical signs consistent with a PLE would be to perform a fecal flotation, or empirically deworm with a broad-spectrum anthelmintic, and obtain a complete blood count (CBC), serum biochemical profile, and urinalysis. CBC results will vary depending on the underlying cause of the PLE. Inflammatory leukograms are possible with any of the diseases associated with inflammation (*e.g.,* inflammatory bowel disease [IBD], neoplasia), but will not be present in all patients. Peripheral eosinophilia may be seen; hypereosinophilia, likely a paraneoplastic phenomenon, has been described in association with canine GI lymphoma. Anemia can be a consequence of chronic inflammation, or acute or chronic GI hemorrhage. There may be features of iron deficiency (microcytosis, hypochromasia) if the cause of PLE itself instigates chronic, low-grade GI hemorrhage. Attention should be paid to the leukogram, because absence of a stress leukogram may suggest hypoadrenocorticism, a cause of PLE infrequently considered by many clinicians (see below). Lymphopenia is variably present in dogs with intestinal lymphangiectasia (IL). Platelet counts may be normal or increased (due to chronic inflammation), but thrombocytopenia would be unusual in most causes of PLE.

The hallmark features of a PLE on a serum biochemical profile are hypoalbuminemia with or without hypoglobulinemia; note that hyperglobulinemia can be seen in some cases. Hypocholesterolemia is common in dogs with IL, but can be seen with other causes of PLE; hypoadrenocorticism is also an important differential for hypocholesterolemia. Hypocalcemia may be noted; this can be a consequence of hypoalbuminemia, or a true hypocalcemia secondary to mucosal disease. An ionized calcium (iCa) assay can clarify if a low total serum calcium level reflects hypoalbuminemia (*i.e.,* iCa will be normal), or a true hypocalcemia (low iCa). Increases in liver enzymes may be seen in some dogs.

A urinalysis, while not often giving specific information regarding the nature of the PLE, helps exclude urinary albumin loss as a cause of, or contributor to, hypoalbuminemia. Proteinuria can be seen in certain breeds (such as Wheaten Terriers) known to develop concurrent PLE and protein-losing nephropathy. A urinalysis is important when investigating hypoalbuminemic patients that have no signs of GI tract disease and those that do not have hypoglobulinemia; globulins are not typically lost in the urine as they are generally too large to pass through the glomerulus. In the absence of proteinuria, evidence of abnormal liver function (elevated bile acids, blood ammonia concentrations) or third-space losses (exudative effusions, edema from vasculitis) as a cause of hypoalbuminemia, the default explanation becomes enteric loss, and a PLE should be suspected even if signs of GI disease are absent.

Table 1. Select causes of canine PLE.

• **GI parasitism (*e.g.,* hookworms, schistosomiasis)**
• **Idiopathic inflammatory GI tract disease** - Lymphoplasmacytic enteritis - Eosinophilic enteritis - Granulomatous enteritis
• **Infectious GI tract disease** - Histoplasmosis - Histiocytic ulcerative colitis *(E. coli)* - Pythiosis
• **Primary intestinal lymphangiectasia**
• **Neoplastic GI tract disease** - Lymphosarcoma - Adenocarcinoma - Spindle cell tumors
• **GI ulceration** - Drugs (NSAID's, glucocorticoids) - Neoplasia (as above) - Hypergastrinemic/hyperhistaminemic syndromes
• **Hemorrhagic gastroenteritis**
• **Chronic obstruction (*e.g.,* foreign body, intussusception)**
• **Hypoadrenocorticism**
• **Portal hypertension (uncommon)**

When dogs develop body cavity effusions secondary to PLE, the fluid type is expected to be a pure transudate, a consequence of hypoalbuminemia and low oncotic pressure. Pure transudates in such cases are very low in protein, often < 1.0 g/dL (10 g/L), have low nucleated cell counts, and can look like water. Dogs with a pure transudate and serum albumin concentrations greater than 1.5 g/dL (15 g/L) should arouse suspicion of a sinusoidal or presinusoidal portal vein abnormality, such as a portal vein thrombus, as pure transudates are not expected when serum albumin concentrations are above this level. Portal vein thrombi have been described in dogs with PLE (3).

Measurement of cobalamin is encouraged in animals suspected of having a PLE, as serum cobalamin concentrations can be low secondary to malabsorption. Measurement of

canine pancreatic lipase (cPLI) should be performed if pancreatitis is a consideration; a negative result makes pancreatitis less likely.

The possibility that hypoadrenocorticism can resemble PLE has already been noted, and should be considered as a possible cause for PLE (4). Common findings in such cases include weight loss, poor body condition, a history of intermittent, often chronic, vomiting and/or diarrhea, hypoalbuminemia and hypocholesterolemia. The absence of a stress leukogram, notably an absence of lymphopenia, is a significant finding in affected dogs. Note that there may not be the classic electrolyte abnormalities of hyponatremia and hyperkalemia, which can make suspicion of hypoadrenocorticism difficult. Because of the potential for unnecessary diagnostic intervention for a dog with hypoadrenocorticism, or the administration of excessive doses of glucocorticoids if empirically treating for IBD, the author proposes that a basal cortisol be done in a PLE candidate if there is no evidence of a stress leukogram; if the basal cortisol is < 2 µg/dL (< 55 nmol/L), an ACTH stimulation test should be performed before pursuing other diagnostic options.

Diagnostic imaging

Abdominal imaging can be useful in the approach to a patient with a PLE. Plain abdominal radiography is often not as helpful as ultrasonography, but can help rule out some GI foreign bodies that occasionally cause PLE-like presentations as a result of chronic obstruction. In some patients, an intestinal mass, or evidence of small intestinal dilation suggestive of obstruction, may be appreciated on plain radiography if there is sufficient serosal detail. However, such detail is often poor in PLE patients because of loss of intra-abdominal fat or abdominal effusion. Contrast radiography may exclude or suggest obstructive disease, ulcerative lesions, or masses with more confidence than plain radiographs.

Abdominal ultrasonography is the author's preferred imaging modality for dogs with features of PLE (5) and the results can help decide if GI biopsy is appropriate and what method (endoscopic vs. surgical) is preferred; evidence for a jejunal lesion, or a disease that appears focal and potentially amenable to surgical resection, would suggest surgery rather than endoscopic evaluation and biopsy. Ultrasonographic abnormalities consistent with PLE can include bright mucosal striations perpendicular to the long axis of the intestine; these may be dilated villus lacteals which can be typical of, but not specific for, IL ***(Figure 1).*** Thickening of the intestinal wall, thickened muscularis (more common with lymphoma than other causes), loss of normal wall layering, dilation of bowel segments (obstructive disease), or masses (tumors, foreign bodies) are also possible findings. While not pathognomic, loss of wall layering is highly correlated with neoplastic GI disease. Enlarged mesenteric lymph nodes may be seen, and ultrasound-guided aspirates may allow diagnosis of large-cell/high-grade GI lymphoma or histoplasmosis. Abnormally small adrenal glands are suggestive of hypoadrenocorticism if other features of the disease are present.

Some limits of abdominal ultrasonography are worth pointing out. Firstly, lesions may not be seen, or can be misinterpreted by the ultrasonographer. The author has seen patients with intestinal obstructions (foreign bodies, focal tumors) that were not noted, or were interpreted as reflecting an abnormality in a different organ/tissue, by board-certified radiologists. Secondly, ultrasonographic images do not provide a cytological or histological diagnosis, so the nature of any ultrasonographic lesion must be confirmed by sampling for cytology or histopathology.

Biopsy findings

Definitive diagnosis of the common causes of PLE requires an intestinal biopsy of adequate quality. Intestinal biopsies can be obtained via endoscopy, or acquired surgically via laparotomy or with laparoscopic assistance. Note hypoalbuminemia is not an absolute contraindication to surgical biopsies – studies have not demonstrated an increased likelihood of intestinal dehiscence in such patients – but the low oncotic pressure can make anesthetic and perioperative management more challenging than with endoscopy.

Figure 1. Ultrasonographic image of the small intestine of a dog with confirmed intestinal lymphangiectasia. Note the vertical striations in the mucosa.

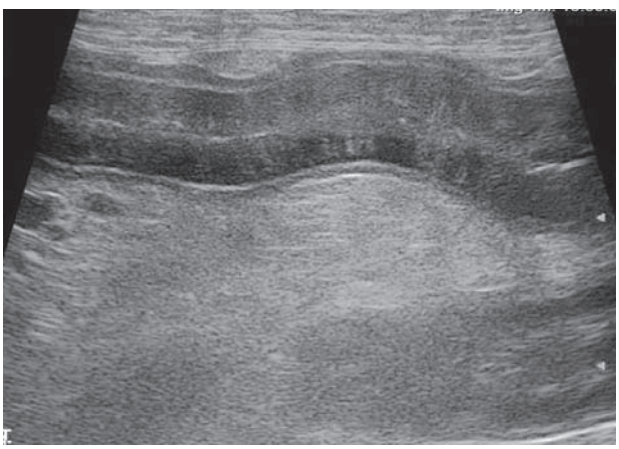

© Rance Sellon

ROYAL CANIN®

Gross endoscopic findings in the duodenum can be suggestive of IL if dilated lacteals, which often appear as white dots/villus tips in the duodenal mucosa, are observed ***(Figure 2).*** Prominent villus tips can be seen with lymphocytic/plasmacytic enteritis or GI lymphoma. Ulcerative lesions of the stomach and duodenum can also be appreciated during endoscopic examination. If an exploratory laparotomy is performed, IL may be suggested if lymphatic vessels are visualized on the serosal surface of the GI tract or within the mesentery. Small nodules, often characterized histologically as lipogranulomas, may be seen on the serosal surface of the intestine or interspersed along the mesenteric lymphatic vessels. Some dogs will have accumulations of gritty material in the intestinal serosa ***(Figure 3).*** Biopsies of duodenum, jejunum and ileum, and enlarged lymph nodes (if found) should be obtained during surgery.

To be of adequate quality, endoscopic biopsies should span villus tip to submucosa and contain several villi. Including crypt epithelium in the sample is important, as some lesions of PLE are more prominent in the crypts than in the villi. If adequate quality biopsies of representative lesions are submitted for microscopic examination, a histologic diagnosis that fits the clinical picture is expected for most patients. The most common histologic diagnoses for dogs with PLE are IBD, IL and GI lymphoma, but other causes are possible ***(Table 1).***

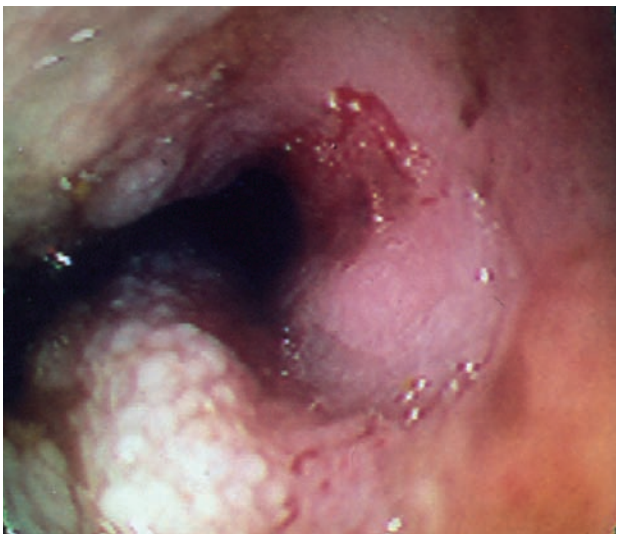

© Rance Sellon

Figure 2. Endoscopic image of the duodenum of a dog with confirmed intestinal lymphangiectasia. Note the row of prominent white villus tips extending distally from the bottom of the image.

© Rance Sellon

Figure 3. Prominent serosal lymphatic vessels in a dog with intestinal lymphangiectasia. These vessels would feel chalky or gritty due to inflammatory changes in the lymphatics.

Treatment

Treatment will be dictated by the underlying cause. For dogs with focal lesions (*e.g.,* foreign bodies, tumors), the treatment will be surgical intervention, possibly followed by chemotherapy if appropriate (*e.g.,* intestinal lymphoma). Treatment of IBD and IL typically involves diet changes and administration of immunomodulatory drugs. Currently, there is no consensus as to the "best" drug therapy for these diseases, although prednisone is widely accepted as a reasonable starting point for most. ***Table 2*** details drugs and dosages that have been reported as beneficial in dogs with IBD or IL (1,6,7); prednisone can be combined with other drugs if a patient does not respond to a single agent.

Alterations in diet (such as novel proteins and hydrolyzed protein diets) are an important factor when treating both IBD and IL. Foods restricted in fats can be helpful, as patients with PLE often have a degree of fat malassimilation; this seems especially true of patients with IL (8). Some patients with PLE will do well without drugs if fed an appropriate diet, although this can take some trial and error. A strategy that the author has used with some success in patients that have not responded to other treatment approaches (other diets, drugs) is to feed a two-ingredient diet using a novel protein and novel carbohydrate. Owners boil, bake, or braise the two ingredients without any other additive (*e.g.,* spices, oils); if a clinical response is appreciated (often within 10-14 days in the author's experience), then consultation with a nutrition service is recommended to ensure a balanced diet for long-term feeding.

Table 2. Drugs commonly used in the treatment of IBD or IL.

Prednisone	1-2 mg/kg PO Q12 h initially, with 20-25% dose reductions every 2-3 weeks if desired clinical response achieved
Azathioprine	1-2 mg/kg PO Q24 h for 10-14 days, then Q48 h indefinitely; monitor CBC for neutropenia, thrombocytopenia and biochemical profile for liver enzymes (especially ALT)
Cyclosporine	5 mg/kg PO Q24 h; if no response, considering therapeutic drug monitoring to determine if a dose increase is appropriate
Chlorambucil	4 to 6 mg/m^2 PO Q24 h for 7-21 days, then increase dose interval based on clinical signs and hematologic tolerance

For patients with cobalamin deficiencies, supplementation is indicated. A recent paper (9) demonstrated that oral cobalamin supplementation in dogs with chronic enteropathy is effective in normalizing serum cobalamin concentrations; subcutaneous administration of cobalamin is still an acceptable route of administration. Because cobalamin is extremely safe – the author is not aware of toxicity associated with cobalamin administration – empirically treating a PLE patient with cobalamin is, in the author's opinion, a reasonable consideration that will lessen the expense associated with monitoring responses to cobalamin supplementation.

Treatment of GI lymphoma is typically based on administration of chemotherapeutic drugs. Consultation with a veterinary oncologist is recommended to choose a protocol that best suits the needs of both patient and client. At a minimum, administration of prednisone alone can be considered and may improve clinical signs for a time in some dogs.

Summary

In summary, PLE should be suspected in any dog with hypoalbuminemia, with or without vomiting or diarrhea, if other causes of hypoalbuminemia have been excluded. Remember that hypoadrenocorticism can look like PLE, so obtain a basal cortisol in PLE-like dogs that have no stress leukogram. Abdominal imaging and intestinal biopsy play important roles in the diagnostic approach to PLE candidates, and diet and immunosuppressive drugs are cornerstones of treatment for IBD and IL. Ultimately, it is essential to emphasize that the prognosis for a dog with PLE is variable and reflects the underlying disease.

References

1. Dossin O, Lavoué R. Protein-losing enteropathies in dogs. *Vet Clin Small Anim* 2011;41:399-418.
2. Whitehead J, Quimby J, Bayliss D. Seizures associated with hypocalcemia in a Yorkshire Terrier with protein-losing enteropathy. *J Am Anim Hosp Assoc* 2015;51:380-384.
3. Respess M, O'Toole TE, Taeymans O, *et al.* Portal vein thrombosis in 33 dogs: 1998-2011. *J Vet Intern Med* 2012;26:230-237.
4. Lyngby JG, Sellon RK. Hypoadrenocorticism mimicking protein-losing enteropathy in 4 dogs. *Canadian Vet J* 2016;57:757-760.
5. Gaschen L. Ultrasonography of small intestinal inflammatory and neoplastic diseases in dogs and cats. *Vet Clin Small Anim* 2011;41:329-344.
6. Allenspach K, Rüfenacht S, Sauter S, *et al.* Pharmacokinetics and clinical efficacy of cyclosporine treatment of dogs with steroid-refractory inflammatory bowel disease. *J Vet Intern Med* 2006;20:239-244.
7. Dandrieux JRS, Noble P-JM, Scase TJ, *et al.* Comparison of a chlorambucil-prednisolone combination with an azathioprine-prednisolone combination for treatment of chronic enteropathy with concurrent protein-losing enteropathy in dogs: 27 cases (2007-2010). *J Am Vet Med Assoc* 2013;242:1705-1714.
8. Okanishi H, Yoshioka R, Kagawa Y, *et al.* The clinical efficacy of dietary fat restriction in treatment of dogs with intestinal lymphangiectasia. *J Vet Intern Med* 2014;28:809-817.
9. Toresson L, Steiner JM, Suchodolski JS, *et al.* Oral cobalamin supplementation in dogs with chronic enteropathies and hypocobalaminemia. *J Vet Intern Med* 2016;30:101-107.
10. Goodwin LV, Goggs R, Chan DL, *et al.* Hypercoagulability in dogs with protein-losing enteropathy. *J Vet Intern Med* 2011;25:273-277.
11. Simmerson SM, Armstrong PJ, Wünschmann A, *et al.* Clinical features, intestinal histopathology, and outcome in protein-losing enteropathy in Yorkshire Terrier dogs. *J Vet Intern Med* 2014;28:331-337.

ROYAL CANIN®

Prevalence of chronic gastrointestinal signs in cats

Emi Saito, VMD, MSPH, MBA, Dipl. ACVPM (Epidemiology)

Dr Saito qualified from the Veterinary Faculty at the University of Pennsylvania in 1997 and joined Banfield's Applied Research and Knowledge (BARK) team in 2013 after several years working for US Government departments as an epidemiologist.

Silke Kleinhenz, BA

Silke Kleinhenz has degrees in Marketing and Advertising and worked as a report writer for the anesthesiology department at Oregon Health Sciences University before joining Banfield in 2013; she now works as part of the BARK team as a senior data analyst.

Introduction

Many owners will consider their cat's vomiting or diarrhea to be "normal" – some clients may not even report it when asked "anything going on at home?" – but because of the many potential causes of chronic gastrointestinal (GI) signs (1-3), it is important to ask owners specifically about the occurrence of vomiting and diarrhea, including characteristics such as frequency, appearance, and consistency, as well as at-home care and health, and to assess appropriateness of diagnostic work-up (*e.g.,* bloodwork, ultrasound). This paper examines the prevalence of chronic vomiting and diarrhea in adult cats in the United States.

Methods of analysis

The health records of all cats aged 12 months and above when presented to a Banfield Pet Hospital from January 1, 2008 through December 30, 2012 for a veterinarian consultation were screened to identify those whose owners reported chronic (*i.e.,* at least 1 month duration) vomiting or diarrhea. The cases were categorized clinically as follows: Chronic diarrhea only – no vomiting within 30 days of the visit; Chronic vomiting only – no diarrhea within 30 days of the visit; and both chronic diarrhea and vomiting – with both conditions recorded within 30 days of each other. Because some cats may have presented multiple times over the study period with different clinical signs, they may be included in more than one case category. Cats that were diagnosed during the same calendar year with hairballs or GI parasites were excluded from the survey.

The prevalence of these signs was estimated and classified by age; young adult (1-3 years of age), mature (3-10 years) and geriatric (10-25 years), with any cat recorded as older than 25 years omitted, as this was a likely indication of inaccurate recording of birth date. Prevalence and relative risk (RR; estimated by the prevalence ratio) of each of the clinical presentations of chronic GI signs were estimated, comparing mature and geriatric adults relative to young adults.

Results

During the study period, over 1 million adult cats visited Banfield Pet Hospital ***(Table 1):*** of these around 2.0% (21,142) were reported to have chronic vomiting and/or diarrhea. Cats more commonly presented with chronic vomiting only (14,039), followed by chronic diarrhea only (4,469). Approximately 1,967 cats (9.3%) presented with more than one clinical sign during the study (*e.g.,* chronic vomiting only and then presenting more than 30 days later with chronic diarrhea only). In all categories, young adult cats consistently had lower prevalence than the mature and geriatric cats. Risks for chronic GI signs in mature and geriatric adults ***(Table 2)*** are significantly greater when compared to young adults, with geriatric cats far more likely to develop chronic GI signs compared to young adults. Across all case categories, mature adults had 1.4-4.0 times the risk and geriatric cats 3.1-18.5 times the risk of young adult cats.

Discussion

Our findings are consistent with other reports that note chronic enteropathy is more common in older cats (2).

Table 1. A breakdown of the total number of affected cats presenting with chronic GI signs (vomiting and/or diarrhea) between 2008-2012. Some cats will have appeared in more than one clinical category and/or age range during the 5-year study period.

Age group	Number of adult cats seen	Total number of affected cats	Chronic vomiting only	Chronic diarrhea only	Both chronic vomiting and diarrhea
Young adult	376,576	2,528 (0.7%)	1,411 (0.4%)	904 (0.2%)	75 (0.0%)
Mature adult	514,082	8,099 (1.6%)	5,579 (1.1%)	1,731 (0.3%)	414 (0.1%)
Geriatric adult	256,214	10,728 (4.2%)	7,177 (2.8%)	1,882 (0.7%)	943 (0.4%)
Total	1,041,887	21,142 (2.0%)	14,039 (1.4%)	4,469 (0.4%)	1,426 (0.1%)

Table 2. Risk ratios of mature and geriatric adult cats with chronic vomiting and/or chronic diarrhea, relative to young adults. 95% confidence intervals for the risk ratios are shown in parentheses.

Age group	Total number of affected cats	Chronic vomiting only	Chronic diarrhea only	Both chronic vomiting and diarrhea
Mature adult	2.4 (2.2-2.5)	2.9 (2.7-3.0)	1.4 (1.3-1.5)	4.0 (3.2-5.2)
Geriatric adult	6.2 (6.0-6.5)	7.5 (7.1-7.7)	3.1 (2.9-3.2)	18.5 (14.6-23.4)

The prevalence estimates of chronic GI signs reported here are likely underestimates of the true level of occurrence, given the likelihood of under-reporting of the condition by the owner and/or veterinary staff.

A cursory examination of the medical diagnoses for a selection of affected cats from the study suggests that diagnostics beyond a minimum database (*i.e.,* complete blood count, chemistry panel, thyroid) may not have been performed in many cases. After chronic kidney disease and hyperthyroidism, the most common diagnoses were (non-specific) vomiting, gastritis, enteritis and gastroenteritis. This may in part reflect a lack of concern about the clinical signs and need for diagnostic evaluation or, alternatively, the financial burden to definitively identify an underlying etiology.

This analysis found that although the prevalence of chronic GI signs was not very high, they were not uncommon in a population of adult cats seen at primary veterinary practices. Given that there are a number of potential causes for chronic enteropathy in cats, including parasites, neoplasia, and food intolerance, it is important for the clinician to delve deeper into client-reported clinical signs to ensure early disease detection and optimum health management of the cat, including other diagnostics, proper medications and dietary changes, in order to improve the quality of life for both the cat and the owner.

References

1. Batchelor DJ, Devauchelle P, Elliott J, *et al.* Mechanisms, causes, investigation and management of vomiting disorders in cats: a literature review. *J Feline Med Surg* 2013;15:237-265.
2. Marsilio S, Steiner J. Feline chronic enteropathies. *Eur J Comp Anim Pract* 2015;25:78-93.
3. Zoran DL. Vomiting cat cases: you can figure them out. Critical Updates on Canine & Feline Health. In: *Proceedings* NAVC/WVC 2015;10-18.

ROYAL CANIN®

Gastrointestinal endoscopy in dogs

Franck Jolivet, DVM
Ecole Vétérinaire de Toulouse (ENVT), Department of Clinical Sciences, University of Toulouse, France

After graduating from the University of Toulouse in 2013 and completing a rotating internship in Small Animal Medicine and Surgery, Dr Jolivet worked as a clinical assistant at the university before commencing a residency in Small Animal Internal Medicine; he is currently studying for the ECVIM diploma.

Olivier Dossin, DVM, PhD, Dipl. ECVIM-CA (Internal Medicine)
Ecole Vétérinaire de Toulouse (ENVT), Department of Clinical Sciences and Institut de Recherche en Santé Digestive (IRSD ; INSERM, INRA, ENVT, UPS), University of Toulouse, France

Olivier Dossin received his veterinary medicine degree from the Veterinary School of Toulouse. He worked for some 15 years as a faculty member at the veterinary school before moving to the University of Illinois for 3 years. He is currently an associate professor in Small Animal Internal Medicine at the Veterinary School of Toulouse, with a focus on gastrointestinal medicine.

Introduction

Endoscopy is a versatile and minimally invasive technique used to visualize the gastrointestinal (GI) lumen, perform biopsies for further analysis such as histopathology or bacterial analysis, and to deliver treatment for problems such as strictures, polyps or foreign body removal. Although complications of routine endoscopic procedures are rare (1), endoscopy must be performed after a thorough work-up and should never be a substitute for a complete history, physical examination, appropriate laboratory procedures and other diagnostic imaging. It is especially important to note that endoscopy and endoscopic biopsy are not always indicated, especially in animals with chronic GI disease, without appropriate therapeutic trials (*e.g.,* deworming, dietary modification, antimicrobial trial). In conjunction with other diagnostic modalities, endoscopy can be both a powerful diagnostic tool for many GI disorders in dogs and an invaluable therapeutic tool, particularly for the retrieval of gastric or esophageal foreign bodies.

This article will consider the benefits of endoscopy in dogs using five case studies. Interventional endoscopy and laparoscopy are beyond the scope of this paper.

KEY POINTS

- **Endoscopy is a safe and effective tool in canine gastroenterology, but it is only one component of the diagnostic work-up and should be used only when appropriately indicated.**
- **Bi-directional endoscopy is always recommended when investigating dogs with chronic intestinal disease.**
- **The clinician should decide if surgical or endoscopic biopsies are preferable for each case.**
- **It is essential to take an adequate number of endoscopic biopsies in order to ensure an accurate histopathological diagnosis.**

Endoscopic equipment

Standard GI videoendoscopy equipment consists of a flexible endoscope, a light source, a videoprocessor, a monitor and an air pump; a videorecording system is frequently connected to the system (2,3). A variety of instruments and accessories are also available, including biopsy forceps, cytology brushes, aspiration/injection needles and foreign body forceps/baskets (4). The main considerations when choosing an endoscope are its length, the outer diameter of the scope, and the diameter of the accessory channel. In dogs, a scope of 8-9 mm diameter and 100-140 cm in length is the most versatile for routine GI endoscopy (2,5), although in the largest breeds this might be too short to pass the ileo-colonic

sphincter or the pylorus. It is usually better to select a scope with an accessory channel with a 2.8 mm diameter, which will accept the largest biopsy forceps; this enables a better biopsy quality.

Endoscopic findings should be recorded (ideally including pictures) immediately after the procedure, and standardized reporting forms have been recently proposed (see: www.wsava.org/guidelines/gastrointestinal-guidelines).

Esophageal endoscopy

Indication and patient preparation

The clinical signs of esophageal disease include regurgitation, dysphagia, hypersalivation, coughing, anorexia, and halitosis. Esophageal endoscopic examination should only be performed after obtaining a thorough history, physical examination, thoracic radiographs (including contrast studies if appropriate), and (where indicated) fluoroscopic examination (6). Esophageal endoscopy, sometimes with biopsy, can offer additional information for the diagnosis of foreign bodies ***(Box 1),*** strictures ***(Box 2),*** esophagitis, granuloma associated with *Spirocera lupi,* and neoplasia. The healthy esophagus is usually very difficult to biopsy and, in general, if samples can be taken easily it means that the esophageal mucosa is abnormal. Esophageal endoscopy requires general anesthesia (ideally after 8-12 hours fasting), with the patient in left lateral or sternal recumbency. If motility is impaired, such that there is retention of food within the esophagus, a 24-hour fast (or even esophageal lavage after tracheal intubation) may be required to permit successful endoscopy.

Contrast studies, especially using barium, should be avoided before endoscopy because this may impair visualization of the mucosa. If such studies are performed, endoscopy must be postponed for at least 24 hours.

Esophageal endoscopy is best undertaken with a flexible scope; rigid endoscopes may be used to remove large foreign bodies, but increase the risk of esophageal perforation and do not allow for extensive esophageal inspection.

Case 1

An 11-month-old male Pug dog was referred for acute anorexia and regurgitation that had developed 3 days previously. Physical examination and bloodwork were unremarkable. Thoracic radiography identified an unusual opacity in the distal esophagus, strongly suggestive of a bony foreign body ***(Figure 1).*** Endoscopy revealed the esophagus to be dilated at the thoracic inlet, with a large bone embedded into the esophageal wall just cranial to the cardia ***(Figure 2).*** Despite altering the patient's position several times, a prolonged endoscopic session failed to retrieve the foreign body, which was eventually pushed into the stomach. Subsequent endoscopic inspection revealed no gastric abnormalities, but considering the severe necrotic ulcerative esophageal lesions and the high risk of esophageal perforation, a gastrotomy was performed only two days later to retrieve the bone. Treatment with omeprazole, sucralfate, antibiotic and methylprednisolone was then administered for 10 days. A postoperative stricture was considered a possible complication, and if clinical signs had persisted a further endoscopic

Box 1. Esophageal foreign bodies in dogs.

Esophageal foreign bodies (FB) are frequent in dogs and are genuine emergencies. Rapid intervention is necessary because of the risk of severe complications; the longer a FB remains within the esophagus, the greater the risk. Diagnosis is usually via a combination of history, physical examination (drooling, anorexia, regurgitation of saliva) and thoracic radiography. Severe esophagitis can produce gagging or regurgitation/vomiting, and respiratory complications such as aspiration pneumonia or pneumothorax may be present. The FB is located within the thoracic esophagus in the vast majority of cases, but abdominal radiography should always be performed to evaluate the rest of the GI tract. Endoscopic retrieval is the preferred method and is curative in 68-90% of cases, but if not successful the FB can usually be pushed into the stomach and surgically removed. However, if there is a risk of esophageal tear or where perforation has already occurred, esophagotomy is preferred, despite a higher risk of complications. During retrieval, it can help to change the dog's position, but, in general, if endoscopic retrieval is not successful after 60-90 minutes it is probably wise to consider a surgical alternative. Complication of endoscopic retrieval (usually in around 10% of cases) include esophagitis and stricture formation, esophageal perforation and even laceration of adjacent organs such as the aorta, with bones most likely to cause complications. Dogs with more severe esophagitis after removal, or weighing < 10 kg, have a higher rate of complication, but surgical intervention has a higher complication rate than endoscopic retrieval.

Further reading: Gianella P, Pfammatter NS, Burgener IA. Oesophageal and gastric endoscopic foreign body removal: complications and follow-up of 102 dogs. *J Small Anim Pract* 2009;50:649-654.

ROYAL CANIN®

evaluation would have been undertaken, but recovery was uneventful and one year later the dog remained well.

Case 2

A 9-month-old neutered female Labrador was referred with a history of chronic (one month) regurgitation/vomiting of food, invariably a few minutes after ingestion. Hypersalivation and severe weight loss over the last month were also reported. The dog's appetite was good but she was unable to keep food down. The dog had been spayed one week before clinical signs appeared. On physical examination, her body condition score was 2/9, with moderate muscle atrophy and dehydration evaluated at 8%. The dog had ptyalism, and palpation of the ventral neck was painful. Bloodwork revealed minor hyperproteinemia, hypernatremia and hypochloremia, compatible with regurgitation/hypersalivation. Radiography showed the rostral half of the thoracic esophagus to be dilated ***(Figure 3).*** With the dog anesthetized and in left lateral recumbency, endoscopy revealed a severe esophageal stricture ***(Figure 4),*** possibly secondary to gastroesophageal reflux during the recent anesthetic episode. The tip of the scope could not be passed through the stricture, but the lesion was successfully dilated using a balloon passed through the scope and inflated with water ***(Figure 5).*** Caudal to the stricture, severe multifocal ulceration was noted ***(Figure 6)*** but no abnormalities were seen within the stomach. In all, three balloon dilations (at intervals of 5-6 days) were required to obtain satisfactory resolution of the stricture. After the second dilation, fluoroscopy with a barium meal was performed: esophageal motility was normal with moist food, whereas a dry food bolus could not pass the stricture without the dog swallowing water. No gastroesophageal reflux was observed during fluoroscopy. Omeprazole, sucralfate and methylprednisolone were prescribed between each stricture dilation and for two weeks after the last treatment. Three months after the last dilation, the patient was doing well and had gained weight, but only moistened kibble was tolerated, with dry kibble inducing regurgitation.

Box 2. Esophageal strictures in dogs.

Clinical signs of esophageal strictures are regurgitation of food, usually shortly after ingestion, sometimes associated with halitosis and ptyalism. Anorexia is rare unless odynophagia is present. Esophageal strictures develop as a complication of esophagitis, especially with gastroesophageal reflux (GER) during anesthesia, but also from esophageal FB retrieval or as a complication of esophageal surgery. Diagnosis is via plain or contrast radiography or by endoscopy. Treatment options include dilation under fluoroscopic or endoscopic guidance; dilation can be performed with a water-inflated balloon or with bougienage, but the latter option is more traumatic than the former. Following dilation triamcinolone can be injected via an endoscopic needle into the esophageal wall to help prevent recurrence, along with antibiotics, proton pump inhibitors and gastric protectants. Stenting has recently been proposed as an option for refractory strictures. Drugs such as omeprazole or esomeprazole can be used to increase the pH of the gastric contents in an attempt to prevent esophagitis and stricture formation secondary to general anesthesia. Fasting for too long before surgery has been associated with increased GER, suggesting that the ideal pre-operative fasting is 8-12 hours.

Further reading: Adamama-Moraitou KK, Rallis TS, Prassinos NN, Galatos AD. Benign esophageal stricture in the dog and cat: a retrospective study of 20 cases. *Can J Vet Res* 2002;66:55-59.

Figure 1. Thoracic radiography of **Case 1** outlined a radio-opaque foreign body in the distal esophagus.

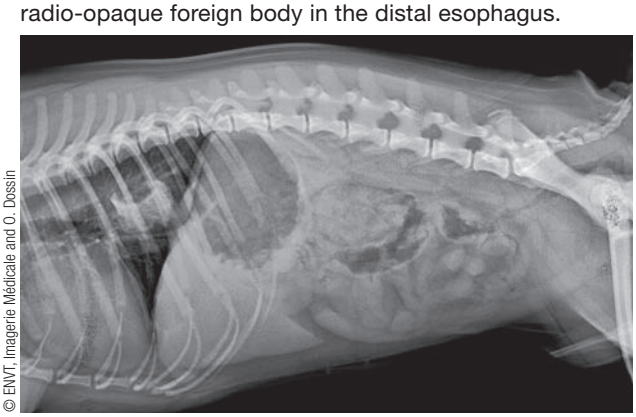

© ENVT, Imagerie Médicale and O. Dossin

Figure 2. Esophageal endoscopy of **Case 1** revealed a large bone just rostral to the cardia.

© ENVT, O. Dossin

Gastric endoscopy

Indication and patient preparation

Clinical signs of gastric disease include vomiting, hematemesis, anorexia, nausea, halitosis and/or melena. Gastric endoscopy is particularly recommended for patients with chronic GI disease, but may also be indicated if an acute problem such as a gastric foreign body or ulceration is suspected (7). During the procedure, and especially when there are chronic GI signs, duodenal endoscopy should also be performed. For most cases with chronic vomiting, duodenal (rather than gastric) endoscopy and biopsy will actually provide the diagnosis. Gastric endoscopy with biopsy can typically assist in the diagnosis of gastritis, neoplasia, chronic hypertrophic gastropathy, and ulcers, but (as previously mentioned) endoscopy should only be performed after a thorough work-up. Endoscopy can also enable foreign body retrieval and removal of polyps, or assist in placement of a feeding tube. Endoscopy requires general anesthesia (again ideally after fasting for at least 8-12 hours, and sometimes up to 24-36 hours if delayed gastric emptying is suspected), with the dog placed in left lateral recumbency for the procedure. Contrast studies, especially if using barium, must be performed at least 24-36 hours before endoscopy, as barium can impair visualization of the mucosa and also damage the scope. If necessary, abdominal radiography can be performed before endoscopy to evaluate for residual barium. The main limitation of gastric endoscopy is that it cannot diagnose submucosal disease and GI motility disorders. In addition, the size or shape of some foreign bodies can mean that endoscopic retrieval is impossible, and removal of large trichobezoars can also be very prolonged using a scope; in such cases, surgical removal may be a rational alternative.

Case 3

A 12-year-old intact female Shih Tzu was referred with a history of vomiting daily for the last 9 months, unresponsive to empirical treatment (deworming, antibiotics, dietary trials, gastric protectants). Physical examination revealed a low body condition score (2/9) and 10% body weight loss over the last 3 months. Blood chemistry, CBC, urinalysis, cPL test, fecal parasite screening and thoracic radiography revealed no abnormalities, but folate and cobalamin were both severely decreased (folate was 2.59 ng/mL (reference interval: 5-12) and cobalamin < 150 ng/L (RI: 250-800)). Severe thickening of the gastric wall was noted on abdominal ultrasound, with a focal reaction in the mesenteric fat ***(Figure 7).*** Ultrasound-guided fine-needle aspiration of the stomach wall revealed a neutrophilic inflammation. Given the strong suspicion of neoplasia, gastric endoscopy was performed. The esophagus, stomach fundus and the greater curvature were normal, but the lesser curvature and the antrum were rigid and did not dilate on insufflation; there was no ulceration. The severity of the changes to the antrum meant that the scope could not be passed through the pylorus ***(Figure 8).*** Histopathology revealed a gastric adenocarcinoma with a very poor prognosis, and the dog was euthanized a few days later ***(Box 3).***

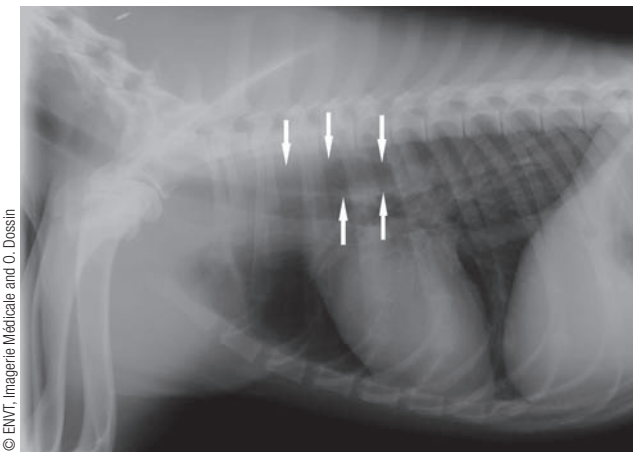

© ENVT, Imagerie Médicale and O. Dossin

Figure 3. Thoracic radiography of **Case 2.** The dilated air-filled esophagus can be easily seen in the cranial mediastinum (arrows), suggesting esophageal obstruction.

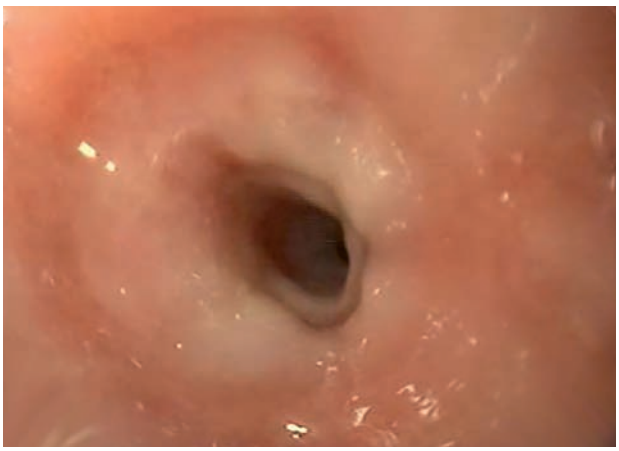

© ENVT, O. Dossin

Figure 4. Esophageal endoscopy of **Case 2** revealed a severe stricture with narrowing of the esophageal lumen.

Duodenal/ileal endoscopy

Indication and patient preparation

Clinical signs of small intestinal disease include chronic or recurrent vomiting and/or diarrhea, abdominal pain, weight loss, GI bleeding (hematemesis, melena or anemia) or irregular appetite. After excluding systemic disease for dogs with weight loss and chronic diarrhea and/or vomiting, the decision to perform endoscopic examination (8) is based on:

ROYAL CANIN®

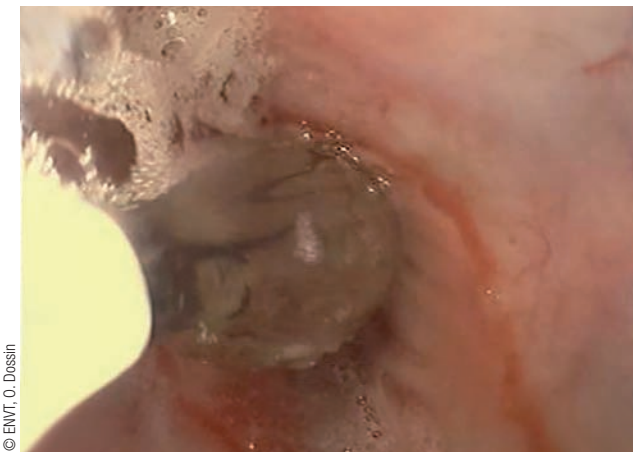

© ENVT, O. Dossin

Figure 5. Ballon dilation was used in **Case 2** to treat the stricture.

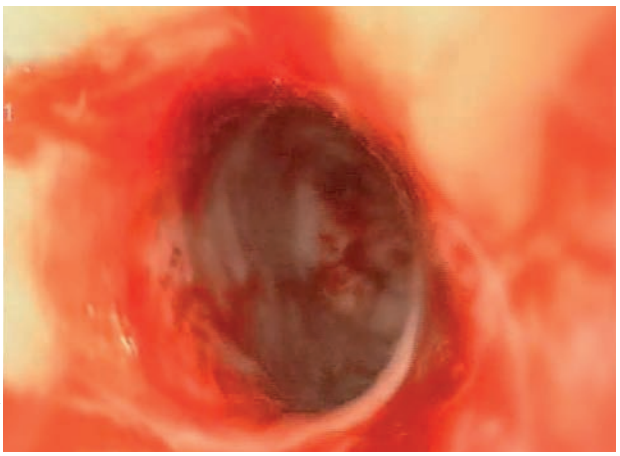

© ENVT, O. Dossin

Figure 6. Endoscopic evaluation of **Case 2** after dilation revealed severe multifocal ulceration.

- The severity of the clinical signs, or if there is GI bleeding
- A non-response to empirical treatment (deworming, dietary modifications, antibiotic trial)
- Laboratory test results (hypoalbuminemia, positive fecal α1-antiprotease, low-serum cobalamin and/or folate with normal TLI)
- Abdominal ultrasound findings (intestinal wall changes or intestinal hyperechoic mucosal striations in a hypoalbuminemic dog (9))

Surgical (rather than endoscopic) biopsy may be a better option for diagnosis in some cases, especially if abdominal ultrasound reveals a focal intestinal disease in a segment that cannot be reached by the scope, or if abnormalities are detected deep into the mucosa. Although the least invasive method for obtaining intestinal biopsies, there are certain situations where endoscopy may be contraindicated: *e.g.,* severe clinical conditions such as hypovolemia, hypotension or coagulopathy, or where the patient is at increased risk for anesthesia. In these cases, depending on the clinician's assessment, medical treatment may be employed to stabilize the patient and endoscopic examination can be delayed. Again, endoscopy should only be performed after a thorough work-up including ultrasound, fecal parasite screening, blood samples (including TLI, folate and cobalamin levels) and urinalysis. The two main limitations are that endoscopic biopsies are superficial and can only diagnose conditions affecting the mucosa, and that it can be difficult to pass the pylorus or the ileocolic sphincter in some patients. An "up-and-down" endoscopic approach is now recommended for dogs with chronic GI disease which require intestinal biopsies, because some diseases processes, including inflammation and lymphangiectasia, can be heterogeneously distributed along the small intestine (10,11). Recent studies have defined the minimal number of adequate endoscopic biopsies necessary to reach a diagnosis (12-14) ***(Table 1).*** Duodenal/ileal endoscopy requires general anesthesia, and the dog should be fasted for 8-12 hours beforehand and placed in left lateral recumbency; ileoscopy requires a longer fasting period and the preparation employed for colonoscopy (see below) should be followed.

Case 4

A 10-year-old female Border Collie was referred with chronic (3 months) mixed bowel diarrhea, with no response to empirical treatment. Other than a low body condition score, clinical examination was unremarkable. Blood samples revealed hypoalbuminemia (13.3 g/L (23-39)), hypomagnesemia (0.15 mmol/L (0.7-1.0)) and hypocobalaminemia (84 ng/L (200-800)). Bile acid tests, CBC, urinalysis, clotting panel, fecal parasite screening, and thoracic radiography did not reveal any abnormalities. On

Figure 7. Abdominal ultrasonography of **Case 3.** Note the severely thickened gastric wall.

© ENVT, Imagerie Médicale and O. Dossin

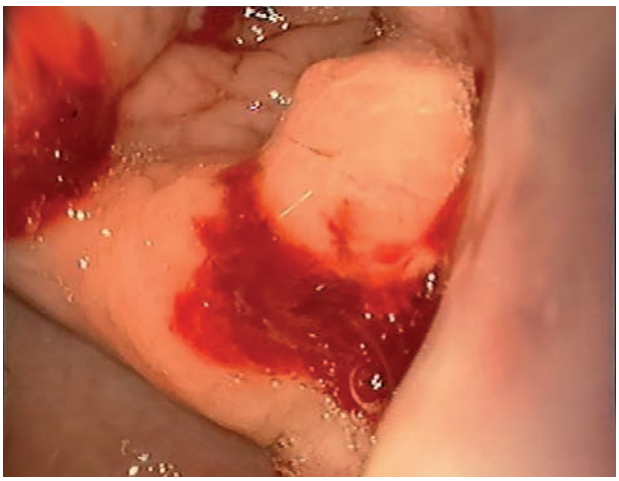

© ENVT, O. Dossin

Figure 8. Case 3: Endoscopy revealed changes suggestive of gastric cancer. Note the polypoid, thickened angular notch, with post-biopsy bleeding.

ultrasound, gastric motility was noted to be abnormal. Considering the severe hypoalbuminemia, bi-directional endoscopy (gastro-duodeno-ileo-colonoscopy) was performed after correcting the hypomagnesemia. Colonic endoscopy was normal. The scope was passed successfully through the ileocolic valve and revealed prominent villi, strongly suggestive of lacteal dilation ***(Figure 9).*** The esophagus and stomach were normal but the duodenal mucosa was friable, again with prominent villi. Biopsies were taken from all GI segments, revealing moderate duodenal inflammation and lymphangiectasia and severe changes in the ileum ***(Box 4).*** Prednisolone and metronidazole, combined with cobalamin supplementation and a hypoallergenic diet, were initiated. The dog showed both clinical and biochemical improvements within a few days; treatment was withdrawn after six weeks without recurrence of clinical signs.

Colonic endoscopy

Indication and patient preparation

Clinical signs of colonic disease include especially signs of large bowel diarrhea, *e.g.,* diarrhea with tenesmus, dyschezia, mucus, and hematochezia. Other signs of colonic disease include vomiting, constipation, hematochezia without diarrhea and mixed bowel diarrhea. Vomiting may be seen in up to 30% of colonic disease cases, and hematochezia without diarrhea is reported in 70% of dogs with rectal tumors (15). Colonic endoscopy requires general anesthesia, again with the dog in left lateral recumbency. Patient preparation involves complete rectal and colonic fecal evacuation, partly because residual fecal material impairs visualization and may prevent complete examination up to the ileo-colonic sphincter, and partly because ileal scoping is now recognized as an essential part of the endoscopic work-up in patients with small bowel signs (16). There are various ways to prepare the patient; the authors prefer a two-stage protocol:

Table 1. Recommendations for number of endoscopic samples.

GI segment	Number of endoscopic samples
Stomach	6 adequate biopsies; biopsy gastric body unless focal lesions present
Duodenum	10-15 adequate biopsies
Ileum	5 adequate biopsies
Colon	9-12 adequate biopsies, with at least 3-4 biopsies from each colonic region

NB: Always biopsy even if the mucosa appears normal and also always biopsy focal lesions.

Box 3. Gastric adenocarcinoma in dogs.

Gastric adenocarcinoma accounts for 70-80% of all stomach cancers in dogs. The most common clinical signs are progressive and include vomiting, anorexia, weight loss and hematemesis, with a duration ranging from days to several months. Routine blood results can be non-specific but may include anemia and increased liver enzymes due to liver metastasis or obstruction of the common bile duct. Endoscopy can detect most, if not all, gastric carcinomas: typically a firm, non-distensible stomach is visualized, with lesions that can be diffusely infiltrative; these may be largely ulcerative with necrotic centers, or can be polypoid in nature. The pylorus and antrum are most likely to be involved, especially close to the angular notch. The definitive diagnosis is based on histopathology findings, but cytology of endoscopic biopsies or fine-needle aspirates retrieved at surgery can be useful. These two techniques correlate well with histopathology findings. A normal histopathological result on endoscopic biopsy may not rule out the presence of gastric cancer; indeed, if the neoplastic infiltration is located deeper in the mucosa, endoscopic biopsies may be too superficial, and the definitive diagnosis may require a full-thickness surgical biopsy. However, ultrasound examination is less invasive, and ultrasound-guided fine-needle aspiration of the gastric wall may be a good alternative. There is no specific therapy, unless complete excisional surgery can be performed before any metastatic spread, and the prognosis is usually poor, with a survival time < 6 months.

Further reading: Marolf AJ, Bachand AM, Sharber J, *et al.* Comparison of endoscopy and sonography findings in dogs and cats with histologically confirmed gastric neoplasia. *J Small Anim Pract* 2015;56:339-344.

ROYAL CANIN®

- The dog must only be fed a low-residue diet (*e.g.,* boiled chicken or white fish) for 4-5 days before endoscopy.
- The patient is hospitalized the day before the procedure and fasted; enemas are administered 24 and 12 hours prior to colonoscopy, with a third enema just before the dog is anesthetized.

Each enema should be performed with 30-50 mL/kg of warm water, without soap. Other type of enema solutions (*e.g.,* sodium phosphate) are not recommended, as life-threatening metabolic disorders with severe hypernatremia, hypocalcemia, hyperphosphatemia, and polycythemia have been reported (17). One study suggested that polyethylene glycol (PEG)-containing electrolyte solution given orally is preferable to administration of multiple enemas when preparing dogs for colonoscopy (18). However, large volumes of PEG are required (> 50 mL/kg) which can be difficult to administer, often necessitating nasogastric or orogastric intubation.

Case 5

A 9-month-old male Boxer was referred for chronic large bowel diarrhea with hematochezia, tenesmus, and fecal mucus for 5 months, with no response to empirical treatment (fenbendazole, toltrazuril, metronidazole, enrofloxacin). Initially, the entire litter had shown the same signs, but the other puppies had improved when treated with enrofloxacin. No weight loss or failure to grow was noted, and the dog was correctly vaccinated and dewormed. There was no abnormality on physical examination, including rectal examination. Fecal parasite screening, CBC, biochemistry, TLI/folate/cobalamin levels, and urinalysis were normal. Abdominal ultrasound revealed severe colonic abnormalities, with significant thickening and loss of stratification of the colonic wall, and moderate hypertrophy of the sublumbar lymph nodes. Cytology of an ultrasound-guided fine-needle aspirate of the lymph nodes revealed a non-specific low-grade granulomatous inflammation. Colonic endoscopy showed a loss of

Figure 9. Ileal endoscopy of **Case 4.** Note the milky appearance of the intestinal mucosa and the prominent dilated villi, suggestive of lymphangiectasia.

© ENVT, O. Dossin

Box 4. Canine protein-losing enteropathy.

Protein-losing enteropathy (PLE) is a syndrome associated with an abnormal loss of albumin through the GI tract. It may be associated with various disease conditions, mostly chronic intestinal inflammation and intestinal lymphangiectasia, but also intestinal lymphoma. The classical presentation is a combination of chronic, relapsing digestive signs associated with severe weight loss and dependent edema or body cavity effusion. Chronic diarrhea is the most common clinical sign, but is not seen in all cases. Other signs include chronic vomiting, respiratory distress secondary to pleural effusion, melena or other signs associated with complications of PLE such as thrombosis.

The diagnosis of PLE must be staged. Once hypoalbuminemia is confirmed, it is important to exclude other causes (*e.g.,* liver disease, protein-losing nephropathy, Addison's disease) using standard blood tests (see paper on page 20). Most, but not all, dogs with PLE also develop a concurrent hypoglobulinemia and hypocholesterolemia. Where available, a fecal alpha 1-antitrypsin measurement may be useful to confirm PLE in cases with concurrent protein-losing nephropathy or liver failure. The second step is abdominal ultrasonography in order to select the biopsy method (endoscopy vs. surgery) and to evaluate other abdominal organs. Ultrasound may identify focal or patchy lesions within the GI tract, and ultrasound-guided fine-needle aspiration of all abnormal organs can be useful if lymphoma is suspected. However, a normal abdominal ultrasound is never a reason to rule out intestinal disease. The third step is intestinal biopsy (endoscopic or surgical full thickness) and histopathological diagnosis.

Endoscopy is not always recommended, especially if lesions are located in a segment inaccessible to endoscopy, but, if performed, a bi-directional procedure (upper and lower gastrointestinal) is always recommended to allow biopsy of the duodenum and the ileum, as lesions can be distributed in a patchy or segmental pattern.

Further reading: Dossin O, Lavoué R. Protein-losing enteropathies in dogs. *Vet Clin North Am Small Anim Pract* 2011;41:399-418.

© ENVT, O. Dossin

Figure 10. Colonic endoscopy of **Case 5.** Note the irregular appearance of the mucosa and poor visualization of the vessels, suggestive of inflammation or neoplasia.

submucosal vessels, with several disseminated nodules and petechiae in the descending colon ***(Figure 10).*** These findings were suggestive of severe colonic inflammation or (less likely) neoplasia; the dog's age and breed suggested that granulomatous colitis was the most likely diagnosis, and this was confirmed on biopsy ***(Box 5).*** Enrofloxacin was prescribed for 6 weeks, along with a hypoallergenic diet, and the patient dramatically improved within 5 days; no relapse has been reported several years after the diagnosis.

Box 5. Granulomatous colitis in dogs.

Granulomatous colitis is an uncommon type of inflammatory bowel disease caused by an adherent, invasive species of *Escherichia coli.* Clinical signs are typical of large bowel diarrhea and weight loss, progressing to cachexia in severe cases. Boxers < 4 years are predisposed, but other breeds can be affected. Diagnosis is via endoscopic biopsy of the colon, with histology typically revealing severe mucosal ulceration and infiltration of the submucosa and lamina propria with macrophages that stain positive with Periodic Acid Schiff. The infectious cause may be identified by Fluorescence *In-Situ* Hybridization (FISH), but a negative FISH result does not rule out *E. coli,* because bacterial invasion of the intestinal tissue can be patchy; a minimum of 10 mucosal biopsies is always recommended. Enrofloxacin (5-10 mg/kg Q24 h for 6-8 weeks, even if the signs disappear quickly) is the preferred treatment and can achieve long-term remission, but bacterial culture of the biopsy (along with sensitivity testing) is recommended because quinolone resistance has been recently reported, associated with a poor clinical outcome. Enrofloxacin should not be prescribed for canine colitis before a definitive histopathological diagnosis of granulomatous colitis has been made.

Further reading: Craven M, Mansfield CS, Simpson KW. Granulomatous colitis of boxer dogs. *Vet Clin North Am Small Anim Pract* 2011;41:433-445.

References

1. Dossin O. Endoscopic complications. In: Washabau R, Day MJ (eds). *Canine and Feline Gastroenterology*. St Louis: Elsevier. St Louis: Elsevier 2013;307-310.
2. Chamness CJ. Endoscopic instrumentation. In: Tams TR (ed). *Small Animal Endoscopy*. St Louis: Mosby 1999;1-16.
3. Radhakrishnan A. Advances in flexible endoscopy. *Vet Clin North Am Small Anim Pract* 2016;46: 85-112.
4. Chamness CJ. Endoscopic instrumentation. In: Washabau R, Day MJ (eds). *Canine and Feline Gastroenterology*. St Louis: Elsevier 2013;267-272.
5. Sum S, Ward CR. Flexible endoscopy in small animals. *Vet Clin North Am Small Anim Pract* 2009;39: 881-902.
6. Leib MS. Esophageal endoscopy. In: Washabau R, Day MJ (eds). *Canine and Feline Gastroenterology.* St Louis: Elsevier 2013;272-276.
7. Jergens AE. Gastric endoscopy. In: Washabau R, Day MJ (eds). *Canine and Feline Gastroenterology.* St Louis: Elsevier.2013;276-282.
8. Spillmann T. Intestinal Endoscopy. In: Washabau R, Day MJ (eds). *Canine and Feline Gastroenterology.* St Louis: Elsevier 2013;282-287.
9. Gaschen L, Kircher P, Stussi A, *et al.* Comparison of ultrasonographic findings with clinical activity index (CIBDAI) and diagnosis in dogs with chronic enteropathies. *Vet Radiol Ultrasound* 2008;49:56-64.
10. Casamian-Sorrosal D, Willard MD, Murray JK, *et al.* Comparison of histopathologic findings in biopsies from the duodenum and ileum of dogs with enteropathy. *J Vet Intern Med* 2010;24:80-83.
11. Procoli F, Motskula PF, Keyte SV, *et al.* Comparison of histopathologic findings in duodenal and ileal endoscopic biopsies in dogs with chronic small intestinal enteropathies. *J Vet Intern Med* 2013;27:268-274.
12. Jergens AE, Willard MD, Allenspach K. Maximizing the diagnostic utility of endoscopic biopsy in dogs and cats with gastrointestinal disease. *Vet J* 2016;214:50-60.
13. Willard MD, Mansell J, Fosgate GT, *et al.* Effect of sample quality on the sensitivity of endoscopic biopsy for detecting gastric and duodenal lesions in dogs and cats. *J Vet Intern Med* 2008;22;1084-1089.
14. Willard MD, Moore GE, Denton BD, *et al.* Effect of tissue processing on assessment of endoscopic intestinal biopsies in dogs and cats. *J Vet Intern Med* 2010;24:84-89.
15. Danova NA, Robles-Emanuelli JC, Bjorling DE. Surgical excision of primary canine rectal tumors by an anal approach in twenty-three dogs. *Vet Surg* 2006;35:337-340.
16. Lecoindre P. Colonic endoscopy. In: Washabau R, Day MJ (eds). *Canine and Feline Gastroenterology.* St Louis: Elsevier 2013;287-290.
17. Tomsa K, Steffen F, Glaus T. Life-threatening metabolic disorders after application of a sodium phosphate containing enema in the dog and cat. *Schweiz Arch Tierheilkd* 2001;143:257-261.
18. Richter KP, Cleveland MB. Comparison of an orally administered gastrointestinal lavage solution with traditional enema administration as preparation for colonoscopy in dogs. *J Am Vet Med Assoc* 1989;195: 1727-1731.

ROYAL CANIN®

HOW I APPROACH...

The cat with chronic diarrhea

Craig Webb, PhD, DVM, Dipl. ACVIM
Clinical Sciences Department, Colorado State University, USA

Dr Webb qualified from the University of Wisconsin-Madison and is currently professor and head of Small Animal Medicine at Colorado State University. His clinical expertise is centered around gastroenterology and endocrinology.

Introduction

There is a significant difference between the way a clinical sign or a disease process is organized within a textbook, and the way a cat with that particular clinical sign or disease process actually presents to you as a clinician. Therefore, although an understanding of the "textbook" case is critical, it is still a very long way from an understanding of the cat on the examination table in front of you. What follows is my attempt to describe what is actually happening between that cat and me as the clinician, as I try to achieve that understanding.

The approach

My approach to a cat with chronic diarrhea – which is defined as continuous or intermittent diarrhea (reduced consistency, increased volume, or increased frequency) of greater than 3 weeks' duration – may actually come from a variety of different directions. Consider the following options:

- I like to start with the cat and the owner together. I use the history of the cat, the history of the clinical sign(s), and a physical examination to rank-order, from most likely to least likely, my list of differentials for feline chronic diarrhea. From that list, I prioritize the diagnostic test(s) that seems best suited to confirm or refute my number one differential. Additional diagnostic testing will move a possible diagnosis either up or down my rank-ordered list until I identify the differential that sticks to the top. This is known as the *Clinical Reasoning Approach,* where one moves logically from a presumptive to a definitive diagnosis.

- The next approach is much less involved. Again I start by looking at the cat and listening to the owner. Then I look at the case presentation, or "illness script", and simply go with what my instinct tells me. This is known as the *Script Recognition Approach* and is based very strongly on "gut feeling".

- As I review the medical history and perform the physical examination, I pay special attention to aspects of the case that do not make sense or do not seem to fit; these incongruities often turn out to be important clues. I will also run a "Cine Loop" of the case through my head, from start to finish, attempting to describe the case more completely and accurately each time, in search of any missing piece of the puzzle. These are components of the *Key Features Approach,* which separates critical notes from background noise.

- Finally, despite the eloquence of the argument for a committed work-up, and often as a result of financial constraints, the owner may opt to begin a "trial treatment". So I prescribe treatment X and schedule a recheck in 2 weeks. This is known as the *Ready-Fire-Aim Approach,* and frequently evolves into the *Ready-Fire-Fire-Fire Approach.*

KEY POINTS

- **The clinician can employ a variety of approaches when dealing with a cat that has chronic diarrhea. Two of the most useful methods are *Clinical Reasoning* and *Script Recognition.***
- **First approach the case as a clinician; diagnostic testing should arise from a clinical diagnosis.**
- **Important incongruities and key features are to be found in the signalment, history, and physical exam.**
- **Defining the problem in an accurate, complete and concise manner aids in diagnosis.**
- **Positive predictive value is a function of the prevalence of the disease in the population being tested.**
- **Diet is a critical component in both the diagnosis and the treatment of cats with chronic diarrhea.**

Many variables can influence the way I approach a case; some in a positive manner, some in a way that results in a (somewhat predictable) error of medical judgement. The above methods are not mutually exclusive – in many cases one approach can complement another. I strongly encourage you to "think about how you think about cases" (1) and this is best illustrated by considering some case presentations.

Case presentation #1

I start with the information as shown in the appointments schedule; it will usually simply give details of a cat with a certain signalment with the presenting complaint of "chronic diarrhea". Beginning with just the signalment and presenting complaint, I begin to form an "illness script" or picture in my head of the case. If the schedule tells me I am about to see a kitten with chronic diarrhea, my illness script is very different than if I know I am about to see a 14-year-old Siamese with chronic diarrhea ***(Table 1).*** When I actually see the cat, perform a physical examination, and take a history from the owner I use that information to fill in details and enhance the clarity of my picture. At this point in my approach, I form a presumptive diagnosis using Script Recognition.

As simple as it sounds, it has been shown that the more experienced a clinician is, the larger the role Script Recognition plays in their approach to cases. The power of this approach depends on how accurate and complete the illness script is, and my ability, through experience, training, and recall to recognize and identify that specific script.

© Craig Webb

Figure 1. Case 1: a 5-month-old F/S domestic shorthair with chronic intermittent large bowel diarrhea.

A "cat with chronic diarrhea" could have almost anything. However, a 5-month-old F/S domestic shorthair (Signalment) with chronic intermittent large bowel diarrhea (Presenting complaint and History), adopted from the shelter and otherwise healthy (History), with a BCS of 5/9 and mild perianal inflammation (Physical exam), unresponsive to repeated courses of metronidazole and fenbendazole (History) is a case of *Tritrichomonas foetus** until proven otherwise (2) ***(Figure 1).***

In this case, the Ready-Fire-Aim approach had already resulted in several trial treatments from the referring clinician,

**Tritrichomonas foetus* may soon be renamed *T. blagburni,* based on molecular testing, host specificity, and pathology. This is simply to distinguish the feline *T. foetus* organism from the bovine organism and has no impact on the diagnosis or treatment of feline trichomonosis.

Table 1. Building an "Illness Script" for cats with chronic diarrhea: an animal's age has a major impact on the etiology.

Signalment, presenting complaint, history, physical examination				
Signalment: age, gender, breed				
Age				
Kitten	**Adult**		**Geriatric**	
Primary GI > secondary GI	**Primary GI & secondary GI**		**Primary GI < secondary GI**	
• Dietary • Infectious - Parasites - Viruses - Protozoa - Bacteria • Stress • Anatomy – Intussusception	• Food responsive • IBD • GI LSA • Infectious • Ileus	• CKD • Pancreatitis • Neoplasia • Cholangitis • Hyperthyroidism • EPI	Intestinal neoplasia	Extra-intestinal neoplasia
			All etiologies listed in Adult section	

GI = gastrointestinal; IBD = inflammatory bowel disease; GI LSA = gastrointestinal lymphosarcoma; EPI = exocrine pancreatic insufficiency; CKD = chronic kidney disease

ROYAL CANIN®

with a broad-spectrum antihelminthic (fenbendazole 50 mg/kg Q24 h for 5 days) and metronidazole benzoate (25 mg/kg Q24 h for 7 days). This would be standard practice in kittens, given the prevalence of parasites in a shelter population of this age group, and here the lack of response to these interventions is a Key Feature of the illness script.

Another important feature of my illness script in this case is to establish whether the diarrhea was predominantly small bowel or large bowel in origin ***(Table 2).*** Frequently, the answer is "mixed", and there is a significant overlap in etiology for both categories. But the distinction turns out to be important in this case, given the fact that this kitten was not afflicted by GI parasites susceptible to standard antihelminthics. That leaves *T. foetus* and a drug-resistant *Giardia spp.* as my top infectious rule-outs, and with signs that indicate large bowel diarrhea I favor the former option.

Fecal examination ***(Figure 2)*** would be an obvious and important diagnostic step when working up most cases of feline chronic diarrhea, especially with this age group and environmental history. The diagnostic techniques available for examination of feces are beyond the scope of this article, but a number of excellent resources are available to help clinicians make sound diagnostic choices** (3).

The importance of dietary intervention in cases of chronic diarrhea will be emphasized a number of times in this paper, and I will also emphasize diet as a diagnostic tool. Considering the likelihood of diet-related diarrhea in kittens ***(Table 1),*** a diet trial would certainly have been a strong consideration in this case. The use of hypoallergenic and hydrolyzed diets will be discussed as we move to an older age group, but in this kitten I would have reached for a highly digestible diet (4), or (because the problem was large bowel diarrhea) possibly a GI-fiber diet (5), whilst bearing in mind the caloric requirements of a growing kitten. My preferred fiber source as a non-specific treatment for diarrhea is psyllium (unflavored powder, 425 mg per 1/8 tsp; 0.25-0.5 tsp per meal), a soluble fiber with evidence-based support for use in canine large bowel diarrhea cases (6).

Expanding the definition of dietary intervention beyond a particular food, I would strongly consider supplementing this particular kitten with a probiotic. Whether a cause or consequence, an unbalanced intestinal microbiome,

© Craig Webb

Figure 2. A fecal sample from a cat with mixed bowel diarrhea; watery and small in quantity, with the cat unable to make it to the litter box.

known as dysbiosis, is likely a very important contributor to gastrointestinal disease and the associated clinical signs in both people and pets. One study showed that giving shelter cats a probiotic significantly reduced the number of days the cats experienced diarrhea (7). Whilst ronidazole is the treatment of choice for *T. foetus* diarrhea (30 mg/kg Q24 h for 14 days) (8), it appears that combining ronidazole with a probiotic might reduce the likelihood that cats will relapse, as is otherwise frequently the case (9). Although our ability to assess or monitor the microbiome is currently quite limited, at least one

Table 2. Distinguishing between small bowel and large bowel diarrhea in cats.

Clinical sign	Small bowel	Large bowel
Mucus	Absent	Common
Fresh Blood	Absent	Common
Melena	+/-	Absent
Volume	Increased	Normal, decreased
Character	Soft to watery	Soft to formed
Frequency	Normal, slight increase	Increased
Dyschezia	Absent	+/-
Tenesmus	Absent	+/-
Urgency	Absent	Common
Weight loss	Common	Uncommon
Vomiting	+/-	Uncommon
Appetite	Variable	Often normal
Activity	Often decreased	Often normal
Borborygmus	+/-	Absent
Flatulence	+/-	+/-

**Companion Animal Parasite Council (CAPC)™ www.capcvet.org

laboratory has recently developed and commercialized a fecal "Dysbiosis Index" test***. Employing this test may help me further refine the illness script, as well as help monitor therapies in cases of chronic diarrhea. As a cautionary note, at least one study has shown that there can be a huge discrepancy between what is on the label and what is inside the bottle when it comes to OTC probiotics (10), and I stick with trusted brands produced by companies with deep roots in veterinary medicine.

In this case, I incorporated a number of different approaches, avoided a variety of potential medical errors in judgement, and with a *T. foetus*-positive fecal PCR result, treated the kitten with ronidazole, a highly digestible diet, psyllium and a probiotic – putting an end to the chronic diarrhea.

Case presentation #2

My next appointment is a 3-year-old F/S domestic shorthair (Signalment) with chronic intermittent small bowel diarrhea (Presenting complaint and History), adopted from the shelter and otherwise healthy except for the occasional hairball vomit (History), a BCS score of 4/9 with mild interdigital inflammation (Physical exam), unresponsive to repeated courses of metronidazole and fenbendazole (History) ***(Figure 3).***

Laboratory tests are PCR-positive for *T. foetus*. I am pleased to get a positive result with minimal financial outlay, and since I have just experienced success treating Case #1 with ronidazole I naturally prescribe the same drug for this cat with chronic diarrhea – but to no effect.

This example highlights how my approach to a case can be significantly impacted by my success or failure with previous cases, previous diagnostics, and previous treatments. That makes sense; we are supposed to learn from our experiences. Unfortunately, in this example, the influence of my recent success affected my focus in constructing an illness script. Case #2 involves a young adult cat, not a kitten; this cat was experiencing small bowel diarrhea, not large bowel; not all cats from shelters have parasites; the vomiting of hairballs was seen as incidental; the BCS was 4/9; the mild interdigital inflammation was regarded as incidental; and the failure to respond to dewormers was interpreted as supporting *T. foetus*... after all, the laboratory diagnostic test result said so.

This case also highlights what I believe to be a critical component in my work-up of cases in veterinary medicine:

*** Gastrointestinal Laboratory, Texas A&M University – although the dysbiosis test is currently only validated for dogs, recent evidence suggests that it may be useful for cats as well.

© Craig Webb

Figure 3. Case 2: a 3-year-old F/S domestic shorthair with chronic intermittent small bowel diarrhea.

the appropriate placement of diagnostic testing. Testing for infectious agents associated with feline chronic diarrhea is a prime example; study after study reminds us that using a diagnostic test to identify an organism does not equate to identifying the cause of the diarrhea. Even in the face of advanced technologies such as PCR-based identification of intestinal parasites, clinical reasoning is crucial for successful treatment (11). So when do I use diagnostic testing, and what tests do I use in my approach to a cat with chronic diarrhea?

Positive predictive value is a function of the prevalence of the disease in the population which I am testing. Each individual cat becomes part of a "population" of patients that I decide to test for this or that... or not test for this or that. The better I am at correctly identifying those patients that likely have disease X, the higher the prevalence of disease X in my "population" of patients. Therefore, the value of the diagnostic test I request and my ability to confidently interpret the result of the test depends on my ability as a clinician to make a clinical diagnosis before ordering a diagnostic test. In summary: my diagnostic test results are only as good as I am!

So back to Case #2, where ronidazole had no effect. Discouraged by my treatment failure, I turn to the literature on feline chronic diarrhea in the hopes of finding a more successful approach to this case. A recent series of articles describe the diagnosis of chronic small bowel disease in adult cats and the intestinal histology in cats

ROYAL CANIN®

suspected of having chronic small bowel disease (12,13). A key component of the diagnostic work-up in these cases was abdominal ultrasound, which frequently demonstrated thickening of the small intestines. Subsequent full-thickness biopsies revealed that about half of the cats had a diagnosis of chronic enteritis and most of the other cats had a diagnosis of GI lymphoma. So one scenario for this cat is that I perform abdominal ultrasound, find thickened small intestines, obtain endoscopic small intestinal biopsy samples for histopathology, diagnose lymphocytic plasmacytic enteritis (IBD), and start the cat on prednisolone.

But before I settle on that approach, I start my Cine Loop review of the illness script. I "walk through" the case again and again, looking for incongruities and key features that I may have missed. I ask myself "What if the same cat's presenting complaint had been interdigital inflammation?". A young adult cat with itchy inflamed digits is an illness script consistent with allergy. Now I add in the GI signs, and using Clinical Reasoning the rule-out that rises to the top of my list is food allergy. The diagnostic test of choice for food allergy is not abdominal ultrasound or intestinal biopsies, but a food trial.

A critical series of papers on cats with chronic diarrhea (14,15) described a significant number of cats (30%) presenting for chronic GI signs (diarrhea or vomiting), pruritus, or both; their clinical signs were resolved with an elimination diet trial, using a commercial canned single-source protein hypoallergenic diet. The authors use the term "food sensitivity" to characterize the etiology behind chronic diarrhea in these cats, including food intolerance and food allergy. Of clinical importance, the food sensitivity cats in these studies showed resolution of GI signs after just a 2-week trial of the hypoallergenic diet. The diagnostic work-up of these cats was extensive. In fact, 50% of the cats who were diagnosed with food sensitivity had histopathology that described mild to severe lymphoplasmacytic enteritis, *i.e.,* inflammatory bowel disease. Ironically, although abdominal radiographs were performed to rule out GI obstruction and abdominal masses, abdominal ultrasound was not part of the diagnostic work-up of these cats.

The message for me is that when I approach an otherwise healthy (*i.e.,* no evidence of secondary GI disease) and stable (*i.e.,* no significant weight loss or decrease in appetite) young adult or adult cat presenting for chronic diarrhea, I think "food first" as an appropriate early diagnostic tool. I may prepare the owner for several sequential 2-week diet trials should the original diet fail. I start with a prescription novel protein or hydrolyzed diet (food allergy), as there does not appear to be a significant clinical difference between the two (16). If that fails, I consider an easily digestible diet (evidence-based) or a GI fiber diet (if large bowel) (17,18). Finally, I might employ a bespoke elimination diet in the hopes of identifying a single offending ingredient.

Case presentation #3

When I consider adult and older cats with chronic diarrhea ***(Table 3),*** or if I am faced with young or young adult cats where the chronic diarrhea appears to be a local sign of a more systemic and serious problem, my approach becomes more aggressive, both in terms of the time-frame and the diagnostics. Although food sensitivity and infectious causes of chronic diarrhea can cause systemic signs, they are much lower on my list for a cat that is more seriously ill. Case #3 is a 12-year-old M/N Persian with chronic small bowel diarrhea, including significant weight loss and poor body condition ***(Figure 4).*** Here, the Ready-Fire-Fire-Fire approach with prophylactic deworming, diet trials, supplements or best-guess antibiotics is no longer appropriate. In this situation, since secondary GI causes of diarrhea become more prominent with age (*e.g.,* linked to liver, pancreas or thyroid problems, etc.), I will attempt to rule out those that warrant diagnostic investigation. Then, if I have done my job as a clinician, the case probably comes down to my attempting to distinguish between IBD and GI lymphoma. I start with an illness script and Script Recognition – does this cat look and feel like it has cancer (cachectic, muscle wasted, thickened intestines) and does it act as if it has cancer (lethargic and hyporexic)?

Then I apply Clinical Reasoning, paying attention to incongruities and key features – does it make sense that the clinical signs of GI lymphoma were first recognized two years ago? Does it make sense that IBD has led to a 35% loss of body weight over 2 months? Does it make

Table 3. A continuum of common case etiologies ranked by age.

Age	Etiology*
Young	Infectious
Young adult	Food
Adult	Inflammation
Older adult	Neoplasia

*The dashed lines between entries emphasize the overlap between etiologies.

© Craig Webb

Figure 4. Case 3: a 12-year-old M/N Persian with chronic small bowel diarrhea, including significant weight loss and poor body condition.

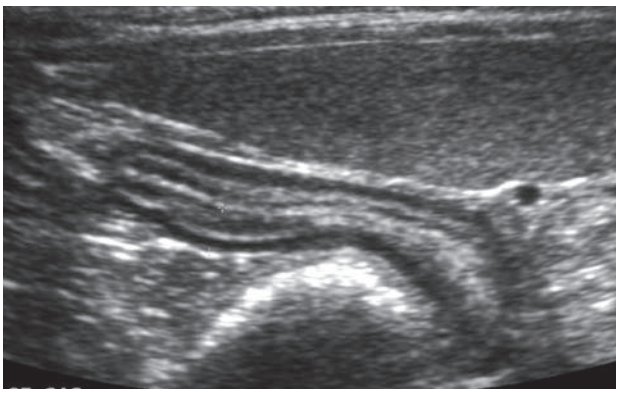

© Dr. Angela Marolf, CSU

Figure 5. Abdominal ultrasound image showing a sagittal section of feline small intestine, highlighting a thickened intestinal wall.

sense that the cat is cachectic in the face of polyphagia? Could the cat have more than one significant problem, as in cases of feline triaditis?

I will check a TT4 for thyroid function and run a fasted panel for folate, cobalamin, fTLI, and fPLI. Low levels of folate and cobalamin are consistent with proximal and distal small intestinal disease, respectively. A disparity between the two, high folate and low cobalamin, is consistent with some degree of dysbiosis. An elevation in fPLI is consistent with pancreatitis, although I would look closely for additional clinical signs such as dysrexia and lethargy, or elevations in blood glucose and total bilirubin. Finally, although exocrine pancreatic insufficiency is rare in cats, it can cause chronic small bowel diarrhea with weight loss, usually despite a good appetite (19). For me, cobalamin is usually the most informative value on the GI panel (20); low values are associated with significant small intestinal disease, and really low values may be associated with GI lymphoma (21). In addition, cobalamin can be easily supplemented (see ***Table 4,*** page 7).

In these more serious cases, an abdominal ultrasound study may reveal findings consistent with small intestinal disease, although thickened intestines or enlarged abdominal lymph nodes can be non-specific ***(Figure 5).*** The character and distribution of thickened intestinal walls may influence my recommendation of endoscopy or surgical biopsy, and a single focal thickening might heighten my suspicion for an intestinal adenocarcinoma. Ultrasound can also be a useful modality for looking for extra-intestinal disease ***(Figure 6)*** but like any other diagnostic test, it is most effective when it follows clinical judgment – an ultrasound exam should not be a "fishing trip". Whether biopsy tissue is best obtained by endoscopy (partial thickness, limited access) as in ***Figure 7*** or laparotomy (full thickness, unlimited access) is the focus of a number of recent publications, much historical debate, and is not a simple question to answer. Regardless of how I obtain the tissue, I first check with my diagnostic laboratory to ensure I prepare the samples in a way that will allow me to make full use of the diagnostic testing available (*e.g.,* special media). I ask the pathologist to interpret the histopathology using WSAVA guidelines, reporting on cell type, severity, and architectural changes. I take full advantage of advanced diagnostic techniques, including immunohistochemistry, flow cytometry, and PCR, to help determine cell phenotype and look for clonality (22).

If the histopathology and molecular assay results match my Script Recognition and Clinical Reasoning, I proceed with treatment. If it does not, I restart my "cine loop" and try to make sense of the incongruity.

Figure 6. Abdominal ultrasound image showing an enlarged, hypoechoic, feline pancreas with hyperechoic surrounding mesentery, consistent with pancreatitis.

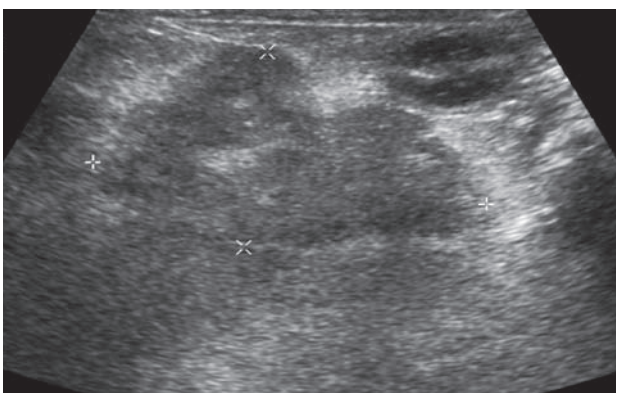

© Dr. Angela Marolf, CSU

ROYAL CANIN®

© Dr. Sara Wennogle, CSU

Figure 7. Endoscopic view of the feline duodenum; histopathology revealed moderate lymphocytic-plasmacytic inflammatory bowel disease.

My preferred treatment for both feline IBD and lymphoma are as set out in the "Chronic small intestinal disease in cats" paper (see page 2-8) although I like to keep track of the number of medications I am asking the owner to give their sick cat, and avoid polypharmacy if at all possible.

Conclusion

In summary, I approach a cat with chronic diarrhea as a clinician, first and foremost. That is what I am trained to be, and that is what the client is paying me to do. Fortunately, that approach is also the best way for me to find an effective path to a correct diagnosis and an effective treatment.

References

1. Canfield PJ, Malik R. Think about how you think about cases. *J Feline Med Surg* 2016;18:4-6.
2. Marks SL. Rational approach to diagnosing and managing infectious causes of diarrhea in kittens. In: Little SE (ed). *August's Consultations in Feline Internal Medicine.* Vol. 7. Philadelphia: Elsevier, 2016;1-22.
3. Marks SL, Rankin SC, Byrne BA, *et al.* Enteropathogenic bacteria in dogs and cats: diagnosis, epidemiology, treatment, and control. *J Vet Intern Med* 2011;25:1195-1208.
4. Laflamme DP, Xu H, Cupp CJ, *et al.* Evaluation of canned therapeutic diets for the management of cats with naturally occurring chronic diarrhea. *J Feline Med Surg* 2012;14:669-677.
5. Zoran DL. Nutritional management of feline gastrointestinal diseases. *Top Compan Anim Med* 2008;23:200-206.
6. Leib MS. Treatment of chronic idiopathic large-bowel diarrhea in dogs with a highly digestible diet and soluble fiber: a retrospective review of 37 cases. *J Vet Intern Med* 2000;14:27-32.
7. Bybee SN, Scorza AV, Lappin MR. Effect of the probiotic *Enterococcus faeciuim* SF68 on presence of diarrhea in cats and dogs housed in an animal shelter. *J Vet Intern Med* 2011;25:856-860.
8. Gookin JL, Copple CN, Papich MG, *et al.* Efficacy of ronidazole for treatment of feline *Tritrichomonas foetus* infection. *J Vet Intern Med* 2006;20:536-543.
9. Lalor SL, Gunn-Moore DA. Effects of concurrent ronidazole and probiotic therapy in cats with *Tritrichomonas foetus*-associated diarrhea. *J Feline Med Surg* 2012;14:650-658.
10. Weese JS, Martin H. Assessment of commercial probiotic bacterial contents and label accuracy. *Can Vet J* 2011;52:43-46.
11. Rijsman LH, Monkelbaan JF, Kusters JG. Clinical consequences of PCR based diagnosis of intestinal parasitic infections. *J Gastroenterol Hepatol* 2016;doi: 10.1111/jgh.13412 [Epub ahead of print].
12. Norsworthy GD, Estep JS, Kiupel M, *et al.* Diagnosis of chronic small bowel disease in cats: 100 cases (2008-2012). *J Am Vet Med Assoc* 2013;15:1455-1461.
13. Norsworthy GD, Estep JS, Hollinger C, *et al.* Prevalence and underlying causes of histologic abnormalities in cats suspected to have chronic small bowel disease: 300 cases (2008-2013). *J Am Vet Med Assoc* 2015;247:629-635.
14. Guilford WG, Markwell PJ, Jones BR, *et al.* Prevalence and causes of food sensitivity in cats with chronic pruritus, vomiting or diarrhea. *J Nutr* 1998;128:2790S-2791S.
15. Guilford WG, Jones BR, Markwell PJ, *et al.* Food sensitivity in cats with chronic idiopathic gastrointestinal problems. *J Vet Intern Med* 2001;15:7-13.
16. Mandigers PG, Biourge V, van den Ingh TS, *et al.* A randomized, open-label, positively controlled field trial of a hydrolyzed protein diet in dogs with chronic small bowel enteropathy. *J Vet Intern Med* 2010;24:1350-1357.
17. Simpson JW. Diet and large intestinal disease in dogs and cats. *J Nutr* 1998;128:2717S-2722S.
18. Freiche V, Houston D, Weese H, *et al.* Uncontrolled study assessing the impact of a psyllium-enriched extruded dry diet on faecal consistency in cats with constipation. *J Feline Med Surg* 2011;13:903-911.
19. Steiner JM. Exocrine pancreatic insufficiency in the cat. *Top Companion Anim Med* 2012;27:113-116.
20. Maunder CL, Day MJ, Hibbert A, *et al.* Serum cobalamin concentrations in cats with gastrointestinal signs: correlation with histopathological findings and duration of clinical signs. *J Feline Med Surg* 2012;14:689-693.
21. Kiselow MA, Rassnick KM, McDonough SP, *et al.* Outcome of cats with low-grade lymphocytic lymphoma: 41 cases (1995-2005). *J Am Vet Med Assoc* 2008;232:405-410.
22. Sabattini S, Bottero E, Turba ME, *et al.* Differentiating feline inflammatory bowel disease from alimentary lymphoma in duodenal endoscopic biopsies. *J Small Anim Pract* 2016;57:396-401.

A SHORT GUIDE TO...

Nasal feeding tubes in dogs

Joris Robben, PhD, Dipl. ECVECC, Dipl. ECVIM-CA
Faculty of Veterinary Medicine, Utrecht University, the Netherlands

Dr Robben graduated from Utrecht University in 1988 and completed his PhD on canine insulinomas in 2004. Since 2014 he has been vice-president of the European College of Veterinary Emergency and Critical Care. He is currently associate professor in Emergency and Critical Care at Utrecht University.

Chiara Valtolina, DVM, Dipl. ECVECC, Dipl. ACVECC
Faculty of Veterinary Medicine, Utrecht University, the Netherlands

After graduating in 2000 from the Faculty of Veterinary Medicine at the University of Milan, Italy, Dr Valtolina completed a residency at the Royal Veterinary College in London before becoming a Diplomate of both the American (2009) and European (2015) Colleges of Veterinary Emergency and Critical Care. She currently works in the Intensive Care Unit at the Faculty of Veterinary Medicine in Utrecht.

Introduction

Nasal feeding tubes are easy to employ in small animal practice and are suitable for various clinical scenarios; they are intended for short-term (1-7 days) use and will allow early enteral feeding to be commenced in a recuperating patient, although only liquid diets can be administered as the diameter of the feeding tube is limited by the diameter of the patient's ventral meatus.

Inserting a nasal feeding tube is quicker and safer than placement of an esophageal tube, especially where a patient is not stable enough to undergo general anesthesia, or where surgery may result in excessive bleeding – *e.g.,* if a coagulopathy is present. A feeding tube will allow the clinician to determine if the gastrointestinal tract of an anorexic patient will tolerate enteral feeding, and to assess the factors that contribute to optimal feeding (*i.e.,* amount fed, diet composition, and if continuous rate infusion (CRI) or bolus feeding is better).

KEY POINTS

- **Nasal feeding tubes are easy to place and allow easy short-term enteral feeding in dogs that are unwilling or unable to eat voluntarily.**
- **Both nasoesophageal and nasogastric tubes can be used; there are advantages and disadvantages with both options.**
- **It is essential to ensure the tube is correctly positioned on placement and at regular intervals during use.**
- **A simple maintenance regime can help minimize problems with the feeding tube whilst *in situ.***

Materials

There are various factors to consider when selecting a suitable feeding tube ***(Table 1),*** and the clinician should select the most appropriate one for the patient. The other items required for tube placement are basic and are shown in ***Figure 1.***

Positioning the feeding tube

There are two options for tube placement:

- A nasoesophageal tube, with the distal tip of the tube sitting in the esophagus at the level of the 9th intercostal space. This method has the advantage of reducing gastric reflux and the potential development of reflux esophagitis or esophageal stricture. However, it does increase the risk that administered food is aspirated into the lungs, especially if the patient is in lateral recumbency.

- A nasogastric tube, with the distal tip of the tube positioned within the stomach at a level caudal to the last rib. This method allows the clinician to check if there is food retained within the stomach prior to administering the next bolus of food, and there is less risk of aspiration if the patient is in lateral recumbency. However, a

ROYAL CANIN®

Table 1. Feeding tube options.

Size	4 to 12 Fr; 6, 8 or 10 Fr mostly commonly used in dogs.
Length	50-100 cm depending on the size of the dog, but the tube should be long enough to allow the access port to be secured to the dog's neck. If necessary, an extension tube can be employed.
Material	The wall of the feeding tube needs to be thin, to allow the lumen to be as large as possible, but the tube also needs to be flexible enough to minimize the risk of kinking, especially where the tube bends as it exits the nose. The options include: • Polyvinyl chloride (PVC): flexible, but such tubes become brittle and rigid the longer they are kept *in situ,* especially when exposed to digestive juices. A rigid tube makes removal difficult and painful. • Silicone: very flexible with little tendency to kink, but the relatively thick wall necessary for strength results in a reduced lumen; since nasal tubes have a small overall diameter, silicone is therefore not ideal. • Polyurethane: this allows for a bigger lumen, but the tube tends to kink more easily as it exits the nose if not properly fixed.
Access ports	Different types of connection are available: • A Luer-Lock connection is suitable for continuous rate infusion (CRI). However, using such a connection in a patient that also has (central) vascular access may lead to inadvertent intravenous administration of food if the wrong tubing is connected to the IV port. • A tapered extension connector will allow a feeding syringe to be used. • A "Christmas tree" adaptor allows a tapered extension connector to be transformed into a Luer-lock connection, which is useful for temporary continuous infusion of food.
Tube tip	Although many feeding tubes have side holes, an open-ended tube has the advantage of reducing the risk of clogging; an open-ended tube is also easier to clear by flushing if it becomes blocked.

Figure 1. Equipment needed for tube placement: 2% lidocaine (with 0.5% epinephrine), lidocaine spray, 2 mL syringe, feeding tube, 10-20 mL syringe, waterproof marker, elastic self-adhesive bandage, tape, suture material, needle holder, scissors.



© Joris Robben & Chiara Valtolina

nasogastric tube does increase the risk of gastric reflux and reflux esophagitis as a result of interference with the cardiac sphincter function.

The advantages and disadvantages of the two methods have not, to the authors' best knowledge, been properly scrutinized in veterinary medicine, and no recommendation as to the better method is offered. Personal preference, patient characteristics, and disease-related aspects will determine the choice for positioning the feeding tube.

Preparation

- It is essential to measure and mark the feeding tube before placement. The point at which the tube reaches the thoracic inlet is marked with a waterproof pen ***(Figure 2).*** If a nasoesophageal method is to be used, the tube should extend to the 9th intercostal space; for the nasogastric option, the tube should extend to a level caudal to the last rib. With either scenario, the point at which the tube will exit the nose when the tip is in the desired position is marked with a small butterfly tape ***(Figure 3).***

Figure 2. Determine the length of the feeding tube required to reach the thoracic inlet **(a)** and mark the point at which the tube should exit the nose using a waterproof pen **(b).**

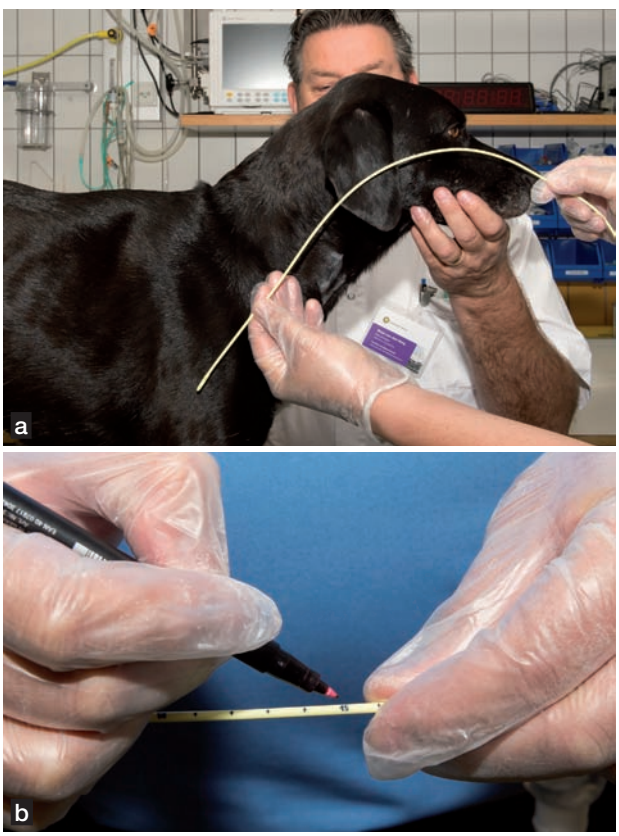

© Joris Robben & Chiara Valtolina

- It is important that the tube is of sufficient length; if necessary, extension tubing can be used. The exterior section of the tube or extension should be able to run from the tip of the nose to the dog's neck without undue tension.
- The feeding tube can be placed with the animal fully conscious or under light sedation. In either case, local analgesia of the nasal mucosa is necessary; apply one drop of lidocaine into both left and right nares (if tube placement using one side of the nose is difficult, the clinician can try the other side) 2-5 minutes before introduction of the tube. Lidocaine with epinephrine is preferred as this produces local vasoconstriction in the nasal capillary beds.

Introduction of the tube

- The tube should be lubricated with lidocaine or silicone spray. With the dog standing, sitting or in sternal recumbency, its head should be held facing forward, with the nose tilted upwards using a thumb or finger while introducing the tip medially and ventrally to guide it into the ventral meatus of the nose; the tube should slide into the nose without resistance ***(Figure 4).***

Figure 3. Determine the length of the feeding tube **(a)** and mark the point it will exit the nose with a butterfly tape **(b).**



© Joris Robben & Chiara Valtolina

ROYAL CANIN®

© Joris Robben & Chiara Valtolina

Figure 4. The tube should enter the ventral meatus of the dog's nose without resistance.

© Joris Robben & Chiara Valtolina

Figure 5. Advance the tube into the oesophagus as the dog swallows; feed the tube to the first mark, indicating that the tip of the tube is at the thoracic inlet.

- Advance the tube into the pharynx and watch for the dog swallowing; when it does, further advance the tube up to the level of the first mark, indicating that the tip of the tube is at the thoracic inlet ***(Figure 5).*** Observe for any coughing or gagging which may suggest inadvertent introduction into the trachea.
- If a guidewire has been used to stiffen the tube, it should be removed at this point ***(Figure 6).*** Use a 10-20 mL syringe to check correct positioning in the esophagus ***(Figure 7).*** Firstly, apply suction with the syringe; a vacuum should be evident. Secondly, introduce some air to determine if the feeding tube is patent and not accidentally kinked in the trachea (see below).
- If placement of the tube is correct, it can now be advanced to its intended position until the butterfly tape reaches the nares.

© Joris Robben & Chiara Valtolina

Figure 6. If a guidewire has been used to stiffen the tube, it should be removed at this point.

Fixation of the tube

- The tube can be sutured to the skin of the muzzle, as close as possible to the side of the nasal planum ***(Figure 8).*** The tube can be guided through the lateral groove under the nares. It is important not to bend the tube too tightly; allow some room to prevent kinking.
- Fixation using tissue adhesive is generally not recommended; although the adhesive can be applied easily and will initially hold the tube securely, the glue tends to become brittle, and the tube can become loose shortly after fixation.
- The tube can then be positioned over the top of the nose and between the eyes onto the forehead, where a fixation suture can be used to hold the tube; alternatively, the tube can be positioned along the lateral aspect of the face (above the whiskers and below the zygomatic arch) and sutured in place.
- Finally, the feeding tube can be taped to a bandage lightly wrapped around the neck ***(Figure 9).***
- An Elizabethan collar is often necessary to prevent the patient removing the tube but this can have a negative effect on voluntary food consumption, and the collar should be removed regularly to check if the patient wants to eat unassisted.

Correct tube positioning

Checks should be performed both during placement of the tube and each time before using the tube. The

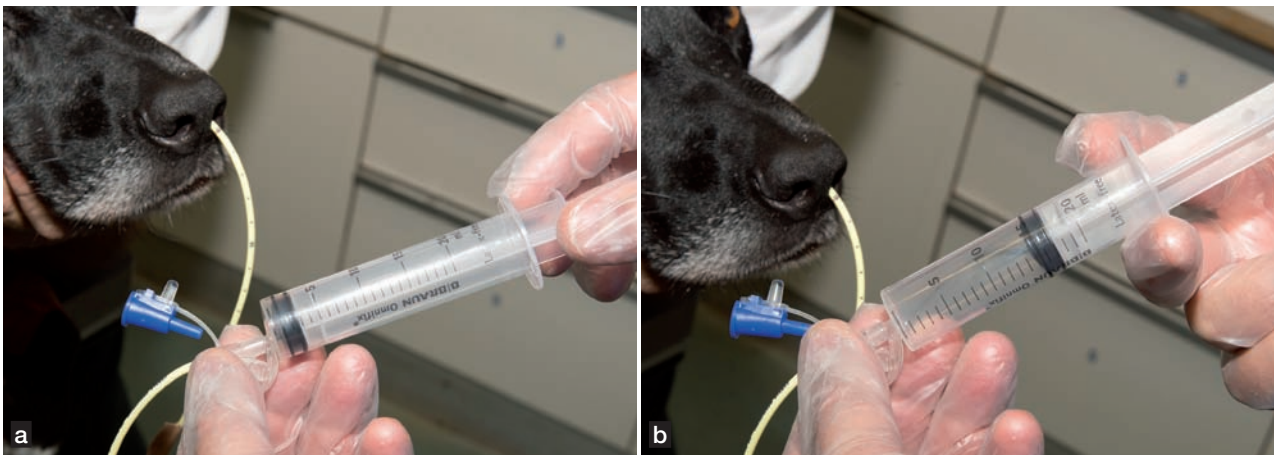

© Joris Robben & Chiara Valtolina

Figure 7. Use a syringe to check correct positioning of the tube. If suction is applied with a syringe, a vacuum should be evident **(a).** Air can be introduced to verify that the tube is patent and not accidentally kinked in the trachea **(b).**

method as described above (1) should result in successful placement, but two other tips are:

- If the dog swallows when the tip of the tube is in the nasopharynx/oropharynx, this gives better assurance that the feeding tube is entering the esophagus.
- Check visually and manually on the left side of the neck to verify correct placement whilst advancing the tube down the esophagus.

Once the tube is in position, it is prudent to check the placement before each feed. This can be done in several ways.

- Check with a syringe as described above. However, note that dyspnea or nausea can make a patient swallow air; this may result in an initial aspiration of gas with the syringe, giving the impression that the tube has entered the trachea. However, if aerophagia is present, the amount of air retrieved should be limited. In addition, if air can be easily flushed through the tube with a syringe, it offers reassurance that the tube is not kinked.
- Flush the feeding tube with 2-20 mL (depending on the size of the dog) of isotonic electrolyte solution; if the tube is in the airway, it should elicit coughing (but note that very sick patients with reduced consciousness or animals under sedation may not cough).
- With a nasogastric tube, 5-15 mL of air can be injected in the tube; borborygmi may be heard by auscultating the cranial abdomen.
- Unless the tube can be seen/felt within the cervical esophagus, none of the above techniques are foolproof. If in doubt, lateral thoracic radiography can be performed ***(Figure 10).***

Contraindications and complications

There are various situations where using a feeding tube is contraindicated or should be used with caution. These include vomiting, dyspnea, or where there is an increased risk for aspiration of gastric contents (*e.g.,* if the swallowing reflex is absent, if the patient has reduced consciousness, or is in lateral recumbency). In addition, a tube may not be suitable if the patient has a head injury involving nose/nasal cavity or pharynx, or if there is a coagulopathy, where tube placement can cause epistaxis.

Various complications can also arise with a feeding tube. These include:

- Epistaxis
- Rhinitis/sinusitis

Figure 8. The tape should be sutured as close as possible to the side of the nasal planum, using the lateral groove as a guide.

© Joris Robben & Chiara Valtolina

ROYAL CANIN®

© Joris Robben & Chiara Valtolina

Figure 9. The tube can be guided along the lateral aspect of the face, with a fixation point on the cheek to hold the tube in place. It can then be taped to a bandage lightly wrapped around the neck.

© Allison Zwingenberger, UCDavis USA

Figure 10. The best method for checking the position of the feeding tube is by obtaining a lateral thoracic radiograph. This figure is a compilation of two separate radiographs and shows a nasal feeding tube which has become looped and accidentally positioned in the trachea.

- Dacryocystitis
- Aspiration pneumonia (if the tube is accidentally placed in the airway or there is food reflux)
- Kinking of the tube (usually where the tube exits the nose; this in turn is dependent on the material used for the tube and how the tube is positioned)
- Clogging of the tube (more common if the tube has a small diameter and/or side holes rather than open ended; inadequate maintenance can also lead to clogging). It is important to flush the tube frequently (see below); a blocked tube may be cleared by installation of water, a carbonated beverage or pancreatic enzyme solutions
- Esophageal irritation or gastric reflux esophagitis
- Tube dislodgement by vomiting or sneezing

The tube may also be removed by the patient, either accidentally or deliberately. Deliberate removal can occur if the patient feels discomfort, *e.g.,* due to irritation from the holding sutures, painful rhinitis, or if the tube interferes with the animal's field of view or facial whiskers (more commonly in cats).

If the cause cannot be determined, or the problem resolved, it may be necessary to use an Elizabethan collar ***(Figure 11)*** or to consider another method of assisted feeding (*e.g.,* an esophageal feeding tube).

Continuous or intermittent feeding?

In a retrospective study looking at both feline and canine patients fed via naso-enteral tube for 24 hours, no significant differences in gastrointestinal complications (vomiting, regurgitation and diarrhea) were demonstrated for

© Joris Robben & Chiara Valtolina

Figure 11. The patient must be checked frequently to ensure the tube remains in place. An Elizabethan collar may be necessary to prevent accidental removal of the feeding tube by the patient.

continuous rate infusion (CRI) versus bolus feeding (2). However, each case should be treated on its own merits and the clinician should be aware of possible problems; for example, it has been reported that cats with feline hepatic lipidosis may have a reduced stomach volume, which could initially increase the risk of emesis, nausea and discomfort if bolus feeding is employed (3).

- **Continuous rate infusion** is recommended for debilitated patients that have been anorexic for a long period of time, as they may have limited gastrointestinal capacity. In such situations, trickle feeding is often combined with the administration of prokinetic drugs (*e.g.*, metoclopramide or cisapride). This method is less labor

intensive and is less likely to cause gastric distension and discomfort during feeding. However, CRI does not resemble normal physiologic food intake, and accumulation of food in the stomach may go unnoticed, leading to regurgitation or vomiting. The liquid diet should be kept at room temperature (*i.e.,* not chilled) and it is important to ensure the food does not precipitate in the syringe or bag; this can be prevented by regular agitation of the mixture.

- **Intermittent (bolus) feeding** can be used in less debilitated patients, *e.g.,* if the animal is discharged with the tube in place for the owner to feed at home. This method is more physiologically normal and allows monitoring of the feeding process, and also permits the clinician to ensure that the stomach does not become overfull. It is, however, more labor intensive and can cause discomfort and nausea in some patients. Always make sure the food is lukewarm and administer it slowly (< 3 mL/kg/min): rapid distension of the stomach in an anorexic patient may cause nausea, discomfort and emesis. A syringe pump can be used to administer small volumes of food at a set pressure; if feeding manually, excess force can cause the tip of the feeding tube to vibrate and induce vomiting; this is more likely with a nasoesophageal tube. After feeding, the tube should be re-flushed and the end closed to prevent food or water escaping.

Tube maintenance

The feeding tube should be checked regularly, at least every 2-4 hours for CRI and before each use for bolus feeding. This involves:

- A visual check to ensure the tube is positioned correctly and that the sutures are holding. If the tube is missing, check to see if the dog has vomited the tube or bitten off the exterior section of the tube.
- Aspirating the tube to determine if food can be retrieved: if a large amount is aspirated with a nasogastric tube it can be an indication of residual stomach contents due to decreased gastrointestinal motility and prolonged stomach emptying. CRI tubes should be flushed regularly – at least every 4-6 hours, or more frequently if required – with 5-10 mL of lukewarm water (depending on the size of the tube) whilst observing the dog for discomfort (*e.g.,* salivation, coughing, gagging, or vomiting); the same technique should be employed for bolus feeding before each meal.

References

1. Herring JM. A novel placement technique for nasogastric and nasoesophageal tubes. *J Vet Emerg Crit Care* 2016;26(4):593-597.
2. Campbell JA, Jutkowitz LA, Santoro KA, *et al.* Continuous versus intermittent delivery of nutrition via nasoenteric feeding tubes in hospitalized canine and feline patients: 91 patients (2002-2007). *J Vet Emerg Crit Care* 2010;20(2):232-236.
3. Armstrong PJ, Blanchard G. Hepatic lipidosis in cats. *Vet Clin North Am Small Anim Pract* 2009;39(3):599-616.

Further reading

- Eirmann L, Michel KE. Enteral nutrition. In: *Small animal critical care medicine*, 2nd ed. Silverstein DC, Hopper K, eds. St. Louis: Elsevier Saunders 2015:681-686.
- Campbell S, Harvey N. Assisted enteral feeding. In: *Advanced monitoring and procedures for small animal emergency and critical care*. Burkitt Creedon JM, Davis H, eds. Ames: Wiley-Blackwell 2012:496-512.
- Dörfelt R. A quick guide to feeding hospitalized cats. *Vet Focus* 2016;26(2): 46-48.

ROYAL CANIN®

ROYAL CANIN®

NUTRITIONAL PERFORMANCE THROUGH INNOVATION & PRECISION

Nutritional precision is part of our DNA. Our expanding knowledge of the nutritional needs of cats and dogs generates product innovation. Together we share your passion in advancing the way we feed and support the health of pets across the world.

royalcanin.com

VETERINARY EXCLUSIVE

© ROYAL CANIN® SAS 2016 - All Rights Reserved.

INCREDIBLE IN EVERY DETAIL

VETERINARY focus

The worldwide journal for the companion animal veterinarian

© Shutterstock

IN OUR NEXT ISSUE...

In our next issue of *Veterinary Focus*, we will look at various aspects relating to fat dogs and thin cats.

- **Practical use of a body condition score model**
  Kazuya Otsuji and Akiko Koizumi, Japan
- **Treating the chronic kidney failure cat with weight loss**
  Jessica Quimby, USA
- **Canine hypothyroidism**
  David Panciera, USA
- **Canine diabetes**
  Federico Fracassi, Italy
- **Canine obesity – How to communicate with the owner**
  Connie Ewering, Germany
- **The genetic predisposition for obesity in dogs**
  Eleanor Raffan and Oliver Forman, UK
- **Radioactive iodine therapy for hyperthyroid cats**
  Elsa Edery, France
- **Disease co-morbidities in underweight cats**
  Emi Saito, USA

ROYAL CANIN®

We welcome offers to write ideas for papers and suggestions for topics and authors, which should be directed to the editor. *Veterinary Focus* is fully covered by copyright. No part of this publication may be reproduced, copied or transmitted in any form or by any means (including graphic, electronic or mechanical), without the written consent of the publishers © Royal Canin 2017. Proprietary names (trademarks) have not been specially identified. It cannot, however, be conducted from the omission of such information that they are non-proprietary names and as such can be used by everyone. The publishers cannot take any responsibility for information provided on dosages and methods of application. Details of this kind must be checked for correctness by the individual user in the appropriate literature. While every effort has been made by the translators to ensure the accuracy of their translations, no responsibility for the correctness of the original articles and thus no resulting claims against professional negligence can be accepted in this connection. Views expressed by authors or contributors do not necessarily reflect the views of the publishers, editors or editorial advisors.

ROYAL CANIN®

THE MOST COMPREHENSIVE RANGE OF GI DIETS AVAILABLE.

When it comes to GI disorders, ROYAL CANIN®'s optimised, adapted diets are part of the solution to manage even your toughest cases.

Contact your ROYAL CANIN® representative today to find out how our tailor-made diets can help you support both your feline and canine patients.

www.royalcanin.com

© ROYAL CANIN® SAS 2016. All Rights Reserved.

VETERINARY DIET