

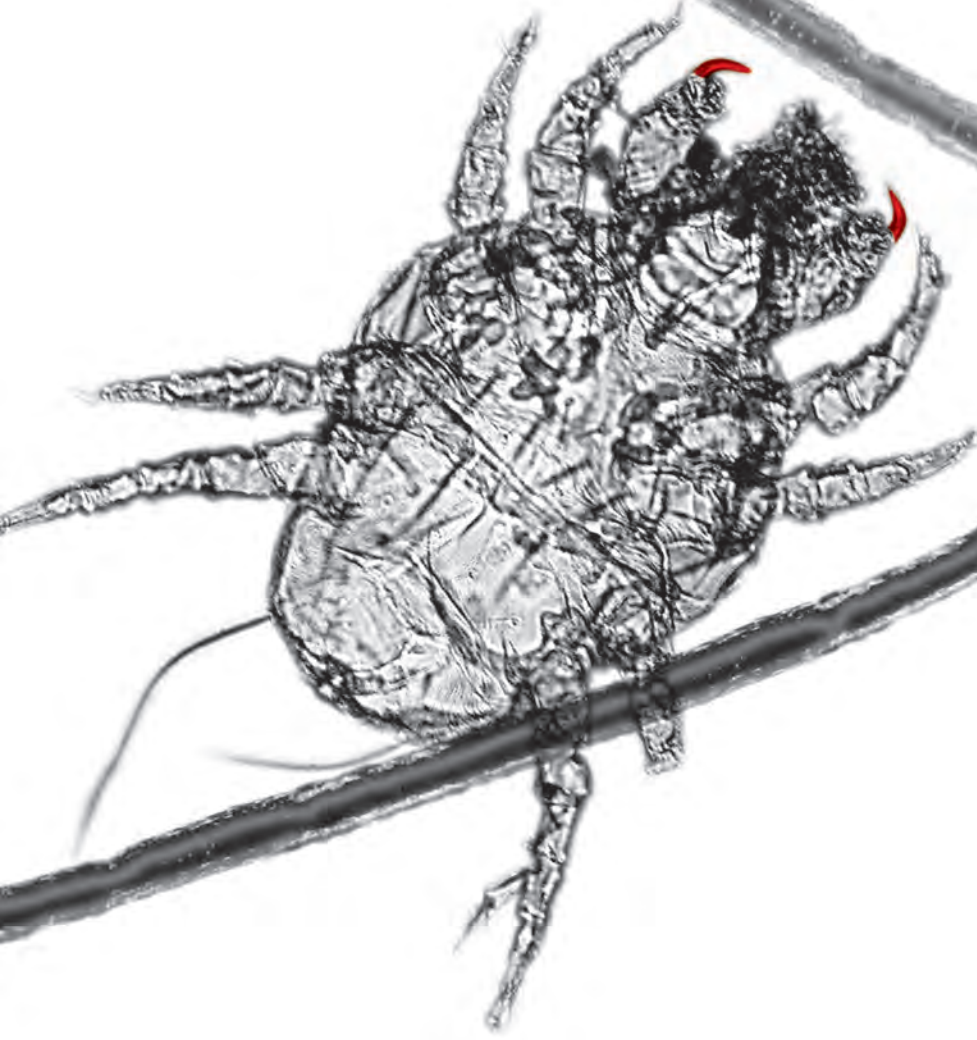# veterinary/ **focus** #31.1

The worldwide journal for the companion animal veterinarian 2021 - \$10 / 10€

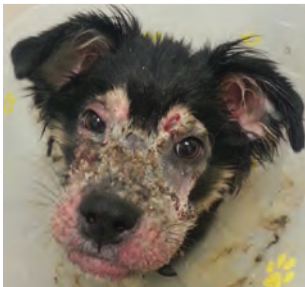## **FELINE**

---

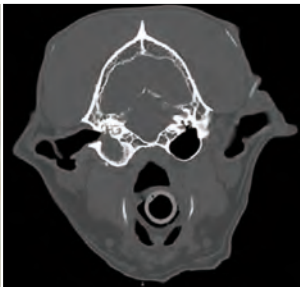
## **DERMATOLOGY**



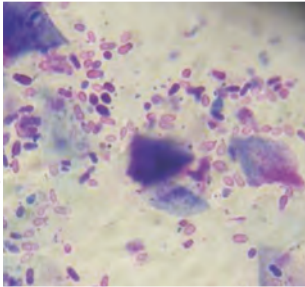
  
**ROYAL CANIN®**



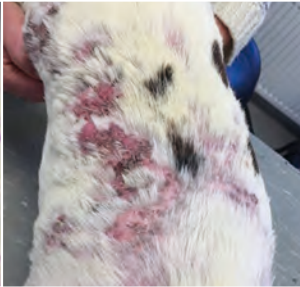© Vincent Defalque



© Royal Veterinary College, London



© M.C. Cadiergues



© Annette van der Lee

## COMING UP...

In our next issue, we will look at various canine dermatology topics.

- **Multidrug-resistant *Staphylococcus* infections**  
*Laura Buckley and Eleanor Wyatt, UK*
- **Canine otitis media and externa**  
*Hannah Lipscomb and Filippo De Bellis, UK*
- **Isoxazolines for canine demodicosis**  
*Vincent Defalque, Canada*
- **Cold plasma therapy for wound healing**  
*Christoph Klinger, Germany*
- **Canine food allergies**  
*Elisa Maina, Italy*
- **Atopic dermatitis – multimodal treatment options**  
*Annette van der Lee, The Netherlands*
- **Atopic dermatitis – diagnosis and immunotherapy**  
*Ana Rostaher, Switzerland*
- **Cutaneous signs of hyperadrenocorticism**  
*Fiona Scholz and Sam Crothers, Australia*



Origine du papier : VIRTON (Belgique)  
Taux de fibres recyclées : 0%  
Certification : 100% PEFC  
Impact sur l'eau : 0.012 P tot kg/tonne



### Editorial committee

- Craig Datz, DVM, Dip. ACVN, Senior Scientific Affairs Manager, Royal Canin, USA
- Mark Edwards, BVSc, MRCVS, Regional Scientific Communications Manager Asia Pacific, Royal Canin, New Zealand
- María Elena Fernández, DVM, Spain
- Bérengère Levin, DVM, Scientific Affairs Manager, Royal Canin, France
- Philippe Marniquet, DVM, Dip. ESSEC, Veterinarian Prescribers Marketing Manager, Royal Canin, France
- Anita Pachatz, DVM, Scientific Communication Manager, Royal Canin, Austria
- Sally Perea, DVM, Dip. ACVN, Augmented Algorithms Certified Nutritionist, Royal Canin, USA
- Alice Savarese, BMedBiotech, DVM, PhD, Scientific Communication Specialist, Royal Canin, Italy
- Heather Weese, BSc, DVM, MSc Scientific Affairs Manager, Royal Canin, Canada
- Daphne Westgeest, DVM, Scientific Communication Advisor, Royal Canin Belux

### Translation control

- Andrea Bauer-Bania, DVM (German)
- Alicia Cózar, DVM, Acred. AVEPA Dermatología, CPCert. Medicina Felina (Spanish)
- Sergey Perevozchikov, DVM, PhD (Russian)

**Deputy publisher:** Buena Media Plus  
Chairman: Julien Kouchner;  
CEO: Bernardo Gallitelli  
11-15, quai De Dion-Bouton  
92800 Puteaux, France  
**Phone:** +33 (0) 1 76 21 91 78

**Editor-in-chief:** Ewan McNeill, BVMS, Cert VR, MRCVS

### Editorial secretary

- Laurent Cathalan  
(laurent.cathalan@1health.fr)

### Artwork

- Pierre Ménard

**Printed in the European Union**  
ISSN 2430-7874

**Legal deposit:** March 2021

**Cover:** Sandrine Fontègne

**Authors portraits:** Manuel Fontègne  
*Veterinary Focus* is published in Brazilian Portuguese, English, French, German, Italian, Polish, Russian, Spanish and Korean.

**Find the most recent issues on:**  
<https://vetfocus.royalcanin.com>  
and [www.ivis.org](http://www.ivis.org).

The licensing arrangements for therapeutic agents intended for use in small animal species vary greatly worldwide. In the absence of a specific license, consideration should be given to issuing an appropriate cautionary warning prior to administration of any such drug.

*Veterinary Focus* is fully covered by copyright. No part of this publication may be reproduced, copied or transmitted in any form or by any means (including graphic, electronic or mechanical), without the written consent of the publishers © Royal Canin SAS 2021. Proprietary names (trademarks) have not been specially identified. It cannot, however, be conducted from the omission of such information that they are non-proprietary names and as such can be used by everyone. The publishers cannot take any responsibility for information provided on dosages and methods of application. Details of this kind must be checked for correctness by the individual user in the appropriate literature. While every effort has been made by the translators to ensure the accuracy of their translations, no responsibility for the correctness of the original articles and thus no resulting claims against professional negligence can be accepted in this connection. Views expressed by authors or contributors do not necessarily reflect the views of the publishers, editors or editorial advisors.

## THE ART OF THE POSSIBLE

*“I would like my portrait to depict me with pimples, warts and everything”*

– Oliver Cromwell

Politics, it is said, is the art of the possible. Or to put it another way, you can't please all the people all the time, but you can try to please most of the people most of the time by making decisions and choosing strategies that the majority of the population find acceptable. Although of course a government will always try to present its policies with an attractive aura, whatever the actuality.

However, one man who would probably not concur with this idea was Oliver Cromwell, the general and politician who challenged King Charles I during the English Civil War, removing the monarch and turning the country into a republic. He was renowned, amongst other things, for his military astuteness and blunt, forthright speech, but not, however, for his looks. He was, by all accounts, fairly ugly in appearance, and there is a widely told tale that, when sitting for his portrait, he commanded the artist to paint him without flattery or enhancement. “Remark all these roughness, pimples, warts and everything” he was alleged to have declared, giving rise to a phrase now in common use in the English language; when we require a comprehensive briefing on a certain matter, with the bad points as well as the good ones, we will ask to know everything - “warts and all.”

Which brings us, in an elliptical way, to the topic of this issue. There are in fact no actual warts or pimples in the pages that follow, but the images are far from pretty and the articles do not flatter, as they starkly reveal the problems that can occur when the feline

epidermis loses its health. However, they also offer the means by which we can restore it to health. In short, the authors describe many aspects of feline dermatology without fear or favour, with no attempt to hide inconvenient details, in a way that we might call warts and all. They may even have achieved that rare accomplishment, by pleasing all of our readers all of the time.



**Ewan McNEILL**  
Editor-in-chief

## In this issue of *Veterinary Focus*

### Feline cutaneous adverse food reactions p.02

Sarah E. Hoff and Darren J. Berger

### Feline atopic dermatitis demystified p.09

Jennifer R. Schissler

### Therapeutic options for the pruritic cat p.15

Jay Korbelic

### Feline dermatophytosis p.20

Amelia G. White

### Feline pododermatitis p.26

Ronnie Kaufmann

### Diseases of the feline nasal planum p.33

Christina M. Gentry

### Feline cutaneous lymphoma p.40

Hannah Lipscomb and Filippo De Bellis

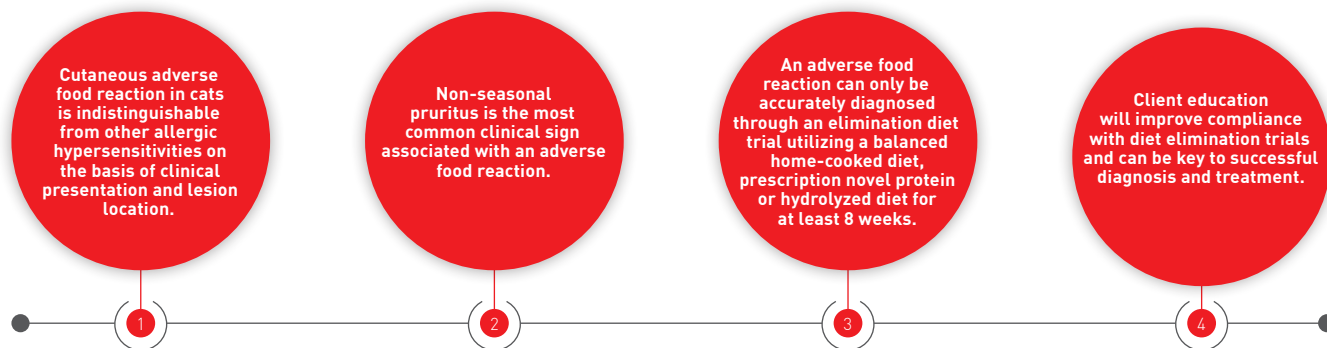### Elizabethan collars for cats p.47

Anne Quain

# FELINE CUTANEOUS ADVERSE FOOD REACTIONS

Owners are often keen to blame their cat's diet if their pet develops a skin problem, but is this correct? In this article the authors discuss appropriate methods for the diagnosis and treatment of adverse food reactions.

## KEY POINTS



## Introduction

A common misconception amongst pet owners is that clinical signs of a food allergy occur soon after a change of diet. While adverse reactions to foods can occur shortly after a new diet is introduced, such reactions are rarely allergic in nature because of the time required to develop an immunologic response, and it is important to educate owners on the distinction between food *intolerance* and food *allergy*. Food intolerance represents any abnormal physiological response that is not immunologically mediated to a component, toxin, or product in the food that results in an undesirable side effect (1). The most common example is lactose intolerance, in which the inability to digest lactose results in hyper-osmotic diarrhea and subsequent flatulence, abdominal discomfort and diarrhea. Food allergy, on the other hand, refers to an immunological reaction to a component in a food, and may be either an immediate type I hypersensitivity reaction, mediated through IgE, or a delayed type hypersensitivity, mediated through lymphocytes and their cytokines (1). In animals the distinction between food intolerance and food allergy may be difficult to make, and thus the term “adverse food reaction” has been proposed to encompass all etiologies that result in a clinically abnormal response attributable to the ingestion of a food substance (2). In the cat, adverse food reactions most commonly manifest as skin disease and gastrointestinal disease, although more rarely they can result in conjunctivitis, rhinitis, neurological signs, and behavioral abnormalities (1,3). This article will primarily discuss manifestations of cutaneous adverse food reactions (CAFR).

## Initial investigations for CAFR

CAFR is a relatively uncommon diagnosis in cats, with the overall reported prevalence ranging from 0.2-6%, although prevalence greatly increases amongst cats presenting to a veterinarian for a primary complaint of pruritus (12-21%) or allergic skin disease (5-13%) (4), and a structured approach to diagnosis is essential.

## History and clinical presentation

In order to make an accurate diagnosis and treatment plan, the importance of obtaining a complete history cannot be understated; this includes a thorough diet history, which helps to determine previous exposures and guide future treatments. Examples of important questions to ask owners regarding their cat's skin disease are listed in **Table 1**, and information gained from a thorough history can narrow the differential list and help guide next steps. For example, the absence of a regular flea control program may make flea allergy dermatitis a primary differential, and if multiple animals from a household are displaying clinical signs a contagious parasite or pathogen is more likely.

Clinical signs of CAFR can appear at any age but are most commonly seen in young to middle aged cats, with an average age at onset of 3.9 years, and there does not appear to be a clear breed or sex predilection (5). The most frequent clinical sign is non-seasonal pruritus (5), with a variable



## Sarah E. Hoff,

DVM, MPH, Iowa State University, College of Veterinary Medicine, USA

Dr. Hoff completed a Masters of Public Health in epidemiology prior to attending veterinary school at the University of Missouri. After graduation she spent three years in small animal general practice before pursuing specialization in dermatology. She is currently a third-year dermatology resident at Iowa State University.



## Darren J. Berger,

DVM, Dip. ACVD, Iowa State University, College of Veterinary Medicine, USA

Dr. Berger qualified from Iowa State University in 2007 and worked in small animal practice for some years before returning to academia. He is currently an Associate Professor of Dermatology at Iowa State University's College of Veterinary Medicine, with research interests that include clinical pharmacology and the management of allergic hypersensitivity disorders.

prevalence of concurrent gastrointestinal signs, reported at around 17-22% of affected cats (2). When present, the most common gastrointestinal sign associated with an adverse food reaction is vomiting, followed by flatulence and diarrhea (3).

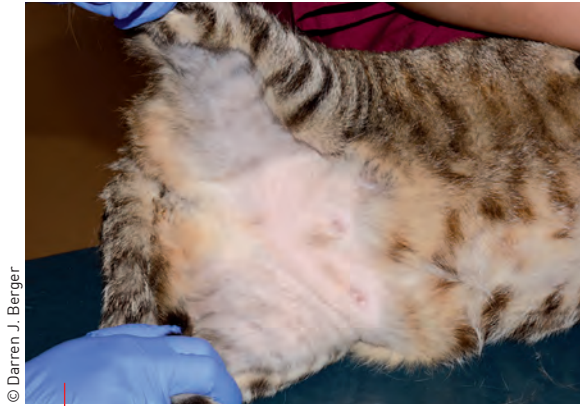Previous response to therapy can be variable. One study reported that all 17 cats diagnosed with CAFR had at least a partial response to either systemic or topical glucocorticoids (6), but another retrospective study of 48 affected cats noted that systemic glucocorticoids were ineffective in 61% of cases (7). In a third study of 10 cats with CAFR, owners reported no benefit from injectable long-acting glucocorticoids (8).

## Physical examination

Physical exam may reveal one of several cutaneous reaction patterns: lesion-less pruritus, self-induced alopecia (**Figure 1**), miliary dermatitis (**Figure 2**), and lesions of eosinophilic skin diseases, namely indolent ulcers, eosinophilic plaques and eosinophilic granulomas (**Figures 3 and 4**) (2). The areas most commonly affected include the face/head, ears, ventrum, and feet (5), but these signs are not pathognomonic for CAFR and there are many other disease processes that can produce identical signs (**Table 2**). Part of the physical examination should include a thorough brushing with a flea comb to look for evidence of fleas, lice,

**Table 1.** Sample questions for acquisition of a complete history.

Medical history	Diet history	Lifestyle	Medication use
<ul style="list-style-type: none"> <li>Describe your pet's problem.</li> <li>How long has the problem been present?</li> <li>Does time of year affect your pet's problem?</li> <li>How often does your cat vomit?</li> <li>How often does your cat have hairballs?</li> <li>Does your cat have recurrent bouts of diarrhea and/or flatulence?</li> <li>Does your cat have any respiratory signs (wheezing, coughing, difficulty breathing)?</li> <li>Has your cat been tested for FeLV or FIV? Results?</li> <li>Does your cat have a history of any other health issues?</li> </ul>	<ul style="list-style-type: none"> <li>What food does your cat currently eat? (brand, flavor, wet or dry, commercial diet or home-made?)</li> <li>What food has your cat eaten in the past? (brand, flavor, wet or dry, commercial diet or home-made?)</li> <li>What treats or table foods does your cat eat?</li> <li>Do you feed your cat at specific meal-times or does he/she graze throughout the day?</li> <li>Do you give your cat any supplements or dental chews?</li> </ul>	<ul style="list-style-type: none"> <li>How often does your cat go outside?</li> <li>Does he/she hunt?</li> <li>How many other animals are in the household? Are any of them affected?</li> <li>When was the last cat brought into the household?</li> <li>Have there been any new additions to the household?</li> <li>Do any of the humans in the household have skin problems?</li> <li>Have there been any changes in how much your cat eats or drinks?</li> </ul>	<ul style="list-style-type: none"> <li>What type of flea treatment do you use for your cat?</li> <li>When was flea treatment last used?</li> <li>What flea treatment is used for the other animals in the house?</li> <li>What therapies have been tried in the past for this problem? How effective were they?</li> </ul>



© Darren J. Berger

**Figure 1.** Self-induced ventral alopecia, often with no obvious lesions, is a common presentation in cats with skin disease.

and mites (*Cheyletiella* spp.), although the absence of fleas (and flea dirt) does not exclude the parasite, as cats are efficient groomers and may remove all evidence of fleas.

## Dermatological database

As CAFR is a relatively uncommon diagnosis, appropriate diagnostics and therapies should be performed to rule out as many differentials as possible. A dermatological database (skin scraping, cytology, trichogram and fecal flotation) should be performed at initial presentation to exclude conditions that can present similarly to CAFR as well as to identify any secondary infections or parasitic infestations. Cats may have secondary bacterial or *Malassezia* infections which can exacerbate pruritus caused by the underlying condition (6). If not previously performed, a fungal culture or ringworm PCR should be considered, as feline dermatophytosis commonly presents with lesions affecting the head and neck as well as variable pruritus (9). Although traditionally thought to be a contagious disease, individual animals can be more susceptible to dermatophyte infections, and other animals may be asymptomatic carriers (9), so the absence of multiple animals or humans displaying clinical signs does not exclude dermatophytes as a potential underlying cause.

## ●●● Specific CAFR diagnostics



Once other diseases have been ruled out, a diagnostic test for CAFR that is simple to perform, relatively inexpensive, and gives an accurate diagnosis would be ideal. However, to date no such test has been found to meet these criteria (10). There are however various proposed tests for CAFR.

## Histopathology

While skin biopsies are useful for the diagnosis of many skin diseases and may aid in eliminating some differentials, there are no pathognomonic findings to definitively diagnose CAFR. Biopsy of animals with CAFR usually demonstrate a perivascular dermatitis characterized by a variable cellular infiltrate consisting of lymphocytes, eosinophils, mast cells, neutrophils, and macrophages. However, these

changes are nonspecific and can be seen with any allergic etiology, so biopsies of animals with CAFR, flea allergy dermatitis, and non-flea, non-food-induced hypersensitivity dermatitis (NFNFIHD) will all exhibit similar changes. Skin biopsy alone cannot therefore distinguish between these allergic etiologies, and likewise intestinal biopsies of animals with concurrent gastrointestinal signs will give a histologic diagnosis but not an etiological diagnosis, and cannot distinguish between animals with adverse food reactions and non-food reactions (10).

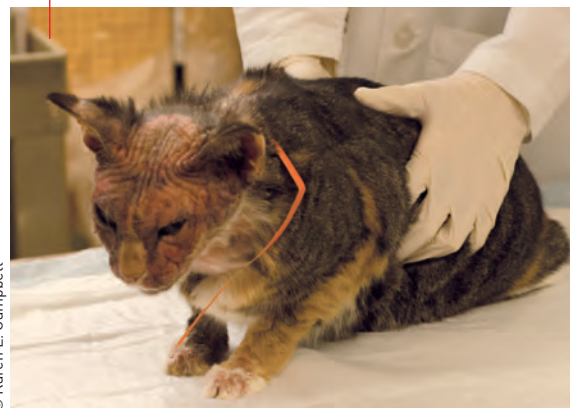## Serum IgE tests

In humans, food-specific serum IgE levels aid in the diagnosis of food allergies (11), because many of the reactions observed in people are immediate type I-hypersensitivity reactions mediated through IgE. However, in animals this phenomenon appears to be quite rare (11). Therefore the significance of food-specific IgE that can be detected in serum of cats (and dogs) is unknown, with studies demonstrating that animals with no clinical signs of CAFR can have food-specific IgE detectable in their serum, even for foods they have no history of consuming (10). Numerous studies show that food-specific serum IgE fails to accurately diagnose animals with CAFR when compared with results from elimination diet trials, and the tests themselves have inconsistencies, as the repeatability has been shown to be low (10). A recent review paper concluded that there is little evidence to support their use in animals and they cannot be recommended at this time (2).

## Skin prick and patch testing

Another diagnostic method utilized in humans to aid in the diagnosis of food allergies is skin prick testing (12). This involves introduction of the allergen into the epidermis with monitoring for subsequent wheal formation, which is indicative of an IgE-mediated response. In people, this test has a high level of sensitivity (~90%), but low specificity (~50%) (12), and because of this it is not recommended for routine screening for human food allergies. Intradermal testing for food allergens has been performed in dogs but not cats, with studies

**Figure 2.** Head and neck excoriations may be seen in cats as part of a miliary pattern of dermatitis secondary to CAFR.



© Karen L. Campbell

showing that skin tests did not have adequate positive or negative predictive values to recommend them for use, nor could they distinguish atopic dogs from those with CAFR (10). Patch testing – which involves directly applying a food substance to the skin and noting signs of irritation – has been evaluated in two canine studies; these tests have shown low positive predictive values but high negative predictive values, and a recent review paper concluded that whilst they may be useful for selecting proteins to use in an elimination diet, they cannot be employed to diagnose CAFR (2). Therefore, it is unlikely that these tests will be beneficial in the diagnosis of feline CAFR.

## Hair and saliva analysis

Studies have shown that hair and saliva analysis are not reproducible, as duplicate samples from the same animal result in disparate results (13). Furthermore, such tests have been unable to distinguish between allergic and non-allergic dogs, nor can they distinguish between inanimate (e.g., teddy bear fibers) and living samples (13). A recent study that evaluated the specificity, sensitivity, and positive and negative predictive values of saliva testing found that overall the results were too low to recommend their use for CAFR diagnosis (2).

**Table 2.** Differential diagnoses and recommended diagnostics for cutaneous adverse food reactions in the cat.

Differential diagnoses	Recommended diagnostics
Flea allergy dermatitis	Physical examination, flea comb, response to parasite control, fecal flotation, evidence of tapeworms
<i>Demodex gatoi</i>	Skin scraping, fecal flotation, response to treatment
<i>Cheyletiella</i> spp.	Physical examination, skin cytology, skin scraping, flea comb, fecal flotation
<i>Otodectes cynotis</i> or <i>Notoedres cati</i>	Physical examination, skin/ear cytology, skin scraping
Dermatophytosis	History, trichogram, Wood's lamp, DTM culture, fungal PCR
Autoimmune diseases (pemphigus foliaceus)	Skin cytology, biopsy and histopathology
Endocrinopathies (hyperthyroidism, diabetes, etc.)	History, bloodwork and urinalysis
Cutaneous adverse drug reaction	History, biopsy and histopathology
Viral diseases (herpesvirus, papillomavirus, calicivirus, poxvirus, feline leukemia virus)	Biopsy and histopathology, PCR, immunohistochemistry
Non-flea, non-food induced hypersensitivity dermatitis (NFNFIHD)	History, excluding other differentials
Psychogenic alopecia	History, response to treatment, excluding all other differentials



**“While adverse reactions to foods can occur shortly after a new diet is introduced, such reactions are rarely allergic in nature because of the time required to develop an immunologic response, and it is important to educate owners on the distinction between food intolerance and food allergies.”**

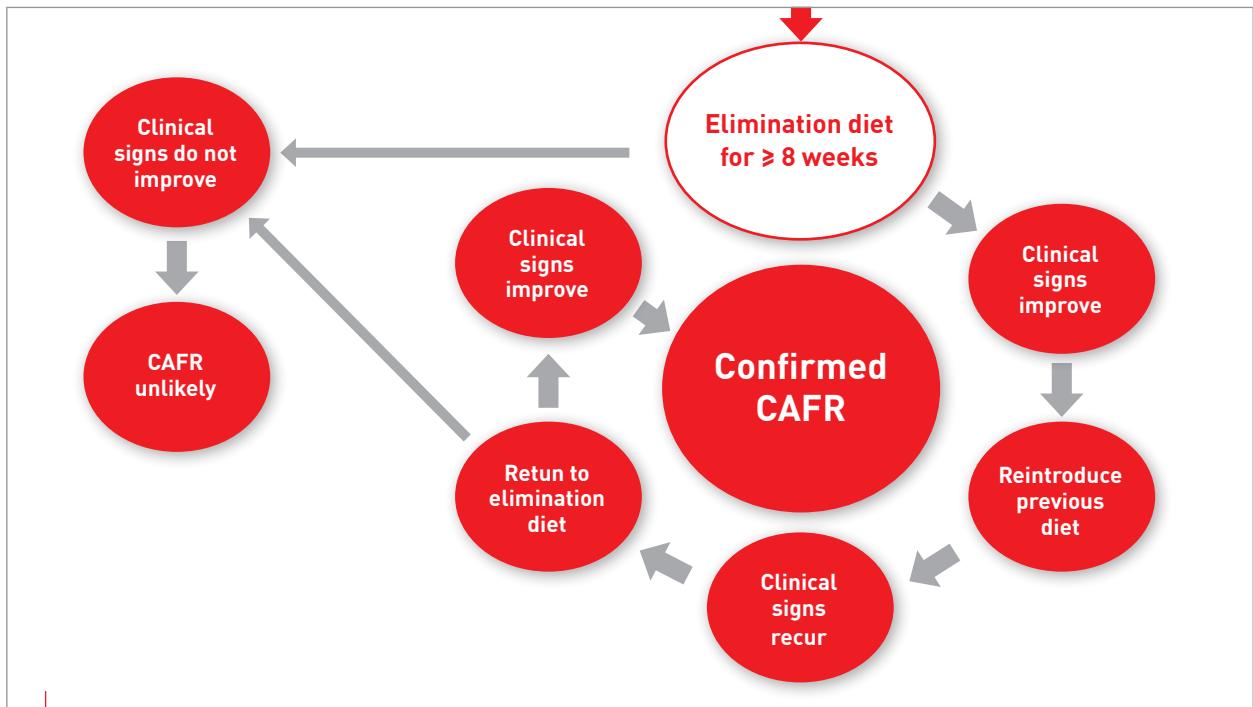
Sarah E. Hoff



## Elimination diet trial

The only method that has been shown to be a reliable diagnostic tool for diagnosis of an adverse food reaction is an elimination diet trial (10). The theory is that removal of the offending agent from the animal's diet should result in an improvement of clinical signs, although one of the most challenging aspects is determining what antigen is stimulating an individual animal's clinical signs. Through individual constituent provocation tests, the ingredients most likely to result in an adverse reaction in cats as identified by a recent literature review were beef, fish, and chicken (2), and the choice of an elimination diet would ideally avoid such ingredients.

Confirmation of an adverse food reaction is a multi-step process (**Box 1**). Firstly, the cat has to eat the elimination diet for a specified period of time and exhibit an improvement in clinical signs. A recent review of published studies concluded that up to 90% of cats with an eventual diagnosis of CAFR will experience a remission in their clinical signs by 8 weeks, therefore the current recommendation is that an elimination diet trial should be for at least this period in order to maximize the likelihood of correctly identifying an affected animal (14). To confirm that the food has been responsible for remission of the clinical signs, the cat's diet then needs to be “challenged” by adding some of the old diet to the elimination diet. Most cats with an adverse food reaction will exhibit an exacerbation of clinical signs within 2-3 days, but this has been reported to take up to 14 days in some cases (6). Some animals may improve on the elimination diet but fail to relapse when challenged with the previous diet, and in these circumstances the initial improvement may be attributable to other therapies such as flea control or treatment of secondary infections, the improved quality of fatty acids and proteins in the elimination diet, or a change of season (2). If the cat worsens when exposed to the previous diet,



**Box 1.** A flow diagram of the recommended diagnostic pathway for CAFR.

the elimination diet is then fed exclusively again. If the clinical signs subsequently improve, a diagnosis of CAFR is confirmed. In order to identify the specific offending allergen, different foods may be added weekly or biweekly and the animal observed for an exacerbation of the clinical signs.

The three choices for an elimination diet trial are a home-cooked diet using a novel protein and carbohydrate source, a commercial novel protein diet, or a commercial hydrolyzed protein diet.

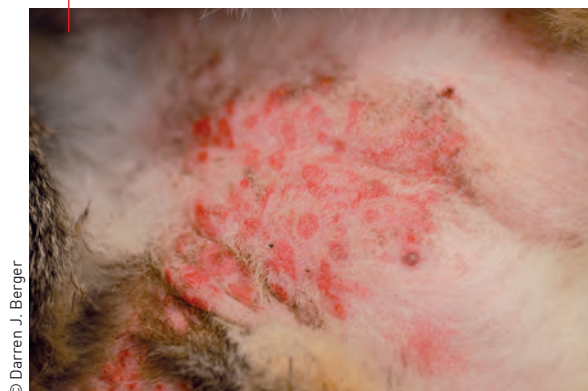Home-cooked options for diet elimination trials offer the opportunity to eliminate the possibility of confounding ingredients (e.g., corn starch, by-products, etc.) [1]. Although a small retrospective study has reported that such diets were more sensitive for the diagnosis of feline CAFR [6], a thorough dietary history is needed to ensure that both the protein source and the carbohydrate source are truly novel (i.e., never eaten before). Home-cooked diets are more labor intensive and require consultation with a veterinary nutritionist to ensure that the diet is balanced in order to avoid adverse events associated with nutritional deficiencies. As a result, practitioners and owners may elect to pursue a trial with a commercial prescription diet to avoid such potential complications.

Certain commercial novel protein diets are a good alternative, especially if owners are unwilling or unable to cook for their pet. As with home-cooked diets, it is important to obtain a full dietary history to avoid selecting a protein source to which the cat has previously been exposed. However, the origin of the diet should also be given consideration; owners will sometimes seek over-the-counter (instead of “prescription”) diets which are often labelled as having “limited ingredients” or “novel protein”, but

many of them have not undergone testing to ensure their purity, and have been shown to contain ingredients not listed on the label [15]. Such unidentified ingredients can negate the benefit from changing the main protein source, as animals may have sensitivities to these contaminants [15]. Even raw diets have been found to have similar mislabeling concerns [16], so over-the-counter diets are not acceptable for elimination diet trials. At this time only appropriate prescription diets should be considered an acceptable choice for such trials.

An additional complicating factor is that there are many reports of cross-reactivity between proteins, so finding a truly novel protein may be challenging. It has been shown that there are common allergens amongst avian species, so feeding a duck diet to an animal previously exposed to chicken may not be a truly novel protein source [17]. It has also been hypothesized that cross-sensitizations exist amongst ruminant

**Figure 3.** Eosinophilic plaques and hair loss secondary to CAFR on a cat’s ventrum.



© Darren J. Berger



species, meaning that for an animal previously exposed to beef, certain ingredients such as lamb, venison, and bison may not be truly novel (18).

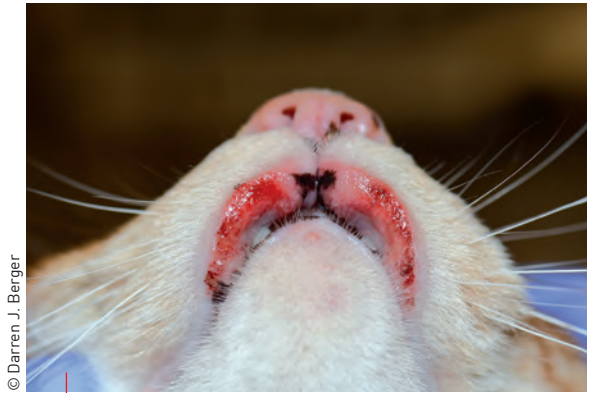For these reasons many veterinarians will utilize prescription hydrolyzed protein diets, where processing produces peptide segments that are anticipated to be small enough to prevent cross-linking of mast cells which would otherwise result in an allergic response. In people, food allergens typically have a molecular weight of around 10-70 kDa (1) but the size of peptide required to minimize the possibility of an allergic response in animals is yet to be determined. There is the potential that an animal may react to the parent protein if the hydrolysate offered is not small enough, and it is recognized that peptide size can vary between different diets. Along these lines, a crossover study of ten known chicken-allergic dogs compared two hydrolyzed diets with different parent proteins and hydrolysis methods [extensively hydrolyzed poultry feathers and hydrolyzed chicken livers]. Owners were asked to score the degree of pruritus, and 4 out of the 10 dogs exhibited an increase in pruritus when fed the hydrolyzed chicken liver diet, whereas none flared when fed the extensively hydrolyzed poultry feather diet (19). To date, no such study has been conducted in cats, with one challenge being that many of these diets may not be palatable to cats. The small peptide size also introduces the risk that hyper-osmotic diarrhea may develop in animals fed such a diet (20).

Some recent studies have brought into question the ability of hydrolyzed protein diets to accurately diagnose CAFR in dogs and cats. The report referred to above (6) found that 50% of cats in the study could not be diagnosed using a hydrolyzed diet and required a home-cooked recipe for accurate diagnosis of CAFR, although this was a small retrospective study and a variety of elimination diets were employed. A study evaluating the reactivity of lymphocytes of dogs with CAFR to residual proteins and peptides (>1 kDa) in two commercial hydrolyzed protein diets found that the residual proteins stimulated lymphocyte activity in approximately 30% of cases



**“Owners will sometimes seek over-the-counter diets which are often labelled as being “limited ingredients” or “novel protein”, but many of these have not undergone testing to ensure their purity, and have been shown to contain ingredients not listed on the label.”**

Darren J. Berger



© Darren J. Berger

**Figure 4.** Bilateral indolent ulcers on the upper lip of a cat secondary to CAFR.

(21), although as this was an *in vitro* study it is unknown if this finding is clinically significant. However, given the limited number of novel proteins available, potential cross-reactions between protein sources, and the challenges in formulating and preparing home-made diets, hydrolyzed protein diets still remain a good option for use in an elimination diet trial.

## ●●●● Client education for maximizing compliance

One of the challenges with elimination diet trials is that they rely on the owners to ensure accurate completion. A recent survey of dog owners reported that almost 60% did not strictly adhere to the elimination diet, with reasons that included perceived barriers such as lifestyle, cost or ability to administer medications (22). Owners were however more likely to be compliant if they had knowledge regarding diets and CAFRs, and such observations underscore the importance of communication and client education when recommending a diet trial.

Finding an elimination diet that a cat will eat may be challenging in itself. It is important to stay in contact with the owners during a trial, and for them to carefully monitor their pet's eating habits, as problems such as hepatic lipidosis can develop in anorectic cats (2). It may take more than one attempt to find a suitable diet for the trial. For multiple cat households, feeding an elimination diet to only the affected cat can also be problematic. Commercial prescription diets are well-balanced and labelled for maintenance of adult cats, and can therefore be appropriate to feed to all cats. If owners wish to limit the cost associated with the prescription diet and feed only the affected cat, the cat may be separated for feeding or a microchip feeder (which will open only for an individual animal to eat) may be utilized.

## ●●●● Control of pruritus

As stated earlier, it may take up to eight weeks for some animals to show improvement in their clinical signs. A recent study in dogs with non-seasonal

pruritus showed that initial treatment with anti-inflammatory doses of glucocorticoids for at least two weeks may shorten the length of the trial by two to four weeks (23). A reduction of pruritus in the initial stages of the diet elimination trial may also improve compliance, as owners may see an improvement before the end of the diet trial.

## Long-term prognosis

The overall approach to the diagnosis and management of feline CAFR essentially involves excluding other possible differential diagnoses for the clinical signs and correct implementation of an elimination diet trial before ensuring long-term avoidance of the offending allergen. Dietary control is the preferred long-term strategy for managing confirmed cases of CAFR, and if a home-cooked diet was used for the elimination diet trial, it is important to use a balanced diet for long-term management. This may involve consultation with a veterinary nutritionist to formulate a balanced home-cooked diet, or a trial of a prescription novel protein or hydrolyzed diet without the offending allergen. One study found that up to 50% of patients that improved on a home-cooked diet could not be managed on a commercial diet without a relapse of clinical signs (6), which led to speculation that there was something in the commercial diet that the cat reacted to, be that an additive, a by-product, or the way proteins are denatured during cooking. While it is possible for a cat to develop new food sensitivities over time, this appears to be quite uncommon and is rarely reported (7). Therefore,

finding a balanced home-cooked or commercial diet that keeps the clinical signs in remission will likely lead to long-term control.

If a cat previously diagnosed with a CAFR exhibits new cutaneous signs, it is possible that they have developed concurrent NFNFIHD or flea allergy dermatitis. In fact, concurrent NFNFIHD and CAFR is more common in the cat than concurrent CAFR and atopy in the dog (24), with one study reporting that up to 50% of cats with CAFR were also diagnosed with NFNFIHD (6). The same initial diagnostic evaluation utilized for CAFR will be useful to rule out any mimickers of allergic disease.

## CONCLUSION

While the overall prevalence of CAFR in the cat is low, it should be a differential in any animal that presents with a history of non-seasonal cutaneous lesions or pruritus with or without concurrent gastrointestinal signs. The only method shown to reliably and accurately diagnose CAFR is a trial of at least 8 weeks using an appropriate elimination diet, possibly with concurrent oral steroids to reduce pruritus in the initial stages of the trial. Once CAFR has been confirmed, avoidance of the offending allergen is the treatment of choice, and any future exacerbations of pruritus are more likely due to development of concurrent disease rather than a new adverse food reaction.



## REFERENCES

1. Verlinden A, Hesta M, Millet S, et al. Food allergy in dogs and cats: a review. *Crit Rev Food Sci Nutr* 2006;46:259-273.
2. Mueller RS, Unterer S. Adverse food reactions: pathogenesis, clinical signs, diagnosis and alternatives to elimination diets. *Vet J* 2018;236:89-95.
3. Mueller RS, Olivry T. Critically appraised topic on adverse food reactions of companion animals (6): prevalence of noncutaneous manifestations of adverse food reactions in dogs and cats. *BMC Vet Res* 2018;14:341.
4. Olivry T, Mueller RS. Critically appraised topic on adverse food reactions of companion animals (3): prevalence of cutaneous adverse food reactions in dogs and cats. *BMC Vet Res* 2016;13:51.
5. Olivry T, Mueller RS. Critically appraised topic on adverse food reactions of companion animals (7): signalment and cutaneous manifestations of dogs and cats with adverse food reactions. *BMC Vet Res* 2019;15:140.
6. Vogelnest LJ, Cheng KY. Cutaneous adverse food reactions in cats: retrospective evaluation of 17 cases in a dermatology referral population (2001-2011). *Aust Vet J* 2013;91:443-451.
7. Scott D, Miller W. Cutaneous food allergy in cats: a retrospective study of 48 cases (1988-2003). *Jpn J Vet Dermatol* 2013;19:203-210.
8. Carlotti D, Remy I, Prost C. Food allergy in dogs and cats; a review and report of 43 cases. *Vet Dermatol* 1990;1:55-62.
9. Moriello KA, Coyner K, Paterson S, et al. Diagnosis and treatment of dermatophytosis in dogs and cats: Clinical Consensus Guidelines of the World Association for Veterinary Dermatology. *Vet Dermatol* 2017;28:266-e268.
10. Mueller RS, Olivry T. Critically appraised topic on adverse food reactions of companion animals (4): can we diagnose adverse food reactions in dogs and cats with *in vivo* or *in vitro* tests? *BMC Vet Res* 2017;13:275.
11. Pali-Schöll I, De Lucia M, Jackson H, et al. Comparing immediate type food allergy in humans and companion animals – revealing unmet needs. *Allergy* 2017;72(11):1643-1656.
12. Kulis M, Wright BL, Jones SM, et al. Diagnosis, management, and investigational therapies for food allergies. *Gastroenterology* 2015;148:1132-1142.
13. Bernstein JA, Tater K, Bicalho RC, et al. Hair and saliva analysis fails to accurately identify atopic dogs or differentiate real and fake samples. *Vet Dermatol* 2019;30:105-e128.
14. Olivry T, Mueller RS, Prélaud P. Critically appraised topic on adverse food reactions of companion animals (1): duration of elimination diets. *BMC Vet Res* 2015;11:225.
15. Olivry T, Mueller RS. Critically appraised topic on adverse food reactions of companion animals (5): discrepancies between ingredients and labeling in commercial pet foods. *BMC Vet Res* 2018;14:24.
16. Cox A, Defalque V, Udenberg T, et al. Detection of DNA from undeclared animal species in commercial canine and feline raw meat diets using qPCR. In: Abstracts North American Veterinary Dermatology Forum 2019. *Vet Dermatol* 2019;296.
17. Kelso JM, Cockrell GE, Helm RM, et al. Common allergens in avian meats. *J Allergy Clin Immunol* 1999;104:202-204.
18. Gaschen FP, Merchant SR. Adverse food reactions in dogs and cats. *Vet Clin North Am Small Anim Pract* 2011;41:361-379.
19. Bizikova P, Olivry T. A randomized, double-blinded crossover trial testing the benefit of two hydrolysed poultry-based commercial diets for dogs with spontaneous pruritic chicken allergy. *Vet Dermatol* 2016;27:289-e270.
20. Marsella, R. Hypersensitivity Disorders. In: Miller WH, Griffin CE, Campbell KL, et al (eds). *Muller & Kirk's Small Animal Dermatology* 7<sup>th</sup> ed. St. Louis, Mo.: Elsevier/Mosby, 2013;363-431.
21. Masuda K, Sato A, Tanaka A, et al. Hydrolyzed diets may stimulate food-reactive lymphocytes in dogs. *J Vet Med Sci* 2020;82:177-183.
22. Painter MR, Tapp T, Painter JE. Use of the Health Belief Model to identify factors associated with owner adherence to elimination diet trial recommendations in dogs. *J Am Vet Med Assoc* 2019;255:446-453.
23. Favrot C, Bizikova P, Fischer N, et al. The usefulness of short-course prednisolone during the initial phase of an elimination diet trial in dogs with food-induced atopic dermatitis. *Vet Dermatol* 2019;30:498.
24. Ravens PA, Xu BJ, Vogelnest LJ. Feline atopic dermatitis: a retrospective study of 45 cases (2001-2012). *Vet Dermatol* 2014;25:95-e28.

# FELINE ATOPIC DERMATITIS DEMYSTIFIED



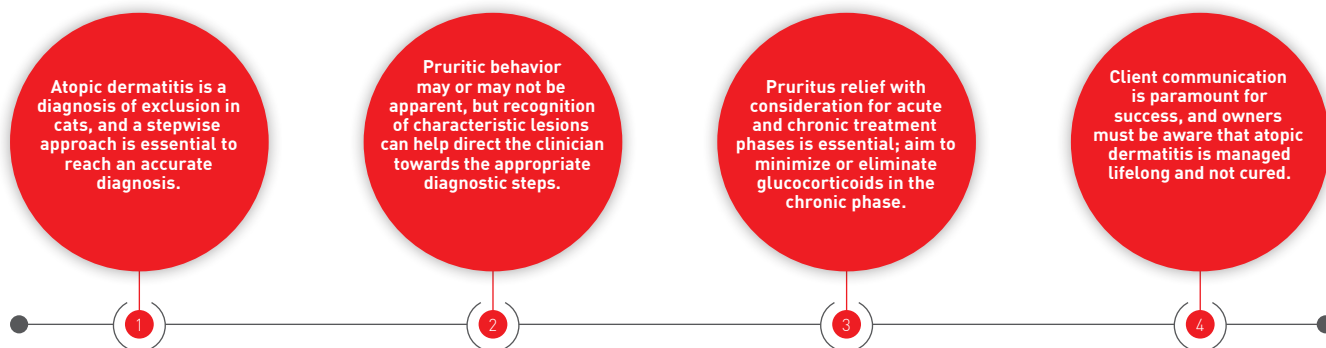
## Jennifer R. Schissler,

DVM, MS, Dip. ACVD, Colorado State University (CSU), Fort Collins, CO, USA

Dr. Schissler graduated from the CSU professional veterinary program in 2005 and went on to complete a combined master's degree and dermatology residency at The Ohio State University. A Diplomate of the American College of Veterinary Dermatology, she joined the CSU faculty in 2011 with a clinical, teaching and research appointment. Her interests include otology, infection control, multidrug resistant staphylococci, and Ehlers-Danlos syndrome.

The atopic cat can be frustrating to diagnose and treat, but in this paper Jennifer Schissler demystifies some of the issues surrounding the condition.

## KEY POINTS



## ●●○ Introduction

Feline atopic dermatitis is an inflammatory, almost invariably pruritic condition with characteristic clinical presentations. Compared to canine atopy, the clinical presentation can be quite different, and less is known about the etiopathogenesis, although – as with dogs – it is a hypersensitivity reaction to certain environmental allergens including pollen, house dust mite and mold. Unlike atopic dermatitis in people and dogs, it is unclear if IgE plays an essential role in the pathogenesis of the condition in the cat, therefore recent publications have advocated for and used the phrase “feline non-flea, non-food hypersensitivity dermatitis” (1). The nomenclature used to describe feline cutaneous allergy is evolving and is not universally accepted; commonly used historic terms include “feline atopy”, “feline atopic syndrome”, “feline atopic-like dermatitis”, and “feline atopic dermatitis”. For the sake of consistency, the latter term is used in this article, given its general historical familiarity to readers, and because this condition is the practical clinical counterpart of canine atopic dermatitis.

## ●●● Diagnosis

Atopic dermatitis is a diagnosis of exclusion. Cutaneous adverse food reactions and flea bite hypersensitivity present with identical clinical signs and may be comorbid with feline atopic dermatitis. Additionally, secondary *Staphylococcus* and *Malassezia* infections can increase dermatitis and pruritus severity. Consideration for and exclusion of infections and infestations, as well as an elimination diet trial in non-seasonal presentations, will prevent unnecessary chronic immunomodulation. A stepwise approach is therefore essential for an accurate and efficient diagnosis, and the following points should be considered in a patient with clinical signs and a history consistent with feline atopic dermatitis:

1. Assess for and treat any known or suspected infestations, and ensure compliance with flea control recommendations.
2. Assess for and treat infections, and assure cytologic resolution of infection.
3. Conduct an elimination diet trial if the patient has non-seasonal signs.

Feline atopic dermatitis will not respond completely to these measures. Although histopathology of feline cutaneous hypersensitivities does not discriminate between flea bite hypersensitivity, cutaneous adverse food reaction or atopic dermatitis, biopsies can support the diagnosis of hypersensitivity in ambiguous presentations. Consider referral of patients with equivocal or incompatible historical features, clinical findings, or lack of therapeutic response to a veterinary dermatologist.

Note that anti-pruritic medications during treatment trials will enhance patient quality of life and owner compliance, but strategic discontinuation of anti-pruritic medication is necessary to assess for response to diagnostic trials.

## ●●● Clinical signs and diagnosis

Feline atopy manifests a diverse array of characteristic lesions, body distributions, and differential diagnoses. These presentations may occur in isolation or in combination. Some cats present for aggressive hair pulling, scratching and excoriations, whilst pruritic behaviors in other cases may occur in secret, with the patient presenting for progressive, grossly non-inflammatory, symmetric alopecia.

There are four recognized feline cutaneous hypersensitivity clinical patterns: eosinophilic granuloma complex lesions, miliary dermatitis, head and neck excoriation, and symmetric alopecia.

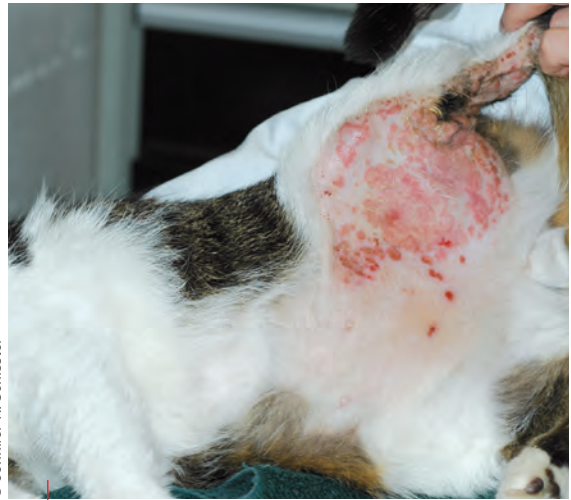### Eosinophilic granuloma complex

Lesions include indolent ulcer (rodent ulcer), eosinophilic plaque, and eosinophilic granuloma (linear or collagenolytic granulomas). Indolent ulcers present unilaterally or bilaterally on the upper lip as eroded plaques (**Figure 1**) and can progress, distorting the upper lip via overall surface ablation and dermal expansion. Eosinophilic plaques present as multiple or singular raised, well-circumscribed erythematous and moist erosions, and are commonly located on the abdomen (**Figure 2**). Eosinophilic granulomas are typically singular, erythematous, alopecic plaques or nodules often presenting on the inguinal region and hindlimbs, although they may also develop on the chin (**Figure 3**), tongue, palate (**Figure 4**), and (rarely) the footpads (**Figure 5**). Differential diagnoses for these lesions include neoplasia, lymphocytosis, herpesviral dermatitis, and deep fungal or bacterial infections. Eosinophilic granuloma complex lesions are often diagnosed via clinical appearance and supportive history; histopathology may confirm the diagnosis. Note that surface cytology of these lesions typically yields suppurative or pyogranulomatous inflammation with cocci; eosinophils are less numerous and not uniformly found. Treatment of lesions secondarily infected with *Staphylococci* with amoxicillin/clavulanate can result in significant clinical improvement, supporting the theory that bacteria play a role in the development, progression, and perpetuation of the lesions (2). In the author's experience, albeit helpful in many instances, antimicrobials are not always essential for the



© Jennifer R. Schissler

**Figure 1.** A cat with an indolent ulcer in partial remission; erosions remain on the upper left lip and tissue loss of the upper lip is permanent.



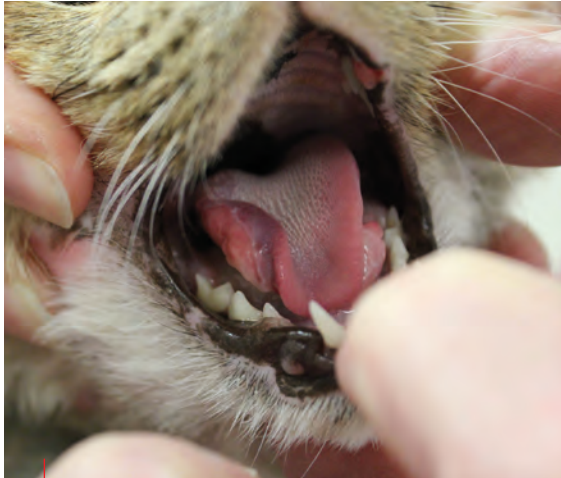© Jennifer R. Schissler

**Figure 2.** Multifocal moist, erythematous plaques on the inguinal area and inner thigh.



© Jennifer R. Schissler

**Figure 3.** An eosinophilic (collagenolytic) granuloma at the mucocutaneous junction of the lower lip.

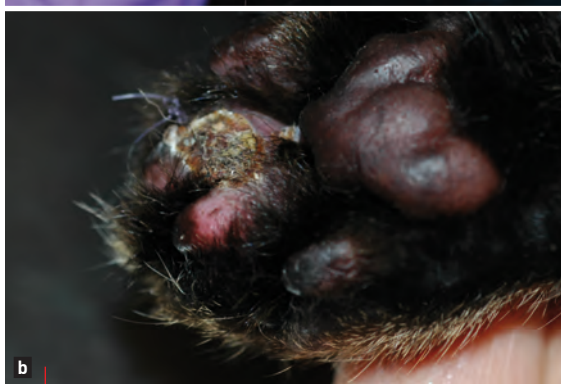
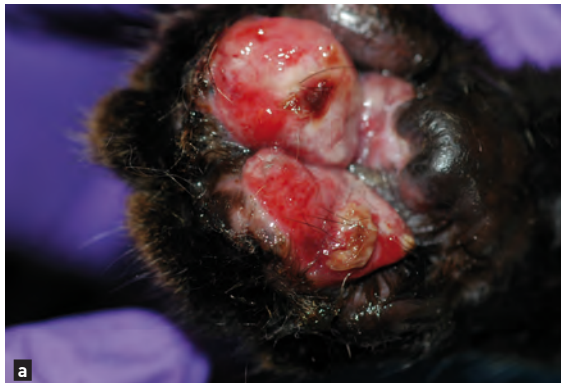
**Figure 4.** A granuloma on the lateral aspect of the tongue in a patient with concurrent pruritus and miliary dermatitis. Hypersalivation may develop secondary to the lingual lesion.

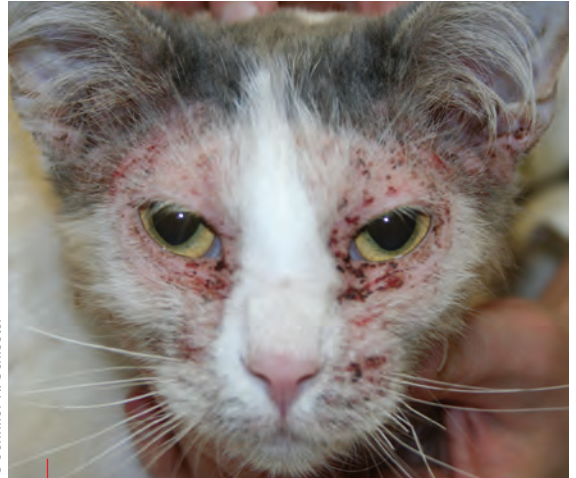resolution of eosinophilic granuloma complex lesions, and the decision to use such therapy is based upon cytologic evaluation (see below).

### Miliary dermatitis

This is a papular, crusting dermatitis, often distributed on the dorsum, and may present alongside alopecia (**Figure 6**). Differential diagnoses include dermatophytosis, *Cheyletiella*,



**Figure 5.** An eosinophilic granuloma on the footpad, confirmed via histopathology as neoplasia was a possible differential diagnosis (**a**). The lesion post-biopsy following two weeks of prednisolone therapy (**b**).

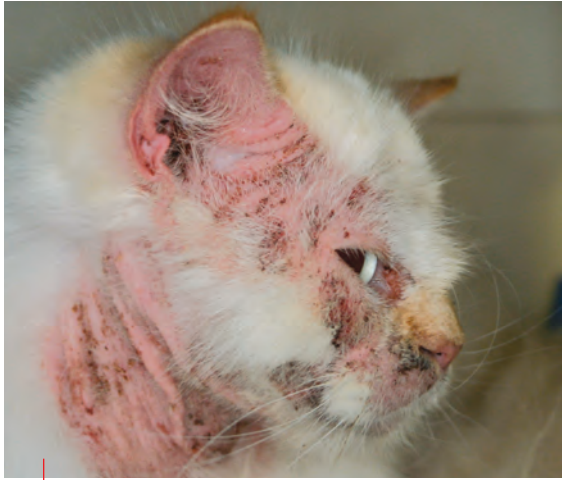

**Figure 6.** Facial miliary dermatitis with diffuse alopecia.

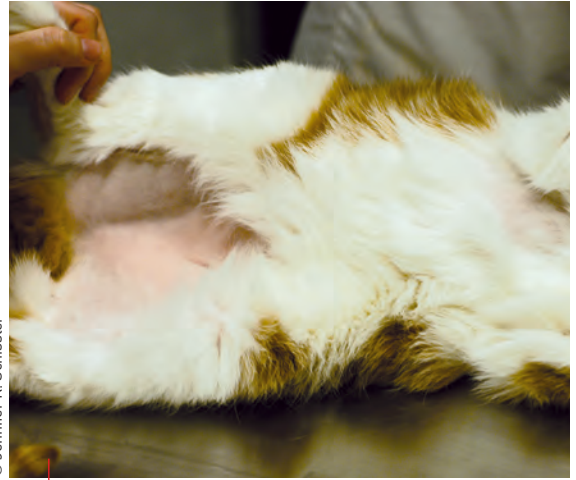
*Demodex cati*, *D. gatoi*, staphylococcal pyoderma, and pemphigus foliaceus. The diagnostic approach includes cytology from beneath crusts, deep and superficial skin scrapes, and assessment for dermatophytosis, which may include a trichogram, and if negative, PCR and/or culture. Nasal bridge and pinnal involvement may indicate mosquito bite hypersensitivity in outdoor cats. Miliary dermatitis resulting from cutaneous hypersensitivity alone can demonstrate mixed or suppurative inflammation on impression smears of avulsed crusts; eosinophils are variably present, and typically in lesser numbers. Many patients with cutaneous hypersensitivity have secondary staphylococcal pyoderma, which presents as miliary dermatitis. Follow up cytology and clinical examination of patients treated for staphylococcal pyoderma is recommended to discriminate between miliary dermatitis due to allergy, superficial staphylococcal pyoderma, or both in concert.

### Head and neck excoriation

This can range from mild to severe, focal to generalized erosions, ulcerations, and alopecia. Hemorrhagic or suppurative exudate and crusts are common, and may occur in conjunction with facial miliary dermatitis (**Figure 7**). Differential diagnoses include *Notoedres cati* (geographically variable), *Otodectes cynotis*, dermatophytosis, *Demodex* spp., and herpesviral dermatitis. These cases require superficial and deep skin scrapes, and cutaneous cytologic examination for secondary *Staphylococcus* and *Malassezia*. Given that otitis externa may be a manifestation of allergy in cats, scratching around the head and neck necessitates otoscopic assessment, ear cytology and mite preparation. A rare differential is idiopathic ulcerative dermatosis; this manifests as a large patch of excoriation, ulceration and fibrosis at the base of the neck. It is diagnosed via presentation and practical exclusion of hypersensitivity, including lack of response to ectoparasite control, antimicrobial therapy for secondary infection, elimination diet trial, and anti-pruritic therapies. When in question, biopsy can support the diagnosis of hypersensitivity.



**Figure 7.** A patient with neck and facial pruritus, erythema, excoriation and miliary dermatitis.



**Figure 8.** Bilaterally symmetric, well circumscribed, grossly non-inflammatory alopecia due to barbering in a pruritic atopic dermatitis patient.

## Symmetrical truncal and limb alopecia

With its given truncal distribution and gross lack of inflammation, this resembles endocrine alopecia (**Figure 8**). The hair loss is a result of pruritic behaviors (licking, biting, or pulling of the hair), and is far more common than feline endocrine alopecia. The alopecia ranges in severity from patchy and partial to complete and well-circumscribed, typically distributed over the lateral trunk, ventrum, and distal limbs. Frayed, broken hair tips are apparent upon microscopic examination. In the absence of any other lesions, the primary differential is *D. gatoi*, and if geographically appropriate, the cat fur mite *Lynxacarus radovskyi* (3), so perform superficial skin scrapes. *D. gatoi* is inconsistently found, even with appropriate sampling, but may be identified via fecal flotation due to ingestion during grooming (4). If *D. gatoi* is suspected despite negative scrapes and fecal tests, trial therapy is required. Weekly lime sulfur dips are effective (5), but when to undertake the trial [i.e., early in the diagnostic process, or reserved for patients with presumed atopic dermatitis failing anti-inflammatory therapy] will vary based on perceived geographic prevalence of the parasite, and a history consistent with risk for contagion (e.g., multicat household or shelter). There is mounting evidence for the efficacy of isoxazoline ectoparasiticides (sarolaner, fluralaner) for *D. gatoi* (6) and compelling evidence for this class of drug in treating *D. canis* and *D. injai*. Exclusion of both *D. gatoi* and flea bite hypersensitivity may therefore be performed more conveniently and efficiently with isoxazoline treatment.

Psychogenic alopecia is a differential for barbering cats, and is apparently less common than dermatitis (7). The diagnosis is reached via a lack of response to *D. gatoi* therapy, flea control, elimination diet trial and immunomodulatory therapy [particularly glucocorticoids (7)], in addition to historical evidence consistent with anxiety, and indications of suboptimal living conditions such as

lack of environmental enrichment (8). Negative biopsy results with regard to hypersensitivity and response to psychotropic medication and/or environmental modification are additionally supportive. Also uncommon (but worth noting), cats may barber in response to pain due to cystitis, inflammatory bowel disease, or peripheral neuropathy, so if the cause of barbering remains elusive reconsider another thorough physical exam, history, and further diagnostic assessment.



## Differential diagnosis

The history and signalment is helpful: patients typically demonstrate clinical signs prior to 4 years of age, and there is no sex predisposition and no well-documented breed predilection. Signs may be seasonal or non-seasonal, and may initially be mild and intermittent, becoming more severe and continuous over time. Both indoor and outdoor cats are affected, with no published assessment of indoor lifestyle as a risk or protective influence. A pruritus score should be obtained (and updated at every recheck), taking care to describe pruritic behaviors: licking, biting, chewing, rubbing, hair pulling and scratching, and identifying the location(s) of the pruritus. The following historical questions can be helpful;

1. At what age did the pruritus start?
2. Is the pruritus seasonal? Atopic dermatitis can be seasonal or non-seasonal.
3. Did the itch start suddenly, or has it become worse over time? In most instances there is increased severity over time.
4. Do other animals in the house have an itch or dermatitis? If so consider ectoparasites (e.g., fleas, *D. gatoi*) or *Microsporum canis*.
5. Has the itch responded to previous treatments? Response to therapy does not make a diagnosis, nor does it discriminate between flea bite hypersensitivity, cutaneous adverse food reaction, or atopic dermatitis, but many hypersensitive cats respond to systemic glucocorticoids.

6. What ectoparasitocides have been given and at what frequency?
7. What is the current diet, and has the cat been fed a different diet previously? This is helpful information for elimination diet trial selection.

Intradermal and serum allergy testing for atopic dermatitis or cutaneous adverse food reaction as a primary diagnostic tool for feline atopic dermatitis is not recommended, as both false positive and negative tests occur. The best use of these tests is when selecting allergens to be included in allergen-specific immunotherapy for atopic dermatitis patients. Note that canine allergen salivary tests, some of which are marketed directly to owners, have shown a shocking lack of accuracy, both with regard to condition (demonstrating positive results in healthy animals) and history (demonstrating positive results to food allergens that the pet has not consumed) [9].

## Atopic therapy

A foundation of maintenance anti-inflammatory medication and/or immunotherapy is optimal for chronic management. However, compliance is essential for optimal control of feline atopic dermatitis; educate owners about the chronic, incurable nature of the problem, discuss the benefits and side-effects of therapies, and (when appropriate) allow the client options in treatment selection. Cultivate a relationship with shared patient goals (e.g., is it possible for the cat to live comfortably without an Elizabethan collar?) and encourage communication; when a trusting relationship is forged, the owner will rely on the clinician's expertise and support when setbacks occur.

Anti-inflammatory treatments are the cornerstone of therapy, but consider the phase of therapy when managing patients with cutaneous hypersensitivity. Acute phase treatments rapidly reduce pruritus in patients at commencement of ectoparasiticide therapy and during elimination diet trials, and are also effective for flares of atopic dermatitis. Glucocorticoids and oclacitinib are the most effective acute phase anti-inflammatories. Once the diagnosis of atopic dermatitis is made, transition to chronic maintenance therapy, with the most evidence-based, safe and effective non-steroid long-term options being modified cyclosporine and allergen-specific immunotherapy. If glucocorticoids must be used long-term, aim to use the lowest dose and frequency required to control signs. Once chronic maintenance therapy is instituted, it is wise within the first year to consider rechecking the patient initially once per season to ensure optimal control and for assessment of secondary cutaneous or otic infections. For chronically well-managed cats, consider recheck every 6-12 months, ideally during the patient's more pruritic season.

Glucocorticoid therapy is ideally limited to the acute and diagnostic phases of therapy. The author prefers oral prednisolone therapy to better tailor and taper dosages, and mitigate side effects, when possible. A typical regime might be 1.0-2.0 mg/kg q24H for initial control of pruritus, and tapering to a dose of 0.5 mg/kg q48H as maintenance therapy.

However, doses of 2-3 mg/kg/day may be required for control of eosinophilic granuloma complex lesions. Given the risks (e.g., iatrogenic Cushing's, diabetes mellitus, and urinary tract infection), it is prudent to perform a biochemical profile and urinalysis at baseline, 3-4 months after commencement, and every 6 months thereafter or as otherwise indicated given general health status. Recrudescence of cutaneous or ocular herpesvirus may also occur.

Modified cyclosporine is approved in some countries for the treatment of feline atopic dermatitis, and is appropriate for chronic management. The most common side effect is gastrointestinal upset, in approximately 25% of cats, which may be transient or sustained. Given concern for life-threatening systemic toxoplasmosis, particularly in naïve patients, hunting and raw meat consumption is contraindicated. The author recommends a dose of 7.5 mg/kg/day for a trial period of 8 weeks, and once shown to be efficacious, the response may be maintained in some individuals with dosing every 48-72 hours. The drug may be administered in wet food without affecting the pharmacokinetic parameters, which can enhance compliance [10]. Although baseline and follow-up bloodwork and urinalysis are prudent, changes in these parameters are rare [11].

Oclacitinib is approved for the treatment of allergic dermatitis in dogs and although off-label, it has demonstrated efficacy [12,13] and safety [14] as both acute and chronic therapy in feline atopic dermatitis. However, reports only extend for up to 28 days, so information regarding long-term safety is entirely anecdotal. Pharmacokinetics in cats support higher and more frequent oral dosing compared to dogs [15], with studies indicating an initial dose range of 0.4-1.0 mg/kg q12H [12,13]; once well controlled, once-daily dosing may be attempted. However, the majority of patients are optimally managed on BID therapy long-term. The requirement for frequent tablet administration is a disadvantage for chronic dosing in cats. Given the general lack of safety data, consider baseline blood analysis and urinalysis, and continue monitoring every 3-6 months. In the author's experience, oclacitinib has demonstrated long-term safety and efficacy in cats, but if used, other immunomodulators should be avoided or approached with caution. The author has diagnosed multifocal *D. cati* and pyelonephritis in a cat receiving concurrent oral dexamethasone and oclacitinib for severe atopic dermatitis.

Allergen-specific immunotherapy administered subcutaneously or sublingually is appropriate for prolonged therapy; it is the only treatment that promotes immune tolerance and has no known long-term side effects. Allergens are selected via intradermal and/or serum IgE allergy testing and patient environmental history, but treatment can take up to 12 months for a notable response. To maintain comfort most patients will need ongoing or intermittent anti-inflammatory therapy over this period. Approximately 60% of cats will demonstrate a good medication-sparing or eliminating response [16], with most patients requiring ongoing treatment to maintain tolerance. Client education, including the

desire to reduce the requirement for drug therapy and the need for long-term treatment, is essential to prevent premature discontinuation and associated squandering of financial and time resources.

Antihistamines are inappropriate for acute management given their general lack of efficacy (17) and delayed onset of action. They may be effective as a steroid-sparing medication, or sole therapy in a very narrow population of patients.

Fatty acid therapy is appropriate for chronic management for all patients with atopic dermatitis, and can be sourced in prescription diets for atopic dermatitis, capsules and liquid preparations. By itself it does not significantly reduce pruritus, but may reduce severity of flares, improve skin barrier function with reduced allergen penetration and secondary infection, and has shown to have a drug-sparing effect in canine atopic dermatitis (18). The author recommends eicosapentanoic acid at a minimum dose of 90 mg per day to reduce pruritus in cats with atopic dermatitis.

Eosinophilic granuloma complex lesions are resolved with glucocorticoids and/or modified cyclosporine, but relatively higher initial doses and longer courses of glucocorticoid therapy may be required for remission. Modified cyclosporine alone may resolve lesions although it has a slow onset of approximately 4-6 weeks, but is reliably efficacious for long-term control of eosinophilic granuloma complex lesions. Diagnostic phase patients may continue glucocorticoid treatment to maintain relief during ectoparasiticide and elimination diet trials, but discontinue treatment at their conclusion to interpret trial efficacy. Peer-reviewed studies describing the use of oclacitinib to treat active eosinophilic granuloma complex lesions are

lacking, but chronic maintenance oclacitinib or allergen-specific immunotherapy may prevent lesion relapse.

Finally, otitis externa, as previously mentioned, may be in exclusion or may occur in concert with other reaction patterns. Systemic anti-inflammatory therapy and immunotherapy are not reliable means of control. Once secondary infection and inflammation are treated topically, and systemic therapy instituted for cutaneous signs, continue to recheck the ears, and consider maintenance topical steroids once or twice weekly. Ear flushing as maintenance therapy may be helpful, but a discussion of topical otic therapeutics is beyond the scope of this article.



## CONCLUSION

Deterioration of quality of life and the significant caregiver burden caused by feline atopic dermatitis must be recognized and addressed whenever possible. Compliant long-term maintenance prevents undue flares, reducing antibiotic and glucocorticoid exposure over time. However, even well-maintained patients can relapse from year to year or season to season, so consider developing a proactive patient-specific treatment and communication plan should a flare occur, and establish a long-term recheck schedule to ensure optimal control.



## REFERENCES

- Hobi S, Linek M, Marignac G, et al. Clinical characteristics and causes of pruritus in cats: a multicentre study on feline hypersensitivity-associated dermatoses. *Vet Dermatol* 2011;22:406-413.
- Wildermuth BE, Griffin CE, Rosenkrantz WS. Response of feline eosinophilic plaques and lip ulcers to amoxicillin trihydrate-clavulanate potassium therapy: a randomized, double-blind placebo-controlled prospective study. *Vet Dermatol* 2012;23(2):110-118, e24-25.
- Han HS, Chua HL, Nellinathan G. Self-induced, noninflammatory alopecia associated with infestation with *Lynxacarus radovskyi*: a series of 11 cats. *Vet Dermatol* 2019;30(4):356-e103.
- Silbermayr K, Joachim A, Litschauer B, et al. The first case of *Demodex gato* in Austria, detected with fecal flotation. *Parasitol Res* 2013;112(8):2805-2810.
- Saari SAM, Juuti KH, Palojärvi JH, et al. *Demodex gato*-associated contagious pruritic dermatosis in cats – a report from six households in Finland. *Acta Vet Scand* 2009;51(1):40.
- Duangkaew L, Hoffman H. Efficacy of oral fluralaner for the treatment of *Demodex gato* in two shelter cats. *Vet Dermatol* 2018;29(3):262.
- Waisglass SE, Landsberg GM, Yager JA, et al. Underlying medical conditions in cats with presumptive psychogenic alopecia. *J Am Vet Med Assoc* 2006;228(11):1705-1709.
- Titeux E, Gilbert C, Briand A, et al. From feline idiopathic ulcerative dermatitis to feline behavioral ulcerative dermatitis: grooming repetitive behaviors indicators of poor welfare in cats. *Front Vet Sci* 2018;16:5:81.
- Lam A, Johnson LN, Heinze CR. Assessment of the clinical accuracy of serum and saliva assays for identification of adverse food reaction in dogs without clinical signs of disease. *J Am Vet Med Assoc* 2019;255(7):812-816.
- Roberts ES, Speranza C, Friberg C, et al. Confirmatory field study for the evaluation of ciclosporin at a target dose of 7.0 mg/kg [3.2 mg/lb] in the control of feline hypersensitivity dermatitis. *J Feline Med Surg* 2016;18(11):889-897.
- Roberts ES, Vanlare KA, Strehlau G, et al. Safety, tolerability, and pharmacokinetics of 6-month daily dosing of an oral formulation of cyclosporine (ATOPICA for cats®) in cats. *J Vet Pharmacol Ther* 2014;37(2):161-168.
- Noli C, Matricoti I, Schievano C. A double-blinded, randomized, methylprednisolone-controlled study on the efficacy of oclacitinib in the management of pruritus in cats with non-flea non-food-induced hypersensitivity dermatitis. *Vet Dermatol* 2019;30(2):110-e30.
- Ortalda C, Noli C, Colombo S, et al. Oclacitinib in feline non-flea-, nonfood-induced hypersensitivity dermatitis: results of a small prospective pilot study of client-owned cats. *Vet Dermatol* 2015;26(4):235-e52.
- Lopes NL, Campos DR, Marilia AM, et al. A blinded, randomized, placebo-controlled trial of the safety of oclacitinib in cats. *BMC Vet Res* 2019;15(1):137.
- Ferrer L, Carrasco I, Cristófol C, et al. A pharmacokinetic study of oclacitinib maleate in six cats. *Vet Dermatol* 2020;31(2):134-137.
- Ravens PA, Xu BJ, Vogelneust LJ, et al. Feline atopic dermatitis: a retrospective study of 45 cases (2001-2012). *Vet Dermatol* 2014;25(2):95-102, e27-28.
- Wildermuth K, Zabel S, Rosychuk RAW. The efficacy of cetirizine hydrochloride on the pruritus of cats with atopic dermatitis: a randomized, double-blind, placebo-controlled, crossover study. *Vet Dermatol* 2013;24(6):576-81, e137-138.
- Muller MR, Linek M, Lowenstein C, et al. Evaluation of cyclosporine-sparing effects of polyunsaturated fatty acids in the treatment of canine atopic dermatitis. *Vet J* 2016;210:77-81.



# THERAPEUTIC OPTIONS FOR THE PRURITIC CAT

The clinician presented with an itchy cat has fewer options than when dealing with a pruritic dog – or is that true? Jay Korbelik offers some ideas backed by clinical studies.

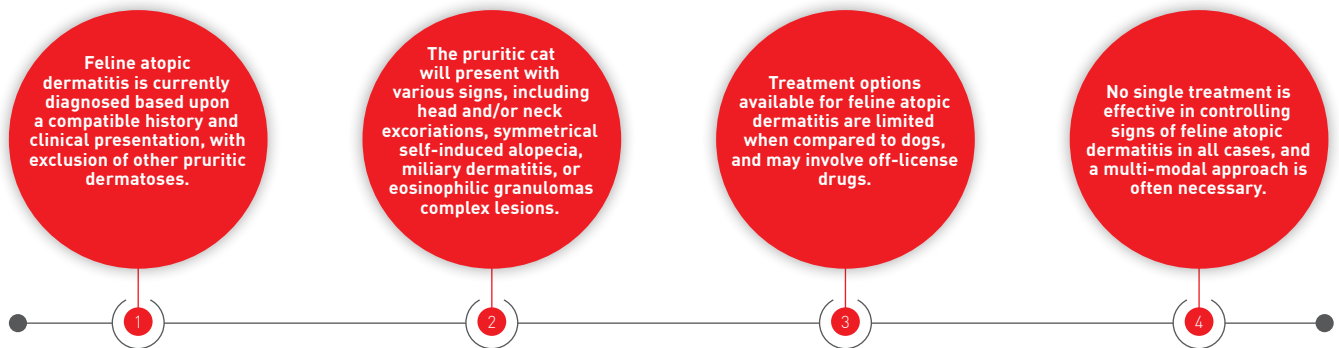


## Jay Korbelik,

BVSc, MSc, Dip. ACVD, North West Veterinary Dermatology Services, Vancouver, Canada

Originally from Canada, Dr. Korbelik graduated with honors from the University of Queensland in 2008 and then returned home to complete a Small Animal Rotating Internship at Saskatoon's Western College of Veterinary Medicine. In 2015 he decided to pursue his passion for dermatology and completed a Residency at Yu of Guelph Veterinary Dermatology, concurrently achieving a Master of Science in Pathobiology at the University of Guelph. He now resides in Vancouver, where he practices at a private dermatology clinic.

## KEY POINTS

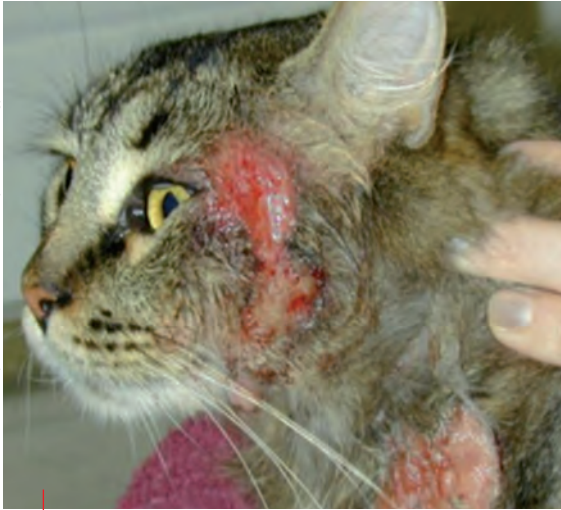

## Introduction

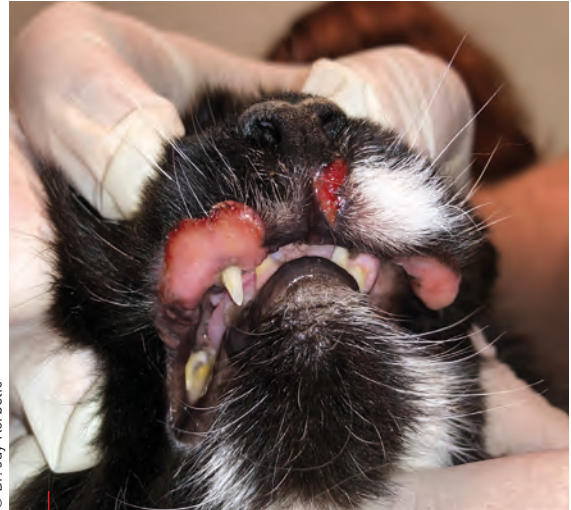Pruritic disorders in cats are often attributed to hypersensitivity dermatides (HD) including flea bite hypersensitivity (FBH), food-induced hypersensitivity dermatitis (FIHD) and atopic dermatitis (AD) (1). Use of the term feline AD remains debatable because the clinical presentation, histologic features and role of IgE differ significantly to that of human and canine atopy (1,2). The significance of IgE in the pathogenesis of this condition has not been firmly established, and there are currently very few studies that have investigated the role of IgE in feline AD (3). The term non-flea, non-food induced hypersensitivity dermatitis (NFNFIHD) is sometimes used to refer to this condition. Feline AD is suggested to be the second most common HD in cats (4); one study reported a prevalence of 12.5% of all feline dermatoses (2), and

also found that Abyssinian, Devon Rex and domestic breed cats were over-represented. Clinical signs typically start manifesting in young cats (under 3 years of age) (5) although one study did find that 22% of cats with feline AD were over 7 years of age (2). This study also found that 93% of cats with feline AD were perceived as being pruritic by their owners, and importantly, trichogram analysis in the remaining 7% confirmed broken hairs consistent with pruritic behavior. The majority of cats (80%) in this study had non-seasonal signs.

Cats with HD will present with one or more of the following patterns: head and/or neck excoriations (**Figure 1**), symmetrical self-induced alopecia, miliary dermatitis, or eosinophilic granulomas complex lesions (**Figures 2 and 3**) (1,2). Other



**Figure 1.** Head and neck excoriations in a cat with AD.



**Figure 2.** A cat with indolent ulcers on the upper lips, a common presentation of lesions associated with the eosinophilic granuloma complex.

presentations, including pododermatitis, facial erythema, seborrheic disorders or ceruminous otitis have also been reported (3,5). It is impossible to distinguish between the different causes of HD based on clinical presentation; although one study found that cats with FIHD were more likely to present with lesions on the head and neck, and cats with FBH were more likely to present with lesions on the dorsal aspect of the body (rump and tail) (1), this finding was not considered statistically significant. **Figure 4** shows the most commonly affected sites of HD with the different causes.

Feline AD is currently diagnosed based upon a compatible history and clinical presentation, along with exclusion of other pruritic dermatoses (5). It is especially important for the clinician to rule out FBH with appropriate ectoparasite treatment and, for cats exhibiting non-seasonal signs, a restricted diet trial (for typically 8 weeks) to rule out FIHD (5). Diagnosing and treating feline AD can be challenging and frustrating for even the most seasoned clinician for several reasons:

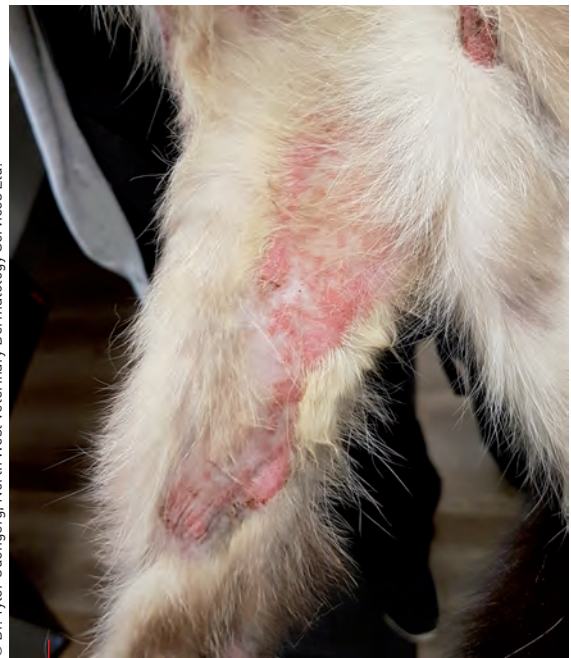- There are currently no widely established clinical diagnostic criteria for feline AD as there are in dogs (6).
- Treatment options available for feline AD are limited.
- It can be notoriously difficult to administer oral medication to cats (5).

This article will discuss some of the pharmaceutical treatment options used to control pruritus caused by AD in feline patients.




## Corticosteroids

Corticosteroids have long been the mainstay of treatment for feline AD, and are frequently used as cats appear to be generally more resistant to the adverse effects of this class of drugs than dogs (5). Although feline AD has been reported as typically corticosteroid responsive (5), one study found that a



**Figure 3.** Eosinophilic plaques in a cat, another common presentation of lesions associated with the eosinophilic granuloma complex.

good response to systemic corticosteroids was only reported in 55% of cats, although the type, dosage and duration of therapy were not evaluated (2). No studies have examined the most effective way to taper corticosteroids, but an induction dosage is generally employed for the first week and then tapered at 1–2 week intervals, with the aim of attaining the lowest every other day dosage that maintains remission and minimizes side effects (7). In cats, prednisolone is recommended over prednisone due to significantly higher bioavailability (100% vs. 21% respectively) (8). One study showed that methylprednisolone (1.41 mg/kg



**Figure 4.** Silhouettes depicting the proportion of distribution of lesions in cats with hypersensitivity dermatides. Reprinted from [1].

q24H) or triamcinolone (0.18 mg/kg q24H) were effective at inducing remission of pruritus in 90.6% of allergic cats within 7-14 days, while prednisolone (1 mg/kg q24H) only achieved remission in 45.5% of cats after 28 days [7]. This study also indicated that 0.54 mg/kg q48H of methylprednisolone or 0.08 mg/kg q48H of triamcinolone were effective at maintaining remission in these cats.

Adverse effects of corticosteroid treatment can include marked cutaneous atrophy, congestive heart failure, iatrogenic hyperadrenocorticism and increased risk of diabetes mellitus, among others [9]. A preliminary study suggested that dexamethasone exhibited a greater diabetogenic effects in cats than the equivalent dose of prednisolone [10].

For patients that require long-term maintenance therapy, injectable glucocorticoids (e.g., methylprednisolone acetate) are usually not recommended, as oral administration is more precise and is associated with a lower risk for side effects [9]. Additionally, a poorly understood but well recognized phenomenon called steroid tachyphylaxis (i.e., resistance) can occur when the drug is administered long-term, and in these cases changing the type of corticosteroid administered can often result in better clinical response [9]. Topical corticosteroids, including mometasone

furoate and hydrocortisone aceponate, are reported to provide good control of pruritus in some cats, or can be used to reduce the need for systemic corticosteroids [2,9].

## ●●● Cyclosporine

Cyclosporine is a calcineurin inhibitor with immunosuppressive activity that focuses on cell mediated immune responses [9]. Several studies have found good efficacy and safety of cyclosporine to treat feline HD when used at 7 mg/kg q24H PO after 4-6 weeks [2,11-13]. One study found that 70% of cats receiving cyclosporine could be reduced to every other day dosing after 4 weeks of treatment, and over the following four weeks 57% of cats could then be reduced to twice weekly dosing [13]. A single study has evaluated the administration of cyclosporine 50 mg/mL subcutaneously; this formulation, given initially at 2.5-5 mg/kg once daily to alternate days, appears to be an efficacious therapy for feline AD and may be an alternative option for cats that cannot be treated orally [14].

Monitoring serum levels of cyclosporine in HD is typically not recommended, as the levels generally do not correlate with clinical response [9]. The most commonly observed adverse effects are digestive tract disorders, including vomiting, diarrhea,



**“No single treatment is effective in controlling signs of feline atopic dermatitis in all cases, and a multimodal approach is often necessary. Because it is an incurable condition requiring life-long management, the clinician must always weigh the potential side effects of treatment with the benefits.”**

Jay Korbelik

hypersalivation and anorexia [9,11,12], and the resulting weight loss may lead to hepatic lipidosis [9]. Most of these adverse effects were mild in nature and did not require withdrawal from the studies [11,12]. Giving the drug with a small amount of food or freezing the capsules before administration have been suggested to minimize gastrointestinal side effects [15]. Some clinicians recommend giving the liquid preparation of this medication cold to alleviate this adverse effect, although the author is not aware of any studies that have confirmed preparation stability at this temperature.

Rarely, development of severe systemic illness due to *Toxoplasma gondii* has been reported [2,9]. Titer testing for *T. gondii* should therefore be considered prior to starting therapy [2], and cats should not be fed a raw food diet or be allowed to hunt while receiving cyclosporine [2]. All cats should also be tested for Feline Immunodeficiency Virus (FIV) and Feline Leukemia Virus (FeLV) prior to treatment [9]. Many clinicians recommend pre-cyclosporine testing to include complete blood count, biochemistry and urinalysis, and will monitor ongoing treatment every 6-12 months thereafter [9].

## Antihistamines

Few studies have evaluated the use of antihistamines to treat pruritus due to feline AD, and dosing recommendations and efficacy vary greatly. Antihistamines generally tend to be well tolerated but have low efficacy [2,16,17]. The efficacy of cetirizine has been most widely evaluated, with one study reporting a reduction in

pruritus in 41% of cats [16], but another study reported a good response in only 6% of cats and a partial response in 34% of cats [2]. However, no statistical difference in reduction of pruritus between cats treated with cetirizine and those treated with a placebo has been reported [17]. A retrospective review noted a good response to loratadine treatment in only 5% of cats and a partial response in 42% of cases, although the number of cats in this study was low [2]. The efficacy of cyproheptadine hydrochloride was evaluated in one study; pruritus was satisfactorily controlled in only 45% of cats [18], and side effects (including polyphagia, sedation, vocalization, affectionate behavior, and vomiting) were noted in 40% of animals.

## Oclacitinib

Oclacitinib is a Janus kinase inhibitor that has primarily been used in the treatment of pruritus in dogs. It can be used off-label in cats, although limited studies have evaluated its efficacy and safety. A pharmacokinetic study of oclacitinib found that larger doses and shorter dosing intervals would be recommended in cats to achieve similar blood concentrations to those in dogs [19]. One study reported that oclacitinib was effective at reducing pruritus in 51% of cats and improved clinical lesions of feline AD in 61% of cats when dosed at 1 mg/kg q12H [20]. The efficacy of the drug was comparable to methylprednisolone efficacy in this study, with the latter performing slightly better.

Oclacitinib appears to be well tolerated in cats, although one study found that 4 out of 14 cats had a mild increase in kidney function tests after 4 weeks of use [20]. A second study evaluating the safety of this drug in cats noted gastrointestinal side effects in a small proportion of cases when given at 2 mg/kg q12H [21]. It also noted a small but significant increase in fructosamine levels when cats were treated with oclacitinib, although values remained within the normal reference range. Further investigation is required to evaluate long-term safety of this treatment in cats.

## Maropitant

Maropitant is a neurokinin-1 receptor antagonist indicated for the prevention of vomiting and nausea in cats. Its anti-pruritic and anti-inflammatory effect is thought to rely on its ability to inhibit substance P by binding to its receptor [22]. In one study, cats were treated with maropitant at 2.22 mg/kg q24H for 4 weeks, resulting in a decrease in both clinical lesions and pruritus scores associated with AD in all animals except one [22]. The efficacy and the tolerability of the treatment were judged as excellent or good in 83.3% of cats, with the only side effect being self-limiting sialorrhea in a small number of cases.



## Palmitoylethanolamide (PEA)

PEA is a naturally occurring lipid compound with antiallergic and anti-inflammatory effects (23,24). PEA binds to peripheral cannabinoid receptors and down-regulates mast cell degranulation (23). A pilot study on cats with eosinophilic granulomas and plaques showed that 30 days of treatment with co-micronized PEA reduced the severity of clinical lesions and pruritus in more than 60% of cases (23). A second study, in which cats were co- and post-administered ultramicronized PEA (PEA-um) at 15 mg/kg q24H PO, showed that the compound enhanced the anti-pruritic effect of a short course of methylprednisolone treatment, and could delay flares in cats with HD (24). It reported that the cats could be maintained relapse- and corticosteroid-free for a mean period of six weeks with no serious side effects, although mild gastrointestinal upset was noted.



## CONCLUSION

No single treatment is effective in controlling signs of feline atopic dermatitis (AD) in all cases and a multi-modal approach is often necessary. As this article focuses on pharmaceutical treatment options of feline AD, allergen-specific immunotherapy is not discussed, but this option certainly plays a role in management of this condition. As feline AD is an incurable condition that requires life-long management, the clinician must always weigh the potential side effects of treatment with the benefit. Further study is needed to develop a diagnostic criteria for feline AD, along with investigation into its pathogenesis and potential treatment options.



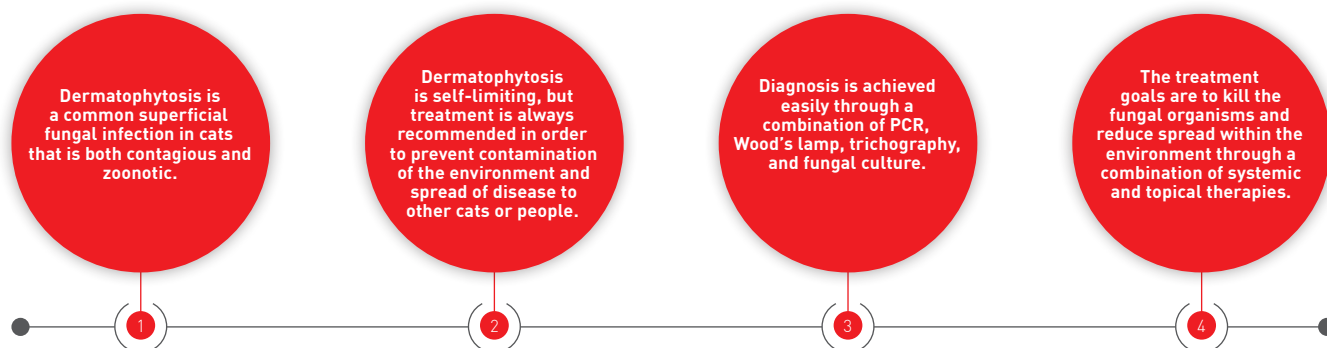
## REFERENCES

- Hobi S, Linek M, Marignac G, *et al.* Clinical characteristics and causes of pruritus in cats: a multicentre study on feline hypersensitivity associated dermatoses. *Vet Dermatol* 2011;22:4006-4013.
- Ravens PA, Xu BJ, Vogelnest LJ. Feline atopic dermatitis: a retrospective study of 45 cases (2001–2012). *Vet Dermatol* 2014;25:95-e28.
- Foster AP, Roosje PJ. Update on feline immunoglobulin E (IgE) and diagnostic recommendations for atopy. In: August JR (ed.) *Consultations in Feline Internal Medicine*, 4<sup>th</sup> ed. Philadelphia: WB Saunders 2004;229-238.
- O'Dair HA, Markwell PJ, Maskell I. An open prospective investigation into aetiology in a group of cats with suspected allergic skin disease. *Vet Dermatol* 1996;7:193-201.
- Marsella R. Hypersensitivity disorders. In: Miller WH, Griffin CE, Campbell KL, eds. *Muller and Kirk's Small Animal Dermatology*. 7<sup>th</sup> ed. St Louis, MO: Elsevier. 2013;363-431.
- DeBoer DJ, Hillier A. The ACVD task force on canine atopic dermatitis (XV): fundamental concepts in clinical diagnosis. *Vet Immunol Immunopathol* 2001;81:271-276.
- Ganz EC, Griffin CE, Keys DA, *et al.* Evaluation of methylprednisolone and triamcinolone for the induction and maintenance treatment of pruritus in allergic cats: a double-blinded, randomized, prospective study. *Vet Dermatol* 2012;23:387-e72.
- Graham-Mize CA, Rosser EJ. Bioavailability and activity of prednisone and prednisolone in the feline patient. *Vet Dermatol* 2004;15(s1):7-10.
- Scott DW, Miller WH, Griffin CE. Dermatologic therapy. In: Miller WH, Griffin CE, Campbell KL (eds). *Muller and Kirk's Small Animal Dermatology*. 7<sup>th</sup> ed. St Louis, MO: Elsevier. 2013;108-183.
- Lowe AD, Graves TK, Campbell KL, *et al.* A pilot study comparing the diabetogenic effects of dexamethasone and prednisolone in cats. *J Am Anim Hosp Assoc* 2009;45(5):215-224.
- King S, Favrot C, Messinger L, *et al.* A randomized double-blinded placebo-controlled study to evaluate an effective ciclosporin dose for the treatment of feline hypersensitivity dermatitis. *Vet Dermatol* 2012;23(5):440-e84.
- Roberts ES, Speranza C, Friberg C, *et al.* Confirmatory field study for the evaluation of ciclosporin at a target dose of 7.0 mg/kg (3.2 mg/lb) in the control of feline hypersensitivity dermatitis. *J Feline Med Surg* 2016;18(11):889-897.
- Steffan J, Roberts E, Cannon A, *et al.* Dose tapering for ciclosporin in cats with non-flea-induced hypersensitivity dermatitis. *Vet Dermatol* 2013;24(3):315-e70.
- Koch SN, Torres SMF, Diaz S, *et al.* Subcutaneous administration of ciclosporin in 11 allergic cats – a pilot open-label uncontrolled clinical trial. *Vet Dermatol* 2018;29(2):107-e43
- Bachtel JC, Pendergraft JS, Rosychuk RA, *et al.* Comparison of the stability and pharmacokinetic in dogs on modified ciclosporin capsules stored at -20 degrees C and room temperature. *Vet Dermatol* 2015;26(4):228-e250.
- Griffin JS, Scott DW, Miller WH Jr, *et al.* An open clinical trial on the efficacy of cetirizine hydrochloride in the management of allergic pruritus in cats. *Can Vet J* 2012;53(1):47-50.
- Wildermuth K, Zabel S, Rosychuk RA. The efficacy of cetirizine hydrochloride on the pruritus of cats with atopic dermatitis: a randomized, double-blind, placebo-controlled, crossover study. *Vet Dermatol* 2013;24(6):576-581, e137-138.
- Scott DW, Rothstein E, Beningo KE, *et al.* Observations on the use of cyproheptadine hydrochloride as an antipruritic agent in allergic cats. *Can Vet J* 1998;39(10):634-637.
- Ferrer L, Carrasco I, Cristófol C, *et al.* Pharmacokinetic study of oclacitinib maleate in six cats. *Vet Dermatol* 2020;31(2):134-137.
- Noli C, Matricoti I, Schievano C. A double-blinded, randomized, methylprednisolone-controlled study on the efficacy of oclacitinib in the management of pruritus in cats with non-flea nonfood-induced hypersensitivity dermatitis. *Vet Dermatol* 2019;30(2):110-e30.
- Lopes NL, Campos DR, Machado MA, *et al.* A blinded, randomized, placebo-controlled trial of the safety of oclacitinib in cats. *BMC Vet Res* 2019;15(1):137.
- Maina E, Fontaine J. Use of maropitant for the control of pruritus in non-flea, non-food-induced feline hypersensitivity dermatitis: an open-label, uncontrolled pilot study. *J Feline Med Surg* 2019;21(10):967-972.
- Scarampella F, Abramo F, Noli C. Clinical and histological evaluation of an analogue of palmitoylethanolamide, PLR 120 [co-micronized Palmidrol INN] in cats with eosinophilic granuloma and eosinophilic plaque: a pilot study. *Vet Dermatol* 2001;12(1):29-39.
- Noli C, Della Valle MF, Miolo A, *et al.* Effect of dietary supplementation with ultramicronized palmitoylethanolamide in maintaining remission in cats with non-flea hypersensitivity dermatitis: a double-blind, multicentre, randomized, placebo-controlled study. *Vet Dermatol* 2019;30(5):387-e117.

# FELINE DERMATOPHYTOSIS

Dermatophytosis (often known as “ringworm”) is a common dermatological fungal infection in cats that should be diagnosed and treated as early as possible, as Amelia White explains.

## KEY POINTS



## Introduction



Fungal dermatoses frequently occur in veterinary medicine, and dermatophytosis represents one of the most common causes of infectious superficial folliculitis in cats. Dermatophytes are keratin-loving organisms that invade skin and hair shafts, leading to clinical signs of folliculitis. The most common dermatophyte species affecting cats is *Microsporum canis*, and the cat serves as its environmental reservoir.

Dermatophytosis is both contagious and zoonotic, therefore rapid diagnosis and treatment will prevent propagation within the environment and spread of disease, which is especially important in multi-cat households, catteries, and shelter environments. The traditional means of diagnosis (including Wood's lamp, trichography, and dermatophyte culture) remain widely accepted, and PCR is a useful tool to shorten time to treatment and clinical resolution. Although the disease is self-limiting, treatment is recommended to prevent spread of infection.

## Prevalence and predispositions



While dermatophytosis is recognized as a common fungal dermatosis in cats, the true prevalence is unknown (1). Disease occurs worldwide, and research trends suggest that animals living in warm environments, group housing, free-roaming cats, young cats, immunodeficient animals, and cats with clinical lesions more commonly culture positive for dermatophyte (1-3). There are no

known predispositions, although evidence suggests that Persian cats are over-represented, especially for the subcutaneous form of dermatophytosis (mycetoma or pseudomycetoma) (1,4).

## Pathogenesis



Most fungi are opportunistic pathogens that invade the body if there is failure of the host's innate immune defense system. This can be defined as the non-specific, naturally present component of the immune system which is not dependent on prior antigen sensitization – e.g., the physical skin barrier, temperature, pH, and antimicrobial peptides. The innate immune system includes cells (e.g., natural killer cells, macrophages, and neutrophils) which recognize conserved regions on pathogens (known as pathogen-associated molecular patterns, or PAMPs) and mount an immune attack.

Dermatophytes invade the superficial layers of skin, the hair shaft/follicle, and the claws, quickly infecting the host while bypassing the innate immune defenses by producing fungal proteases (e.g., fungalysins, lipases, ceramidase, adhesins) that promote penetration into the keratinous tissue (5-7). Arthrospores released from the skin, hair, and claws of infected cats into the environment form the infectious stage of the lifecycle. These infective arthrospores develop when fungal hyphae fragment, and directly or indirectly (via clippers, brushes, bedding, etc.) make contact with a new host and create infection within hours of exposure. Once in contact with the skin, arthrospores create germ tubes to penetrate the stratum corneum and hair (5).



## Amelia G. White,

DVM, MS, Dip. ACVD, Auburn University College of Veterinary Medicine, Alabama, USA

Dr. White graduated from the University of Georgia in 2010 and served as a small animal intern in the College of Veterinary Medicine at Auburn University between 2010-2011. She completed a three-year dermatology residency at the University of Illinois in Champaign-Urbana before returning to Auburn in 2014 where she serves as Associate Clinical Professor of Dermatology. She received the Dean's Award for Excellence in Teaching in 2020 and has authored or co-authored various dermatology papers.

Fungal invasion is more likely to occur in animals with microtrauma to the skin (e.g., scratches from allergies, clipper blade trauma), ectoparasites, and increased humidity (7). Clinical signs of infection develop 2-4 weeks after exposure, but infected cats shed infectious spores before signs appear (8). Infected hairs and spores remain viable in the environment for 12-18 months, but rarely serve as a source of reinfection (1).

The host immune response to the presence of dermatophytic hyphae and arthrospores, mediated by neutrophils, macrophages and cytokine release, eventually leads to spontaneous resolution of infection over a course of weeks to months; however, infection may persist in cats with a compromised immune system. This could happen for numerous reasons, such as physical trauma to the skin barrier, surgery, poor husbandry, underlying disease (e.g., allergic dermatitis, endocrinopathy, neoplasia), and immune-compromising medications (e.g., steroids, chemotherapeutics).



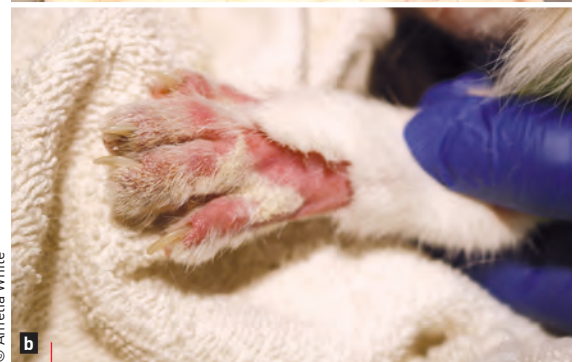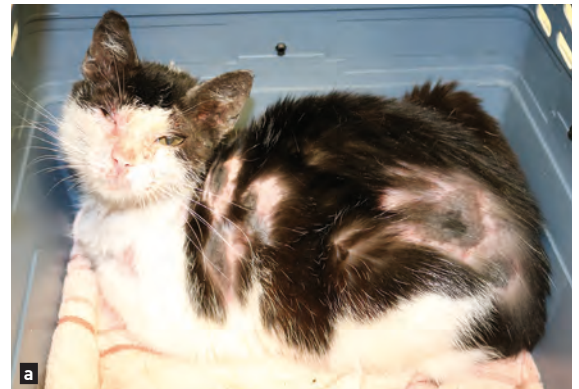### Clinical appearance

Dermatophytes need keratin to survive, so lesions occur in areas of the skin with the most keratin: epidermis, hair follicles and claws. Folliculitis is the hallmark of infection, and clinical lesions include papules, pustules, alopecia, broken hairs, scales, crusts, follicular casts (keratin plugs), and skin hyperpigmentation (Figures 1-3). Infected claws will become misshapen and are prone to fracture and break. Most affected cats are not pruritic. Cats with subcutaneous forms of the disease may present with nodules in the deep dermis and subcutis that develop fistulae and ulcers with purulent exudate. As is typical of most infectious dermatoses, clinical lesions are asymmetrically distributed over the body; they may be single or multifocal in nature, and the severity of clinical presentation is usually dependent upon the cat's immune response to infection.



### Differential diagnoses

The prime differential in cats is superficial folliculitis, which occurs secondary to *Staphylococcus* spp. and *Demodex* spp. infections, as well as allergic dermatitis and eosinophilic granuloma complex. Less common considerations would include psychogenic alopecia, anagen/telogen defluxion, pemphigus foliaceus, pseudopelade, thymoma-associated exfoliative dermatitis, and cutaneous lymphoma.



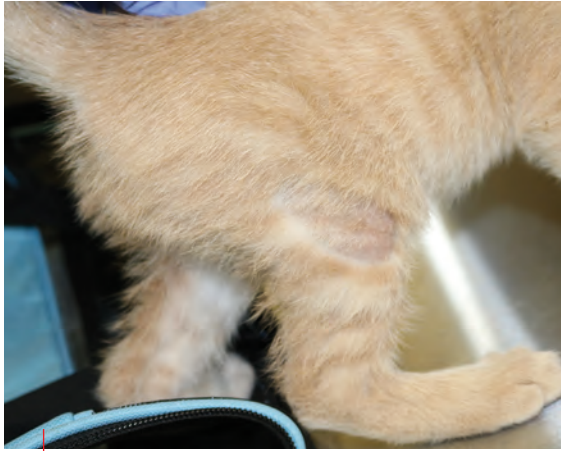© Amelia White

**Figure 1.** Multifocal areas of alopecia, erythema, hyperpigmentation, scaling and crusting on an adult female spayed domestic shorthaired cat with *M. canis* infection (a,b).



© Amelia White

**Figure 2.** Multifocal areas of alopecia and crusting on the dorsal nasal bridge and rostral muzzle of a kitten with *M. canis* infection.



**Figure 3.** A well-demarcated, focal area of alopecia and minor scaling on the right lateral stifle on the same kitten.

Nodular forms of the disease may appear similar to other opportunistic bacterial (e.g., *Mycobacteria* spp., *Nocardia* spp.) or fungal (e.g., phaeohiphomycosis, hyalohiphomycosis, zygomycosis) infections, neoplasia, or sterile nodular panniculitis.

## Diagnosis

Many cats go undiagnosed for days to weeks after developing infection due to camouflaging of lesions within the hair coat, or misdiagnosis as another similar-appearing dermatosis such as pyoderma (bacterial dermatitis) or allergic dermatitis. Any delay in diagnosis leads to increased contamination of the environment and risk of spread within the population of cats, dogs and people. Rapid diagnosis is critical to eliminate infection as quickly as possible. Dermatophytosis is commonly over-diagnosed based on clinical lesions alone, so additional testing is required. Many diagnostic techniques are available but they vary in reliability; however, it is usually possible to accurately diagnosis infection through a combination of tests.



**“When dealing with dermatophytosis, the most important part of diagnosis is confirming the presence of infection at the onset of clinical signs, and the absence of infection at the end of treatment.”**

Amelia G. White

The most important part of diagnosis is confirming the *presence* of infection at the onset of clinical signs, and the *absence* of infection at the end of treatment (1). Accurate diagnosis of dermatophytosis will be important when making decisions about which cats to treat, isolate, and re-test. Confirming the absence of infection ensures that animals can be reintroduced into the population without risk of spreading infection. Choosing the best tests to answer these questions is important to reliably diagnose and treat dermatophytosis.

## History

Clients may be able to provide information confirming multiple in-contact animals or people with suspicious skin lesions. While this information certainly increases the suspicion of dermatophytosis, it is not enough in itself to diagnose the condition.

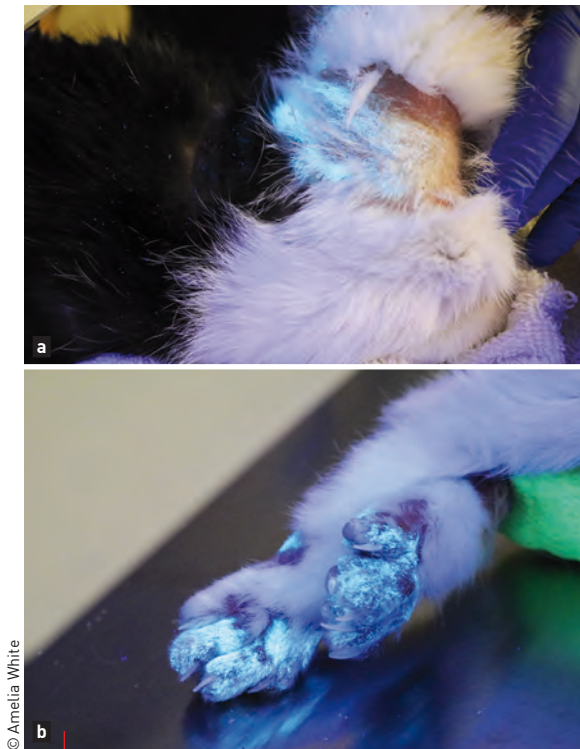
## Wood's lamp

Most *M. canis* isolates fluoresce bright green when ultraviolet light highlights a chemical reaction occurring between the dermatophyte and the water-soluble chemical metabolite, pteridine, located in the hair (1,9) (**Figure 4**). Data suggest that 91-100% of spontaneously infected cats fluoresce prior to initiation of antifungal treatment, but this may decrease to 39-53% after treatment (1). When examining the cat, be sure the hair shaft is glowing by looking through the magnification lens at a distance of 2-4 cm from the skin. Keep in mind that other things can fluoresce to create a false positive result, including medications, bacteria, scale/crust, soaps, petroleum, and fabric fibers, but these will lack the classic green coloring. Lack of fluorescence does not rule out dermatophytosis, so this method alone is insufficient to make the diagnosis; it is important to perform fungal PCR or culture to confirm the dermatophyte species causing infection. Note that Wood's lamp examination can be very helpful for several reasons, from making a diagnosis to selecting the best hairs to sample for culture.

## Dermatophyte test medium (DTM)

DTMs are specialized fungal agars for growing dermatophytes; they contain antibacterial and antifungal agents to inhibit contamination, along with phenol red, a pH indicator that causes a red discoloration when dermatophytes grow and release alkaline metabolites. DTMs should be examined daily for concurrent colony growth and color change. One study demonstrated that DTMs are as reliable as diagnostic laboratory fungal culture results when (i) manufacturer storage and incubation instructions are followed, and (ii) colony growth is evaluated microscopically to identify morphology of fungal reproductive structures [macroconidia and microconidia] (10). False positive color change is possible, so cytological evaluation of all growing colonies to identify the fungal species present is important. Cultures are negative if no growth occurs within 14 days (11) although





© Amelia White

**Figure 4.** Green-colored fluorescence of infected hairs of the neck **(a)** and paw **(b)** using a Wood's lamp.

false negative results may occur when non-infected hairs are sampled, with a small sample size, improper storage and incubation, and overgrowth of bacterial/fungal contaminants in culture (1).

Collect skin and hair samples by hair plucking or via a toothbrush or sticky tape technique. When collecting hair and skin samples, pluck from the margin of lesions while using the Wood's lamp to identify and select fluorescing hairs. Alternatively use a sterile toothbrush to brush over the top and margins of clinical lesions, or brush the entire cat if no clinical lesions are evident; brush for two to three minutes utilizing about twenty strokes, or until ample hair is collected within the bristles (1,12). The least-utilized technique involves using sticky tape pressed over skin lesions and then applied directly onto the fungal culture plate (13).

Typically, culture is preferred when monitoring response to treatment and mycological cure. Current guidelines recommend that a combination of skin lesions, Wood's lamp examinations, and number of colony forming units (cfu/plate) on culture is the best monitoring tool. Response to treatment is defined as a decrease in cfu/plate, and clinical cure is defined as two to three negative fungal cultures (1).

### Dermatophyte PCR

PCR is a sensitive and rapid technique for the identification of fungal DNA within the skin and hair (14,15). The technique does not prove fungi are viable, since it is simply measuring the presence of

DNA, so paired positive PCR results along with DTM culture are required for confirmation of living organisms, especially when cats are non-lesional. A positive PCR result could indicate any of the following: active infection, resolving infection, or contamination of hair coat (fomite carriage). A negative PCR result could indicate lack of infection or poor sampling technique (1). Dermatophyte PCR has the advantages of being fast, affordable, widely available, and sensitive (*i.e.*, it can detect a small amount of DNA in a small sample size). Dermatophyte PCR is best used to make an initial, rapid diagnosis, while DTM cultures are more reliable for monitoring response to treatment in cases where PCR remains positive (14-18). A negative PCR in cats undergoing treatment is consistent with mycological cure (1).

### Skin cytology

Direct impression and acetate tape cytologies will reveal neutrophils and some macrophages with suitable staining. Occasionally, fungal arthrospores are identified in heavily infected animals. Fine-needle aspirate of dermal nodules due to dermatophytosis reveals pyogranulomatous inflammation and occasionally fungal hyphae and/or arthrospores.

### Dermoscopy

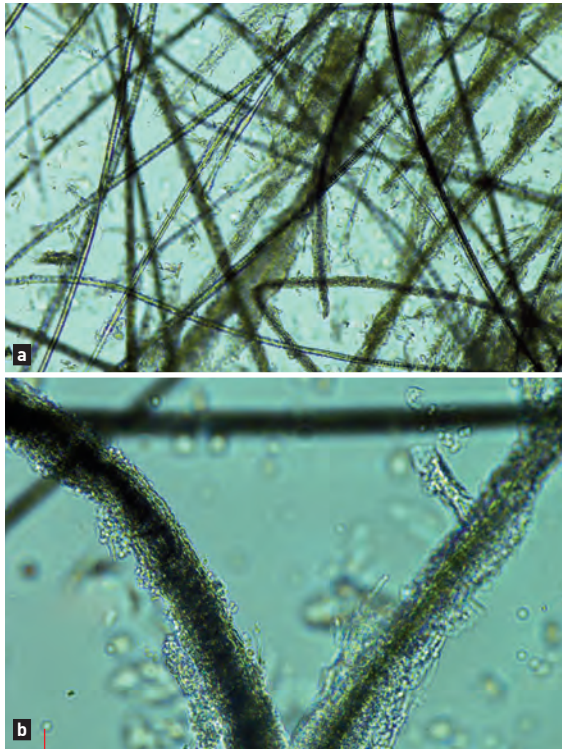
A specialized dermoscope magnifies skin and hair for evaluation of external changes in cats infected with dermatophyte, and typical changes include hairs that are opaque, slightly curved, broken, and thickened ("comma shaped"), and skin with brown to yellow crusts (19).

### Trichography

Microscopic evaluation of fluorescing and/or lesional hairs allows identification of fungal hyphae within the hair shafts and accumulation of arthrospores along or within hair shafts (**Figure 5**). Pluck suspicious hairs and scrape alopecic skin, place in mineral oil on a glass slide, apply a coverslip, and evaluate at x100-400 magnification. One study found that when using both hair plucking and skin scraping, positive identification occurred in 87.5% of infected cats (20).

### Macerated tissue fungal culture and histopathology

Dermatophytes will rarely causes deep nodular lesions. These are termed pseudomycetoma or mycetoma, and they usually contain very few fungal elements, so histopathology may not reveal evidence of fungi in tissue, even with specialized stains such as periodic acid Schiff (PAS) or Grocott methenamine silver (GMS). If dermatophyte elements are identified on histopathology, culture or PCR is needed to determine the species of dermatophyte present. It is important to remember that in the case of pseudomycetoma, even tissue culture may result in false negative results (4,21).



© Amelia White

**Figure 5.** Trichogram of hairs plucked from an area of alopecia and crusting from a cat with dermatophytosis. Notice the fungal hyphae within the hair shafts and fungal arthrospores along the outside of the hair shafts – (a) x100 magnification, (b) x400 magnification –.

## Treatment and prevention

Treatment of lesional, culture or PCR-positive cats is recommended in order to reduce the contamination of the environment and spread of disease. Treatment may be topical, systemic or both, but isolation of the affected animal during treatment is generally recommended. Prevention is best achieved by treating predisposing conditions and decontaminating the environment. Isolate infected cats into easily disinfected rooms away from non-infected cats. Cats are easily stressed when isolated, especially if completely alone, which may exacerbate disease, and clinical consensus guidelines suggest that the shortest possible confinement time should be employed (1). However, time to cure is highly variable and dependent on various factors (e.g., overall health status, age, environmental stresses, treatment compliance, etc.), although the time period involved is usually weeks to months. Infected hairs and spores are a source of reinfection of the same cat, or spread to other pets and people in the environment in rare circumstances (2,22). Frequent (twice weekly at least) vacuuming and disposal of contents helps to remove hairs, crusts, and scales from the environment. Washing bedding, steam cleaning, and cleaning with dust wipes, accelerated hydrogen peroxide, bleach, and enilconazole are effective environmental decontamination measures. Performing environmental cultures is not recommended, since environmental contamination is an expected finding when infected animals are present.

## Topical therapies

Topical therapy is important to reduce the infectious elements shed by the cat by physically removing infected hairs, scales, and crusts, and acting as a fungicidal agent. Options include: lime sulfur leave-on rinse, enilconazole leave-on rinse, miconazole/ketoconazole/climbazole formulations, terbinafine formulations, topical essential oils, and accelerated hydrogen peroxide formulations. However, not all of these are particularly effective. The clinical consensus guidelines recommend the use of twice weekly applications of lime sulfur, enilconazole, or miconazole/chlorhexidine shampoo for generalized dermatophytosis, or the use of clotrimazole, miconazole, or enilconazole for localized disease in conjunction with other therapies (1).

Different formulations of topical agents range from concentrated rinses, shampoos, sprays, lotions, mousses, or creams/ointments. Some studies suggest that clipping hair improves topical treatment efficacy and reduces environmental contamination; however, it may also increase stress to the cat and lead to spread of infection through skin microtrauma (1). Many factors will determine if topical therapy is the best route of treatment and which formulation to use, including patient tolerance, hair coat, owner compliance, cutaneous lesion characteristics, and product characteristics. Topical therapy has the advantage of avoiding systemic side effects of medications, so it is safe for use in almost all cats, including the young, old, and debilitated. Topical antifungal therapy can be used as an adjunctive therapy for subcutaneous dermatophytosis, but is not appropriate as sole therapy.

## Systemic therapies

The purpose of systemic therapy is to inhibit proliferation of fungal infection within the hair and skin of the infected animal so that there is a decreased risk of lesion propagation throughout the infected animal, contamination within the environment, and contagion to other animals and people. Systemic therapeutic options include itraconazole, ketoconazole, fluconazole, terbinafine and griseofulvin (1). The current consensus guidelines recommend the use of itraconazole or terbinafine due to their wide safety profile and high efficacy rates, while ketoconazole and fluconazole are considered less effective treatment options (1). Griseofulvin is effective, but has the potential for severe adverse effects compared to itraconazole and terbinafine. Lufenuron is not an effective treatment, and fungal vaccines most likely are only useful as an adjunct therapy (1).

Itraconazole is a triazole with a broad spectrum of activity. It inhibits ergosterol formation in the fungal cell membrane via the inhibition of the fungal cytochrome P450 enzyme, 14 $\alpha$  demethylase. Itraconazole is considered fungistatic at low doses and fungicidal at high doses. It is highly lipophilic and concentrates in the skin and sebum at concentrations ten times that of plasma. The recommended dose for feline dermatophytosis is 5-10 mg PO q24H with food. Studies in cats

demonstrate that weekly pulse dosing (5 mg/kg PO q24H, week on/week off) results in cumulative, increasing drug concentrations in hairs above the minimum inhibitory concentration (MIC) for *M. canis* (0.1 µg/mL) over a 35-day period [23]. Repeated pulse dosing at this level for five weeks resulted in 97.5% cure of infected cats by nine weeks [24]. Compounded formulations, while cheaper, are not reliable nor recommended for use in cats. Side effects may occur but are less likely compared to other azoles and triazoles; they include gastrointestinal disturbance, elevated liver enzyme activity, and hepatotoxicity.

Terbinafine is a synthetic allylamine with a broad spectrum of activity. It inhibits the fungal membrane-bound enzyme, squalene epoxidase, thereby preventing the conversion of lanosterol to ergosterol. Terbinafine has a very low MIC for *M. canis* (0.002-0.25 µg/mL) as compared to itraconazole. It is highly concentrated in the hair of cats at doses ranging from 10-40 mg/kg PO q24H, with drug concentrations in the hair ranging from 0.47-9.6 µg/g. In one study, cats maintained therapeutic drug concentrations in the hair follicle for 56 days after completing two weeks of terbinafine at 35-40 mg/kg PO q24H [25]. Despite its reported high drug concentration in hairs well after the final dose, clinical studies show the best outcomes occur when terbinafine is dosed for a minimum of 21 consecutive days [25,26]. Terbinafine is well tolerated and side effects (e.g., gastrointestinal disturbance, lethargy and weight loss) are uncommon and mild in nature. Elevation of liver enzymes may occur but rarely extends outside of reference intervals, even at high doses in cats [1].



## Prognosis

Dermatophytosis carries a good prognosis for cure; however, treatment can be frustrating in multi-animal households where environmental contamination is prevalent. It is important to look for underlying causes of infection and initiate treatment if the disease is ongoing (e.g., allergies, stress, immunocompromise, etc.).



## CONCLUSION

**Dermatophytosis is a common superficial fungal dermatosis that is highly contagious between cats and carries a zoonotic risk. Clinical lesions vary and tend to be both multifocal and asymmetrical in distribution. Diagnosis is achieved readily through a combination of history, physical exam and diagnostic tests, although false positive and negative results are possible. Topical and systemic treatments are recommended – despite the self-limiting nature of this disease and the fact that the disease carries a good prognosis – in order to prevent contagion to the infected and noninfected animals, as well as people.**



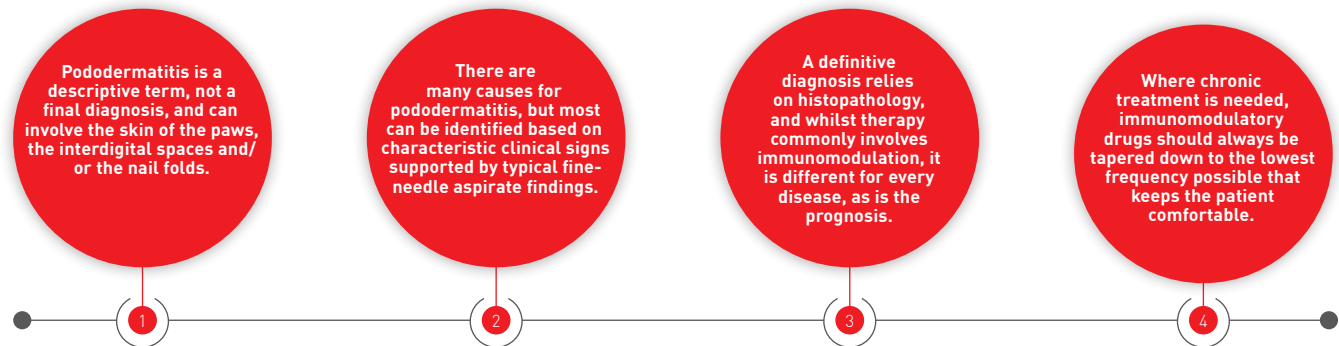
## REFERENCES

- Moriello KA, Coyner K, Paterson S, *et al.* Diagnosis and treatment of dermatophytosis in dogs and cats: Clinical Consensus Guidelines of the World Association for Veterinary Dermatology. *Vet Dermatol* 2017;28:266-e268.
- Mancianti F, Nardoni S, Corazza M, *et al.* Environmental detection of *Microsporum canis* arthrospores in the households of infected cats and dogs. *J Feline Med Surg* 2003;5:323-328.
- DeTar LG, Dubrovsky V, Scarlett JM. Descriptive epidemiology and test characteristics of cats diagnosed with *Microsporum canis* dermatophytosis in a Northwestern US animal shelter. *J Feline Med Surg* 2019;21:1198-1205.
- Nuttall TJ, German AJ, Holden SL, *et al.* Successful resolution of dermatophyte mycetoma following terbinafine treatment in two cats. *Vet Dermatol* 2008;19:405-410.
- Tainwala R, Sharma Y. Pathogenesis of dermatophytoses. *Indian J Dermatol* 2011;56:259-261.
- Baldo A, Chevigné A, Dumez ME, *et al.* Inhibition of the keratinolytic subtilisin protease Sub3 from *Microsporum canis* by its propeptide [proSub3] and evaluation of the capacity of proSub3 to inhibit fungal adherence to feline epidermis. *Vet Microbiol* 2012;159:479-484.
- Ogawa H, Summerbell RC, Clemons KV, *et al.* Dermatophytes and host defence in cutaneous mycoses. *Med Mycol* 1998;36 Suppl 1:166-173.
- DeBoer DJ, Moriello KA. Development of an experimental model of *Microsporum canis* infection in cats. *Vet Microbiol* 1994;42:289-295.
- Wolf FT, Jones EA, Nathan HA. Fluorescent pigment of *Microsporum*. *Nature* 1958;182:475-476.
- Kaufmann R, Blum SE, Elad D, *et al.* Comparison between point-of-care dermatophyte test medium and mycology laboratory culture for diagnosis of dermatophytosis in dogs and cats. *Vet Dermatol* 2016;27:284-e268.
- Stuntebeck R, Moriello KA, Verbrugge M. Evaluation of incubation time for *Microsporum canis* dermatophyte cultures. *J Feline Med Surg* 2018;20:997-1000.
- Goldberg HC. "Brush" technique in animals. Finding contact sources of fungus diseases. *Arch Dermatol* 1965;92:103.
- Sparkes AH, Robinson A, MacKay AD, *et al.* A study of the efficacy of topical and systemic therapy for the treatment of feline *Microsporum canis* infection. *J Feline Med Surg* 2000;2:135-142.
- Cafarchia C, Gasser RB, Figueredo LA, *et al.* An improved molecular diagnostic assay for canine and feline dermatophytosis. *Med Mycol* 2013;51:136-143.
- Jacobson LS, McIntyre L, Mykusz J. Comparison of real-time PCR with fungal culture for the diagnosis of *Microsporum canis* dermatophytosis in shelter cats: a field study. *J Feline Med Surg* 2018;20:103-107.
- Jacobson LS, McIntyre L, Mykusz J. Assessment of real-time PCR cycle threshold values in *Microsporum canis* culture-positive and culture-negative cats in an animal shelter: a field study. *J Feline Med Surg* 2018;20:108-113.
- Dabrowska I, Dworecka-Kaszak B, Brillowska-Dabrowska A. The use of a one-step PCR method for the identification of *Microsporum canis* and *Trichophyton mentagrophytes* infection of pets. *Acta Biochimica Polonica* 2014;61:375-378.
- Moriello KA, Leutenegger CM. Use of a commercial qPCR assay in 52 high risk shelter cats for disease identification of dermatophytosis and mycological cure. *Vet Dermatol* 2018;29:66-e26.
- Dong C, Angus J, Scarampella F, *et al.* Evaluation of dermoscopy in the diagnosis of naturally occurring dermatophytosis in cats. *Vet Dermatol* 2016;27:275-e265.
- Colombo S, Cornegliani L, Beccati M, *et al.* Comparison of two sampling methods for microscopic examination of hair shafts in feline and canine dermatophytosis. *Veterinaria* 2010;24:27-33.
- Chang SC, Liao JW, Shyu CL, *et al.* Dermatophytic pseudomycetomas in four cats. *Vet Dermatol* 2011;22:181-187.
- Heinrich K, Newbury S, Verbrugge M. Detection of environmental contamination with *Microsporum canis* arthrospores in exposed homes to and efficacy of the triple cleaning decontamination technique. 2005;16:205-206.
- Vlaminck K, Engelen M. An overview of pharmacokinetic and pharmacodynamic studies in the development of itraconazole for feline *Microsporum canis* dermatophytosis. In: Hillier A, Foster A, Kwochka K (eds). *Advances in Veterinary Dermatology* Oxford: Blackwell Publishing, 2005;130-136.
- Puls C, Johnson A, Young K, *et al.* Efficacy of itraconazole oral solution using an alternating-week pulse therapy regimen for treatment of cats with experimental *Microsporum canis* infection. *J Feline Med Surg* 2018;20:869-874.
- Foust AL, Marsella R, Akucewicz LH, *et al.* Evaluation of persistence of terbinafine in the hair of normal cats after 14 days of daily therapy. *Vet Dermatol* 2007;18:246-251.
- Moriello K, Coyner K, Trimmer A, *et al.* Treatment of shelter cats with oral terbinafine and concurrent lime sulphur rinses. *Vet Dermatol* 2013;24:618-620, e149-650.

# FELINE PODODERMATITIS

Cats will often present to first opinion clinics with a variety of foot lesions; Ronnie Kaufmann discusses the main differentials, diagnostics and treatment options.

## KEY POINTS



## ●○○○ Introduction

Pododermatitis is the name given to the clinical presentation of an inflammation affecting the paws, although it can involve the skin of the paws, the interdigital spaces and/or the nail folds (paronychia). Pododermatitis can be the only abnormality detected, or it may be accompanied by other dermatologic or systemic clinical signs, so any cat with footpad lesions warrants a complete dermatological and physical examination. Remember that pododermatitis is a descriptive term, not a final diagnosis, and there is more than one differential diagnosis!

The overall prevalence of feline pododermatitis among dermatological diagnoses is low (1). Diseases affecting the pads include, though are not limited to, eosinophilic granuloma, pemphigus foliaceus, mosquito bite hypersensitivity, metastatic adenocarcinoma (so called "lung-digit syndrome") and plasma cell pododermatitis.

## ●●○○ Plasma cell pododermatitis

### Etiology and clinical signs

Plasma cell pododermatitis (PCP) is a rare dermatological condition of cats characterized by soft swelling of the paw-pads, which may eventually ulcerate to cause pain and lameness (2-7). The exact etiology and pathogenesis are not fully elucidated, although many studies have looked at possible triggers. A recent study (7) failed to detect several infectious agents (including *Bartonella* spp.,

*Ehrlichia* spp., *Anaplasma phagocytophilum*, *Chlamydomphila felis*, *Mycoplasma* spp., *Toxoplasma gondii*, and feline herpesvirus) in tissue samples by immunohistochemistry and PCR. Previous publications reported concurrent FIV infection in 44-62% of cases, but the association is possibly incidental rather than causal (4,5-8). An allergic etiology has also been suggested due to apparent seasonality (4,8). Regardless of cause, an immune-mediated pathogenesis purportedly underlies PCP, based both on lack of evidence of infectious agents and on the findings of tissue plasmacytosis, consistent hypergammaglobulinemia, and the favorable response to immunomodulating agents (2,3).

The disease can affect cats of almost any age, with no sex or breed predisposition. Clinical signs can range from painless soft, spongy swelling of the pads, with erythema, depigmentation, silvery striae and fine scaling, to ulceration and consequently bleeding, pain and lameness which can be severe (Figures 1-3). Typically, multiple paws are affected, with lesions predominantly on the central metacarpal and metatarsal pads. The digital pads may also be affected, but usually to a lesser degree. Rarely a single footpad will be affected. Secondary bacterial infection is not uncommon (2-8).

Some affected cats may show other clinical signs including poor body condition, hypersalivation (4), lymphadenopathy, pyrexia, anorexia, lethargy and (rarely) plasma cell dermatitis, with swelling of the nose or stomatitis (3,4). Immune-mediated glomerulonephritis or renal amyloidosis have also been reported (2,3,8). Clinical pathologic



## Ronnie Kaufmann,

BSc., DVM, Dip. ECVD, The Veterinary Teaching Hospital, Koret School of Veterinary Medicine, The Hebrew University of Jerusalem, Israel

Dr. Kaufmann received her veterinary degree from the Hebrew University of Jerusalem in 2006 and worked in general practice for three years before returning to the Koret School of Veterinary Medicine as a dermatology resident. She then remained as a clinician and lecturer at the school before being promoted to her current position as head of dermatology in 2017. Her main areas of interest include straelensiosis in companion animals and genetic dermatological conditions.

findings may include anemia, leukocytosis and thrombocytopenia. A polyclonal gammopathy is present in all cases and can persist after treatment (2,5).

### Diagnosis

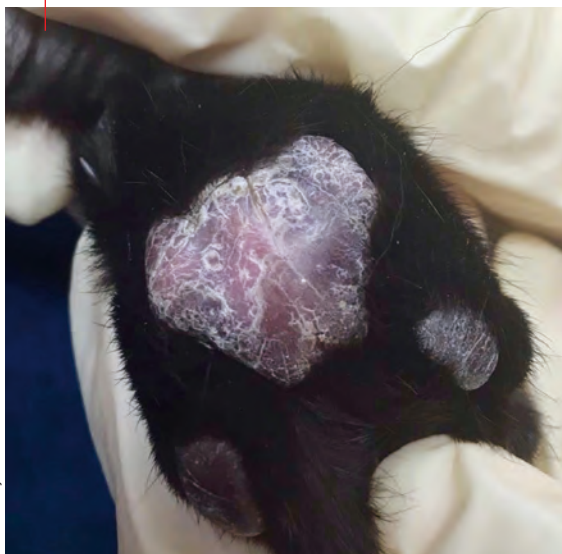A tentative diagnosis can be made based on typical clinical signs, as the hallmark of PCP is soft swelling of the central pads, with or without ulceration, and usually in more than one foot. When this is present without other dermatological lesions the suspicion should be very high, and fine-needle aspiration (FNA) from a swollen pad showing plasma cells (2,3,6) (**Figure 4**) will support the notion. Definitive diagnosis is based on histopathology, but should avoid sampling ulcerated lesions. Histopathology features commonly include diffuse infiltration of plasma cells throughout the dermis and subcutis, and a variable number of lymphocytes, neutrophils and eosinophils in addition to Mott cells (plasma cells containing Russell bodies). Fibrosis and granulation tissue may be seen in chronic cases

(2-4,6-8). The main differential diagnosis for PCP is eosinophilic granuloma, although the latter frequently has concurrent skin lesions, rarely affects multiple paws, and tends to affect the interdigital spaces rather than only the paw-pads (2,3). When a single pad is affected, neoplasia or a foreign body should be considered (3). Multiple affected paws, especially when accompanied by paronychia, could suggest an infectious etiology.

### Treatment

Plasma cell pododermatitis is characterized by a waxing and waning course, with some cases experiencing spontaneous remission, while others need life-long therapy (2,3,6,8). The current mainstay of treatment is immunomodulatory therapy and the initial therapy of choice is oral doxycycline (2,3), an antibiotic with immunomodulatory properties. The recommended dose is 10 mg/kg q24H or 5 mg/kg q12H until clinical resolution, which might take up to 12 weeks (5,6). Since cats are prone to develop drug-induced esophagitis and subsequent

**Figure 1.** Typical silvery striae and fine scaling affecting mostly the central pad in a cat with plasma cell pododermatitis.



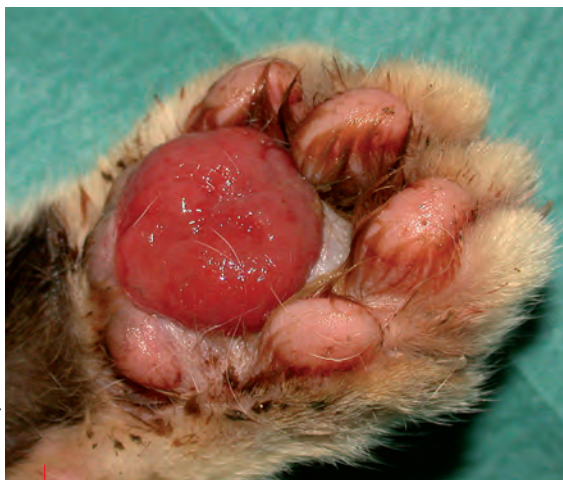© Courtesy of Dr. Ramon Almela

**Figure 2.** Plasma cell pododermatitis can affect felines other than the domestic cat! This image is from a captive tiger (*Panthera tigris*) with suspected PCP; note the ulceration which affects most of the pads but particularly the central metacarpal pad.



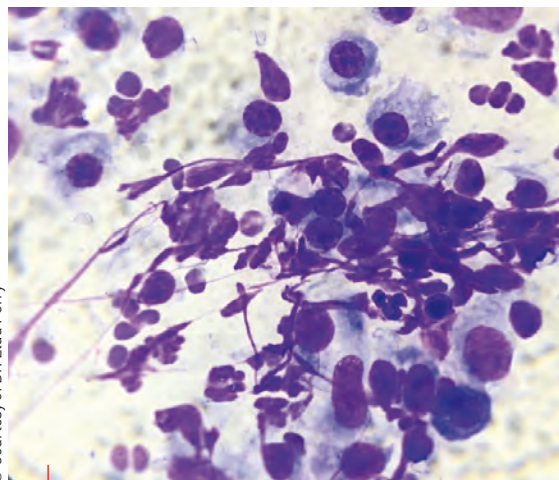
© Ronnie Kaufmann

© Courtesy of Dr. Federico Leone



**Figure 3.** Ulceration of the central pad as typically seen in plasma cell pododermatitis.

© Courtesy of Dr. Elad Perry



**Figure 4.** Cytology from a cat with PCP; note the round cells (plasma cells) amongst the neutrophils.

esophageal stricture with this drug, it is imperative to administer the tablets or capsules with food and/or water [2,3]. Cases with severe clinical signs and/or where doxycycline is ineffective will require systemic glucocorticoids: *i.e.*, prednisolone at 2-4 mg/kg q24H, triamcinolone at 0.4-0.6 mg/kg q24H or dexamethasone 0.5 mg/kg, along with cyclosporine at 5-7.5 mg/kg q24H, to be tapered off slowly once in remission [2,3]. Surgical excision has also been reported as curative, with no recurrence in the surgically treated pads after a follow-up period of 2 years [4,8]. In cases requiring chronic treatment the immunomodulating drug should always be tapered down to the lowest frequency that allows the patient to remain comfortable.



## Eosinophilic granuloma

### Etiology and clinical signs

Feline eosinophilic granuloma (EG) affecting the paws is a manifestation of one of the three common presentations of feline eosinophilic granuloma complex (FEGC) [9-11]. Eosinophilic granuloma is a cutaneous reaction pattern and rarely a final diagnosis. Although the exact etiopathogenesis of FEGC is unclear, most evidence points to an underlying hypersensitivity to insects (mostly fleas), environmental allergens or foods. Some cases are idiopathic, although a genetic background may also be considered [9-12].

Excluding hereditary forms, which present at a younger age [9,10,12], no breed, sex or age predilection exists for EG [9-11]. The clinical presentation is very variable, as lesions can occur anywhere on the body, including the oral cavity. They are usually non-pruritic, well demarcated, raised to nodular, erythematous to orange-yellow in color, and occasionally ulcerated [9-11]. Lesions on the footpads are typically crusted and ulcerated (**Figure 5**). Eosinophilia may be present, although this is not a diagnostic feature [9-11]. A recent study has described atypical EG lesions affecting multiple paws in two littermates [12].

### Diagnosis

When a cat is presented with crusty and/or ulcerated lesions of the paws a thorough dermatological examination should be performed, including the oral cavity, to exclude involvement of additional sites. Characteristic lesions in other locations should raise the suspicion of EG. Affected cats can also suffer simultaneously from other eosinophilic lesions and/or miliary dermatitis, further consolidating the suspicion of an eosinophilic disease [9-11]. Touch smears from ulcerated lesions or from under crusty lesions, or FNA from nodular lesions will aid diagnosis; samples usually show a mixed inflammatory reaction with a predominantly eosinophilic infiltrate [9,10]. Tissue eosinophilia, albeit supportive, is not diagnostic in itself for EG, and histologic evaluation is required to establish a diagnosis [9-11].

Differential diagnoses for EG footpad lesions include neoplasia [squamous cell carcinoma and mast cell tumor], infectious granuloma (bacterial folliculitis and furunculosis, mycobacteria, dermatophytes or deep fungal infection), abscessation, feline cowpox, foreign body reaction and sterile granulomatous disease [9-11]. Final diagnosis is achieved by histopathology, which is mandatory in solitary nodular lesions to rule out neoplasia or foreign bodies. Histopathology features consist of nodular to diffuse granulomatous dermatitis with a prominent eosinophilic infiltrate and multi-focal areas of collagen surrounded by degranulated eosinophils, known as “flame figures” [9-11]. Once the diagnosis of EG is confirmed, every attempt should be made to identify the underlying etiology.

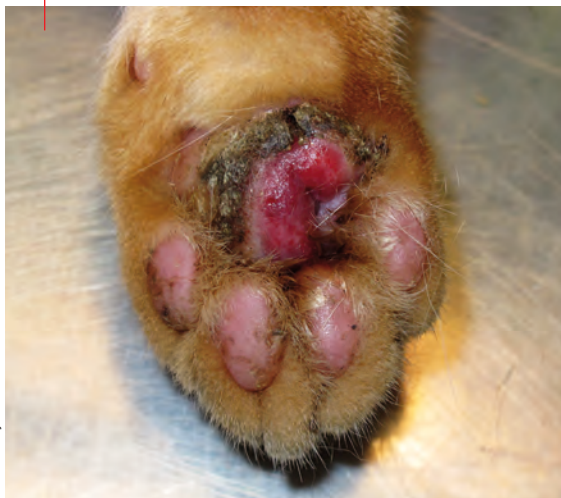### Treatment

As with PCP, the prognosis for EG is variable, and spontaneous resolution is possible. In cases when an underlying cause is successfully identified and managed (*i.e.*, flea or food hypersensitivity) the prognosis is very good as long as the offending triggers can be avoided. In idiopathic or atopy-related cases life-long treatment is necessary

(9-11). Therapy consists of immunomodulation, specifically oral prednisolone 1-2 mg/kg daily, then tapered to alternate-day dosing when possible. Sometimes higher doses (up to 4 mg/kg) may be required, and some cases will respond better to dexamethasone at 0.1-0.2 mg/kg (tapering to a maintenance dose of 0.05-0.1 mg/kg q72H), or triamcinolone 0.2-0.3 mg/kg daily. The goal is always to maintain the cat on the lowest possible dose and – more importantly – the lowest possible frequency that keeps it comfortable [9-11]. Every attempt should be made to avoid methylprednisolone acetate injections due to the higher risk of side effects, combined with the inability to withdraw treatment if adverse effects occur and the fact that increased doses may be required for cases with insufficient response [9]. Side effects of glucocorticoid therapy, though less common compared to dogs, include polydipsia, polyphagia, weight gain, diabetes mellitus, urinary tract infection, iatrogenic hyperadrenocorticism and feline cutaneous fragility syndrome, congestive heart failure, demodicosis and dermatophytosis [9,10].

Cyclosporine at 7-7.5 mg/kg q24H has also proved efficacious for EG [9-11]. Due to a lag phase of 2-3 weeks, treatment should continue for at least 4 weeks and then taper to alternate days when possible, with some cases successfully managed on a q72H regimen. Side effects are not common, although 25% of cats may suffer transient gastrointestinal signs, including vomiting and diarrhea. In the author's experience co-administration of maropitant (2 mg/kg) during the first 2-3 weeks and/or gradually increasing the daily dose of cyclosporine can reduce the risk of vomiting. Other described adverse effects are weight loss, and (rarely) gingival hyperplasia, hypersalivation, anorexia and hepatic lipidosis [9,10]. Cats prescribed cyclosporine should be FIV and FeLV negative and should not be allowed to hunt or eat raw meat, due to the risk of developing fatal toxoplasmosis.

**Figure 5.** An ulcerated crusty pad in a cat with eosinophilic granuloma.



© Courtesy of Dr. Federico Leone



**“When a cat is presented with crusty and/or ulcerated lesions of the paws a thorough dermatological examination should be performed, including the oral cavity, to exclude involvement of additional sites.”**

Ronnie Kaufmann



## Pemphigus foliaceus

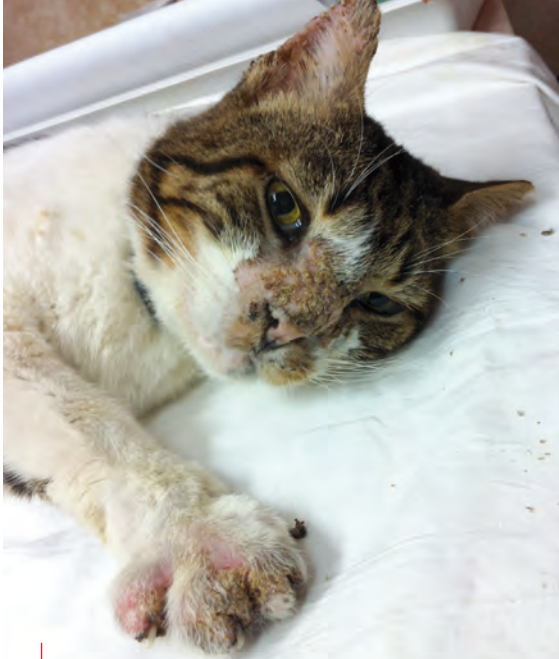### Etiology and clinical signs

Pemphigus foliaceus (PF) is the most common autoimmune skin disease in cats, accounting for almost 1% of all cases seen by dermatologists [1]. It is a pustular, erosive and crusting dermatosis involving the face, ears and feet. Relapse is frequent and most cases will require long-term therapy, which should be personalized to each patient [13-18].

Most cases appear to be idiopathic, with the remainder resulting from drug reactions and vaccines [13-16], thymoma [14-16] and leishmaniasis [14]. The disease is characterized by autoantibodies produced against intercellular connections between epidermal cells in the superficial epidermis and follicular epithelium, known as desmosomes. These engender loss of cell-to-cell adhesion and the formation of acantholytic cells, which accumulate in sub-corneal and intraepidermal pustules which might eventually erupt into crusts, giving the disease its classically crusty appearance [13-16]. Though tissue-bound and circulating anti-keratinocyte IgG autoantibodies are detected in the majority of cats with PF, the exact pathomechanism is yet to be discovered, and the major target autoantigen in cats is still unknown [14-18].

The median age of onset is 6 years of age, with a range of 0.25-16 years [13-18]. Domestic breed cats are over-represented, sex predilection has not been confirmed, but two recent reviews suggest that females may be marginally more prone to the condition [13-14].

PF presents as a symmetric bilateral pustular disease, but since pustules rupture easily the typical clinical signs often include crusts,



© Ronnie Kaufmann

**Figure 6.** A cat with lesions of pemphigus foliaceus; crusts on the muzzle, ear pinna and paws.

erosions, ulcerations, erythema and alopecia (**Figure 6**). In the majority of cases lesions involve more than one body region, most notably the head/face, claw folds and paws/pads (13-18). In some cases, claw folds can be the only affected area, which warrants consideration of PF in cats with erosive, exudative and/or crusting paronychia affecting the majority of the digits (14), which is sometimes so severe that the digits are forced to splay out (**Figure 7**). Pruritus is variable, and more than half of all cases will show systemic signs such as lethargy, pyrexia and anorexia (13-18). Lameness and pain are common if there are severe lesions affecting the paws. Clinicopathological findings of leukocytosis, neutrophilia, hyperglobulinemia and anemia are variably present (13,15).



**“The hallmark of plasma cell pododermatitis is soft swelling of the central pads, with or without ulceration, and usually in more than one foot. When this is present without other dermatological lesions the suspicion should be very high, and fine-needle aspiration will support the diagnosis.”**

Ronnie Kaufmann

## Diagnosis

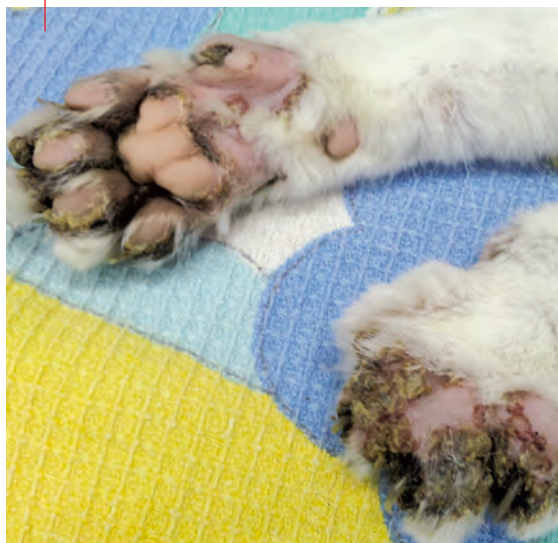When typical clinical signs are present, most commonly pustules and crusts affecting multiple body sites with bilateral symmetry or multiple digits, cytology should be obtained directly from pustules or from underneath crusts. Characteristic findings include acantholytic cells (rounded keratinocytes with dark cytoplasm, resembling a “fried egg”) with intact neutrophils and occasionally eosinophils (15-18) (**Figure 8**).

Definitive diagnosis is based on biopsies, either of whole pustules or (when a pustule cannot be sampled) crusts. Typical histopathological findings consist of crusting which frequently spans numerous hair follicles, sub-corneal or intragranular pustules, numerous acantholytic keratinocytes, and a predominantly neutrophilic dermal infiltrate which is often accompanied by eosinophils, mast cells and plasma cells (13-18).

## Treatment

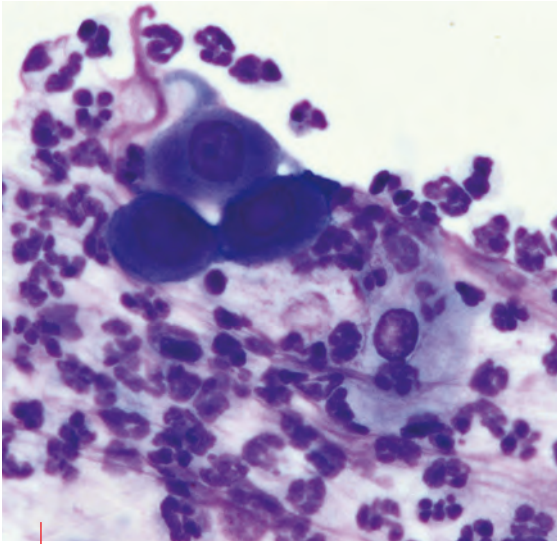
Feline PF carries a favorable prognosis, with the majority of cats experiencing remission within a few weeks of treatment commencing (13-18). Importantly, disease control is defined as cessation of active lesions and healing of original lesions and not necessarily complete disappearance of all signs (14). Most cats respond very well to glucocorticoid (GC) monotherapy, typically prednisolone at an initial dose of 2-4 mg/kg daily, with most documented cases responding to the lower dose. Other options include oral triamcinolone (0.2-0.6 mg/kg) or dexamethasone (0.1-0.2 mg/kg). Tapering the dose (20-25% reduction every

**Figure 7.** Pemphigus foliaceus can cause severe paronychia and crusts, forcing the digits to splay out. In this case the lesions affected all paws and all digits, including the dewclaws.



© Ronnie Kaufmann





**Figure 8.** Typical cytological findings from a pustule from a cat with PF. Note the rounded keratinocytes with dark cytoplasm, resembling a “fried egg” (i.e., acantholytic cells) surrounded by neutrophils.

2-4 weeks) is recommended once the disease is inactive for at least 2 weeks and most original skin lesions have healed (14,15,17,18).

Non-steroidal drugs reported to induce disease control in cats include cyclosporine (5-10 mg/kg daily) and chlorambucil (0.1-0.3 mg/kg daily) and are recommended in cases failing to respond to GC monotherapy, when severe side effects are seen with GC treatment, or when GC cannot be tapered off (14-18). Most cats require long-term treatment due to the high frequency of relapse which can be due to drug tapering or discontinuation, but can also occur in well controlled cases (13-18).

Owners should be aware of this latter possibility from the time of diagnosis, and discussion of different treatment protocols and side effects is warranted.

## ●●●○ Mosquito bite hypersensitivity

### Etiology and clinical signs

Feline mosquito bite hypersensitivity (MBH) is an uncommon, seasonal, pruritic dermatitis typically affecting the scarcely haired areas of the skin including the face, ears and paw-pads; the mosquito bite causes an IgE type I hypersensitivity reaction (10,19).

There is no age, sex or breed predilection. Lesions are seen on poorly haired areas on the muzzle, pinnae, periaural and periorbital areas and the footpads, as cats will often lie with their legs outstretched. Erythematous papules or plaques progress to erosions and ulcers with crusts. Hyperkeratosis and variable pigmentation of the footpads is common, and pruritus can be intense. Occasionally regional lymphadenopathy, fever and mild eosinophilia are present (10,19).

## Diagnosis

The differential diagnosis will depend on the number of feet affected, and the aforementioned causes of pododermatitis should be considered. Cytology of lesions and lymph nodes can be supportive of MBH if dominated by eosinophils (19). Typical histopathology findings consist of eosinophilic folliculitis and furunculosis, eosinophil exocytosis, a diffuse dermal eosinophilic inflammation and occasional flame figures (19). Where the suspicion is high and there is a history of seasonality, mosquito avoidance will result in resolution within a few days.

## Treatment

Usually a short course of systemic GC is needed to control acute clinical signs, but mosquito avoidance is the mainstay of therapy (10,19). Cats should be kept indoors during active mosquito hours and/or wear a protective anti-parasitic collar (19).

## ●●●● Metastatic adenocarcinoma

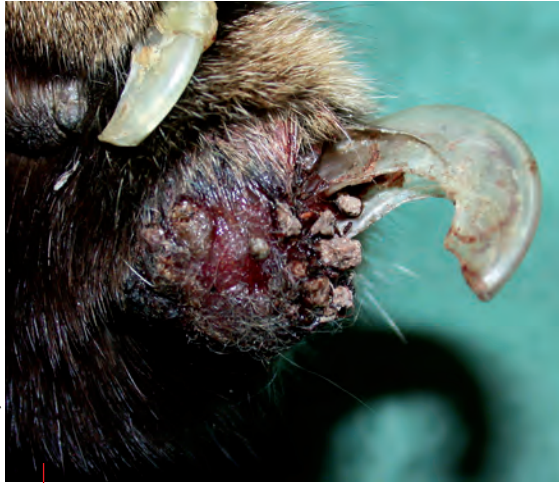### Etiology and clinical signs

Feline lung-digit syndrome (FLDS) describes an unusual pattern of metastasis from primary lung tumors, most commonly adenocarcinoma, to one or more digits (20-22). Primary lung tumors are considered rare in the cat, with adenocarcinoma being the most common (21). In one retrospective study, 88% of carcinomas in the digits represented metastases from primary lung carcinoma (23). A more recent study looking at biopsies from 85 amputated feline digits identified a neoplastic disease in the majority (63) of cases, with 95.2% of them being malignant (24). Metastatic adenocarcinomas of the lungs was the third most prevalent cause, which suggests that approximately 1 in 6 amputated digits submitted for histopathology in this study was a metastatic lesion (20). The metastatic spread to the digits is thought to be due to the angioinvasive properties of these lesions and subsequent hematological spread. Cats have a high digital blood flow, offering a possible explanation for the significant rate of metastatic spread to this site (20).

This is an uncommon disease affecting mostly older cats, with a mean age of 12 years (range 4-20 years) (20,24). Usually more than one digit is affected, with the exception of the dew claws (20,22). Typical signs include lameness, digital swelling, purulent nail bed discharge and fixed exsheathment of nails (**Figure 9**). Clinical signs associated with the primary lung tumor are often absent.

## Diagnosis

Diagnosis can be easily confirmed by radiographs of the digits, which will classically show osteolysis of P3, potentially invading the P2-P3 intra-articular space, and possible osteolysis of P2; this is



**Figure 9.** A cat with feline lung-digit syndrome; paronychia, hemorrhage and fixed exsheathment of the nail are evident.

combined with thoracic radiography demonstrating a solitary circumscribed mass, usually in the caudal lung lobes [20-22]. Rarely, a thoracic radiograph will prove poorly sensitive, and a CT scan is recommended [22]. When in doubt, histopathology of an amputated digit will confirm the diagnosis [20,22-24].

## Treatment

The prognosis is grave, with reported survival time as low as 12 days and up to 125 days. Cats are usually euthanized due to pain, lethargy and anorexia [20,21] and sudden death is possible [21]. Attempting surgical amputation should be carefully considered, given the poor prognosis [20-22].



## CONCLUSION

Any cat presenting with paw-pad lesions should undergo a full dermatological and physical examination. When signs are confined to the feet, PCP and FLDS are the main differentials, and to a lesser degree EG, which occasionally only affect the paws; these can be tentatively differentiated by their gross appearance, supported by FNA findings. PF can also infrequently be confined to the paws, usually involving all feet and accompanied by severe paronychia. EG, MBH and PF more typically affect other body sites, but PF will usually have a bilateral symmetry with pustules and crusts, as opposed to the sporadic distribution of EG or localization of MBH to sparsely haired areas of the face. Lastly, systemic signs are more common in PF. A definitive diagnosis relies on histopathology, and although therapy commonly involves immunomodulation, it is different for every disease, as is the prognosis.



## REFERENCES

1. Scott DW, Miller WH, Erb HN. Feline dermatology at Cornell University: 1407 cases (1988-2003). *J Feline Med Surg* 2012;15(4):307-316.
2. Cain CL, Mauldin EA. Diagnostically Challenging Dermatoses of Cats. In: Little SE [ed.] *August's Consultations in Feline Internal Medicine* Vol. 7. 1<sup>st</sup> ed. St Louis, MO; WB Saunders 2016;295-306.
3. Banovic F. Immune-Mediated Diseases. In: Noli C, Colombo S (eds.) *Feline Dermatology*. 1<sup>st</sup> ed. Switzerland AG, Springer Nature 2020;511-530.
4. Guaguere E, Prelaud P, Degorce-Rubiales F, et al. Feline plasma cell pododermatitis: a retrospective study of 26 cases. *Vet Dermatol* 2004;15:27.
5. Scarampella F, Ordeix L. Doxycycline therapy in 10 cases of feline plasma cell pododermatitis: clinical, haematological and serological evaluations. *Vet Dermatol* 2004;15:27.
6. Bettenay SV, Mueller RS, Dow K, et al. Prospective study of the treatment of feline plasmacytic pododermatitis with doxycycline. *Vet Rec* 2003;152:564-566.
7. Bettenay SV, Lappin MR, Mueller RS. An immunohistochemical and polymerase chain reaction evaluation of feline plasmacytic pododermatitis. *Vet Pathol* 2007;44:80-83.
8. Pereira PD, Faustino AMR. Feline plasma cell pododermatitis: a study of 8 cases. *Vet Dermatol* 2003;14:333-337.
9. Buckley L, Nuttall T. Feline eosinophilic granuloma complexities: some clinical clarification. *J Feline Med Surg* 2012;14:471-481.
10. Bloom PB. Canine and feline eosinophilic skin diseases. *Vet Clin North Am Small Anim Pract* 2006;36:141-160.
11. Miller WH, Griffin CE, Campbell KL. Miscellaneous skin diseases. In: *Muller and Kirk's Small Animal Dermatology*. 7<sup>th</sup> ed. Philadelphia, WB Saunders, 2013;695-723.
12. Pressanti C, Cadiergues MC. Feline familial pedal eosinophilic dermatosis in two littermates. *J Feline Med Surg* 2015;1(1):2055116915579683.
13. Jordan TJM, Affolter VK, Outerbridge CA, et al. Clinicopathological findings and clinical outcomes in 49 cases of feline pemphigus foliaceus examined in Northern California, USA (1987-2017). *Vet Dermatol* 2019;30:209-219.
14. Bizikova P, Burrows A. Feline pemphigus foliaceus: original case series and a comprehensive literature review. *BMC Vet Res* 2019;22:1-15.
15. Preziosi DE. Feline pemphigus foliaceus. *Vet Clin Small Anim* 2019;49:95-104.
16. Olivry T. A review of autoimmune skin diseases in domestic animals: 1 – superficial pemphigus. *Vet Dermatol* 2006;17:291-305.
17. Bizikova P. Autoimmune Diseases. In: Noli C, Colombo S (eds.) *Feline Dermatology*. 1<sup>st</sup> ed. Switzerland AG, Springer Nature 2020;495-509.
18. Klinger CJ, Mueller RS. Pemphigus foliaceus in feline patients. *Vet Focus* 2018;28.1:15-19.
19. Mason K. Mosquito-bite Hypersensitivity. In: Noli C, Colombo S (eds.) *Feline Dermatology*. 1<sup>st</sup> ed. Switzerland AG Springer Nature, 2020;489-494.
20. Goldfinch N, Argyle D. Feline lung-digit syndrome: unusual metastatic patterns of primary lung tumors in cats. *J Feline Med Surg* 2012;14:202-208.
21. Sugiyama H, Maruo T, Shida T, et al. Clinical findings in lung-digit syndrome in five cats. *J Jpn Vet Cancer Soc* 2010;1(1):8-13.
22. Thrift E, Greenwell C, Turner AL, et al. Metastatic pulmonary carcinomas in cats ("feline lung-digit syndrome"): further variations on a theme. *J Feline Med Surg open rep* 2017;1-8.
23. van der Limde-Sipman JS, van den Ingh TS. Primary and metastatic carcinomas in the digits of cats. *Vet Q* 2010;3:141-145.
24. Wobeser BK, Kidney BA, Powers BE, et al. Diagnoses and clinical outcomes associated with surgically amputated feline digits submitted to multiple veterinary diagnostic laboratories. *Vet Pathol* 2007;44:362-365.

# DISEASES OF THE FELINE NASAL PLANUM



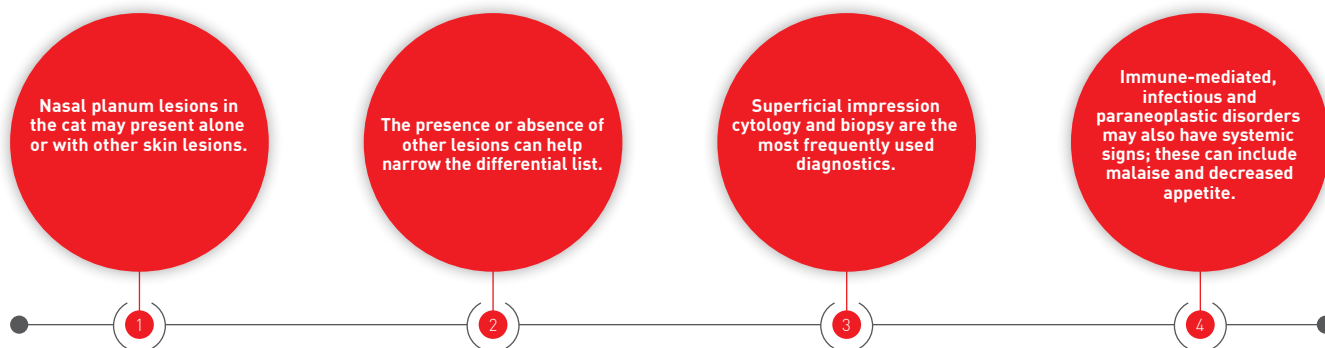
## Christina M. Gentry,

DVM, Dip. ACVD, Gulf Coast Veterinary Specialists, Houston, TX, USA

Dr. Gentry undertook both her undergraduate study and Doctor of Veterinary Medicine at Texas A&M University and went on to complete a small animal rotating internship at the University of Georgia before doing her dermatology residency at the Veterinary Referral Center of Colorado. She achieved her dermatology diplomate status in 2016 and currently works in a private referral practice in Texas. She has a special interest in feline dermatology, otitis, and immune-mediated skin diseases.

Skin lesions on a cat's nose can be challenging in terms of differential diagnosis and treatment; Christina Gentry shows how to approach them in a logical fashion.

## KEY POINTS



## Introduction

Diseases of the nose and the bridge of the nose are uncommon to rare in feline patients. Some conditions will affect both the non-haired area (nasal planum and nasal philtrum) and the haired bridge of the nose, while others will affect only the nasal planum. A variety of conditions may lead to lesions on the nose, including neoplastic, parasitic, immune-mediated, infectious, genetic, environmental and idiopathic causes. Diseases affecting the nasal planum may also involve both the surrounding skin and distant sites. The goal of this article is to briefly review the pathogenesis, diagnostics, treatment options and prognosis for conditions that the practitioner is likely to encounter, based on the underlying etiology.

## Neoplastic and paraneoplastic

### Squamous cell carcinoma

Squamous cell carcinomas (SCC) are a common occurrence in the cat, accounting for around 15% of all feline cutaneous neoplasms (1). Most cutaneous SCC are found on the face, especially the minimally haired tips of the ears, bridge of the nose, eyelids, and non-haired nasal planum (**Figure 1**). The pathogenesis involves chronic exposure to UV radiation, with white or light-colored cats being at an increased risk due to the higher amount of UVB light reaching the skin surface (2). The initial lesions that develop – which may at first resemble a non-healing scratch or other trauma (3) – are actinic keratosis (pre-cancerous lesions of chronic sun exposure), then squamous cell carcinoma *in situ*, followed by squamous cell carcinoma.



**Figure 1.** A 10-year-old female spayed DSH barn cat with a one-year history of a lesion on the left bridge of nose and nasal planum. Squamous cell carcinoma was diagnosed on biopsy (**a,b**).

A combination of lesions may be present at the same time, but typically they are inflamed with crusts overlying erythematous, alopecic, and eroded skin [3], varying in size from a few millimeters to a few centimeters in diameter. Affected areas may be depressed and the crusts can be hemorrhagic, with papillary or fungiform masses sometimes present in more advanced cases.

Diagnosis is typically made by biopsy or excision. A punch biopsy method (see **Box 1**) can be used for the nasal planum, while a margin/shave biopsy may be more useful on the ear tips. Since the lesions affect the epidermis, a fine-needle aspirate may not be as helpful for diagnosis for smaller lesions. The histopathology of a well-differentiated SCC will have trabeculae and islands of epidermal cells that dive into the dermis. These lesions have more basal-appearing keratinocytes on the periphery, with gradual differentiation to keratinized epidermal cells in the center of the lesions. These epidermal

cells form keratin "pearls" that can be found in the center of the neoplastic epidermal islands [3].

Squamous cell carcinomas of the face have a low metastatic rate [4] and most therapy is directed at individual lesions. Staging may be recommended prior to treatment, including blood work, local lymph node aspirates and chest radiographs. Treatment options for facial SCC include surgery, radiation therapy, and intralésional chemotherapy. Surgical excision is recommended for most SCC affecting the face [4], although surgical removal of larger tumors on the nasal planum may lead to disfigurement. In these cases radiation therapy is recommended; this includes the use of strontium-90 brachytherapy for tumors that are 3 mm deep or less, and teletherapy for deeper lesions [5]. Smaller lesions that can be completely removed tend to have the best outcome, and radiation therapy on smaller lesions can significantly increase the disease-free interval by months to years [5]. More invasive lesions have a faster recurrence rate.

**Box 1.** Technique for biopsy of the nasal planum.

- Heavy sedation or anesthesia is recommended for nasal planum biopsy.
- Do not attempt to scrub or clean biopsy site, as the crusts can be diagnostic.
- 4 mm punch biopsy typically provides an adequate sample.
- Sample any other affected areas of skin to improve diagnostic results.
- Include a detailed history, physical examination findings, and photographs with the biopsy samples on submission to a laboratory.

## Paraneoplastic lesions

Paraneoplastic alopecia is a rare syndrome reported primarily in the cat. The underlying pathogenesis is not fully understood, but almost all cases are secondary to malignant neoplasia of the pancreas, intestines, liver, or biliary tract [6]. General clinical signs will include malaise, weight loss and decreased appetite in a previously healthy older feline. Cutaneous signs can be striking and include a rapid loss of easily epilating hair on the belly with progression to hair loss on limbs and face. The underlying skin is smooth, occasionally

with a brown discharge from a secondary *Malassezia* dermatitis [7]. The paw pads and nasal planum are shiny and smooth, whilst the bridge of the nose may be alopecic.

The outcome is generally poor, as metastases to lymph nodes, liver, and lungs have typically occurred before alopecia and loss of normal layering on the nasal planum is seen [6,7]. Palliative care or euthanasia is recommended for most cases if surgical intervention is unlikely to be curative.

## ●●● Hypersensitivity



Mosquito bite hypersensitivity is especially common in outdoor, darker-coated cats during the warmer months in certain warmer climates such as the southern United States and the Mediterranean countries. Indoor-only cats are rarely affected. This is considered to be a Type 1 hypersensitivity, although it also has features of a Type 4 hypersensitivity. Some affected cats may start to show wheal formation within 20 minutes of being bitten [8]. Miliary dermatitis and occasionally eosinophilic granulomas are seen on the bridge of the nose, ear tips, and foot pads (**Figure 2**). These lesions may progress to larger crusts, erosions, and excoriations from pruritus. The lesions may extend into the nasal planum from the bridge of the nose in more severely affected cats, and there may be regional lymphadenopathy [8,9].

This condition is often diagnosed based on history and physical examination. A biopsy can be considered in more severe cases where there is concern for pemphigus foliaceus or herpes virus dermatitis. Superficial cytology is recommended to check for secondary bacterial infection; in non-infected cases, this will often predominately demonstrate eosinophils, with other cell types

being less common. Histopathology of mosquito bite hypersensitivity typically reveals a marked eosinophilic inflammation with overlying crusts and serum exudate. It may be difficult to differentiate from other eosinophilic skin disease in the cat or from herpes virus dermatitis if viral inclusion bodies are not seen [9].

Successful treatment requires therapy for the acute inflammation and secondary infection (if present), along with decreasing or eliminating the number of mosquito bites. Oral or injectable short-acting steroids at mid to high anti-inflammatory doses (1-2 mg/kg daily) are most likely to be effective at controlling the inflammation [8]. Therapy may only be needed for 2-4 weeks if further bites can then be avoided, but treatment can be continued during the peak mosquito season if environmental changes cannot be made (e.g., in barn/farm cats).

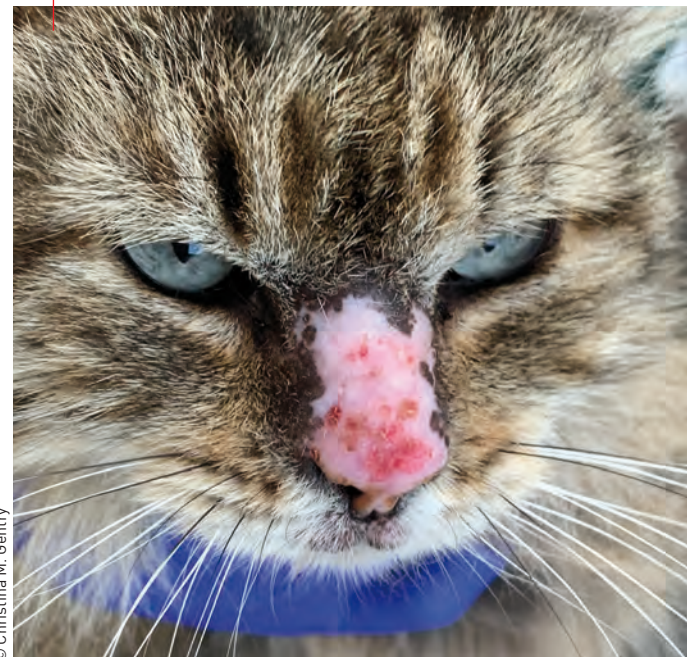Avoidance is the best strategy. This may include keeping the cat indoors during peak mosquito hours and seasons, eradicating stagnant water sources where mosquito larvae may be present, removing shrubs and tall grass near water sources, and using environmental repellents [8]. Topical repellents can be applied if cats cannot be kept indoors, but they can have variable efficacy and should be applied daily whenever possible. Permethrin products (formulated for cats),

**Figure 2.** A 13-year-old female spayed DLH outdoor-only cat with mosquito bite hypersensitivity, demonstrating seasonal alopecia, crusting and erosion of the nasal planum and bridge of the nose.

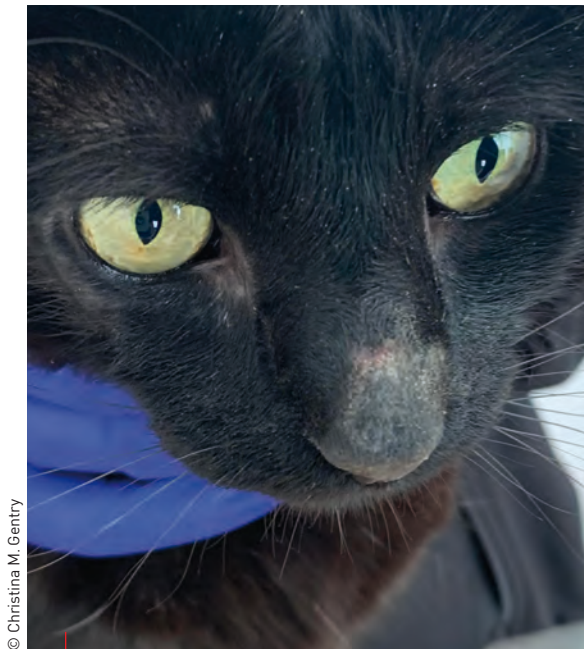


**“Squamous cell carcinomas are a common occurrence in the cat, accounting for 15% of all feline skin tumors, with most of them occurring on the face, especially the minimally haired tips of the ears, bridge of the nose, eyelids, and non-haired nasal planum.”**

Christina M. Gentry

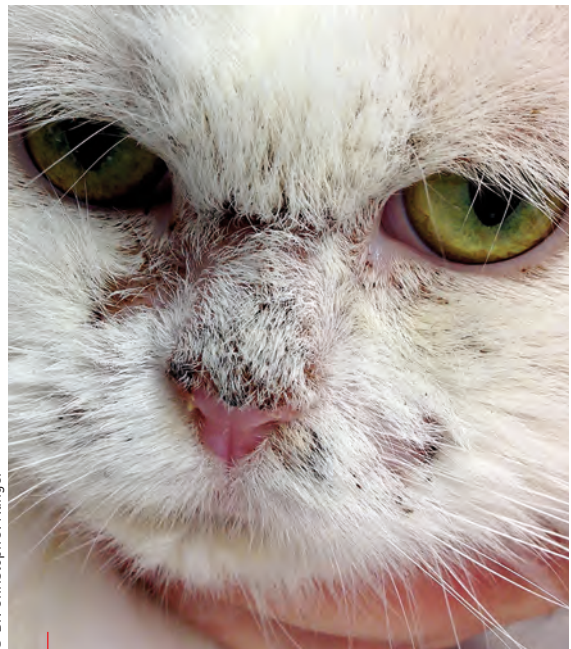

© Christina M. Gentry



© Christina M. Gentry

**Figure 3.** A 5-year-old male neuter DSH cat with pemphigus foliaceus involving the pinna, bridge of nose, and nasal planum; note the thin yellow crusts and hypotrichosis in affected areas.



© Dr. Christoph J. Klingner

**Figure 4.** A DSH cat with nasal erythema, crusting and hair loss. The diagnosis was pemphigus foliaceus.

citronella, neem oil, or essential oil of the catnip plant can also be used, although the risk of toxicity should be considered (8). In the author's anecdotal experience picaridin-containing preparations can be effective for several hours when applied on the cat's dorsum and ear tips.

Prognosis is excellent for cats that can be housed indoors, but is still fair to good for patients where significant environmental management is not possible.

## ●●● Immune-mediated

Pemphigus foliaceus (PF) is the most common cutaneous immune-mediated disease in the cat (10), although overall it is uncommon in the feline population. Pemphigus foliaceus affects the desmosomal junctions between the more superficial epidermal cells. This attack leads to separation of superficial epidermal cells prior to full maturation as anucleated keratinocytes. Most cases are idiopathic, with a smaller proportion being triggered by certain drugs (11). Typically affected cats are middle aged, but cats of any age, including kittens, can develop the condition.

PF lesions are more commonly seen on the concave surface of the pinna, face, bridge of nose and nasal planum (**Figure 3**); nasal planum lesions are seen in up to 50% of cats (**Figure 4**) (11,12). Affected animals may also have lesions surrounding the mammary papilla, the footpads, nail beds and haired skin (11). Some cats have facially centered lesions, some will only have paw and nail bed involvement, while others have lesions in multiple body areas. The primary lesions consist of yellow pustules that span multiple hair follicles which then

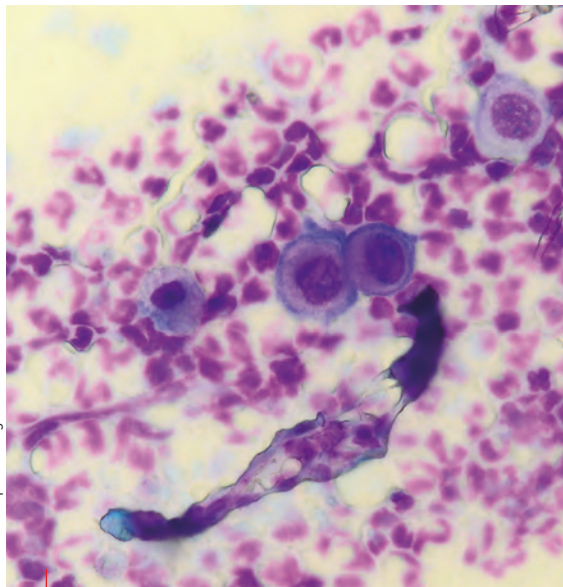
progress into annular yellow crusts, possibly with underlying erosion. Loss of the normal cobblestone appearance can be seen in the affected nasal planum and footpads, and nail beds may have thick yellow, or occasionally green, purulent discharge exuding from the claw folds. Pruritus is variable with PF; significant self-trauma may alter the appearance of lesions, especially on the face and ears, and affected cats may develop fever, malaise and a decreased appetite.

Initial diagnostics should include impression cytology of lesions, either by rupturing a pustule or lifting of a crust. Cytology will show mainly non-degenerate neutrophils and variable number of acantholytic keratinocytes; these are rounded nucleated keratinocytes that have lost desmosome junctions and appear blue with routine staining. Dermatophyte test medium (DTM) cultures, Wood's lamp examination and skin scraping may be recommended to rule out dermatophytosis and ectoparasites (*i.e.*, *Demodex* spp. and *Notoedres cati*). Baseline blood work may demonstrate a leukocytosis and hyperglobulinemia (13).

A biopsy is recommended for definitive diagnosis, but because the diagnostic lesions (*i.e.*, neutrophilic pustules with acantholytic keratinocytes) are superficial in nature, biopsy sites should not be clipped, shaved or scrubbed, as the diagnostic sample may be lost. Histopathology will reveal neutrophilic crusting; epidermal and superficial dermal infiltrate will be predominately neutrophilic, or mixed neutrophilic and eosinophilic (14). The pustules may have predominately neutrophilic or eosinophilic infiltrate with acantholytic keratinocytes, either alone or in rafts, and the hair follicles may also be affected (**Figure 5**) (14).

Corticosteroids are the primary treatment option, with monotherapy being successful in many cats. Induction doses of prednisolone at 2-6 mg/kg PO per day have been used, with 2-3 mg/kg per day being sufficient in most patients [12]. Oral therapy is preferred and likely more effective compared with injectable long-acting steroids, although exceptions can be made for patients that are difficult to medicate. Remission is typically achieved in 2-8 weeks, although the majority of patients will require lifelong therapy. Once remission occurs, steroid dosage is tapered by approximately 25% every 2-3 weeks until the patient is either fully off steroids or begins to flare again.

Adjunctive immune modulators should be considered due to the long-term nature of feline PF and the potential for steroid-adverse events, such as weight gain, risk of diabetes development, and increased risk of viral upper respiratory infections. Modified cyclosporine, either in liquid or capsule form, at 5-7 mg/kg per day can be used to reduce (and in certain cases eliminate) corticosteroid requirements. The dosage can be tapered to 2-3 days per week in some cases [15]. Chlorambucil can be considered for cases that are refractory to modified cyclosporine, if the patient has significant gastrointestinal side effects from the drug, or there is a concern for long-term steroid-adverse events [15]. Azathioprine is not recommended in cats due to the potential for bone marrow suppression [15]. The outcome for most cats is good if they tolerate oral medications well and do not develop steroid-related adverse events [11].



© Dr. Christoph J. Klinger

**Figure 5.** Cytology in feline pemphigus foliaceus; note the rounded (acantholytic) keratinocytes in small clusters (like “fried eggs”) surrounded by neutrophils.



**“Pemphigus foliaceus lesions are more commonly seen on the concave surface of the pinna, face, bridge of nose and – in up to 50% of cats – the nasal planum; affected animals may also have lesions surrounding the mammary papilla, the footpads, nail beds and haired skin.”**

Christina M. Gentry

## ●●● Infectious

### FHV-1

Feline herpesvirus dermatitis is an uncommon manifestation of feline herpesvirus-1 (FHV-1) infection. This virus is a common pathogen that affects the upper respiratory tract, frequently causing self-limiting rhinotracheitis and conjunctivitis. In the majority of cats respiratory signs resolve but the virus remains latent within the trigeminal ganglia [16]. Cats that develop skin lesions may have a history of upper respiratory infection, corticosteroid use, or stressors prior to the development of lesions, with adult cats being affected more often than kittens. The cutaneous lesions are vesicles, erosions and ulceration of the face with overlying crusts. The bridge of the nose, nasal planum, muzzle, and periorcular region may be affected, but body-wide ulcerations can develop [17].

Suspicion of this condition may be raised based on history and physical examination, especially if concurrent upper respiratory signs are present. Biopsy is strongly recommended for definitive diagnosis. FHV-1 can appear similar to mosquito bite dermatitis, pemphigus foliaceus, eosinophilic granulomas, and erythema multiforme depending on the level of crusting and self-trauma. Histopathology reveals necrosis of the epidermis which can extend into the dermis. There is considerable exudate and crusting, with a significant eosinophilic infiltrate being found more commonly than a neutrophilic infiltrate [9]. The presence of intranuclear inclusion bodies in keratinocytes or giant cells is diagnostic, but will not be detected in all cases. PCR of the affected tissue or immunohistochemistry may be needed if inclusion bodies are not found in the sample. A recent study has demonstrated reliability in using RNA scope *in situ* hybridization to diagnose FHV-1 on formalin-fixed paraffin-embedded tissues [18].

Note that viral PCR of respiratory or ocular lesions cannot confirm or exclude cutaneous herpes virus, although it may help in diagnosing the cause of a concurrent upper respiratory disease.

Treatment depends on the severity of the condition; oral and topical antivirals, interferon omega, and imiquimod have all been recommended [16,19]. If an affected cat is being treated with corticosteroids these should be discontinued wherever possible.

## Sporotrichosis

This is the clinical disease caused by infection with the dimorphic fungus *Sporotrix schenckii*. This environmental organism is found in organic matter and soil and the fungal conidia are traumatically inoculated via plant matter or by animal (mainly cat) scratches or bites. This condition is endemic in central and South America – with an epidemic in Brazil over the last 20 years [20] – and is occasionally seen in North America [20,21]. Importantly, this disease is zoonotic, with the most common route of transmission being cat bites or scratches to their human caretakers [20].

In cats the cutaneous and cutaneous-lymphatic form are more common. The face and head are commonly involved, with lesions on the bridge of the nose extending into the nasal planum [21]. Cutaneous lymphatic progression to the disseminated form is less common.

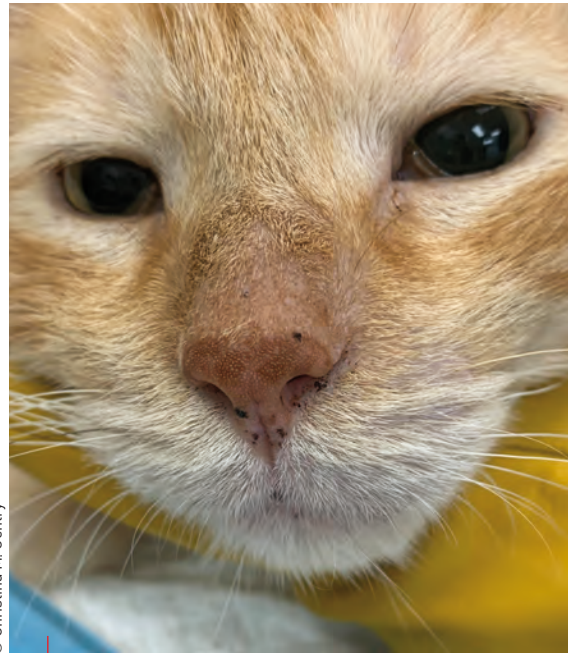A retrospective evaluation of 23 cases noted that almost all infected cats had outdoor access, and most cats were previously systemically healthy, although a small proportion were found to have co-morbidities, including retroviral infection at the time of diagnosis [21].

Infection may be diagnosed by fine-needle aspirate and cytology, fungal culture and histopathology [22]. Treatment with the azole antifungals (most commonly itraconazole) is typically successful, although sodium or potassium iodide have also been used [22]. Therapy is typically continued for several months, and for at least 1-2 months after resolution of clinical signs. The prognosis is good for the cutaneous and cutaneous lymphatic forms, but may be less favorable for systemic cases.

## Idiopathic

Idiopathic nasal dermatitis is an uncommon disorder of unknown etiology and pathogenesis that has been reported to occur on the nasal planum of Bengal cats. Affected animals are typically less than one year of age, and only the nasal planum is affected by crusting, fissures, and ulceration. One study reviewed 48 cases and reported that the affected cats had no other cutaneous lesions and were otherwise unaffected [23]. The condition is typically diagnosed by history and physical examination.

Several treatments, including oral prednisolone, topical salicylic acid and tacrolimus have been employed. Prednisolone tablets and salicylic acid cream were reported to be variably successful,



© Christina M. Gentry

**Figure 6.** A 5-year-old male neuter DSH cat with small lentiginos on the nasal planum, nasal philtrum, and lip margins. The lesions are flat without any erythema or erosion.

while topical tacrolimus was most likely to lead to a clinical remission [23], although some cats will improve spontaneously. Prognosis is good to excellent, since most affected cats will respond to therapy.

## Pigmentary disorders

### Lentigo simplex

This is an uncommon condition that occurs mainly in adult orange-colored cats. It appears as black lesions (asymptomatic macular melanosis) most commonly on the lips, although the nose, gingiva and eyelids can also be affected [24]. The lesions are typically flat, annular to ovoid and are less than 1 cm in diameter (**Figure 6**). The skin is deeply pigmented but not irregular, and whilst the pigmented areas may slowly enlarge over time (**Figure 7**) they do not progress to plaques or masses [24]. Diagnosis is typically made on physical examination, but a biopsy can be performed if there is concern for melanoma; histopathology will show marked melanosis, especially in the deepest layers of epithelium. As this is a cosmetic condition no treatment is indicated.

### Vitiligo

Vitiligo occurs when the majority of melanocytes (pigment-producing cells) are destroyed within an area of skin, and is rarely seen in the cat. The cause is multifactorial and may involve genetic susceptibility, immune-mediated destruction, and oxidative damage. Signs include symmetric depigmentation of both non-haired areas of skin (leukoderma) and haired skin (leukotrichia). In cats the pigment loss can be seen around the eyes, on





© Rachel Rodriguez

**Figure 7.** A 17-year-old male neuter DMH cat with larger coalescing lentiginos of the nasal planum and nasal philtrum.

the nose, lip margins, foot pads, and extremities. Other body regions are affected less commonly. There will be no inflammation, erosion or crusting in affected areas [25]. The literature references are limited to Siamese cats, most of which were female and young adult to middle age at diagnosis [25]. The diagnosis may be made on physical examination in a young adult Siamese cat presented for pigment loss without inflammation or crusting. Biopsy is recommended in cats that do not fit this profile or to rule out diseases such as cutaneous epitheliotropic lymphoma, a nutritional deficiency, or early discoid lupus erythematosus.

Vitiligo is considered a cosmetic disease in the cat, but the loss of pigment around eyelids and nose may predispose an otherwise pigmented cat to actinic keratosis and potentially squamous cell carcinoma. Treatment is not recommended.



## CONCLUSION

External nasal lesions in the cat are relatively rare but the clinician should approach these with the same care and logic as when investigating other dermatological conditions, remembering that the external nasal signs may be part of a more widespread problem. The lesions may be differentiated by a thorough history and physical examination, cytology, and potentially biopsy, but discussion with a veterinary dermatologist can be helpful for assistance with the more difficult or complicated cases.



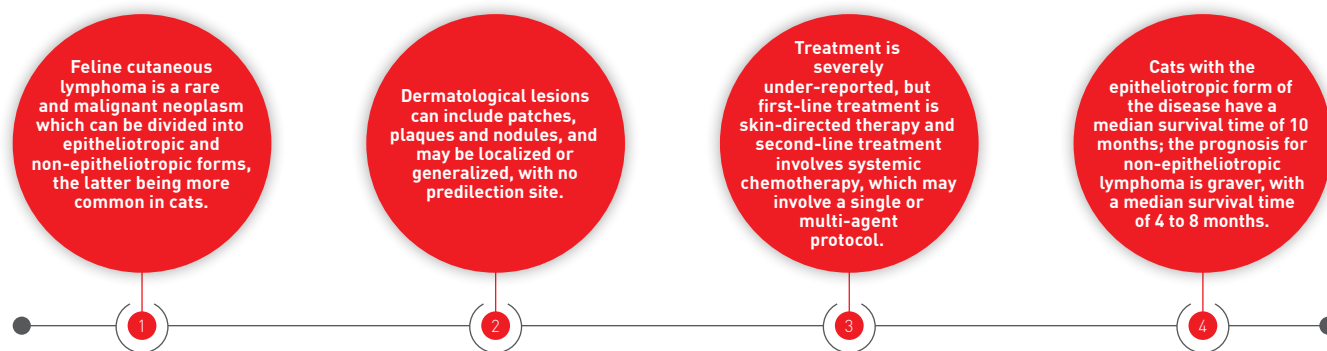
## REFERENCES

- Murphy S. Cutaneous squamous cell carcinoma in the cat: current understanding and treatment approaches. *J Feline Med Surg* 2013;15(5):401-407.
- Dorn CR, Taylor DO, Schneider R. Sunlight exposure and risk of developing cutaneous and oral squamous cell carcinomas in white cats. *J Natl Cancer Inst* 1971;46:1073-1078.
- Gross TL, Ihrke PJ, Walder EJ, et al. Epidermal tumors. In: *Skin diseases of the dog and cat, clinical and histopathologic diagnosis*. 2<sup>nd</sup> ed. Oxford, Blackwell Science Ltd 2005;562-600.
- Hauck ML. Tumors of the skin and subcutaneous tissues. In: Vail DM, Withrow SJ [eds.] *Withrow and MacEwen's Small Animal Clinical Oncology*. St Louis, Elsevier Saunders 2013;305-320.
- Hammond GM, Gordon IK, Theon AP, et al. Evaluation of strontium Sr90 for the treatment of superficial squamous cell carcinoma of the nasal planum in cats: 49 cases (1990-2006). *J Am Vet Med Assoc* 2007;231(5):736-741.
- Miller WH, Griffin CE, Campbell, KL. Miscellaneous Alopecias. In: *Small Animal Dermatology 7<sup>th</sup> Ed*. St. Louis, Elsevier Mosby 2013;554-572.
- Caporali C, Albanese F, Binanti D, et al. Two cases of feline paraneoplastic alopecia associated with a neuroendocrine pancreatic neoplasia and a hepatosplenic plasma cell tumour. *Vet Dermatol* 2016;27(6):508-e137.
- Nagata M. Mosquito Bites. In: Noli C, Foster A, and Rosenkrantz W [eds.] *Veterinary Allergy*. 1<sup>st</sup> ed. Oxford, John Wiley and Sons Ltd 2014;265-270.
- Gross TL, Ihrke PJ, Walder EJ, et al. Ulcerative and crusting diseases of the epidermis. In: *Skin diseases of the dog and cat, clinical and histopathologic diagnosis*. 2<sup>nd</sup> ed. Oxford, Blackwell Science Ltd, 2005;116-135.
- Scott DW, Miller WH, Erb HN. Feline dermatology at Cornell University: 1407 cases (1988-2003). *J Feline Med Surg* 2013; 15(4):307-316.
- Bizikova P, Burrows A. Feline pemphigus foliaceus: original case series and a comprehensive literature review. *BMC Vet Res* 2019;15(1):22.
- Simpson DL, Burton GG. Use of prednisolone as monotherapy in the treatment of feline pemphigus foliaceus: a retrospective study of 37 cats. *Vet Dermatol* 2013;24(6):598-e144.
- Jordan TJM, Affolter VK, Outerbridge CA, et al. Clinicopathological findings and clinical outcomes in 49 cases of feline pemphigus foliaceus examined in Northern California, USA (1987-2017). *Vet Dermatol* 2019;30(3):209-e65.
- Gross TL, Ihrke PJ, Walder EJ, et al. Pustular diseases of the epidermis. In: *Skin diseases of the dog and cat, clinical and histopathologic diagnosis*. 2<sup>nd</sup> ed. Oxford, Blackwell Science Ltd 2005;4-26.
- Irwin KE, Beale KM, Fadok VA. Use of modified ciclosporin in the management of feline pemphigus foliaceus: a retrospective analysis. *Vet Dermatol* 2012;23(5):403-e76.
- Miller WH, Griffin CE, Campbell, KL. Viral, Rickettsial, and Protozoal Skin Diseases. In: *Small Animal Dermatology 7<sup>th</sup> Ed*. St. Louis, Elsevier Mosby 2013;343-362.
- Hargis AM, Ginn PE. Feline herpesvirus 1-associated facial and nasal dermatitis and stomatitis in domestic cats. *Vet Clin North Am Small Anim Pract* 1999;29(6):1281-1290.
- Mazzei M, Vascellari M, Zanardello C, et al. Quantitative real time polymerase chain reaction (qRT-PCR) and RNAscope *in-situ* hybridization (RNA-ISH) as effective tools to diagnose feline herpesvirus-1-associated dermatitis. *Vet Dermatol* 2019;30(6):491-e147.
- Gutzwiller ME, Brachelente C, Taglinger K, et al. Feline herpes dermatitis treated with interferon omega. *Vet Dermatol* 2007; 18(1):50-54.
- Gremião ID, Miranda LH, Reis EG, et al. Zoonotic epidemic of Sporotrichosis: cat to human transmission. *PLOS Pathog* 2017;13(1):e1006077.
- Crothers SL, White SD, Ihrke PJ, et al. Sporotrichosis: a retrospective evaluation of 23 cases seen in northern California (1987-2007). *Vet Dermatol* 2009;20(4):249-259.
- Lloret A, Hartmann K, Pennisi MG, et al. Sporotrichosis in cats: ABCD guidelines on prevention and management. *J Feline Med Surg* 2013;15(7):619-623.
- Bergvall K. A novel ulcerative nasal dermatitis of Bengal cats. *Vet Dermatol* 2004;15:28.
- Miller WH, Griffin CE, Campbell, KL. Pigmentary Abnormalities. In: *Small Animal Dermatology 7<sup>th</sup> Ed*. St. Louis, Elsevier Mosby, 2013;618-629.
- Tham HL, Linder KE, Olivry T. Autoimmune diseases affecting skin melanocytes in dogs, cats and horses: vitiligo and the uveodermatological syndrome: a comprehensive review. *BMC Vet Res* 2019;15(1):251.

# FELINE CUTANEOUS LYMPHOMA

Cutaneous lymphoma in the cat is a rare but life-threatening neoplasm that warrants inclusion in the differential diagnosis list of many dermatology cases; this paper reviews the current knowledge of the condition and the options for treatment.

## KEY POINTS



## Introduction

Lymphoma is the most diagnosed neoplasm in the cat, representing around 50% of all tumors seen in the species. From this overall percentage cutaneous lymphoma accounts for 0.2-3.0% of cases, highlighting the fact that it is a rare but malignant neoplasm (1). To date only a handful of reports on feline cutaneous lymphoma cases have been published, whereas in dogs and people it is a well-recognized and documented disease (2,3).

As per the classification system used in human medicine, cutaneous lymphoma is separated into two main types: epitheliotropic and non-epitheliotropic. The classification indicates if the epidermis, dermis and adnexa have been infiltrated with neoplastic lymphocytes (epitheliotropic) versus just the dermis and subcutis (non-epitheliotropic) (4) – although to be more exact, feline cutaneous epitheliotropic lymphoma (CETL) does not involve the adnexal glands (2).

Cutaneous epitheliotropic lymphoma is a subset of cutaneous T-cell lymphoma (CTCL) and is further divided into mycosis fungoides, Sézary syndrome (a leukemic variant) and pagetoid reticulosis (2-4); in cats this latter condition has yet to be described (2). Cutaneous non-epitheliotropic lymphoma (CNEL) is the more common condition in cats and includes indolent T-cell lymphoma (or cutaneous lymphocytosis), diffuse T-cell lymphoma, T-cell-rich large B-cell lymphoma, and lymphoplasmacytic

lymphoma (1). In more recent years there has been acknowledgement of feline CNEL subgroups: cutaneous lymphoma at injection sites, tarsal lymphoma, and CNEL associated with a fracture site. They all lack epitheliotropism, hence their subgrouping, but clinical and pathological features discern them as unique disease entities (1,5,6). In dogs and humans CETL is the more common condition and has consequently influenced research in the cat (1).

## Etiology and predisposing factors

In general, cutaneous lymphoma affects older cats (with a median age of onset at 10 years) and there are no apparent breed or sex predispositions (3,7). As a corollary to the rarity of feline cutaneous lymphoma, the etiology is still not well understood (3,7). For more common feline lymphomas (e.g., mediastinal and multicentric) there is an evident association between viruses (e.g., feline leukemia virus [FeLV] and feline immunodeficiency virus [FIV]) and lymphoma, but such a relationship has not been established for feline cutaneous lymphoma (1-3,8). However, one study (9) employed a PCR technique to highlight integrated FeLV provirus in tumor DNA from a cat with CNEL. This finding, along with other suggestions in the field, does not conclusively exclude FeLV and/or other feline viruses as possible causes (3), and advanced molecular diagnostics may be required to definitively identify any link (9).



## Hannah Lipscomb,

BVet Med, MRCVS, Greater Manchester, UK

Dr. Lipscomb gained her degree from London's Royal Veterinary College in 2016 and was the first dermatology intern at Southern Counties Veterinary Specialists (SCVS), working alongside the specialist Filippo De Bellis. After qualification she initially worked in a first opinion small animal practice for 18 months – where she developed her interest in dermatology – and then progressed to a rotating internship at a private referral clinic before moving to SCVS to undertake a dermatology internship.



## Filippo De Bellis,

DVM, CertVD, Dip. ECVD, MRCVS, Davies Veterinary Specialists, Hertfordshire, UK

Dr. De Bellis qualified from the University of Bari, Italy in 2001 and moved to the UK to undertake a dermatology residency at the Royal Veterinary College in 2006. He gained the RCVS Certificate in Veterinary Dermatology in 2009 and a year later became a Diplomate of the European College of Veterinary Dermatology. He has a particular interest in ear diseases and allergies, and is currently Head of Dermatology Services at Davies Veterinary Specialists, Southfields Veterinary Specialists and London Vet Specialists.

Other contributory factors have also been proposed. Whilst there is limited information available for the extremely rare dermatopathy follicular mucinosis (a presumed immune-mediated disease), two cats have been described with the disease which both subsequently developed CETL (7,10). Although it is not possible to confirm the evolution of follicular mucinosis to CETL, follicular mucinosis in cats may be a predisposing factor or an indicator of more severe disease to come. Furthermore, pre-existing chronic dermatitis in dogs and people with CTCL has been researched as a possible predisposing factor to skin cancer, although (in dogs, people and cats) transformation of inflammatory skin disease (e.g., atopic dermatitis) to neoplasia of the integument has not been proven (3).

Predisposing factors for feline CNEL have also been evaluated: a study of 17 cats with CNEL at injection sites was linked to a case report of a cat with fracture site associated CNEL. The study and case report were linked as both authors proposed chronic inflammation (post injection and fracture respectively) to be a possible cause for malignant transformation (1,5). Chronic inflammation is well documented in humans as a potential nidus for B-cell lymphoma, and other applicable nidus examples include surgery, trauma, metallic implants and viral infections (1).

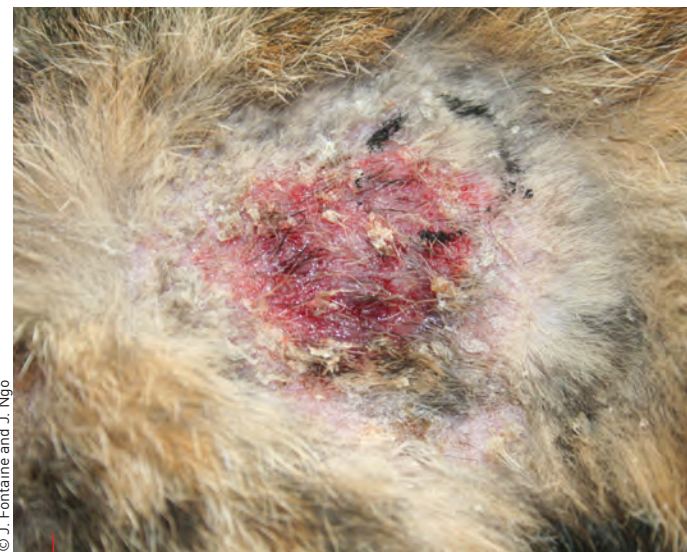### ●●● Clinical presentation and diagnosis

#### Cutaneous epitheliotropic lymphoma

Most reported cases of feline CETL are the mycosis fungoides form (3). When the neoplasm occurs, it has a slow progression and at the time of presentation there may be no significant systemic signs and/or abnormalities on routine

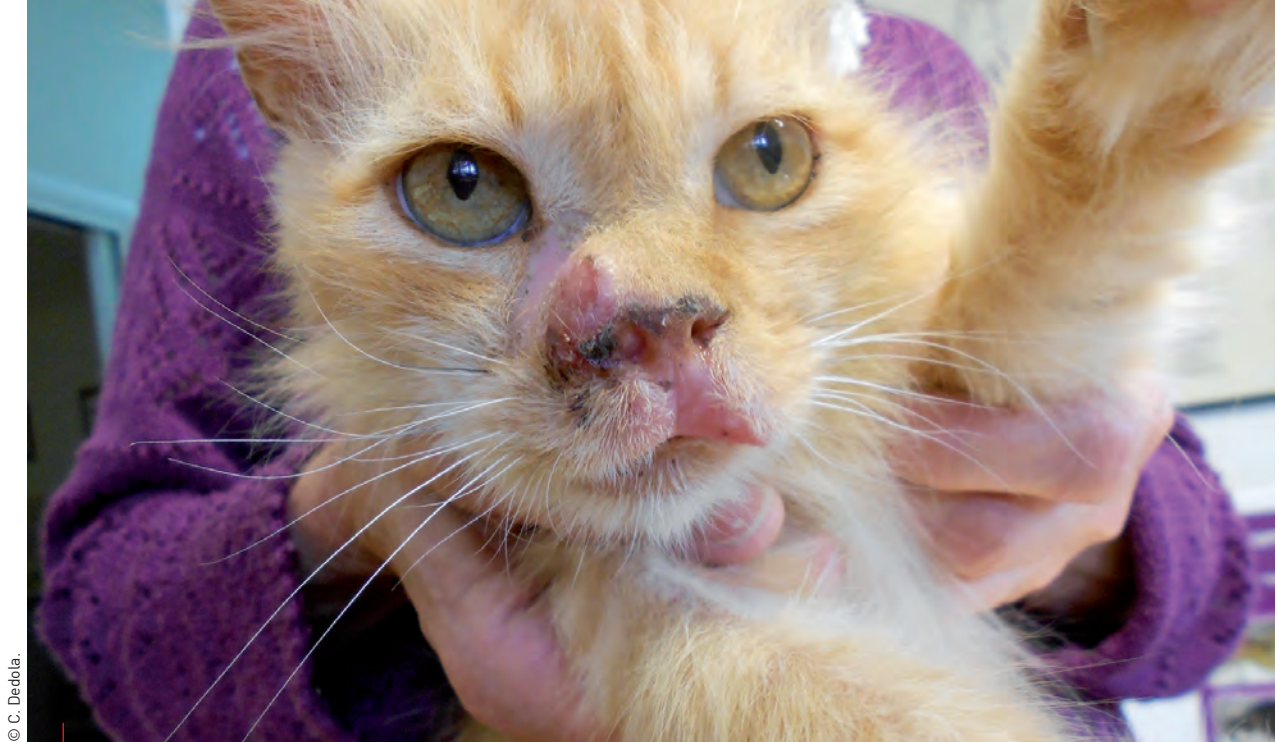hematology and biochemistry (3,11). Moreover, cats with Sézary syndrome typically present with intense pruritus and lymphadenomegaly, and on cytology have circulating neoplastic lymphocytes (leukemia) (2,11).

Dermatological examination may identify lesions which can be localized or generalized, arising anywhere on the body. Skin lesions include exfoliative erythroderma, patches, plaques, erosions and ulcers (**Figure 1**), and lesions at mucocutaneous junctions (**Figure 2**) and in the oral cavity (**Figure 3**) (3,12). As a result, skin lesions are comparable in appearance to those



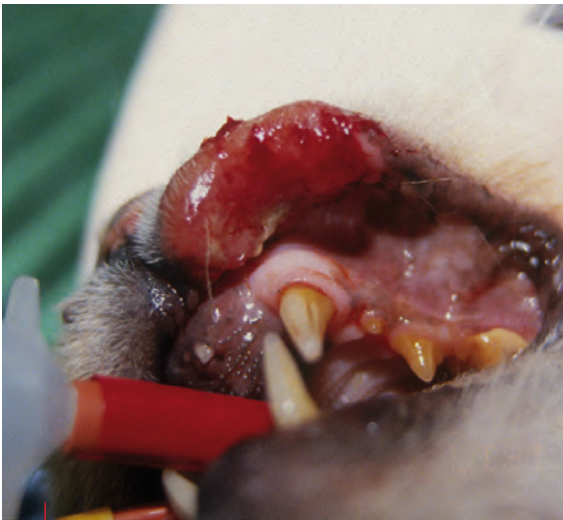© J. Fontaine and J. Ngo

**Figure 1.** A cat with CETL showing alopecia, scaling and crusting centered around an erythematous and eroded plaque. The peripheral skin is erythematous and scaly.



© C. Dardola.

**Figure 2.** Depigmentation of the philtrum and right medial canthus and nasal planum in a cat with CETL; a raised, eroded plaque-like lesion is affecting the same areas and extends to the left maxillary lip fold, right nostril and dorsal muzzle. The nasal planum is crusted.



© N. Rich

**Figure 3.** An ulcerated, hemorrhagic mass-like lesion on the most rostral part of the mucocutaneous junction of the left maxillary lip fold caused by CETL.

caused by parasites (e.g., *Demodex* spp.), infection (e.g., dermatophyte species) and allergic skin disease (e.g., eosinophilic granuloma complex) (7,12). However, one case report noted a cat with feline CETL where the clinical summary was remarkably different, with acute onset of nodular lesions starting on the tail (13). This further complicates the list of differential diagnoses, as clinically CETL seems to have an unpredictable manifestation.

Diagnosis is based on histopathology. For a definitive diagnosis, small-to-medium or medium-to-large lymphocytes with tropism for the epidermis must be identified (12), but the pathologist may also variably describe Pautrier's microabscessation, spongiosis and apoptosis of keratinocytes, a mixed inflammatory reaction and orthokeratosis and parakeratosis of the epidermis (3). Histopathology alone does not reveal any specific features clearly distinguishing mycosis fungoides from Sézary syndrome (7,11).

It is widely accepted that CETL is nearly always T-cell in origin, but beyond that little research exists for the more precise immunophenotype and immunopathology of feline CETL. Some pathologists believe that the immunophenotype of feline CETL most closely resembles mycosis fungoides in people, as the T-cells involved are thought to be helper T-cells (CD4 cells) (3). However, this has been challenged by the identification of perforin in neoplastic T-cells from a cat with CETL. Perforin is a pore-forming protein stored in the cytoplasmic granules of cytotoxic T-cells (CD8 cells) and has a role in targeted cellular killing. Unfortunately, in this case CD8 expression was not reviewed, but by comparison to relevant human studies it was suggested that the T-cells were most likely CD8 cells (13). Essentially more work is required to elucidate the immunophenotype of feline CETL.

### Cutaneous non-epitheliotropic lymphoma

Clinically, CNEL presents as non-pruritic solitary or multifocal plaques and/or nodules that are often ulcerated (**Figure 4 and 5**); erythema, crusting and scaling occur sporadically (**Figure 6**) (2,14). There are no listed predilection sites but a literature

search suggests lesions can develop on peripheral areas, at common injection sites (cutaneous lymphoma at injection sites), on the tarsus (cutaneous lymphoma of the tarsus) and where there was a previous fracture (CNEL associated with a fracture site) (1,5,6,14). These can manifest as edematous swelling, a nodule, or a subcutaneous mass (1,5,6). Cats with these more atypical lesions represent distinct forms of cutaneous lymphoma, reinforcing the point that it should always be a differential diagnosis for any swelling, nodule or mass within the dermis or subcutis, irrespective of bodily location. Moreover, it is unclear how long lesions are observed before diagnosis; this can range from possibly months to years versus rapid progression, where lymphatic and systemic dissemination can occur within days (1,2,5,6,14).

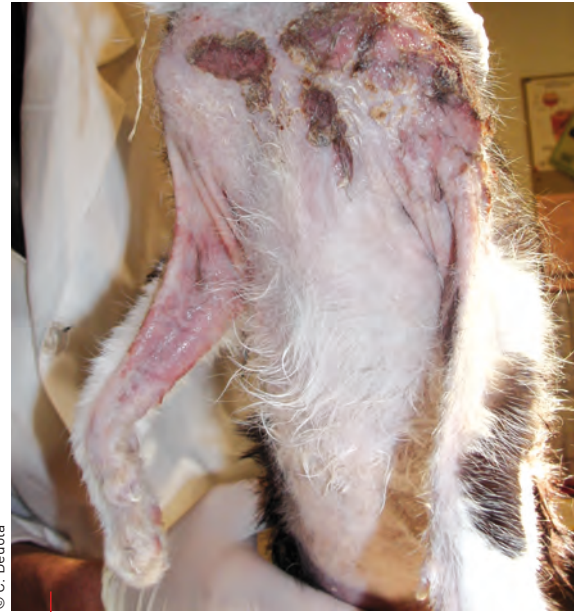CNEL has been defined as a diffuse, poorly differentiated lymphocytic lymphoma (2), thus making it difficult to separate from other cutaneous round cell tumors, histiocytic proliferative disorders and advanced mycosis fungoides. More recent case reports that include histopathology describe an infiltrative growth of well-differentiated lymphocytic tumor cells, medium-to-large in size, between the corium and subcutis (5,14). Additionally, for the CNEL subgroups, shared histopathological findings include neoplastic cells arranged in sheets with high mitotic indices and areas of necrosis (1,5,6).

CNEL is a disease of either T- or B-cell immunophenotype and this has been neatly demonstrated by two separate studies. In one study more cats were classified as having B-cell lymphoma than T-cell (6), whereas the opposite occurred in the other report (1). Immunophenotyping was achieved via immunohistochemistry and the specific identification of surface antigens expressed by the neoplastic lymphocytes: CD3 by T-cells and CD79 by B-cells (1,6). However, CNEL predominantly has a T-cell phenotype, and diagnosis of a B-cell tumor is generally considered extremely rare (1,6,7).



**“When managing a case of suspected feline cutaneous lymphoma, early diagnosis is key to an improved prognosis; whenever possible skin biopsy should be performed near the start of the diagnostic investigation.”**

Hannah Lipscomb



© C. Dedola

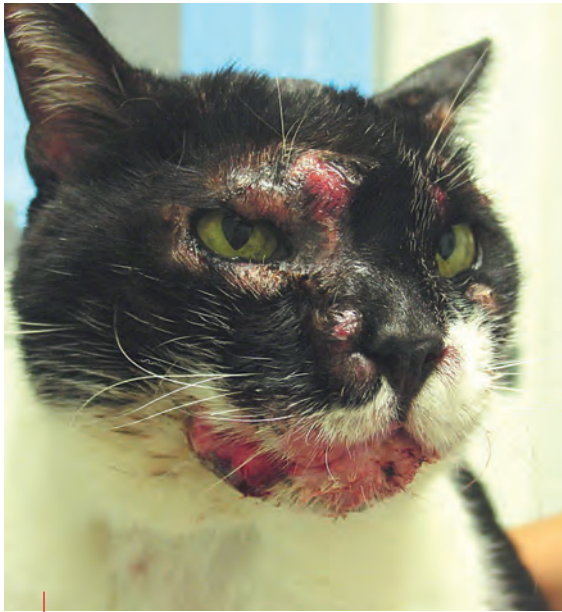**Figure 4.** A cat with CNEL showing alopecia and erythema of the cranioventral thorax and medial aspect of the forelimbs, with severe exudative ulceration and crusting over the left shoulder. There is an eroded and crusted lesion over the right clavicle and the skin on the medial aspect of the right forelimb is eroded.

## ●●●● Treatment – CETL

Evidence-based medicine for the treatment of CETL in cats is scarce and as a result has been adapted from canine or human medicine. First-line treatment in people with localized, superficial or early lesions is skin-directed, namely topical therapy, phototherapy, and photodynamic and radiation therapy. Systemic chemotherapy is considered second-line treatment and reserved for advanced cases and/or palliation (15). The following is an outline of current and evolving treatment modalities for humans and dogs and, with the caveat that most drugs discussed are not licensed for use, could theoretically be applied to cats.

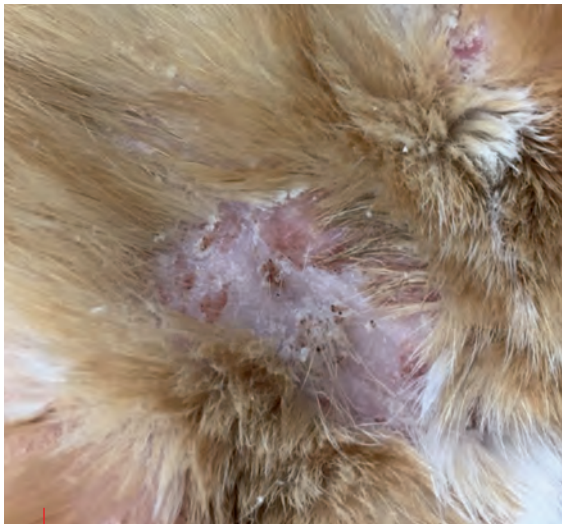
### Topical therapies

Topical corticosteroids are used initially in people with CTCL and work by inhibiting lymphocyte endothelial binding and inducing apoptosis; they have an excellent response rate (82 to 94%) (15). Cats presenting with early lesions could be treated in the same way, the primary aim being to achieve remission or, at the very least, provide symptomatic relief (7). Topical chemotherapy in the form of mechlorethamine has also been used successfully in both people and dogs: in a human study 75% of participants (155 in total) with early lesions completely responded, and for dogs with patch and



© F. Leone

**Figure 5.** CNEL in a cat with facial distribution of multiple adjacent to coalescing plaques and nodules. The skin is partially alopecic, eroded and ulcerated, especially over the right eye and mandibular lip fold.



© R. McFadden

**Figure 6.** Patches of alopecia, erythema, scaling and crusting and multifocal ulcers on the caudal aspect of the head in a cat with CNEL.

plaque-stage lesions a good response has been described (7,15). Application of tretinoin gel has been anecdotally useful in a few dogs with CTCL. This treatment was inspired by the synthetic retinoid bexarotene used in humans (7,15), as topical retinoids selectively bind and activate RX receptors, regulating cellular differentiation, proliferation and apoptosis (15). Another potential topical requiring further research in both human and veterinary medicine is imiquimod, an immunomodulatory agent that has shown antitumor activity in basal cell carcinoma (15).

## Phototherapy, photodynamic therapy and radiation

In human medicine phototherapy (ultraviolet light radiation) is a more researched technique than photodynamic therapy for treatment of CTCL, and various studies support its efficacy in early cases (15). Whereas in veterinary medicine, despite remaining in its infancy, photodynamic therapy has produced exciting results for the remission of cutaneous squamous cell carcinoma and small, non-invasive tumors in cats. The technique involves administration of a tumor-localizing photosensitizer (topical, oral or intravenous) followed by light activation, resulting in tissue damage (16).

Electron beam radiation therapy uses low-energy electrons requiring specialized technology. In human medicine, when the entire skin surface is treated, it is known as total skin electron beam (TSEB) radiation, and is actively used in people with superficial lesions, plaques and tumors that have not responded to topical therapy (15). Initial response to TSEB in selected cases is good; however, relapses are common and there appears to be a correlation between CTCL stage and relapse rate: the more advanced the CTCL, the higher the rate of relapse (15,17). In veterinary medicine TSEB therapy has been investigated for several years and applied to chosen patients; one case report described its use in a dog with chemoresistant CTCL, which induced remission for 19 months (18), but there are no reports of its use in cats.

## Disease-modifying agents and systemic chemotherapy

In human CTCL, as the neoplasm progresses, malignant T-cells proliferate and produce a cytokine imbalance, which is the target of disease-modifying agents. Such agents are used as second-line treatment when skin-directed therapy has failed and/or the disease is more advanced (15). In veterinary medicine the use of synthetic retinoids has been explored and proven favorable due to a discovered non-overlapping toxicity when combined with standard cytotoxic therapy. Systemic retinoids are natural or synthetic analogues of vitamin A that exert profound effects on cellular growth, maturation and differentiation (19). In one study dogs with CTCL were treated with a mixture of synthetic retinoids (isotretinoin and etretinate) with a 42% response rate recorded (20). Unfortunately, their use has not accelerated due to the lag phase between initiation of therapy and clinical effect, and also cost (20).

The most researched treatment option for CETL in veterinary medicine is systemic chemotherapy, and there are various single agent versus multiagent protocols. This is partly because the disease is often already at an advanced stage by the time of diagnosis, requiring a more aggressive approach. Neoplastic lymphocytes remain sensitive to oral corticosteroids, which are reported to have clinical and palliative effects (2,19). Unfortunately,

corticosteroid monotherapy rarely provides long-term effective treatment; they are more efficacious when incorporated into multiagent chemotherapy protocols [19].

Chemotherapy protocols for feline CETL have not yet been determined; in dogs, single agent chemotherapy protocols are most commonly reported. An initial pilot study monitoring the response of 7 dogs, including 5 dogs with epitheliotropic lymphoma, to lomustine revealed that all dogs achieved complete remission [2 months to over a year] [21]. Two retrospective studies published in 2006 evaluated the response of dogs with CTCL to lomustine, and in both approximately 80% of dogs achieved a measurable response. Inevitably the high response rates were accompanied by side effects (myelosuppression and increased hepatic enzymes), and in addition some of the dogs in these studies had previously received other chemotherapy agents and/or were being treated with corticosteroids [19,22,23]. Therefore, despite these studies giving veterinary oncologists and dermatologists the confidence to use lomustine for canine CTCL, more research is required to establish protocols for patients showing chemoresistance versus those that are chemonaive [19]. Due to its efficacy in dogs, lomustine has been recommended for use in cats with CETL [3].

Single agent chemotherapy with L-asparaginase or doxorubicin has also been investigated, but so far only in dogs. A study observing pegylated (polyethylene glycol capsule) L-asparaginase included seven dogs with CTCL, and clinically all initially appeared to improve, but long-term the responses were partial and short-lived [24]. Another prospective study assessed the toxicosis and response of dogs with various neoplasms to pegylated doxorubicin; nine of the cases had CTCL, and three of them went into complete remission



**“In general, cutaneous lymphoma affects older cats, with a median age of onset at 10 years, and there are no apparent breed or sex predispositions. As a corollary to the rarity of feline cutaneous lymphoma, the etiology is still not well understood.”**

Filippo De Bellis

(with a median of 90 days). The report noted that pegylated doxorubicin had a markedly reduced cardiotoxic and myelosuppressive effect compared to free doxorubicin, but remains impractical due to cost [25].

In human medicine multiagent chemotherapy protocols for CTCL have been described, but are not considered superior based on survival rates [15]. Combination chemotherapy has been trialed for dogs with CTCL (with various permutations of prednisolone, vincristine, cyclophosphamide and doxorubicin) and a moderate response noted, with survival times varying from 2 to 6 months [7,19]. COP (cyclophosphamide, vincristine and prednisolone) and CHOP (cyclophosphamide, doxorubicin, vincristine and prednisolone) protocols have also been used in a small case series of canine CTCL and one case report of feline CETL, with moderate success [4,7,13,19].

## Other options

Other treatment options for feline cutaneous lymphoma include placentary lysate, surgical excision of solitary lesions, and fibronectin (local and intravenous) [3,6]. Fibronectin is a glycoprotein with the antineoplastic ability to opsonize target cells for macrophagic and monocytic destruction [3]. Despite publication of different treatment modalities, none have been supported by an adequate case series with reliable treatment response and survival rates [6], and all require further research in the field.

## Multimodal and symptomatic treatment

A multimodal treatment approach does not seem to improve survival rates in people with CTCL, but it does successfully increase complete response rates. Nonetheless, combining treatment modalities with non-overlapping toxicities (e.g., excision of a mass with adjunctive chemotherapy) is a rational protocol and should be adopted for chosen veterinary patients. Importantly, symptomatic treatment (e.g., analgesia and antibiotics) should be initiated parallel to the conventional treatment plan to optimize quality of life, especially in palliative cases [19].



## Treatment – CNEL

As CNEL is less common in dogs, insufficient research has been performed to create a foundation for treatment recommendations, and consequently there is no standard of care for treating feline CNEL. Despite this, relevant publications exist which help make an evidence-based decision for therapy options. Two case reports of cats with CNEL detail the therapeutic approach elected and response experienced: one cat treated with lomustine went into complete remission for approximately 4 months, and the other received a modified CHOP protocol, achieving maintenance for a total of 4 weeks [5,14].

A retrospective study of 23 cats with tarsal CNEL reported that treating affected cases with combination therapy (radiation and chemotherapy) or surgery (with or without chemotherapy) led to a significantly longer mean survival time compared to a monotherapy approach (corticosteroids or chemotherapy), at 316 days versus 155 days (6). Cats being treated for CNEL should of course also receive multimodal and symptomatic treatment (as above) when appropriate.

## Prognosis

With little information available for feline cutaneous lymphoma it is difficult to comment on prognosis. In humans, survival rates are determined by the type of CTCL diagnosed; for example, Sézary syndrome has a worse prognosis than mycosis fungoides [33% versus 89-93% 5-year survival rate] (3) although in general the prognosis of CTCL in people is considered good (15). Dogs diagnosed with early CTCL and treated appropriately may survive beyond 12 months, whereas dogs diagnosed with an advanced version may only live for another 6 months, regardless of response to treatment (19). In cats the median survival time reported for CETL is approximately 10 months, but for CNEL the prognosis is graver, with a median survival time of 4 to 8 months (3,7).

## CONCLUSION

Cutaneous lymphoma is a rare neoplasm in cats, and little has been published about the manifestation, treatment and prognosis of the two forms. However, when managing a case of suspected feline cutaneous lymphoma early diagnosis is key to an improved prognosis; whenever possible skin biopsy should be performed near the start of the diagnostic investigation. For treatment, an outline of standard of care has not been defined and undeniably requires further research, but on review cats have generally been treated with systemic chemotherapy, and where appropriate a multimodal approach should be adopted to optimize treatment response. Additionally, alongside the main therapeutic, symptomatic treatment should be initiated to enhance quality of life, particularly for cats being treated palliatively.



## REFERENCES

- Roccabianca P, Avallone G, Rodriguez A, et al. Cutaneous lymphoma at injection sites: pathological, immunophenotypical, and molecular characterization in 17 cats. *Vet Pathol* 2016;53(4):823-832.
- Moore PF, Olivry T. Cutaneous lymphoma in companion animals. *Clin Dermatol* 1994;12(4):499-505.
- Fontaine J, Heimann M, Day MJ. Cutaneous epitheliotropic T-cell lymphoma in the cat: a review of the literature and five new cases. *Vet Dermatol* 2011;22(5):454-461.
- Schmidt V. Epitheliotropic T-cell cutaneous lymphoma in dogs. *UK Vet Comp Anim* 2011;16(3):49-54.
- Jegatheeson S, Wayne J, Brockley LK. Cutaneous non-epitheliotropic T-cell lymphoma associated with a fracture site in a cat. *J Feline Med Surgery Open Reports* 2018;4(1):1-6.
- Burr HD, Keating JH, Clifford CA, et al. Cutaneous lymphoma of the tarsus in cats: 23 cases (2000-2012). *J Am Vet Med Assoc* 2014;244(12):1429-1434.
- Miller Jr WH, Griffin CE, Campbell KL. Neoplastic and Non-Neoplastic Tumours. In: Duncan L, Rudolph P, Graham B, et al (eds). *Muller and Kirk's Small Animal Dermatology*. 7<sup>th</sup> ed. Missouri: Elsevier Mosby, 2013;810-815.
- Beatty J. Viral causes of feline lymphoma: retroviruses and beyond. *Vet J* 2014;201(2):174-180.
- Tobey JC, Houston DM, Breur GJ, et al. Cutaneous T-cell lymphoma in a cat. *J Am Vet Med Assoc* 1994;204(4):606-609.
- Scott DW. Feline Dermatology 1983-1985: "the secret sits". *J Am Anim Hosp Assoc* 1987;23:255-274.
- Wood C, Almes K, Bagladi-Swanson M, et al. Sézary syndrome in a cat. *J Am Anim Hosp Assoc* 2008;44(3):144-148.
- Rook KA. Canine and feline cutaneous epitheliotropic lymphoma and cutaneous lymphocytosis. *Vet Clin North Am Small Anim Pract* 2019;49(1):67-81.
- Neta M, Naigamwalla D, Bienzle D. Perforin expression in feline epitheliotropic cutaneous lymphoma. *J Vet Diagn Invest* 2008;20(6):831-835.
- Komori S, Nakamura S, Takahashi K, et al. Use of lomustine to treat cutaneous nonepitheliotropic lymphoma in a cat. *J Am Vet Med Assoc* 2005;226(2):237-239.
- Knobler E. Current management strategies for cutaneous T-cell lymphoma. *Clin Dermatol* 2004;22(3):197-208.
- Buchholz J, Heinrich W. Veterinary photodynamic therapy: a review. *Photodiagnosis Photodyn Ther* 2013;10(4):342-347.
- Jones GW, Hoppe RT, Glatstein E. Electron beam treatment for cutaneous T-cell lymphoma. *Hematol Oncol Clin North Am* 1995;9(5):1057-1076.
- Santoro D, Kubicek L, Lu B, et al. Total skin electron therapy as treatment for epitheliotropic lymphoma in a dog. *Vet Dermatol* 2017;28(2):246-e65.
- De Lorimier LP. Updates on the management of canine epitheliotropic cutaneous T-cell lymphoma. *Vet Clin North Am Small Anim Pract* 2006;36(1):213-228.
- White SD, Rosychuk RA, Scott KV, et al. Use of isotretinoin and etretinate for the treatment of benign cutaneous neoplasia and cutaneous lymphoma in dogs. *J Am Vet Med Assoc* 1993;202(3):387-391.
- Graham JC, Myers RK. Pilot study on the use of lomustine (CCNU) for the treatment of cutaneous lymphoma in dogs. In: *Proceedings, 17<sup>th</sup> Annual Meeting Veterinary Internal Medicine Forum* 1999;723.
- Risbon RE, De Lorimier LP, Skorupski K, et al. Response of canine cutaneous epitheliotropic lymphoma to lomustine (CCNU): a retrospective study of 46 cases (1999-2004). *J Vet Intern Med* 2006;20(6):1389-1397.
- Williams LE, Rassnick KM, Power HT, et al. CCNU in the treatment of canine epitheliotropic lymphoma. *J Vet Intern Med* 2006;20(1):136-143.
- Moriello KA, MacEwen EG, Schultz KT. PEG-L-asparaginase in the treatment of canine epitheliotropic lymphoma and histiocytic proliferation dermatitis. In: Ihrke PJ, Mason IS, White SD (eds). *Advances in Veterinary Dermatology* Vol. 2. UK: Pergamon Press, 1993;293-299.
- Vail DM, Kravis LD, Cooley AJ, et al. Preclinical trial of doxorubicin entrapped in sterically stabilized liposomes in dogs with spontaneously arising malignant tumours. *Cancer Chemother Pharmacol* 1997;39(5):410-416.



# ELIZABETHAN COLLARS FOR CATS



## Anne Quain,

BA, BScVet, BVSc, MVetStud, GradCertEdStud (HigherEd), Dip. ECAWBM (AWSEL), School of Veterinary Science, University of Sydney, Australia

Dr. Quain graduated from the University of Sydney in 2005 and currently splits her time between working in private companion animal practice and teaching at the Sydney School of Veterinary Science. She is a member of the Australian and New Zealand College of Veterinary Scientists Animal Welfare Chapter and is a Diplomate of the European College of Animal Welfare and Behaviour Medicine in Animal Welfare Science, Ethics and Law. She recently co-authored the textbook *Veterinary Ethics: Navigating Tough Cases*.

## KEY POINTS

Elizabethan collars are an important non-pharmacological means of preventing self-trauma in feline patients, but they may negatively impact a cat's behavior and welfare.

1

Suitable alternative or adjunctive interventions may be an option for some cats, but comprehensive communication with the owners can help mitigate a collar's negative effects.

2

An Elizabethan collar is often used when a cat is itchy, but they can also be detrimental to an animal's wellbeing; this short paper considers the pros and cons of the "plastic cone".

## Introduction

Elizabethan collars are a commonly used, non-pharmacological intervention employed to prevent self-trauma and overgrooming in feline patients. However, they may also cause distress to both cats and their owners [1]; understanding the potential negative impacts of such collars may help veterinarians minimize this distress while maximizing the benefits of the collars when they are used.

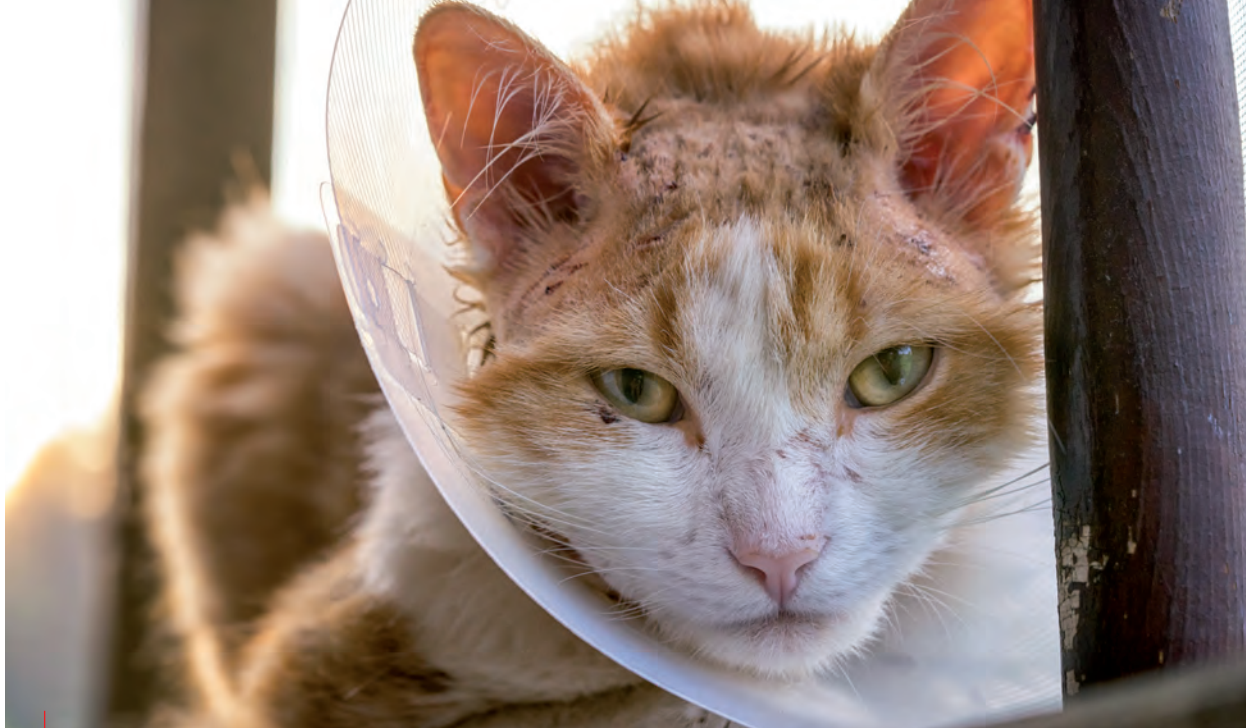## What are the benefits?

Because cats are fastidious groomers, they are prone to removing sutures and traumatizing surgical sites, particularly on the body, limbs and tail. Moreover, the presence of pruritus because of a dermatological problem can lead to self-trauma and exacerbation of the condition (**Figure 1**). A well-fitted Elizabethan collar can often help, by allowing skin lesions to heal, wounds to repair and preventing the need for additional surgery; **Box 1** offers a detailed list of indications for their use. In addition, the collars are inexpensive and may be applied by owners at home as well as members of the veterinary team at the clinic.

## What are the downsides?

Many owners, and cat owners in particular, report that their pet dislikes wearing an Elizabethan collar. This was confirmed in a recent global survey involving the owners of dogs and cats that had worn an Elizabethan collar during the previous 12 months (n=434), with 77% of owners reporting that their companion animal had a worse quality of life when wearing the collar [2]. To compound the problem, some pets may be required to wear a collar for extended periods of time. In a case series of 13 cats medically managed for deep ulcerative keratitis, the mean duration of Elizabethan collar use was 28 days, with a range of 13 to 73 days [3]. Owners reported that some animals seemed to acclimatize to the collar over time, while others apparently did not.

It can be challenging to determine whether the behavioral changes seen in cats wearing Elizabethan collars are due to the collars themselves, or the underlying reasons for cats being required to wear them. For example, in one study looking at behavioral changes and severity of pain in cats recovering from elective neutering,



**Figure 1.** An Elizabethan collar may be useful to prevent a cat from inflicting self-trauma due to pruritus resulting from a skin problem.

wearing an Elizabethan collar significantly affected the overall extent of behavior changes in female cats (4). The most commonly reported alterations in this study included overall activity level, amount of time sleeping, playfulness and movement, but it can be argued that major surgery such as neutering could directly lead to these changes in behavior anyway.

Although many cats will wear Elizabethan collars without any apparent adverse effects, the welfare of some individuals can be negatively impacted by the collars. Another study noted that owners reported Elizabethan collars interfered with various daily feline activities including drinking (60.2%), playing (67.5%), and other actions such as toileting, grooming and being fitted for a harness or lead (2). Some owners also noted dramatic changes in their cat's behavior, including agitation, altered posture or gait, or "freezing". Other problems have also been reported; in some cases, the Elizabethan collar increased antagonism between cats in multi-cat households, and a collar may prohibit a cat from entering or leaving their house via the cat flap, interfering with their normal routine. Indeed, collars can interfere with an animal's mobility in general, which may increase the risks to cats that have outdoor access while wearing one.

**Box 1.** Indications for Elizabethan collars in cats.

- Prevention of removal of topical medication or patches
- Prevention of over-grooming or self-trauma due to pruritis or anxiety
- Prevention of suture removal following surgery
- Protection of wounds to facilitate healing
- Protection of catheters, dressings or bandages

Elizabethan collars should therefore be the smallest size needed to shield the site requiring protection in order to minimize the impact on movement and daily activities.

Importantly, if the underlying cause of self-trauma is not addressed (for example, if a dermatological problem is not resolved) the cat may continue to suffer from the negative feelings of pruritus or pain, with self-trauma recurring once the collar is removed (5).

## ••• What can be done?

Although Elizabethan collars are often deemed to be necessary to protect cats from themselves, there is no guarantee that some cats (and their



**“Many cats wear Elizabethan collars without any adverse effects, but the welfare of some individuals can be negatively impacted, interfering with daily activities such as drinking, playing, toileting and grooming.”**

Anne Quain

**Box 2.** Alternative or adjunctive means of preventing self-trauma in cats.

- Anti-pruritic medication
- Wound dressing
- Topical (non-toxic) bitterants
- Pre-, peri- and post-operative analgesia
- Multi-modal analgesia, extending into at-home care
- Sedation
- Anxiolytic medication

owners) will accept the collar within a reasonable time frame once applied. Because of this, veterinarians can and should consider alternative or adjunctive methods of preventing self-trauma (**Box 2**), which may eliminate the need for an Elizabethan collar entirely, or at least reduce the duration for which they are required to be worn.

If an Elizabethan collar is to be worn, discussion with the cat's owners is essential, as they play an important role in minimizing the negative impacts and maximizing the benefits of the collar (**Figure 2**). It is therefore essential to communicate the following information.

- The reason their cat needs to wear the Elizabethan collar and the potential implications if this is removed prematurely (such as worsening of the skin problem, wound breakdown, or requirements for additional surgery and the associated risks and costs).
- The fact that some cats may have trouble performing certain activities, and may require some assistance (for example, elevating food and water bowls to make these accessible while the



© Shutterstock

**Figure 2.** The veterinary team should carefully discuss the use of a collar when the patient is initially fitted with one in order to minimize the negative impacts and maximize the benefits.

collar is on, removing the hood from a hooded litter tray, or providing alternative access if the collar makes use of a cat flap impossible).

- The potential risks of misadventure during unsupervised outdoor access for cats wearing a collar.
- How to remove, replace and adjust the collar (in case the owner removes the collar to help their cat eat or drink).
- The importance of contacting the veterinary hospital if they feel that their cat is not coping well with the collar.



## CONCLUSION

Elizabethan collars are currently a necessary means of preventing self-trauma in some feline patients. The veterinary team can assist both cats and their owners by providing clear advice about the purpose of the collar, and the potential complications that can arise whilst in use, including transient impacts on feline behavior. Clinic staff can also help owners troubleshoot problems with collars and advise on strategies to maximize the comfort of cats whilst wearing them. Finally, veterinarians can consider alternative or adjunctive means of preventing self-trauma in cats, which may eliminate the need for an Elizabethan collar altogether, or at least reduce the duration of wear.



## REFERENCES

1. Noli C, Borio S, Varina A, *et al.* Development and validation of a questionnaire to evaluate the quality of life of cats with skin disease and their owners, and its use in 185 cats with skin disease. *Vet Dermatol* 2016;27:247-e58.
2. Shenoda Y, Ward MP, McKeegan D, *et al.* "The Cone of Shame": Welfare implications of Elizabethan collar use on dogs and cats as reported by their owners. *Animals* 2020;10:333.
3. Martin De Bustamante MG, Good KL, Leonard BC, *et al.* Medical management of deep ulcerative keratitis in cats: 13 cases. *J Feline Med Surg* 2019;21:387-393.
4. Väisänen MA, Tuomikoski SK, Vainio OM. Behavioral alterations and severity of pain in cats recovering at home following elective ovariohysterectomy or castration. *J Am Vet Med Assoc* 2007;231:236-242.
5. Titeux E, Gilbert C, Briand A, *et al.* From feline idiopathic ulcerative dermatitis to feline behavioral ulcerative dermatitis: grooming repetitive behaviors indicators of poor welfare in cats. *Frontiers Vet Sci* 2018;5:81-81.

# TAKE A COMPLETE NUTRITIONAL APPROACH TO ALLERGIC DERMATITIS

Allergic dermatitis is complex to diagnose and could lead to frustration for pet owners.

Thanks to 50 years of science, obsessive observation and partnerships with veterinarians, we know that targeted nutrition can be used from diagnostic to long-term management.

This is why we have developed an extensive range of nutritional solutions tailored to answer every stage of your clinical approach, including **ANALLERGENIC** product, your first choice for AFR\* dietary elimination trials.

